

# World Journal of *Clinical Cases*

*World J Clin Cases* 2021 September 16; 9(26): 7614-7962



## Contents

Thrice Monthly Volume 9 Number 26 September 16, 2021

## EDITORIAL

- 7614 Advances in deep learning for computed tomography denoising  
*Park SB*

## REVIEW

- 7620 Spirituality, religiousness, and mental health: A review of the current scientific evidence  
*Lucchetti G, Koenig HG, Lucchetti ALG*
- 7632 Role of hospitalization for inflammatory bowel disease in the post-biologic era  
*Soriano CR, Powell CR, Chiorean MV, Simianu VV*

## MINIREVIEWS

- 7643 Combined targeted therapy and immunotherapy for cancer treatment  
*Guo CX, Huang X, Xu J, Zhang XZ, Shen YN, Liang TB, Bai XL*

## ORIGINAL ARTICLE

## Basic Study

- 7653 Mechanism of Jianpi Qingchang Huashi Recipe in treating ulcerative colitis: A study based on network pharmacology and molecular docking  
*Zheng L, Wen XL, Dai YC*

## Case Control Study

- 7671 Common bile duct morphology is associated with recurrence of common bile duct stones in Billroth II anatomy patients  
*Ji X, Jia W, Zhao Q, Wang Y, Ma SR, Xu L, Kan Y, Cao Y, Fan BJ, Yang Z*

## Retrospective Cohort Study

- 7682 Efficacy of roxadustat in treatment of peritoneal dialysis patients with renal anaemia  
*Zhu XW, Zhang CX, Xu TH, Jiang GN, Yao L*

## Retrospective Study

- 7693 Clinical metagenomic sequencing for rapid diagnosis of pneumonia and meningitis caused by *Chlamydia psittaci*  
*Yin XW, Mao ZD, Zhang Q, Ou QX, Liu J, Shao Y, Liu ZG*
- 7704 Evaluation of the etiology and risk factors for maternal sepsis: A single center study in Guangzhou, China  
*Lin L, Ren LW, Li XY, Sun W, Chen YH, Chen JS, Chen DJ*

- 7717 Influencing factors for hepatic fat accumulation in patients with type 2 diabetes mellitus

Wu MJ, Fang QL, Zou SY, Zhu Y, Lu W, Du X, Shi BM

- 7729 Clinical effect of peripheral capsule preservation in eyes with silicone oil tamponade

Jiang B, Dong S, Sun MH, Zhang ZY, Sun DW

- 7738 Potential effects of the nursing work environment on the work-family conflict in operating room nurses

Fu CM, Ou J, Chen XM, Wang MY

### Observational Study

- 7750 Effect and satisfaction of outpatient services by precision valuation reservation registration

Jin HJ, Cheng AL, Qian JY, Lin LM, Tang HM

### Randomized Controlled Trial

- 7762 Impact of intravenous dexmedetomidine on postoperative bowel movement recovery after laparoscopic nephrectomy: A consort-prospective, randomized, controlled trial

Huang SS, Song FX, Yang SZ, Hu S, Zhao LY, Wang SQ, Wu Q, Liu X, Qi F

### META-ANALYSIS

- 7772 Comparison of different methods of nasogastric tube insertion in anesthetized and intubated patients: A meta-analysis

Ou GW, Li H, Shao B, Huang LM, Chen GM, Li WC

### CASE REPORT

- 7786 Secondary injuries caused by ill-suited rehabilitation treatments: Five case reports

Zhou L, Zhou YQ, Yang L, Ma SY

- 7798 Gastric *syphilis* mimicking gastric cancer: A case report

Lan YM, Yang SW, Dai MG, Ye B, He FY

- 7805 Low-grade chondrosarcoma of the larynx: A case report

Vučković L, Klisic A, Filipović A, Popović M, Čulafić T

- 7811 Pediatric temporal fistula: Report of three cases

Gu MZ, Xu HM, Chen F, Xia WW, Li XY

- 7818 Treatment for CD57-negative  $\gamma\delta$  T-cell large granular lymphocytic leukemia with pure red cell aplasia: A case report

Xiao PP, Chen XY, Dong ZG, Huang JM, Wang QQ, Chen YQ, Zhang Y

- 7825 Rare neonatal malignant primary orbital tumors: Three case reports

Zhang Y, Li YY, Yu HY, Xie XL, Zhang HM, He F, Li HY

- 7833 Carbon ion radiotherapy for bladder cancer: A case report

Zhang YS, Li XJ, Zhang YH, Hu TC, Chen WZ, Pan X, Chai HY, Wang X, Yang YL

- 7840** Extravasation of chemotherapeutic drug from an implantable intravenous infusion port in a child: A case report  
*Ly DN, Xu HZ, Zheng LL, Chen LL, Ling Y, Ye AQ*
- 7845** Chronic active Epstein-Barr virus infection treated with PEG-asparaginase: A case report  
*Song DL, Wang JS, Chen LL, Wang Z*
- 7850** Omental mass combined with indirect inguinal hernia leads to a scrotal mass: A case report  
*Liu JY, Li SQ, Yao SJ, Liu Q*
- 7857** Critical lower extremity ischemia after snakebite: A case report  
*Lu ZY, Wang XD, Yan J, Ni XL, Hu SP*
- 7863** Migration of the localization wire to the back in patient with nonpalpable breast carcinoma: A case report  
*Choi YJ*
- 7870** Uniportal video-assisted thoracoscopic surgery for complex mediastinal mature teratoma: A case report  
*Hu XL, Zhang D, Zhu WY*
- 7876** Congenital disorder of glycosylation caused by mutation of *ATP6AP1* gene (c.1036G>A) in a Chinese infant: A case report  
*Yang X, Lv ZL, Tang Q, Chen XQ, Huang L, Yang MX, Lan LC, Shan QW*
- 7886** Rare monolocular intrahepatic biliary cystadenoma: A case report  
*Che CH, Zhao ZH, Song HM, Zheng YY*
- 7893** Hepatocellular carcinoma with inferior vena cava and right atrium thrombus: A case report  
*Liu J, Zhang RX, Dong B, Guo K, Gao ZM, Wang LM*
- 7901** Delayed diagnosis of ascending colon mucinous adenocarcinoma with local abscess as primary manifestation: Report of three cases  
*Han SZ, Wang R, Wen KM*
- 7909** Gastrointestinal bleeding caused by syphilis: A case report  
*Sun DJ, Li HT, Ye Z, Xu BB, Li DZ, Wang W*
- 7917** Transient involuntary movement disorder after spinal anesthesia: A case report  
*Yun G, Kim E, Do W, Jung YH, Lee HJ, Kim Y*
- 7923** Diagnosis and treatment of an inborn error of bile acid synthesis type 4: A case report  
*Wang SH, Hui TC, Zhou ZW, Xu CA, Wu WH, Wu QQ, Zheng W, Yin QQ, Pan HY*
- 7930** Malignant fibrous histiocytoma of the bone in a traumatic amputation stump: A case report and review of the literature  
*Zhao KY, Yan X, Yao PF, Mei J*

- 7937** Rare complication of acute adrenocortical dysfunction in adrenocortical carcinoma after transcatheter arterial chemoembolization: A case report  
*Wang ZL, Sun X, Zhang FL, Wang T, Li P*
- 7944** Peripherally inserted central catheter placement in neonates with persistent left superior vena cava: Report of eight cases  
*Chen Q, Hu YL, Li YX, Huang X*
- 7954** Subcutaneous angiolipoma in the scrotum: A case report  
*Li SL, Zhang JW, Wu YQ, Lu KS, Zhu P, Wang XW*

**LETTER TO THE EDITOR**

- 7959** Should people with chronic liver diseases be vaccinated against COVID-19?  
*Chen LP, Zeng QH, Gong YF, Liang FL*

**ABOUT COVER**

Editorial Board Member of *World Journal of Clinical Cases*, Alessandro Leite Cavalcanti, DDS, MSc, PhD, Associate Professor, Department of Dentistry, State University of Paraiba, Campina Grande 58429500, Paraiba, Brazil. alessandrouepb@gmail.com

**AIMS AND SCOPE**

The primary aim of *World Journal of Clinical Cases* (WJCC, *World J Clin Cases*) is to provide scholars and readers from various fields of clinical medicine with a platform to publish high-quality clinical research articles and communicate their research findings online.

WJCC mainly publishes articles reporting research results and findings obtained in the field of clinical medicine and covering a wide range of topics, including case control studies, retrospective cohort studies, retrospective studies, clinical trials studies, observational studies, prospective studies, randomized controlled trials, randomized clinical trials, systematic reviews, meta-analysis, and case reports.

**INDEXING/ABSTRACTING**

The WJCC is now indexed in Science Citation Index Expanded (also known as SciSearch®), Journal Citation Reports/Science Edition, Scopus, PubMed, and PubMed Central. The 2021 Edition of Journal Citation Reports® cites the 2020 impact factor (IF) for WJCC as 1.337; IF without journal self cites: 1.301; 5-year IF: 1.742; Journal Citation Indicator: 0.33; Ranking: 119 among 169 journals in medicine, general and internal; and Quartile category: Q3. The WJCC's CiteScore for 2020 is 0.8 and Scopus CiteScore rank 2020: General Medicine is 493/793.

**RESPONSIBLE EDITORS FOR THIS ISSUE**

Production Editor: Jia-Hui Li; Production Department Director: Yun-Jie Ma; Editorial Office Director: Jin-Lei Wang.

**NAME OF JOURNAL**

*World Journal of Clinical Cases*

**ISSN**

ISSN 2307-8960 (online)

**LAUNCH DATE**

April 16, 2013

**FREQUENCY**

Thrice Monthly

**EDITORS-IN-CHIEF**

Dennis A Bloomfield, Sandro Vento, Bao-Gan Peng

**EDITORIAL BOARD MEMBERS**

<https://www.wjgnet.com/2307-8960/editorialboard.htm>

**PUBLICATION DATE**

September 16, 2021

**COPYRIGHT**

© 2021 Baishideng Publishing Group Inc

**INSTRUCTIONS TO AUTHORS**

<https://www.wjgnet.com/bpg/gerinfo/204>

**GUIDELINES FOR ETHICS DOCUMENTS**

<https://www.wjgnet.com/bpg/gerinfo/287>

**GUIDELINES FOR NON-NATIVE SPEAKERS OF ENGLISH**

<https://www.wjgnet.com/bpg/gerinfo/240>

**PUBLICATION ETHICS**

<https://www.wjgnet.com/bpg/gerinfo/288>

**PUBLICATION MISCONDUCT**

<https://www.wjgnet.com/bpg/gerinfo/208>

**ARTICLE PROCESSING CHARGE**

<https://www.wjgnet.com/bpg/gerinfo/242>

**STEPS FOR SUBMITTING MANUSCRIPTS**

<https://www.wjgnet.com/bpg/gerinfo/239>

**ONLINE SUBMISSION**

<https://www.f6publishing.com>



## Critical lower extremity ischemia after snakebite: A case report

Zi-Ying Lu, Xiao-Dong Wang, Jin Yan, Xiao-Long Ni, Si-Pin Hu

**ORCID number:** Zi-Ying Lu 0000-0001-9790-752X; Xiao-Dong Wang 0000-0003-1371-3926; Jin Yan 0000-0003-0324-4839; Xiao-Long Ni 0000-0002-0497-1459; Si-Pin Hu 0000-0003-1393-8316.

**Author contributions:** Lu ZY and Wang XD were the patient's surgeons, reviewed the literature, and contributed to the drafting of the manuscript; Yan J reviewed the literature and contributed to the drafting of the manuscript; Ni XL analyzed and interpreted the imaging findings; Hu SP reviewed the literature and drafted the manuscript; all authors issued final approval for the version to be submitted.

**Supported by** the 13th FIVE-YEAR Key Project for Traditional Chinese Medicine of Zhejiang Province, No. 2A11951; Basic Public Welfare Research Program of Zhejiang Province, No. LGF21H020002; Clinical Research Fund of Zhejiang Medical Association, No. 2020ZYCA03; and Traditional Chinese Medicine Scientific Research Fund Project of Zhejiang Province, No. 2021ZA038.

**Informed consent statement:** Informed written consent was obtained from the patient for publication of this report and any accompanying images.

**Conflict-of-interest statement:** The authors declare that they have no

**Zi-Ying Lu, Xiao-Dong Wang, Jin Yan, Xiao-Long Ni, Si-Pin Hu**, Department of Vascular Surgery, Tongde Hospital of Zhejiang Province, Hangzhou 310000, Zhejiang Province, China

**Corresponding author:** Xiao-Dong Wang, MD, Chief Doctor, Department of Vascular Surgery, Tongde Hospital of Zhejiang Province, No. 234 Gucui Road, Hangzhou 310000, Zhejiang Province, China. [hzsparks@hotmail.com](mailto:hzsparks@hotmail.com)

### Abstract

#### BACKGROUND

Globally, the estimated annual incidence of snakebites is approximately 5 million, and approximately 100000 deaths occur from snakebites annually. Local tissue reaction, haemorrhagic clotting disorder, nephrotoxicity, and neurotoxicity are very common effects of snake envenomation, but other rarer complications, such as thrombosis, may also occur as a result of underlying disease. In the treatment of snakebite patients, attention should be paid to the patient's underlying diseases to avoid serious and catastrophic consequences secondary to snakebite.

#### CASE SUMMARY

We report a 69-year-old man with critical right lower extremity pain after left foot snakebite 10 d prior without intermittent claudication or atrial fibrillation history. He was diagnosed with acute right lower extremity arterial thrombosis, which may have been caused by coagulopathy after snakebite and lower extremity atherosclerotic occlusive disease. Lower extremity computed tomography angiography at another hospital revealed that the aortoiliac and femoral arteries had neither filling defects nor atherosclerosis, but the right popliteal artery was occluded 2.3 cm below the tibial plateau. The patient received emergency catheter-directed thrombolysis, but amputation was carried out 11 d after admission because the patient had been admitted to the hospital too late to save the extremity.

#### CONCLUSION

Acute ischaemia of the lower extremity due to snakebite is a rare event, and physicians should bear in mind the serious complications that may occur, especially in patients with atherosclerotic disease.

**Key Words:** Critical extremity ischaemia; Snakebite; Thrombosis; Haematological abnormalities; Case Report

©The Author(s) 2021. Published by Baishideng Publishing Group Inc. All rights reserved.

conflicts of interest to report.

# CARE Checklist (2016) statement:

The authors have read the CARE Checklist (2016), and the manuscript was prepared and revised according to those criteria.

**Open-Access:** This article is an open-access article that was selected by an in-house editor and fully peer-reviewed by external reviewers. It is distributed in accordance with the Creative Commons Attribution NonCommercial (CC BY-NC 4.0) license, which permits others to distribute, remix, adapt, build upon this work non-commercially, and license their derivative works on different terms, provided the original work is properly cited and the use is non-commercial. See: <http://creativecommons.org/licenses/by-nc/4.0/>

**Manuscript source:** Unsolicited manuscript

**Specialty type:** Surgery

**Country/Territory of origin:** China

# Peer-review report's scientific quality classification

Grade A (Excellent): 0  
Grade B (Very good): 0  
Grade C (Good): C  
Grade D (Fair): 0  
Grade E (Poor): 0

**Received:** March 30, 2021

**Peer-review started:** March 30, 2021

**First decision:** June 7, 2021

**Revised:** June 8, 2021

**Accepted:** July 30, 2021

**Article in press:** July 30, 2021

**Published online:** September 16, 2021

**P-Reviewer:** Sung WY

**S-Editor:** Wu YXJ

**L-Editor:** Wang TQ

**P-Editor:** Ma YJ



**Core Tip:** We report a 69-year-old man who presented with critical right lower extremity pain and was diagnosed with acute right lower extremity arterial thrombosis that may be caused by coagulopathy after snakebite and arteriosclerosis in lower extremity. Haematological abnormalities are very common with snakebites, but thrombotic manifestations are less common. Physicians should bear in mind the rare complications and devastating sequela of extremity ischemia following snakebite, especially for patients with atherosclerotic disease.

**Citation:** Lu ZY, Wang XD, Yan J, Ni XL, Hu SP. Critical lower extremity ischemia after snakebite: A case report. *World J Clin Cases* 2021; 9(26): 7857-7862

**URL:** <https://www.wjgnet.com/2307-8960/full/v9/i26/7857.htm>

**DOI:** <https://dx.doi.org/10.12998/wjcc.v9.i26.7857>

# INTRODUCTION

Snake envenomation can result in local tissue reactions, coagulopathy, neurotoxicity, and nephrotoxicity[1]. However, thrombotic manifestations are relatively rare. We report a 69-year-old man with acute right lower extremity arterial thrombosis caused by snakebite.

# CASE PRESENTATION

## Chief complaints

A 69-year-old man presented to our facility with critical right lower extremity pain accompanied by gangrene of the right toes.

## History of present illness

The symptoms had started 5 d prior to admission.

## History of past illness

The patient had been bitten by a viper 2 wk prior. He showed no symptoms of shock or hemorrhage after snakebite, and he was sent to a local hospital to be injected with antivenom 3 h later. There was no other relevant past history.

## Personal and family history

No personal or family history was identified.

## Physical examination

Vital sign measurements showed that the blood pressure was 117/65 mmHg and heart rate was 78 beats per minute. Physical examination revealed a 3 cm × 2 cm ulcerated area with a haemorrhagic crust on the left dorsum (Figure 1A); the right foot showed blackening of the skin, accompanied by blister formation and exudate. Tissue necrosis was found on the toes (Figure 1B). There was a normal pulse in the left lower limb arteries and right femoral and popliteal arteries, but the right posterior and dorsal pedal arteries had no pulse.

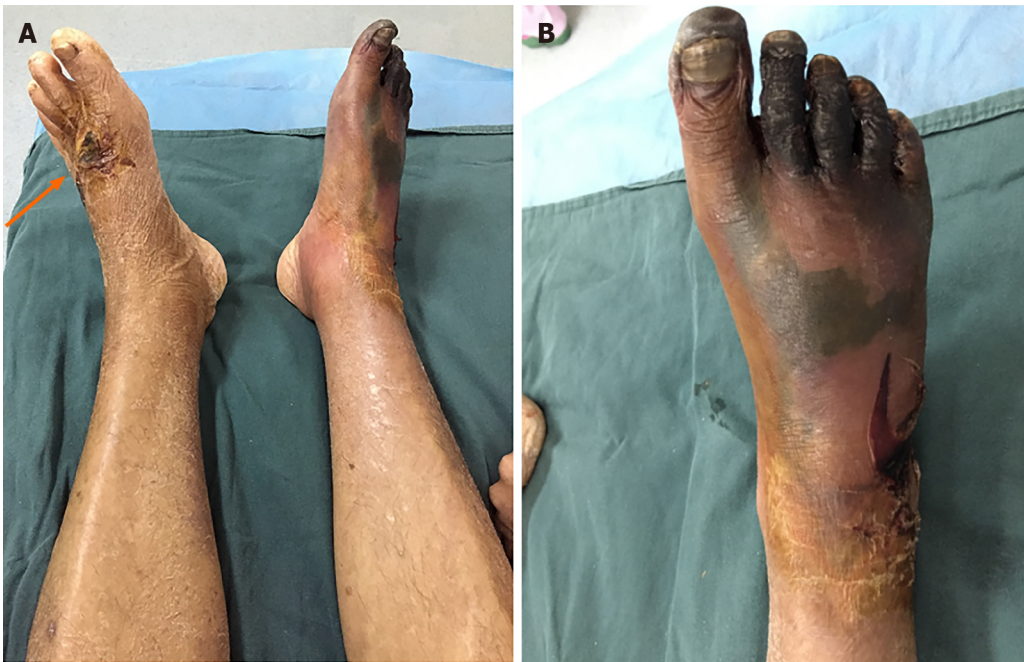## Laboratory examinations

The laboratory results showed a fibrinogen level of 5.50 g/L and D-dimer level of 0.89 mg/L, and normal activated partial thromboplastin time, thrombin time, prothrombin time, and platelet count.

## Imaging examinations

Lower extremity computed tomography angiography revealed that the aorto-iliac and femoral arteries had neither a filling defect nor atherosclerosis, but the right popliteal artery was occluded 2.3 cm below the tibial plateau (the patient did not have a computed tomography film available because the scan was performed at another hospital).





**Figure 1 Physical examinations.** A: The bitten area (orange arrow); B: The skin of the right foot became black in the right foot, accompanied by blister formation and exudate. Tissue necrosis was found on the toes.

## FINAL DIAGNOSIS

With a history of snakebite and the exclusion of embolic diseases, the patient was diagnosed with acute right lower extremity arterial thrombosis and lower extremity atherosclerotic occlusive disease.

## TREATMENT

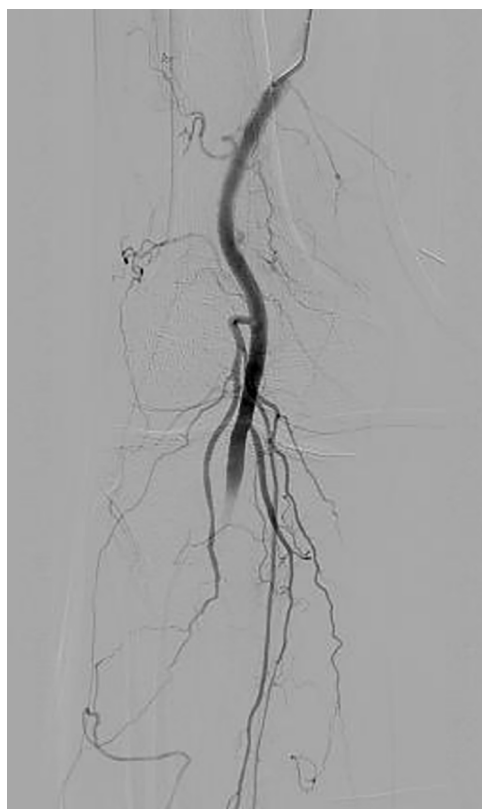
The patient received anticoagulant therapy immediately after admission to our hospital. In an attempt to salvage the limb, the patient was sent promptly for emergent right lower extremity angiography. The guide wire met with resistance when passing through the right popliteal artery; the distal popliteal artery was not visible on angiography, and a large number of lateral branches could be seen (Figure 2). Then he received a 6-d course of catheter-directed thrombolysis (CDT) [a bolus of 300000 U urokinase (UK) was given *via* the catheter with the pulse spray technique in the first operation, followed by a continuous intra-arterial UK infusion at a rate of 50000 U/h through the infusion catheter], therapeutic dose of anticoagulant therapy, and percutaneous balloon dilatation percutaneous transluminal balloon angioplasty (PTA) of the right anterior tibial and peroneal arteries, but the outflow was not significantly improved after PTA (Figure 3A and B). The patient underwent an amputation 9 cm below the right tibial plateau (Figure 3C).

## OUTCOME AND FOLLOW-UP

Eventually, the patient fully recovered and was discharged from the hospital 21 d after admission. He was fitted with a prosthetic leg 6 mo after amputation.

## DISCUSSION

Snake envenomation commonly causes local tissue reactions, coagulopathy, nephrotoxicity, and neurotoxicity[1-3]. Haematological abnormalities are very common with snakebite; however, thrombotic manifestations are very rare.



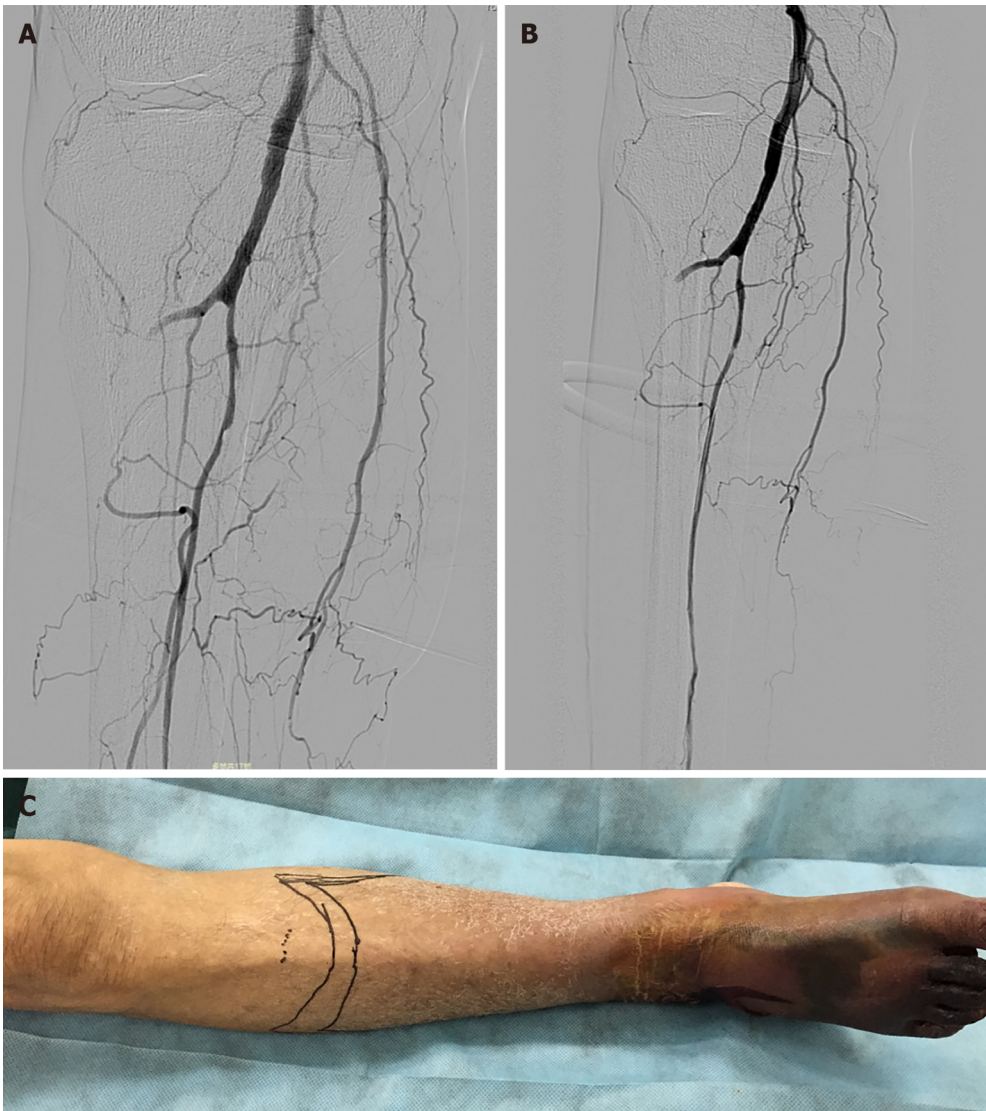**Figure 2** On angiography, the distal popliteal artery was not visible, and a large number of lateral branches could be seen.

In a study in Sweden[4], deep vein thrombosis and myocardial infarction (MI) were less commonly reported complications. In another study[5], cerebral infarction, pulmonary embolism, and MI were common thrombotic events. Roplekar Satish reported a case in which venom caused haemodynamic disorders and abnormal coagulation in a patient, leading to MI[6]. In the present case, we initially believed that the patient's lower extremity arterial thrombosis was due to the hypercoagulable state caused by snake venom, but the resistance that the guide wire encountered when passing through the lower limb arteries and the ineffectiveness of vascular recanalization after thrombolysis therapy suggested that the patient may have had local atherosclerotic stenosis occluded by a thrombus. This also explains why the patient's thrombotic event occurred in the contralateral limb rather than ipsilateral to the snakebite.

Another issue to consider is what role anti-venom therapy played in this patient's course. The patient showed no signs of shock or local or systemic bleeding after snakebite, which showed that venom did not cause hemorrhagic disorder. But he was unable to provide further detailed information, such as blood coagulation function changes before and after antivenin injection, therefore we cannot judge the role of antivenom in the development of the patient's conditions. We guess that the most likely thing is that venom caused the patient's hypercoagulable state, but the antivenom partially alleviated this coagulation dysfunction, so the patient's ischemia was limited to the calf. It reminds us that we need to collect more information when we encounter rare cases in future.

Emergency revascularization is necessary for patients with acute limb ischaemia (ALI) that threatens the survival of the limb[7]. CDT is the preferred method of delivery for ALI[8], especially for ALI with a history of less than 14 d and without movement disorders[9]. The patient missed the optimal time window for treatment. However, CDT treatment enabled a lower plane of amputation, preserved the function of the knee, and enhanced the patient's quality of life.

The mechanism behind thrombotic complications is thought to be the imbalance between the anti-coagulant and pro-coagulant systems in body. The risk of life-threatening bleeding is a major issue with thrombolysis in the context of snakebite, which is known to cause consumption coagulopathy[10]. Changes in coagulation indices as well as clinical symptoms and signs should be closely monitored during thrombolytic therapy. This case showed no manifestations of bleeding or haemo-



**Figure 3 Angiography and physical examinations of the right anterior tibia.** A: On the sixth day of thrombolytic therapy, the proximal right anterior tibial and peroneal arteries were imaged by angiography; B: The right anterior tibial artery and peroneal artery were treated by low-pressure balloon dilatation; C: The amputation level was 9 cm below the right tibial plateau (marked with a marker pen).

dynamic changes, therefore, thrombolytics were deemed safe for him.

## CONCLUSION

Acute ischaemia of the lower extremity due to snakebite is a rare event, but physicians should bear in mind the serious complications and the devastating sequela of lower limb ischaemia following snakebite, especially in patients with atherosclerotic disease.

## REFERENCES

- 1 **Maheshwari M**, Mittal SR. Acute myocardial infarction complicating snake bite. *J Assoc Physicians India* 2004; **52**: 63-64 [PMID: [15633722](#)]
- 2 **Razok A**, Shams A, Yousaf Z. Cerastes cerastes snakebite complicated by coagulopathy and cardiotoxicity with electrocardiographic changes. *Toxicon* 2020; **188**: 1-4 [PMID: [33035563](#) DOI: [10.1016/j.toxicon.2020.10.003](#)]
- 3 **Kim JS**, Yang JW, Kim MS, Han ST, Kim BR, Shin MS, Lee JI, Han BG, Choi SO. Coagulopathy in patients who experience snakebite. *Korean J Intern Med* 2008; **23**: 94-99 [PMID: [18646512](#) DOI: [10.3904/kjim.2008.23.2.94](#)]
- 4 **Karlson-Stiber C**, Salmonson H, Persson H. A nationwide study of Vipera berus bites during one year-epidemiology and morbidity of 231 cases. *Clin Toxicol (Phila)* 2006; **44**: 25-30 [PMID: [16511111](#)]

- 16496490 DOI: [10.1080/15563650500394597](https://doi.org/10.1080/15563650500394597)
- 5 **Thomas L**, Tyburn B, Bucher B, Pecout F, Ketterle J, Rieux D, Smadja D, Garnier D, Plumelle Y. Prevention of thromboses in human patients with Bothrops lanceolatus envenoming in Martinique: failure of anticoagulants and efficacy of a monospecific antivenom. Research Group on Snake Bites in Martinique. *Am J Trop Med Hyg* 1995; **52**: 419-426 [PMID: [7771608](https://pubmed.ncbi.nlm.nih.gov/7771608/) DOI: [10.4269/ajtmh.1995.52.419](https://doi.org/10.4269/ajtmh.1995.52.419)]
- 6 **Niraj M**, Jayaweera JL, Kumara IW, Tissera NW. Acute myocardial infarction following a Russell's viper bite: a case report. *Int Arch Med* 2013; **6**: 7 [PMID: [24499589](https://pubmed.ncbi.nlm.nih.gov/24499589/) DOI: [10.1186/1755-7682-6-7](https://doi.org/10.1186/1755-7682-6-7)]
- 7 **Fluck F**, Augustin AM, Bley T, Kickuth R. Current Treatment Options in Acute Limb Ischemia. *Rofo* 2020; **192**: 319-326 [PMID: [31461761](https://pubmed.ncbi.nlm.nih.gov/31461761/) DOI: [10.1055/a-0998-4204](https://doi.org/10.1055/a-0998-4204)]
- 8 **Björck M**, Earnshaw JJ, Acosta S, Bastos Gonçalves F, Cochenne F, Debus ES, Hinchliffe R, Jongkind V, Koelemay MJW, Menyhei G, Svetlikov AV, Tshomba Y, Van Den Berg JC; Esvs Guidelines Committee, de Borst GJ, Chakfé N, Kakkos SK, Koncar I, Lindholt JS, Tulamo R, Vega de Ceniga M, Vermassen F, Document Reviewers, Boyle JR, Mani K, Azuma N, Choke ETC, Cohnert TU, Fitridge RA, Forbes TL, Hamady MS, Munoz A, Müller-Hülsbeck S, Rai K. Editor's Choice - European Society for Vascular Surgery (ESVS) 2020 Clinical Practice Guidelines on the Management of Acute Limb Ischaemia. *Eur J Vasc Endovasc Surg* 2020; **59**: 173-218 [PMID: [31899099](https://pubmed.ncbi.nlm.nih.gov/31899099/) DOI: [10.1016/j.ejvs.2019.09.006](https://doi.org/10.1016/j.ejvs.2019.09.006)]
- 9 **Writing Committee Members**. Gerhard-Herman MD, Gornik HL, Barrett C, Barshes NR, Corriere MA, Drachman DE, Fleisher LA, Fowkes FGR, Hamburg NM, Kinlay S, Lookstein R, Misra S, Mureebe L, Olin JW, Patel RAG, Regensteiner JG, Schanzer A, Shishehbor MH, Stewart KJ, Treat-Jacobson D, Walsh ME; ACC/AHA Task Force Members, Halperin JL, Levine GN, Al-Khatib SM, Birtcher KK, Bozkurt B, Brindis RG, Cigarroa JE, Curtis LH, Fleisher LA, Gentile F, Gidding S, Hlatky MA, Ikonomidis J, Joglar J, Pressler SJ, Wijeyesundera DN. 2016 AHA/ACC Guideline on the Management of Patients with Lower Extremity Peripheral Artery Disease: Executive Summary. *Vasc Med* 2017; **22**: NP1-NP43 [PMID: [28494710](https://pubmed.ncbi.nlm.nih.gov/28494710/) DOI: [10.1177/1358863X17701592](https://doi.org/10.1177/1358863X17701592)]
- 10 **Satish R**, Kanchan R, Yashawant R, Ashish D, Kedar R. Acute MI in a stented patient following snake bite-possibility of stent thrombosis - a case report. *Indian Heart J* 2013; **65**: 327-330 [PMID: [23809391](https://pubmed.ncbi.nlm.nih.gov/23809391/) DOI: [10.1016/j.ihj.2013.04.029](https://doi.org/10.1016/j.ihj.2013.04.029)]



Published by **Baishideng Publishing Group Inc**  
7041 Koll Center Parkway, Suite 160, Pleasanton, CA 94566, USA

**Telephone:** +1-925-3991568

**E-mail:** [bpgoffice@wjgnet.com](mailto:bpgoffice@wjgnet.com)

**Help Desk:** <https://www.f6publishing.com/helpdesk>

<https://www.wjgnet.com>

