

Microsoft Bing

国内版 国际版

Plexiform angiomyxoid myofibroblastic tumor of the stomach treat

Sign in

ALL IMAGES VIDEOS

27,900 Results Any time

Plexiform angiomyxoid myofibroblastic tumor of stomach: A ...

<https://www.ncbi.nlm.nih.gov/pmc/articles/PMC5067475>

Oct 16, 2016 · Plexiform angiomyxoid myofibroblastic tumor (PAMT) is a rare benign mesenchymal tumor of stomach. Rarity of this kind of tumors and scarce review articles may cause underrecognitio...

Cited by: 6 Author: Laimas Jonaitis, Mindaugas Kiudelis, Pau...

Publish Year: 2016

Plexiform angiomyxoid myofibroblastic tumor of the ...

<https://onlinelibrary.wiley.com/doi/full/10.1002/dc.23572>

Aug 26, 2016 · Plexiform angiomyxoid myofibroblastic tumor (PAMT) is a rare mesenchymal tumor of the stomach. To date, about 40 cases of PAMT have been reported in the literature. This tumor is...

Cited by: 4 Author: Li Liang, Lin Fanzong, Zhang Peixi, Han ...

Publish Year: 2017

W See more

Plexiform angiomyxoid myofibroblastic tumor of stomach: A ...

<https://www.ncbi.nlm.nih.gov/pmc/articles/PMC5067475>

Oct 16, 2016 · **Plexiform angiomyxoid myofibroblastic tumor (PAMT)** is a benign mesenchymal tumor of stomach. To date, only 19 immunohistochemically confirmed cases have been reported in the literature. We report a case of 28-year-old woman with submucosal tumor in the anterior wall of the antrum.

Cited by: 6

Author: Laimas Jonaitis, Mindaugas Kiudelis, Pauli...

Publish Year: 2016

A rare case of plexiform angiomyxoid myofibroblastic tumor ...

<https://www.ncbi.nlm.nih.gov/pmc/articles/PMC6225817>

Sep 20, 2005 · **Plexiform angiomyxoid myofibroblastic tumor (PAMT)** is a rare gastric mesenchymal entity with a peculiar plexiform pattern, bland spindle cells and myxoid stroma rich in arborizing blood vessels. Here we report a 44-year-old Chinese woman with PAMT.

Cited by: 3

Author: Xi Li, Shuangqing Li, Shenghua Xiong, Zhuj...

Publish Year: 2018

Plexiform Angiomyxoid Myofibroblastic Tumor of the Stomach ...

<https://www.ncbi.nlm.nih.gov/pmc/articles/PMC3479767>

Jun 22, 2012 · **Plexiform angiomyxoid myofibroblastic tumor (PAMT)** of the stomach is a recently recognized entity. Because of its rarity, only 22 cases have been reported in the English-language literature and most of these are single case reports. We report two cases of gastric PAMT.

Cited by: 23

Author: Youngran Kang, Wonkyung Jung, In-Gu Do, ...

Publish Year: 2012

Plexiform angiomyxoid myofibroblastic tumor (PAMT) of the ...

<https://www.ncbi.nlm.nih.gov/pmc/articles/PMC3925914>

Jan 15, 2014 · **Plexiform angiomyxoid myofibroblastic tumor (PAMT)** is a rare mesenchymal tumor of the stomach, which consists of spindle cells with myofibroblastic characteristics. PAMT is also called as plexiform angiomyxoma, angiomyxoid tumor or myxofibroma. Miettinen et al. estimated that the frequency of PAMT is less than 1/150 that of GIST [4], but only 27 cases of PAMT have been reported, including the present case ...

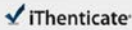
Cited by: 14

Author: Masako Ikemura, Eriko Maeda, Fumihiko H...

21-Jul-2021 10:04AM


3064 words • 24 matches • 10 sources

FAQ

66196_Auto_Edited-IT check.docx

Quoted Excluded
Bibliography Excluded

14%
similarity



Name of Journal: *World Journal of Gastroenterology*

Manuscript NO: 66196

Manuscript Type: CASE REPORT

Plexiform angiomyxoid myofibroblastic tumor treated by endoscopic submucosal dissection: A case report and review of the literature

A case of Plexiform angiomyxoid myofibroblastic tumor

Jian-Di Wu, Yi-Xiong Chen, Chang Luo, Feng-Hua Xu, Lei Zhang, Xiao-Hua Hou, Jun Song

Match Overview

1

Internet 122 words
created on 04-Apr-2021
downloaded from

4%

2

Internet 61 words
created on 06-Apr-2021
www.kciopen.or.kr

2%

3

Crossref 55 words
Lukic-Petrovic, Chandra McCann, Jandic Schwartz, Melissa D
ot, Peter Senarone, Gus Skelton. "Plexiform Angiomyxoid ...

2%

4

Crossref 43 words
Lorden Via (Jackschicht, Raul S, Grotzke, Matthew Martel
8, Chen Liu, Cheryl M, Cullen, John D, Roth. "Plexiform P

2%

5

Internet 33 words
created on 05-Nov-2020
www.vigneti.com

1%

6

Internet 26 words
received on 20-Sep-2019
online.library.wiley.com

1%

7

Internet 19 words
created on 24-Feb-2021
www.tandfonline.com

1%

8

Internet 18 words
created on 20-Nov-2016
TMDX.com




1%

9

Crossref 14 words
Li Xiang, Lin Fangrong, Zhang Pei, Han Caifeng. "Plexi-
om angiomyxoid myofibroblastic tumor of the stomach: A

<1%

PAGE: 1 OF 12

Top Only Report

国内版

国际版

Plexiform angiomyxoid myofibroblastic tumor treated by endoscopy



ALL

IMAGES

VIDEOS

846 Results

Any time ▾

Plexiform angiomyxoid myofibroblastic tumor of stomach: A ...

<https://www.ncbi.nlm.nih.gov/pmc/articles/PMC5067475>

Oct 16, 2016 · Plexiform angiomyxoid myofibroblastic tumor (PAMT) is a rare benign mesenchymal tumor of stomach. Rarity of this kind of tumors and scarce review articles may cause underrecognition of this entity and pose a real diagnostic challenge to gastroenterologists, pathologists and surgeons when encountering such patients and differentiating PAMT from other gastric intramural tumors.

Cited by: 6

Author: Laimas Jonaitis, Mindaugas Kiudelis, Pa...

Publish Year: 2016

A rare case of plexiform angiomyxoid myofibroblastic tumor ...

<https://www.ncbi.nlm.nih.gov/pmc/articles/PMC6225817>

Sep 20, 2005 · Plexiform angiomyxoid myofibroblastic tumor (PAMT) is a rare gastric mesenchymal entity with a peculiar plexiform pattern, bland spindle cells and myxoid stroma rich in arborizing blood vessels. Here we report a 44-year-old Chinese woman with PAMT.

Cited by: 3

Author: Xi Li, Shuangqing Li, Shenghua Xiong, Zh...

Publish Year: 2018

Gastric plexiform fibromyxoma resected by endoscopic ...

<https://www.sciencedirect.com/science/article/pii/S2214330020301176>

Mar 01, 2021 · Plexiform fibromyxoma (PF), also known as plexiform angiomyxoid myofibroblastic tumor (PAMT), was first described in 2007 by Takahashi et al. This rare benign tumor is considered mesenchymal origin typically seen in the stomach and has been adopted by the 2010 WHO classification of tumors of digestive system.

Author: XiaoBo Zhao, XinLou Li, Xin Huang, Le... Publish Year: 2021

Gastric plexiform fibromyxoma resected by endoscopic ...

<https://www.sciencedirect.com/science/article/abs/pii/S2214330020301176>

Gastric plexiform fibromyxoma resected by endoscopic submucosal dissection: A case report and review of literature ... Plexiform fibromyxoma (PF), known as plexiform angiomyxoid myofibroblastic tumor firstly, is derived from gastrointestinal mesenchyme cells, being officially adopted as a distinct benign entity in the 2010 WHO Classification of ...

Author: XiaoBo Zhao, XinLou Li, Xin Huang, Le... Publish Year: 2021