

29,700 Results

Any time ▾

Spinal Epidural Hematoma After Spinal Manipulative Therapy ...

<https://www.sciencedirect.com/science/article/pii/S0161475406001801>

Sep 01, 2006 · Review of the literature revealed 7 reported cases of SEH after manipulation; 5 patients underwent cervical manipulation and 1 patient received Coumadin therapy. Conclusion...

Cited by: 24

Author: James M. Whedon, Patricia B. Quebada,...

Publish Year: 2006

Acute thoracic epidural hematoma following spinal ...

<https://www.sciencedirect.com/science/article/pii/S0303846711000424>

Sep 01, 2011 · Spinal epidural hematoma is a rare complication of chiropractic manipulation. This study reports a case of thoracic spinal epidural hematoma following spinal manipulative therapy i...

Cited by: 9

Author: Tsung-Han Lee, Tsung-Han Lee, Chih-Fen...

Publish Year: 2011

Cervical epidural hematoma after spinal manipulation ...

<https://link.springer.com/article/10.1186/s12891-019-2871-y> ▾

Oct 22, 2019 · Cervical spinal manipulation therapy is a common non-invasive treatment for neck pain and stiffness, and has been widely used in the population. However, most people do not pay attention t...

Author: Qian Chen, Jun-fei Feng, Xin Tang, Yu...

Publish Year: 2019

Cervical Epidural Hematoma That Induced Sudden ...

<https://pubmed.ncbi.nlm.nih.gov/29408299>

Background: Most people understand spinal manipulation therapy to be a safe procedure, and in many cases treatment is provided without a diagnosis if there is musculoskeletal pain. Cervical epidur...

Cited by: 2

Author: Je Il Ryu, Myung Hoon Han, Jae Min Kim...

Publish Year: 2018

Lumbar spinal epidural hematoma after chiropractic ...

<https://www.sciencedirect.com/science/article/pii/S2210794012000077>

Feb 01, 2012 · Serious complications after spinal manipulation therapy are rare, and are most often seen in the cervical region. 1 Spinal epidural hematoma is one of these rare conditions and can cau...

Author: Hung Ming Chen, Lien Chen Wu, Lien...

Publish Year: 2012

Microsoft Bing

国内版 国际版

Spinal epidural hematoma after spinal manipulation therapy: Three

ALL IMAGES VIDEOS

218,000 Results Any time

Spinal Epidural Hematoma After Spinal Manipulative Therapy ...

<https://www.sciencedirect.com/science/article/pii/S0161475406001801>

Sep 01, 2006 - We report on the case of a patient with spinal epidural hematoma (SEH) after spinal manipulative therapy and review features of reported cases of a similar nature. Clinical Features The patient was undergoing Coumadin anticoagulant therapy for atrial fibrillation and presented to the chiropractor complaining of a stiff neck.

Cited by: 24 Author: James M. Whedon, Patricia B. Quebada,...

Publish Year: 2006

Cervical epidural hematoma after spinal manipulation ...

<https://link.springer.com/article/10.1186/s12891-019-2871-y>

Oct 22, 2019 - Reports of epidural hematoma caused by cervical spinal manipulation are rare. We present the case of a patient with tetraplegia and spinal shock after neck manipulation. A physical examination of the patient on admission found tenderness in the neck and increased muscle tension in both upper limbs.

Author: Qian Chen, Jun-fei Feng, Xin Tang, Yu...

Publish Year: 2019

Lumbar spinal epidural hematoma after chiropractic ...

<https://www.sciencedirect.com/science/article/pii/S2210794012000077>

Feb 01, 2013 - Chiropractic spinal manipulation therapy is widely used in individualized practice

Chat with Bing

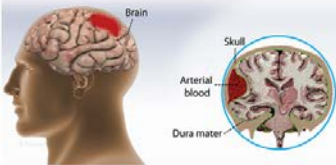
Am I the most talkative search engine?

Say something...

Epidural hematoma

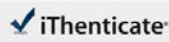Medical Condition

An accumulation of blood between inner surface of the skull and outer layer of the brain



Accumulation of blood between the dura mater (tough outer membrane covering the brain), and the skull. 转到“设置”以删除 Windows...

Common (More than 200,000 cases per year in US)



66538-Manuscript-File-revision.doc

Quotes Excluded
Bibliography Excluded

3%

Spinal epidural hematoma after spinal manipulation therapy: Three case reports and review of literature

Hua Liu, Tao Zhang, Tao Qu, Cheng-Wei Yang, Song-Kai Li

Match Overview

- | | | |
|---|--|----|
| 1 | Crossref 17 words
Liber-Zak, L.D. "Neurologic complications of sit-ups associated with the valsalva maneuver: 2 case reports". Archives | 1% |
| 2 | Crossref 15 words
Min Goo Lee "Cerebellar Embolization in Patients with Hiccup Murmur". Chonnam Medical Journal, 2011 | 1% |
| 3 | Crossref 14 words
Scott Johnson, Lubdith M. Shuh, "Imaging of Acute Low Back Pain". Radiologic Clinics of North America, 2019 | 1% |
| 4 | Internet 14 words
crawled on 28-Apr-2018
academicjournals.org | 1% |

国内版 国际版

Spinal epidural hematoma after spinal manipulation therapy: Three



ALL IMAGES VIDEOS

46,400 Results

Any time ▾

Spinal Epidural Hematoma After Spinal Manipulative Therapy ...

<https://www.sciencedirect.com/science/article/pii/S0161475406001801>

Sep 01, 2006 · We report on the case of a patient with **spinal epidural hematoma (SEH) after spinal manipulative therapy** and review features of reported cases of a similar nature. Clinical Features The patient was undergoing Coumadin anticoagulant therapy for atrial fibrillation and presented to the chiropractor complaining of a stiff neck.

Cited by: 23

Author: James M. Whedon, Patricia B. Quebada,...

Publish Year: 2006

Cervical epidural hematoma after spinal manipulation ...

<https://link.springer.com/article/10.1186/s12891-019-2871-y> ▾

Oct 22, 2019 · Reports of **epidural hematoma** caused by **cervical spinal manipulation** are rare. We present the case of a patient with tetraplegia and spinal shock **after neck manipulation**. A physical examination of the patient on admission found tenderness in the neck and increased muscle tension in both upper limbs.

Author: Qian Chen, Jun-fei Feng, Xin Tang, Yu... Publish Year: 2019

Lumbar spinal epidural hematoma after chiropractic ...

<https://www.sciencedirect.com/science/article/pii/S2210794012000077>

Feb 01, 2012 · Chiropractic **spinal manipulation therapy** is widely used in industrialized countries, **spinal epidural hematoma** being a rare complication of chiropractic manipulation. 3 On reviewing the literature, although the true incidence of chiropractic manipulation for spinal disorder remains uncertain, the annual incidence of **spinal epidural hematoma** has been estimated at 0.1 per 100,000.3, 4, 5. **Spinal epidural hematomas ...**

Author: Hung Ming Chen, Lien Chen Wu, Lien... Publish Year: 2012

Cervicothoracic epidural hematoma after chiropractic ...

<https://www.ncbi.nlm.nih.gov/pubmed/17977203>

A **spinal epidural hematoma** is an extremely rare complication of **cervical spine manipulation therapy (CSMT)**. The authors present the case of an adult woman, otherwise in good health, who developed Brown-Séquard syndrome after CSMT. Decompressive surgery performed within 8 hours after the onset of symptoms allowed for complete recovery of the patient's preoperative neurological deficit.

Cited by: 21

Author: Maurizio Domenicucci, Alessandro Rami...