


World Journal of *Gastrointestinal Surgery*

World J Gastrointest Surg 2021 November 27; 13(11): 1293-1522



REVIEW

- 1293** Acute appendicitis—advances and controversies
Teng TZJ, Thong XR, Lau KY, Balasubramaniam S, Shelat VG

MINIREVIEWS

- 1315** Application and progress of medical imaging in total mesopancreas excision for pancreatic head carcinoma
Feng P, Cheng B, Wang ZD, Liu JG, Fan W, Liu H, Qi CY, Pan JJ
- 1327** Retrorectal tumors: A challenge for the surgeons
Balci B, Yildiz A, Leventoglu S, Montes B
- 1338** Surgical ampullectomy: A comprehensive review
Scroggie DL, Mavroeidis VK
- 1351** Is surgery the best treatment for elderly gastric cancer patients?
Kawaguchi Y, Akaike H, Shoda K, Furuya S, Hosomura N, Amemiya H, Kawaida H, Kono H, Ichikawa D

ORIGINAL ARTICLE

Case Control Study

- 1361** Nomogram for predicting chylous ascites after right colectomy
Zheng HD, Liu YR, Chen ZZ, Sun YF, Xu CH, Xu JH
- 1372** Comparison of safety, efficacy, and long-term follow-up between “one-step” and “step-up” approaches for infected pancreatic necrosis
Zheng Z, Lu JD, Ding YX, Guo YL, Mei WT, Qu YX, Cao F, Li F

Retrospective Study

- 1390** Risk of station 12a lymph node metastasis in patients with lower-third gastric cancer
Dong YP, Cai FL, Wu ZZ, Wang PL, Yang Y, Guo SW, Zhao ZZ, Zhao FC, Liang H, Deng JY
- 1405** Choice of operative method for pancreaticojejunostomy and a multivariable study of pancreatic leakage in pancreaticoduodenectomy
Liang H, Wu JG, Wang F, Chen BX, Zou ST, Wang C, Luo SW
- 1414** Laparoscopic vs open surgery in ileostomy reversal in Crohn’s disease: A retrospective study
Wan J, Yuan XQ, Wu TQ, Yang MQ, Wu XC, Gao RY, Yin L, Chen CQ

- 1423** Preoperative serum carbohydrate antigen 19-9 levels predict early recurrence after the resection of early-stage pancreatic ductal adenocarcinoma

Hong S, Song KB, Hwang DW, Lee JH, Lee W, Jun E, Kwon J, Park Y, Park SY, Kim N, Shin D, Kim H, Sung M, Ryu Y, Kim SC

- 1436** Patients with *Clostridium difficile* infection and prior appendectomy may be prone to worse outcomes

Shaikh DH, Patel H, Munshi R, Sun H, Meher Shahi S, Baiomi A, Alemam A, Pirzada U, Nawaz I, Naher K, Hanumanthu S, Nayudu S

Observational Study

- 1448** Novel roles of lipopolysaccharide and TLR4/NF- κ B signaling pathway in inflammatory response to liver injury in Budd-Chiari syndrome

Li J, Chen XM, Zhou CZ, Fang WW, Lv WF, Cheng DL

- 1463** Long-term survival of patients with stage II and III gastric cancer who underwent gastrectomy with inadequate nodal assessment

Desiderio J, Sagnotta A, Terrenato I, Garofoli E, Mosillo C, Trastulli S, Arteritano F, Tozzi F, D'Andrea V, Fong Y, Woo Y, Bracarda S, Parisi A

- 1484** Defecation disorders are crucial sequelae that impairs the quality of life of patients after conventional gastrectomy

Nakada K, Ikeda M, Takahashi M, Kinami S, Yoshida M, Uenosono Y, Terashima M, Oshio A, Kodera Y

SYSTEMATIC REVIEWS

- 1497** Is omentectomy necessary in the treatment of benign or malignant abdominal pathologies? A systematic review

Atay A, Dilek ON

SCIENTOMETRICS

- 1509** Global trends in research related to sleeve gastrectomy: A bibliometric and visualized study

Barqawi A, Abushamma FA, Akkawi M, Al-Jabi SW, Shahwan MJ, Jairoun AA, Zyoud SH

ABOUT COVER

Editorial Board Member of *World Journal of Gastrointestinal Surgery*, Ali Coskun, MD, Associate Professor, Doctor, Department of General Surgery, Izmir Bozyaka Training and Research Hospital, Izmir 35380, Turkey. dralicoskun3564@hotmail.com

AIMS AND SCOPE

The primary aim of *World Journal of Gastrointestinal Surgery* (WJGS, *World J Gastrointest Surg*) is to provide scholars and readers from various fields of gastrointestinal surgery with a platform to publish high-quality basic and clinical research articles and communicate their research findings online.

WJGS mainly publishes articles reporting research results and findings obtained in the field of gastrointestinal surgery and covering a wide range of topics including biliary tract surgical procedures, biliopancreatic diversion, colectomy, esophagectomy, esophagostomy, pancreas transplantation, and pancreatectomy, etc.

INDEXING/ABSTRACTING

The WJGS is now abstracted and indexed in Science Citation Index Expanded (SCIE, also known as SciSearch®), Current Contents/Clinical Medicine, Journal Citation Reports/Science Edition, PubMed, and PubMed Central. The 2021 edition of Journal Citation Reports® cites the 2020 impact factor (IF) for WJGS as 2.582; IF without journal self cites: 2.564; 5-year IF: 3.378; Journal Citation Indicator: 0.53; Ranking: 97 among 212 journals in surgery; Quartile category: Q2; Ranking: 73 among 92 journals in gastroenterology and hepatology; and Quartile category: Q4.

RESPONSIBLE EDITORS FOR THIS ISSUE

Production Editor: Rui-Rui Wu, Production Department Director: Xiang Li, Editorial Office Director: Ya-Juan Ma.

NAME OF JOURNAL

World Journal of Gastrointestinal Surgery

ISSN

ISSN 1948-9366 (online)

LAUNCH DATE

November 30, 2009

FREQUENCY

Monthly

EDITORS-IN-CHIEF

Shu-You Peng, Varut Lohsiriwat, Jin Gu

EDITORIAL BOARD MEMBERS

<https://www.wjgnet.com/1948-9366/editorialboard.htm>

PUBLICATION DATE

November 27, 2021

COPYRIGHT

© 2021 Baishideng Publishing Group Inc

INSTRUCTIONS TO AUTHORS

<https://www.wjgnet.com/bpg/gerinfo/204>

GUIDELINES FOR ETHICS DOCUMENTS

<https://www.wjgnet.com/bpg/gerinfo/287>

GUIDELINES FOR NON-NATIVE SPEAKERS OF ENGLISH

<https://www.wjgnet.com/bpg/gerinfo/240>

PUBLICATION ETHICS

<https://www.wjgnet.com/bpg/gerinfo/288>

PUBLICATION MISCONDUCT

<https://www.wjgnet.com/bpg/gerinfo/208>

ARTICLE PROCESSING CHARGE

<https://www.wjgnet.com/bpg/gerinfo/242>

STEPS FOR SUBMITTING MANUSCRIPTS

<https://www.wjgnet.com/bpg/gerinfo/239>

ONLINE SUBMISSION

<https://www.f6publishing.com>



Retrospective Study

Laparoscopic vs open surgery in ileostomy reversal in Crohn's disease: A retrospective study

Jian Wan, Xiao-Qi Yuan, Tian-Qi Wu, Mu-Qing Yang, Xiao-Cai Wu, Ren-Yuan Gao, Lu Yin, Chun-Qiu Chen

ORCID number: Jian Wan 0000-0002-5922-2375; Xiao-Qi Yuan 0000-0002-4954-3426; Tian-Qi Wu 0000-0002-0103-4806; Mu-Qing Yang 0000-0002-4982-7186; Xiao-Cai Wu 0000-0001-7546-6882; Ren-Yuan Gao 0000-0002-7602-0601; Lu Yin 0000-0002-9060-0178; Chun-Qiu Chen 0000-0002-4248-7414.

Author contributions: Wan J reviewed the literature and drafted the manuscript; Yuan XQ and Wu TQ contributed to data analysis; Wan J, Yuan XQ, Wu TQ, Yang MQ, Yin L, and Chen CQ performed the surgery; Chen CQ, Wu XC, and Gao RY made revision to the manuscript; all authors have approved the submission of this manuscript.

Institutional review board

statement: The study protocol was approved by the Ethics Committee of the Shanghai Tenth People's Hospital Affiliated to the Tongji University School of Medicine (approval No. 21K53).

Informed consent statement: Given that the research was retrospective, the requirement for informed patient consent was waived.

Conflict-of-interest statement: The authors declare that there is no conflict of interest regarding the publication of this article.

Jian Wan, Xiao-Qi Yuan, Tian-Qi Wu, Mu-Qing Yang, Xiao-Cai Wu, Ren-Yuan Gao, Lu Yin, Chun-Qiu Chen, Center for Difficult and Complicated Abdominal Surgery, Shanghai Tenth People's Hospital, School of Medicine, Tongji University, Shanghai 200092, China

Corresponding author: Chun-Qiu Chen, MD, Chief Doctor, Center for Difficult and Complicated Abdominal Surgery, Shanghai Tenth People's Hospital, School of Medicine, Tongji University, No. 301 Yanchangzhong Road, Shanghai 200092, China. chenchunqiu6@126.com

Abstract

BACKGROUND

Although minimally invasive surgery is becoming more commonly applied for ileostomy reversal (IR), there have been relatively few studies of IR for patients with Crohn's disease (CD). It is therefore important to evaluate the potential benefits and risks of laparoscopy for patients with CD.

AIM

To compare the safety, feasibility, and short-term and long-term outcomes of laparoscopic IR (LIR) vs open IR (OIR) for the treatment of CD.

METHODS

The baseline characteristics, operative data, and short-term (30-d) and long-term outcomes of patients with CD who underwent LIR and OIR at our institution between January 2017 and January 2020 were retrieved from an electronic database and retrospectively reviewed.

RESULTS

Of the 60 patients enrolled in this study, LIR was performed for 48 and OIR for 12. There were no statistically significant differences in baseline characteristics, operation time, intraoperative blood loss, days to flatus and soft diet, postoperative complications, hospitalization time, readmission rate within 30 d, length of hospitalization, hospitalization costs, or reoperation rate after IR between the two groups. However, patients in the LIR group more frequently required lysis of adhesions as compared to those in the OIR group (87.5% vs 41.7%, respectively, $P < 0.05$). Notably, following exclusion of patients who underwent enterectomy plus IR, OIR was more advantageous in terms of postoperative recovery of gastrointestinal function and hospitalization costs.

Data sharing statement: No additional data are available.

Country/Territory of origin: China

Specialty type: Gastroenterology and hepatology

Provenance and peer review: Unsolicited article; Externally peer reviewed.

Peer-review report's scientific quality classification

Grade A (Excellent): 0
Grade B (Very good): B
Grade C (Good): 0
Grade D (Fair): 0
Grade E (Poor): 0

Open-Access: This article is an open-access article that was selected by an in-house editor and fully peer-reviewed by external reviewers. It is distributed in accordance with the Creative Commons Attribution NonCommercial (CC BY-NC 4.0) license, which permits others to distribute, remix, adapt, build upon this work non-commercially, and license their derivative works on different terms, provided the original work is properly cited and the use is non-commercial. See: <http://creativecommons.org/licenses/by-nc/4.0/>

Received: April 25, 2021

Peer-review started: April 25, 2021

First decision: July 15, 2021

Revised: July 23, 2021

Accepted: September 8, 2021

Article in press: September 8, 2021

Published online: November 27, 2021

P-Reviewer: Souza JLS

S-Editor: Gao CC

L-Editor: Wang TQ

P-Editor: Li JH



CONCLUSION

The safety and feasibility of LIR for the treatment of CD are comparable to those of OIR with no increase in intraoperative or postoperative complications.

Key Words: Crohn's disease; Laparoscopy; Ileostomy reversal; Intestinal adhesion; Enterolysis; Faster recovery

©The Author(s) 2021. Published by Baishideng Publishing Group Inc. All rights reserved.

Core Tip: Laparoscopic surgery has been shown to promote faster recovery, decrease postoperative pain and morbidity, and improve postoperative quality of life. For Crohn's disease (CD) patients who require IR, laparoscopy greatly improves the rate of enterolysis and reduces the incidence of ileus. Meanwhile, laparoscopy can effectively explore the entire gastrointestinal tract to identify strictures within short segments of the small bowel, while avoiding large incisions. The aim of the present study was to compare the operative data and short-term and long-term outcomes of laparoscopic ileostomy reversal vs open ileostomy reversal to explore the safety and feasibility of laparoscopic ileostomy reversal for CD.

Citation: Wan J, Yuan XQ, Wu TQ, Yang MQ, Wu XC, Gao RY, Yin L, Chen CQ. Laparoscopic vs open surgery in ileostomy reversal in Crohn's disease: A retrospective study. *World J Gastrointest Surg* 2021; 13(11): 1414-1422

URL: <https://www.wjgnet.com/1948-9366/full/v13/i11/1414.htm>

DOI: <https://dx.doi.org/10.4240/wjgs.v13.i11.1414>

INTRODUCTION

A temporary ileostomy is frequently created during low colorectal anastomosis to prevent fistula formation. After intestinal anastomosis, patients with active Crohn's disease (CD) are at a greater risk for anastomotic fistula formation, which often requires ileostomy[1,2] to alleviate symptoms. Given the proclivity for recurrence, ileostomy reversal (IR) is limited to relatively few CD patients[3]. However, as compared with colostoma, ileostoma requires more complex care and is associated with a greater risk for complications[4]. Therefore, in the remission stage of CD, many patients consider IR. Normally, open IR (OIR) is not overly complicated. But, the varying degrees of intestinal adhesions in CD require intraoperative enterolysis[5]. In addition, with the progression of CD, the whole digestive system will inevitably become fibrotic, eventually leading to stricture[6]. Therefore, it is essential to check the whole gastrointestinal tract during IR for patients with CD.

Previous studies have shown that laparoscopic surgery promotes faster recovery, decreases postoperative pain and morbidity, and improves postoperative quality of life[5,7,8]. During open surgery for CD, surgeons often have to explore the entire gastrointestinal tract to avoid missing occult diseased segments and critical proximal strictures. Laparoscopy can effectively explore the entire gastrointestinal tract to identify strictures within short segments of the small bowel, while avoiding large incisions. Although laparoscopy has become more commonly applied in IR[9], relatively few studies have compared OIR with laparoscopic IR (LIR) for CD. It is therefore important to evaluate the potential benefits and risks of LIR in patients with CD. The aim of the present study was to compare the operative data and short-term and long-term outcomes of LIR vs OIR to explore the safety and feasibility of LIR for CD.

MATERIALS AND METHODS

Patients

The study protocol was approved by the Ethics Committee of the Shanghai Tenth People's Hospital Affiliated to the Tongji University School of Medicine (approval No.

21K53) and conducted in accordance with the tenets of the Declaration of Helsinki. The cohort of this retrospective study consisted of 60 patients who underwent IR at our institution from January 2017 to January 2020. Of these 60 patients, LIR was performed for 48 and OIR for 12. The inclusion criteria were age 18-75 years and pathological confirmation of CD. All procedures were performed by two experienced laparoscopic colorectal surgeons. Standardized treatment regimens were used during the perioperative period. The following data were retrieved from the electronic database of Shanghai Tenth People's Hospital: Age, gender, body mass index (BMI), American Society of Anesthesiologists (ASA) physical status classification, duration of ileostomy, duration of CD, history of abdominal surgery, hematologic parameters (WBC, CRP, ESR, ALB, HB, PLT, PT, and APTT), operation time, intraoperative blood loss, enterolysis rate, days to flatus and soft diet, postoperative complications, hospitalization time, readmission rate within 30 days, length of stay, and hospitalization cost. As a long-term outcome, the reoperation rate after IR was determined by telephone interviews.

Preoperative preparation

Preoperative preparation included physical examination, computed tomography, magnetic resonance imaging, ultrasonography, and colonoscopy. Patients in the remission stage of CD were considered for IR.

Surgical procedure

Laparoscopy was performed using the four-port method. Briefly, two transverse sites below the umbilicus were punctured with 12-mm trocars for observation, the right abdomen was punctured with a 5-mm trocar, and the left abdomen was punctured with 5- and 12-mm trocars. The entire gastrointestinal tract was explored laparoscopically to separate the intraperitoneal adhesions at the stoma and the distal intestinal stump (Figure 1A-C). Following incision of the annulus of the skin around the stoma, the stoma and distal intestinal stump were pulled out. If the bowel segment was obviously fibrotic with a stricture, strictureplasty or resection of the strictured segment was performed. The proximal and distal intestines were anastomosed side to side with auto sutures (GIA 80 mm; Medtronic plc, Dublin, Ireland). Then, the openings were closed and the anastomosis was reinforced with 3-0 absorbable sutures. For open surgery, an incision was made directly along the skin around the stoma. Then, the stoma and distal intestinal stump were separated under direct visualization. The anastomosis method was the same as that in the laparoscopic group.

Statistical analysis

All data analyses were conducted using IBM SPSS Statistics for Windows, version 24.0. (IBM Corporation, Armonk, NY, United States) and GraphPad Prism version 8.0 (GraphPad Software Inc., San Diego, CA, United States). Quantitative data are expressed as the mean \pm SD (range). Data were compared using the Student's *t*-test and chi-squared test. A probability (*P*) value of < 0.05 was considered statistically significant.

RESULTS

Baseline characteristics

There were no statistically significant differences in age, gender, BMI, ASA class, duration of ileostomy, CD duration, history of abdominal operation, or hematologic examination between the LIR and OIR groups ($P > 0.05$) (Table 1).

Characteristics of intraoperative and postoperative observation indexes

Postoperative recovery, operation time, intraoperative blood loss, and days to flatus and soft diet were similar between the two groups. Enterolysis was required for 42/48 (87.5%) patients in the LIR group and 5/12 (41.7%) in the OIR group ($P < 0.05$). However, when cases of enterectomy combined with IR were excluded, OIR was still advantageous for patients with CD. In those cases, OIR was superior to LIR in terms of days to flatus (1.7 ± 0.7 d *vs* 2.3 ± 0.6 d, respectively, $P < 0.05$), days to soft diet (2.7 ± 0.7 d *vs* 4.5 ± 1.7 d, respectively, $P < 0.05$), and hospitalization costs (37301 RMB *vs* 57967 RMB, respectively, $P < 0.05$) (Table 2). There was no significant difference in postoperative complications between the LIR and OIR groups (10.4% *vs* 16.7%, respectively). One patient in the LIR group developed an anastomotic fistula after

Table 1 Baseline characteristics

Variable	Laparoscopic (n = 48)	Open (n = 12)	P value
Age, yr, mean (range)	36.5 (18-70)	39.8 (20-73)	NS
Gender, male	36	8	NS
BMI, kg/m ² , mean ± SD	20.2 ± 4.9	20.3 ± 2.9	NS
ASA class			NS
I-II	45	11	
III-IV	3	1	
Duration of ileostomy, mo, mean ± SD (range)	7.6 ± 6.8 (3-48)	13.0 ± 18.5 (3-72)	NS
Disease duration, mo, mean ± SD (range)	46.1 ± 48.7 (3-168)	39.3 ± 33.5 (4-96)	NS
History of abdominal operation	1.4 ± 0.7	1.4 ± 0.9	NS
Hematologic examination			
WBC (/L)	5.2 ± 1.3	5.2 ± 1.0	NS
CRP (mg/L)	5.9 ± 8.9	8.9 ± 17.6	NS
ESR (mm)	15.4 ± 11.5	15.8 ± 6.9	NS
ALB (g/L)	45.4 ± 4.8	43.6 ± 4.0	NS
Hb (g/L)	134.0 ± 18.2	131.0 ± 16.0	NS
PLT (/L)	240.8 ± 105.6	206.3 ± 49.3	NS
PT (s)	11.5 ± 0.9	11.2 ± 0.8	NS
APTT (s)	29.3 ± 3.4	28.2 ± 4.0	NS

BMI: Body mass index; ASA: American Society of Anesthesiologists; WBC: White blood cell count; CRP: C-reactive protein; ESR: Erythrocyte sedimentation rate; ALB: Albumin; Hb: Hemoglobin; PLT: Platelets; PT: Prothrombin time; APTT: Activated partial thromboplastin time; NS: Not significant.

surgery and recovered after continuous double-cannula irrigation, which explains why one patient in the LIR group was hospitalized for 32 d. Another patient developed anastomotic bleeding, which was resolved after hemostasis treatment. One patient with ileus recovered after conservative treatment. Two patients developed incisional infections in both the LIR and OIR groups and recovered after periodic dressing change. As a long-term outcome, the reoperation rate after IR was similar between the LIR and OIR groups. One patient in the LIR group and one in the OIR group underwent enterectomy again at 22 and 24 mo, respectively (Figure 2).

DISCUSSION

The aim of this retrospective study was to compare the feasibility, safety, and short-term and long-term outcomes of LIR *vs* OIR for CD. The results showed that LIR is a safe and feasible technique with acceptable outcomes and, thus, is worthy of further promotion and clinical study.

For high-risk intestinal anastomosis, the use of prophylactic ileostomy can significantly reduce the incidence of anastomotic leakage[10,11]. However, enterostomy is often associated with many complications due to improper management. According to multiple studies, the overall stoma complication rate ranges from 12% to 72%, with the most common complications being retraction, hernia, prolapse, peristomal skin problems, and necrosis, which severely affect the psychosocial status of the patient and the ability to return to normal daily activities[12-14]. Restoration of intestinal continuity by IR is an ideal strategy to improve quality of life. In recent decades, laparoscopic techniques have become increasingly widely applied in gastrointestinal surgery[15,16]. LIR has also attracted the attention of surgeons because this procedure is associated with earlier gastrointestinal recovery, shorter postoperative hospital stay, and lower complication rates[17,18]. However, CD is characterized by extensive intestinal inflammation and thickening of the mesentery and blood vessels, which pose

Table 2 Operative data and short-term (30-d) outcomes

Variable	Ileostomy reversal (without enterectomy)			Ileostomy reversal		
	Laparoscopic (n = 30)	Open (n = 7)	P value	Laparoscopic (n = 48)	Open (n = 12)	P value
Operative time, min	116.5 ± 38.4	117.1 ± 28.6	NS	128.2 ± 41.7	142.5 ± 41.7	NS
Estimated blood loss, mL	69.7 ± 93.1	71.4 ± 94.8	NS	73.1 ± 91.3	94.2 ± 88.1	NS
Days to flatus, d, mean ± SD	2.3 ± 0.6	1.7 ± 0.7	P < 0.05	2.3 ± 0.8	2.0 ± 0.7	NS
Days to soft diet, d, mean ± SD	4.5 ± 1.7	2.7 ± 0.7	P < 0.05	5.1 ± 3.9	3.8 ± 1.4	NS
Total postoperative complication, n (%)	3 (10)	1 (14.3)	NS	5 (10.4)	2 (16.7)	NS
Anastomotic hemorrhage	1	0		1	0	
Anastomotic leakage	0	0		1	0	
Ileus	0	0		1	0	
Wound infection	1	1		2	2	
Reoperation	0	0		0	0	
Readmission after discharge	0	0	-	0	0	-
Length of stay, d, mean ± SD (range)	9.6 ± 2.7 (5-15)	8.6 ± 2.8 (6-15)	NS	10.3 ± 4.0 (5-32)	10.8 ± 3.7 (6-18)	NS
Cost (RMB)	57967	37301	P < 0.05	62916	52274	NS

NS: Not significant.

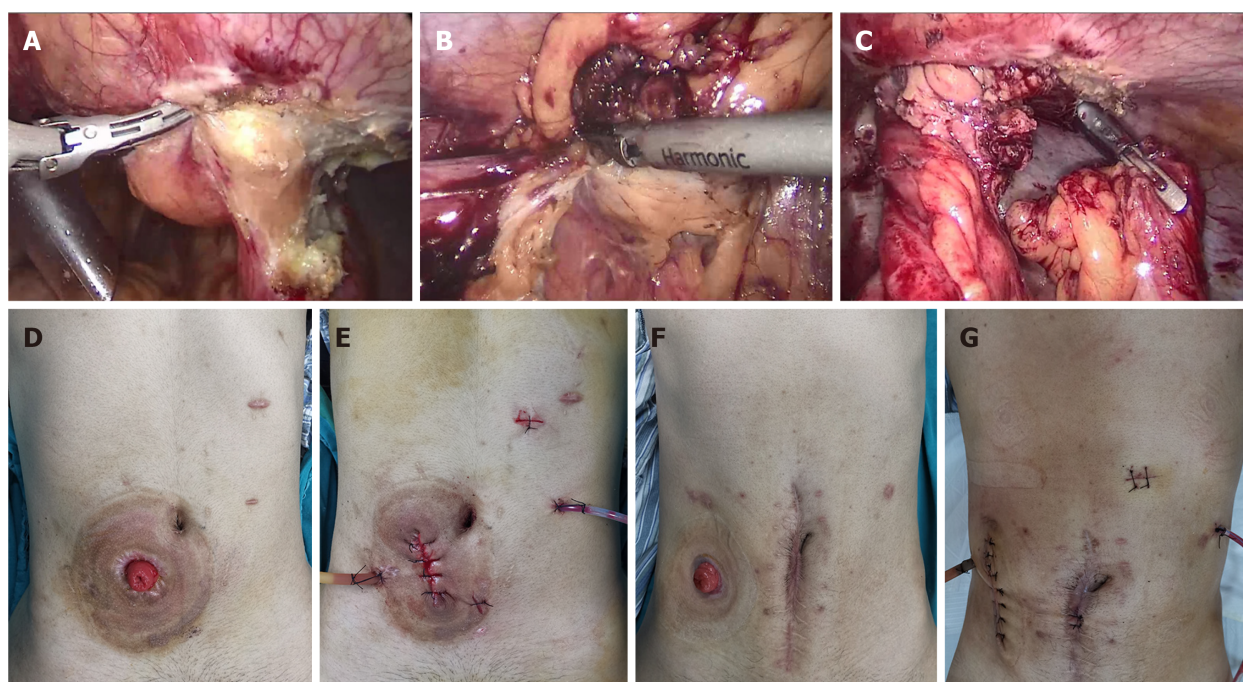


Figure 1 Laparoscopic ileostomy reversal and open ileostomy reversal. A: The intraperitoneal adhesions at the stoma were separated; B: The distal intestinal stump was separated; C: Separation was completed under laparoscopy; D and E: Abdominal incision of laparoscopic ileostomy reversal; F and G: Abdominal incision of open ileostomy reversal.

significant risks and difficulties in laparoscopic surgery[19]. Moreover, widespread inflammation can invade peripheral organs, such as the ureters, which can limit the application of minimally invasive surgery. Previous clinical studies have confirmed that laparoscopic resection in patients with ileocecal CD following failure of conventional therapy should be considered as a reasonable alternative[20]. The advantages of minimally invasive surgery for CD include reduced immune and inflammatory responses, fewer postoperative intestinal adhesions, less incision pain, and faster recovery[21,22]. Although laparoscopic techniques remain challenging in patients with

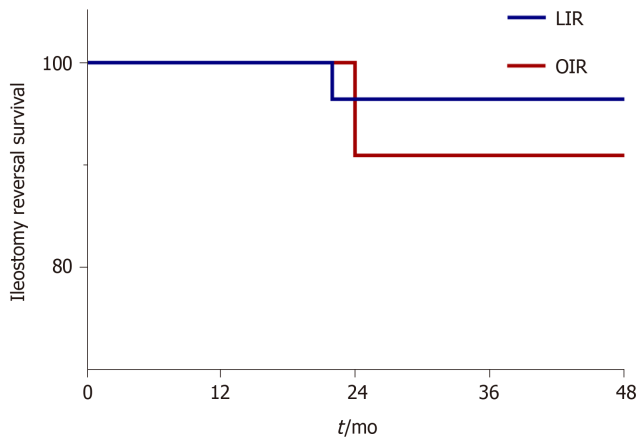


Figure 2 Long-term outcomes after ileostomy reversal. The reoperation rate after ileostomy reversal was similar between laparoscopic ileostomy reversal and open ileostomy reversal. LIR: Laparoscopic ileostomy reversal; OIR: Open ileostomy reversal.

CD, Bitner *et al*[3] reported that LIR was a safe and feasible option in 44 patients with CD after subtotal colectomy. However, larger studies are needed to confirm this claim. To date, LIR has been mainly applied for treatment of non-inflammatory diseases, such as colorectal cancer[23,24]. A study conducted by Russek *et al*[25] of 24 patients who underwent LIR found that the complication rate and surgical time were comparable to those of open surgery. In addition, extending the time to IR improved the patients' nutritional status and allowed time for the adhesions to become less dense. A retrospective review of 133 patients demonstrated similar estimated blood loss, mean length of stay, and 30-d morbidity rates between LIR and OIR. Although the duration of LIR was longer, the additional procedures may provide long-term benefits[26].

To the best of our knowledge, this study is the first to evaluate the surgical approach and postoperative recovery of LIR for CD. In this study, cases of enterectomy during IR were excluded in order to compare OIR *vs* LIR alone. The results showed that postoperative recovery of patients with CD was better in the OIR group than the LIR group. This result is not difficult to explain. CD is a progressive disease resulting in fibrosis of the entire digestive tract. So, the entirety of the small intestine and colon can be explored during laparoscopic surgery, while only relatively small portions can be explored by open surgery. Also, in both LIR and OIR, incisions of the same length were made around the original ileostomy. Moreover, less minimally invasive instruments were used in OIR, so hospitalization costs were lower. In addition, laparoscopy is more convenient for the surgeon to dissociate the ileostoma from the abdominal cavity because of the good field of vision. Meanwhile, laparoscopy provides a clear field of vision of the entire gastrointestinal tract, which facilitates assessment of the remaining length of the healthy intestine, as well as the diseased portions. Therefore, laparoscopy greatly improves the rate of enterolysis and reduces the incidence of ileus. In this study, there was a significant difference in the rate of enterolysis between the IR and OIR groups (87.5% *vs* 41.7%, respectively, $P < 0.05$). In this regard, laparoscopy is undoubtedly beneficial to patients with CD. Hence, we continue to combine IR with enterectomy. The results of the present study showed that LIR did not increase the operative time, intraoperative blood loss, postoperative recovery time, length of hospitalization stay, hospitalization costs, or reoperation rate. Therefore, LIR is not a contraindication for patients with CD. In this study, 18 patients underwent enterectomy simultaneously with IR. In general, there are two main reasons for resection of the diseased intestinal segment at the same time of IR. First, ileostomy is often performed as an emergency surgery, as the diseased intestine can be removed at a later stage in the remission stage of CD. Second, during surgery for CD, excision of the intestine should be limited to avoid the occurrence of short bowel syndrome, as disease of the bowel can be alleviated with the use of biological agents. However, if drug treatment fails, simultaneous resection of the diseased bowel can be considered during IR.

Studies have shown that LIR with intracorporeal anastomosis was associated with shorter length of hospitalization without increasing overall costs[17]. A double-blind randomized controlled trial showed that intracorporeal anastomosis can reduce bowel manipulation and mesentery traction, which promotes quicker recovery of bowel function[27]. However, in the case of CD, extracorporeal anastomosis is preferred in

our center because CD is often accompanied by thickening of the mesentery and vasculature, thus hemostasis and reinforcing sutures are often required after anastomosis. These procedures will be safer and more reliable *in vitro*. In order to avoid anastomotic stoma-associated strictures in patients with CD, in addition to side-to-side anastomosis in digestive tract reconstruction, extracorporeal anastomosis can ensure the maximum size of the anastomotic stoma. For extracorporeal anastomosis, the length of the incision was not increased, which alleviated postoperative pain and improved satisfaction with the cosmetic result (Figure 1D-G).

CONCLUSION

LIR for CD is both safe and feasible. The short-term and long-term outcomes of LIR are comparable to those of OIR and do not prolong postoperative recovery. In view of the fact that this is a retrospective study with a small sample size, larger prospective trials are required to further confirm these findings.

ARTICLE HIGHLIGHTS

Research background

The advantages of minimally invasive surgery for ileostomy reversal (IR) have attracted increasing attention, although relatively few studies have investigated the benefits of IR for patients with Crohn's disease (CD).

Research motivation

It is worthwhile to evaluate the potential benefits and risks of laparoscopy for patients with CD.

Research objectives

To compare the safety, feasibility, and short-term and long-term outcomes of laparoscopic IR (LIR) *vs* open IR (OIR) for treatment of CD.

Research methods

The baseline characteristics, operative data, and short-term (30-d) and long-term outcomes of patients with CD who underwent LIR and OIR between January 2017 and January 2020 were retrieved from an electronic database and retrospectively reviewed.

Research results

A total of 60 eligible patients were enrolled into the study, including 48 in the LIR group and 12 in the OIR group. There were no statistically significant differences in baseline characteristics, operative data, or short-term and long-term outcomes between the two groups. However, patients in the LIR group more frequently required lysis of adhesions as compared to those in the OIR group. Notably, following exclusion of patients who underwent enterectomy plus IR, OIR was more advantageous in terms of postoperative recovery of gastrointestinal function and hospitalization costs.

Research conclusions

The safety and feasibility of LIR for the treatment of CD are comparable to those of OIR with no increase in intraoperative or postoperative complications.

Research perspectives

LIR is feasible and safe for the treatment of CD patients with IR, and the short-term and long-term results are similar to those of OIR, thus further studies are warranted. In view of the fact that this is a retrospective study with a small sample size, larger prospective trials are required to further confirm these findings.

REFERENCES

- 1 Neary PM, Aiello AC, Stocchi L, Shawki S, Hull T, Steele SR, Delaney CP, Holubar SD. High-Risk Ileocolic Anastomoses for Crohn's Disease: When Is Diversion Indicated? *J Crohns Colitis* 2019; **13**:

- 856-863 [PMID: [31329836](#) DOI: [10.1093/ecco-jcc/jjz004](#)]
- 2 **Celentano V**, O'Leary DP, Caiazzo A, Flashman KG, Sagias F, Conti J, Senapati A, Khan J. Longer small bowel segments are resected in emergency surgery for ileocaecal Crohn's disease with a higher ileostomy and complication rate. *Tech Coloproctol* 2019; **23**: 1085-1091 [PMID: [31664551](#) DOI: [10.1007/s10151-019-02104-9](#)]
 - 3 **Bitner D**, D'Andrea A, Grant R, Khetan P, Greenstein AJ. Ileostomy reversal after subtotal colectomy in Crohn's disease: a single institutional experience at a high-volume center. *Int J Colorectal Dis* 2020; **35**: 2361-2363 [PMID: [32725347](#) DOI: [10.1007/s00384-020-03709-5](#)]
 - 4 **Sun X**, Han H, Qiu H, Wu B, Lin G, Niu B, Zhou J, Lu J, Xu L, Zhang G, Xiao Y. Comparison of safety of loop ileostomy and loop transverse colostomy for low-lying rectal cancer patients undergoing anterior resection: A retrospective, single institute, propensity score-matched study. *J BUON* 2019; **24**: 123-129 [PMID: [30941960](#)]
 - 5 **Mege D**, Michelassi F. Laparoscopy in Crohn Disease: Learning Curve and Current Practice. *Ann Surg* 2020; **271**: 317-324 [PMID: [30080737](#) DOI: [10.1097/SLA.0000000000002995](#)]
 - 6 **Rieder F**, Fiocchi C, Rogler G. Mechanisms, Management, and Treatment of Fibrosis in Patients With Inflammatory Bowel Diseases. *Gastroenterology* 2017; **152**: 340-350.e6 [PMID: [27720839](#) DOI: [10.1053/j.gastro.2016.09.047](#)]
 - 7 **Guillou PJ**, Quirke P, Thorpe H, Walker J, Jayne DG, Smith AM, Heath RM, Brown JM; MRC CLASICC trial group. Short-term endpoints of conventional vs laparoscopic-assisted surgery in patients with colorectal cancer (MRC CLASICC trial): multicentre, randomised controlled trial. *Lancet* 2005; **365**: 1718-1726 [PMID: [15894098](#) DOI: [10.1016/S0140-6736\(05\)66545-2](#)]
 - 8 **Panteleimonitis S**, Ahmed J, Parker T, Qureshi T, Parvaiz A. Laparoscopic resection for primary and recurrent Crohn's disease: A case series of over 100 consecutive cases. *Int J Surg* 2017; **47**: 69-76 [PMID: [28951290](#) DOI: [10.1016/j.ijsu.2017.09.055](#)]
 - 9 **Royds J**, O'Riordan JM, Mansour E, Eguare E, Neary P. Randomized clinical trial of the benefit of laparoscopy with closure of loop ileostomy. *Br J Surg* 2013; **100**: 1295-1301 [PMID: [23939842](#) DOI: [10.1002/bjs.9183](#)]
 - 10 **Mrak K**, Uranitsch S, Pedross F, Heuberger A, Klingler A, Jagoditsch M, Weihs D, Eberl T, Tschmelitsch J. Diverting ileostomy vs no diversion after low anterior resection for rectal cancer: A prospective, randomized, multicenter trial. *Surgery* 2016; **159**: 1129-1139 [PMID: [26706610](#) DOI: [10.1016/j.surg.2015.11.006](#)]
 - 11 **Cauley CE**, Patel R, Bordeianou L. Use of Primary Anastomosis With Diverting Ileostomy in Patients With Acute Diverticulitis Requiring Urgent Operative Intervention. *Dis Colon Rectum* 2018; **61**: 586-592 [PMID: [29630003](#) DOI: [10.1097/DCR.0000000000001080](#)]
 - 12 **Salvadalea G**. Incidence of complications of the stoma and peristomal skin among individuals with colostomy, ileostomy, and urostomy: a systematic review. *J Wound Ostomy Continence Nurs* 2008; **35**: 596-607; quiz 608 [PMID: [19018200](#) DOI: [10.1097/01.WON.0000341473.86932.89](#)]
 - 13 **Bafford AC**, Irani JL. Management and complications of stomas. *Surg Clin North Am* 2013; **93**: 145-166 [PMID: [23177069](#) DOI: [10.1016/j.suc.2012.09.015](#)]
 - 14 **Kaidar-Person O**, Person B, Wexner SD. Complications of construction and closure of temporary loop ileostomy. *J Am Coll Surg* 2005; **201**: 759-773 [PMID: [16256921](#) DOI: [10.1016/j.jamcollsurg.2005.06.002](#)]
 - 15 **van der Pas MH**, Haglind E, Cuesta MA, Fürst A, Lacy AM, Hop WC, Bonjer HJ; COLOrectal cancer Laparoscopic or Open Resection II (COLOR II) Study Group. Laparoscopic vs open surgery for rectal cancer (COLOR II): short-term outcomes of a randomised, phase 3 trial. *Lancet Oncol* 2013; **14**: 210-218 [PMID: [23395398](#) DOI: [10.1016/S1470-2045\(13\)70016-0](#)]
 - 16 **Hida K**, Okamura R, Sakai Y, Konishi T, Akagi T, Yamaguchi T, Akiyoshi T, Fukuda M, Yamamoto S, Yamamoto M, Nishigori T, Kawada K, Hasegawa S, Morita S, Watanabe M; Japan Society of Laparoscopic Colorectal Surgery. Open vs Laparoscopic Surgery for Advanced Low Rectal Cancer: A Large, Multicenter, Propensity Score Matched Cohort Study in Japan. *Ann Surg* 2018; **268**: 318-324 [PMID: [28628565](#) DOI: [10.1097/SLA.0000000000002329](#)]
 - 17 **Sujatha-Bhaskar S**, Whealon M, Inaba CS, Koh CY, Jafari MD, Mills S, Pigazzi A, Stamos MJ, Carmichael JC. Laparoscopic loop ileostomy reversal with intracorporeal anastomosis is associated with shorter length of stay without increased direct cost. *Surg Endosc* 2019; **33**: 644-650 [PMID: [30361967](#) DOI: [10.1007/s00464-018-6518-0](#)]
 - 18 **Su H**, Luo S, Xu Z, Zhao C, Bao M, Wang X, Zhou Z, Zhou H. Satisfactory short-term outcome of total laparoscopic loop ileostomy reversal in obese patients: a comparative study with open techniques. *Updates Surg* 2021; **73**: 561-567 [PMID: [32980964](#) DOI: [10.1007/s13304-020-00890-8](#)]
 - 19 **Coffey JC**, O'Leary DP, Kiernan MG, Faul P. The mesentery in Crohn's disease: friend or foe? *Curr Opin Gastroenterol* 2016; **32**: 267-273 [PMID: [27115218](#) DOI: [10.1097/MOG.0000000000000280](#)]
 - 20 **Stevens TW**, Haasnoot ML, D'Haens GR, Buskens CJ, de Groof EJ, Eshuis EJ, Gardenbroek TJ, Mol B, Stokkers PCF, Bemelman WA, Ponsioen CY; LIR!C study group. Laparoscopic ileocaecal resection vs infliximab for terminal ileitis in Crohn's disease: retrospective long-term follow-up of the LIR! *Lancet Gastroenterol Hepatol* 2020; **5**: 900-907 [PMID: [32619413](#) DOI: [10.1016/S2468-1253\(20\)30117-5](#)]
 - 21 **Makni A**, Chebbi F, Ksantini R, Fétirich F, Bedioui H, Jouini M, Kacem M, Ben Mami N, Filali A, Ben Safta Z. Laparoscopic-assisted vs conventional ileocelectomy for primary Crohn's disease: results of a comparative study. *J Visc Surg* 2013; **150**: 137-143 [PMID: [23092647](#) DOI: [10.1016/j.jvisc Surg.2012.10.006](#)]

- 22 **Umanskiy K**, Malhotra G, Chase A, Rubin MA, Hurst RD, Fichera A. Laparoscopic colectomy for Crohn's colitis. A large prospective comparative study. *J Gastrointest Surg* 2010; **14**: 658-663 [PMID: 20127200 DOI: [10.1007/s11605-010-1157-3](https://doi.org/10.1007/s11605-010-1157-3)]
- 23 **Yellinek S**, Krizzuk D, Gilshtein H, Djadou TM, de Sousa CAB, Qureshi S, Wexner SD. Early postoperative outcomes of diverting loop ileostomy closure surgery following laparoscopic vs open colorectal surgery. *Surg Endosc* 2021; **35**: 2509-2514 [PMID: 32458288 DOI: [10.1007/s00464-020-07662-w](https://doi.org/10.1007/s00464-020-07662-w)]
- 24 **Pei KY**, Davis KA, Zhang Y. Assessing trends in laparoscopic colostomy reversal and evaluating outcomes when compared to open procedures. *Surg Endosc* 2018; **32**: 695-701 [PMID: 28726139 DOI: [10.1007/s00464-017-5725-4](https://doi.org/10.1007/s00464-017-5725-4)]
- 25 **Russek K**, George JM, Zafar N, Cuevas-Estandia P, Franklin M. Laparoscopic loop ileostomy reversal: reducing morbidity while improving functional outcomes. *JSLs* 2011; **15**: 475-479 [PMID: 22643501 DOI: [10.4293/108680811X13176785203950](https://doi.org/10.4293/108680811X13176785203950)]
- 26 **Young MT**, Hwang GS, Menon G, Feldmann TF, Jafari MD, Jafari F, Perez E, Pigazzi A. Laparoscopic Versus Open Loop Ileostomy Reversal: Is there an Advantage to a Minimally Invasive Approach? *World J Surg* 2015; **39**: 2805-2811 [PMID: 26272594 DOI: [10.1007/s00268-015-3186-2](https://doi.org/10.1007/s00268-015-3186-2)]
- 27 **Allaix ME**, Degiuli M, Bonino MA, Arezzo A, Mistrangelo M, Passera R, Morino M. Intracorporeal or Extracorporeal Ileocolic Anastomosis After Laparoscopic Right Colectomy: A Double-blinded Randomized Controlled Trial. *Ann Surg* 2019; **270**: 762-767 [PMID: 31592811 DOI: [10.1097/SLA.0000000000003519](https://doi.org/10.1097/SLA.0000000000003519)]



Published by **Baishideng Publishing Group Inc**
7041 Koll Center Parkway, Suite 160, Pleasanton, CA 94566, USA

Telephone: +1-925-3991568

E-mail: bpgoffice@wjgnet.com

Help Desk: <https://www.f6publishing.com/helpdesk>

<https://www.wjgnet.com>

