

World Journal of *Clinical Cases*

World J Clin Cases 2021 September 6; 9(25): 7292-7613



Contents

Thrice Monthly Volume 9 Number 25 September 6, 2021

EDITORIAL

- 7292 Radiation oncology practice during COVID-19 pandemic in developing countries

Abuhijla F, Abuhijlih R, Mohamad I

OPINION REVIEW

- 7297 Complete mesocolic excision and central vascular ligation in colorectal cancer in the era of minimally invasive surgery

Franceschilli M, Di Carlo S, Vinci D, Sensi B, Siragusa L, Bellato V, Caronna R, Rossi P, Cavallaro G, Guida A, Sibio S

- 7306 Fecal diversion in complex anal fistulas: Is there a way to avoid it?

Garg P, Yagnik VD, Dawka S

MINIREVIEWS

- 7311 Regulatory roles of extracellular vesicles in immune responses against *Mycobacterium tuberculosis* infection

Yan Z, Wang H, Mu L, Hu ZD, Zheng WQ

- 7319 Aortic stenosis and Heyde's syndrome: A comprehensive review

Lourdusamy D, Mupparaju VK, Sharif NF, Ibebuogu UN

ORIGINAL ARTICLE

Retrospective Study

- 7330 Key determinants of misdiagnosis of tracheobronchial tuberculosis among senile patients in contemporary clinical practice: A retrospective analysis

Tang F, Lin LJ, Guo SL, Ye W, Zha XK, Cheng Y, Wu YF, Wang YM, Lyu XM, Fan XY, Lyu LP

- 7340 Long-term outcome of pancreatic function following oncological surgery in children: Institutional experience and review of the literature

Bolasco G, Capriati T, Grimaldi C, Monti L, De Pasquale MD, Patera IP, Spada M, Maggiore G, Diamanti A

- 7350 Efficacy of arbidol in COVID-19 patients: A retrospective study

Wei S, Xu S, Pan YH

- 7358 Characteristic analysis of clinical coronary heart disease and coronary artery disease concerning young and middle-aged male patients

Peng KG, Yu HL

- 7365 Quantitative analysis of early diabetic retinopathy based on optical coherence tomography angiography biological image

Shi Y, Lin PY, Ruan YM, Lin CF, Hua SS, Li B

- 7372** Mucin 1 and interleukin-11 protein expression and inflammatory reactions in the intestinal mucosa of necrotizing enterocolitis children after surgery

Pan HX, Zhang CS, Lin CH, Chen MM, Zhang XZ, Yu N

Observational Study

- 7381** Research on the prognosis of different types of microvessels in bladder transitional cell carcinoma

Wang HB, Qin Y, Yang JY

- 7391** Is burnout a mediating factor between sharps injury and work-related factors or musculoskeletal pain?

Chen YH, Tsai CF, Yeh CJ, Jong GP

- 7405** Role of international normalized ratio in nonpulmonary sepsis screening: An observational study

Zhang J, Du HM, Cheng MX, He FM, Niu BL

Randomized Controlled Trial

- 7417** Clinical effectiveness of adding probiotics to a low FODMAP diet: Randomized double-blind placebo-controlled study

Turan B, Bengi G, Cehreli R, Akpınar H, Soytürk M

SYSTEMATIC REVIEWS

- 7433** Association between COVID-19 and anxiety during social isolation: A systematic review

Santos ERRD, Silva de Paula JL, Tardieux FM, Costa-e-Silva VN, Lal A, Leite AFB

CASE REPORT

- 7445** Avascular necrosis of the first metatarsal head in a young female adult: A case report and review of literature

Siu RWH, Liu JHP, Man GCW, Ong MTY, Yung PSH

- 7453** Successful treatment of solitary bladder plasmacytoma: A case report

Cao JD, Lin PH, Cai DF, Liang JH

- 7459** Pseudomyxoma peritonei originating from intestinal duplication: A case report and review of the literature

Han XD, Zhou N, Lu YY, Xu HB, Guo J, Liang L

- 7468** Agranulocytosis following injection of inactivated Japanese encephalitis vaccine (Vero cell): A case report

Wang L, Zhang X, Liu YT

- 7472** Importance of clinical suspicion and multidisciplinary management for early diagnosis of a cardiac laminopathy patient: A case report

Santobuono VE, Guaricci AI, Carulli E, Bozza N, Pepe M, Ranauro A, Ranieri C, Carella MC, Loizzi F, Resta N, Favale S, Forleo C

- 7478** First case of forearm crisscross injury in children: A case report

Jiang YK, Wang YB, Peng CG, Qu J, Wu DK

- 7484** Octreotide-induced acute life-threatening gallstones after vicarious contrast medium excretion: A case report
Han ZH, He ZM, Chen WH, Wang CY, Wang Q
- 7490** Acute deep venous thrombosis induced by May-Thurner syndrome after spondylolisthesis surgery: A case report and review of literature
Yue L, Fu HY, Sun HL
- 7498** Successful treatment of refractory lung adenocarcinoma harboring a germline *BRCA2* mutation with olaparib: A case report
Zhang L, Wang J, Cui LZ, Wang K, Yuan MM, Chen RR, Zhang LJ
- 7504** Effective treatment of polyneuropathy, organomegaly, endocrinopathy, M-protein, and skin changes syndrome with congestive heart failure: A case report
Fu LY, Zhang HB
- 7512** Awake craniotomy for auditory brainstem implant in patients with neurofibromatosis type 2: Four case reports
Wang DX, Wang S, Jian MY, Han RQ
- 7520** Coexistence of tuberculosis and squamous cell carcinoma in the right main bronchus: A case report
Jiang H, Li YQ
- 7527** Is simultaneous presence of IgG4-positive plasma cells and giant-cell hepatitis a coincidence in autoimmune hepatitis? A case report
Tan YW, Wang JM, Chen L
- 7535** Surgical treatment of delayed cervical infection and incomplete quadriplegia with fish-bone ingestion: A case report
Li SY, Miao Y, Cheng L, Wang YF, Li ZQ, Liu YB, Zou TM, Shen J
- 7542** Neonatal biliary atresia combined with preduodenal portal vein: A case report
Xiang XL, Cai P, Zhao JG, Zhao HW, Jiang YL, Zhu ML, Wang Q, Zhang RY, Zhu ZW, Chen JL, Gu ZC, Zhu J
- 7551** Hemorrhagic transformation after acute ischemic stroke caused by polycythemia vera: Report of two case
Cao YY, Cao J, Bi ZJ, Xu SB, Liu CC
- 7558** Treatment of lower part of glenoid fractures through a novel axillary approach: A case report
Jia X, Zhou FL, Zhu YH, Jin DJ, Liu WX, Yang ZC, Liu RP
- 7564** Trigger finger at the wrist caused by an intramuscular lipoma within the carpal tunnel: A case report
Huang C, Jin HJ, Song DB, Zhu Z, Tian H, Li ZH, Qu WR, Li R
- 7572** Thrombolysis and embolectomy in treatment of acute stroke as a bridge to open-heart resection of giant cardiac myxoma: A case report
Chang WS, Li N, Liu H, Yin JJ, Zhang HQ
- 7579** Breast adenoid cystic carcinoma arising in microglandular adenosis: A case report and review of literature
An JK, Woo JJ, Kim EK, Kwak HY

- 7588** Diagnosis and management of ophthalmic zoster sine herpete accompanied by cervical spine disc protrusion: A case report
Yun G, Kim E, Baik J, Do W, Jung YH, You CM
- 7593** Hemorrhagic pericardial effusion following treatment with infliximab: A case report and literature review
Li H, Xing H, Hu C, Sun BY, Wang S, Li WY, Qu B
- 7600** Wernicke's encephalopathy in a rectal cancer patient with atypical radiological features: A case report
Nie T, He JL
- 7605** Total hip revision with custom-made spacer and prosthesis: A case report
Liu YB, Pan H, Chen L, Ye HN, Wu CC, Wu P, Chen L

ABOUT COVER

Editorial Board Member of *World Journal of Clinical Cases*, Lan Sun, MD, PhD, Chief Physician, Professor, Department of Oncology, The People's Hospital of Bishan District, Chongqing 402760, China. sunlan6203@163.com

AIMS AND SCOPE

The primary aim of *World Journal of Clinical Cases* (WJCC, *World J Clin Cases*) is to provide scholars and readers from various fields of clinical medicine with a platform to publish high-quality clinical research articles and communicate their research findings online.

WJCC mainly publishes articles reporting research results and findings obtained in the field of clinical medicine and covering a wide range of topics, including case control studies, retrospective cohort studies, retrospective studies, clinical trials studies, observational studies, prospective studies, randomized controlled trials, randomized clinical trials, systematic reviews, meta-analysis, and case reports.

INDEXING/ABSTRACTING

The WJCC is now indexed in Science Citation Index Expanded (also known as SciSearch®), Journal Citation Reports/Science Edition, Scopus, PubMed, and PubMed Central. The 2021 Edition of Journal Citation Reports® cites the 2020 impact factor (IF) for WJCC as 1.337; IF without journal self cites: 1.301; 5-year IF: 1.742; Journal Citation Indicator: 0.33; Ranking: 119 among 169 journals in medicine, general and internal; and Quartile category: Q3. The WJCC's CiteScore for 2020 is 0.8 and Scopus CiteScore rank 2020: General Medicine is 493/793.

RESPONSIBLE EDITORS FOR THIS ISSUE

Production Editor: Yan-Xia Xing; **Production Department Director:** Xiang Li; **Editorial Office Director:** Jin-Lai Wang.

NAME OF JOURNAL

World Journal of Clinical Cases

ISSN

ISSN 2307-8960 (online)

LAUNCH DATE

April 16, 2013

FREQUENCY

Thrice Monthly

EDITORS-IN-CHIEF

Dennis A Bloomfield, Sandro Vento, Bao-Gan Peng

EDITORIAL BOARD MEMBERS

<https://www.wjgnet.com/2307-8960/editorialboard.htm>

PUBLICATION DATE

September 6, 2021

COPYRIGHT

© 2021 Baishideng Publishing Group Inc

INSTRUCTIONS TO AUTHORS

<https://www.wjgnet.com/bpg/gerinfo/204>

GUIDELINES FOR ETHICS DOCUMENTS

<https://www.wjgnet.com/bpg/GerInfo/287>

GUIDELINES FOR NON-NATIVE SPEAKERS OF ENGLISH

<https://www.wjgnet.com/bpg/gerinfo/240>

PUBLICATION ETHICS

<https://www.wjgnet.com/bpg/GerInfo/288>

PUBLICATION MISCONDUCT

<https://www.wjgnet.com/bpg/gerinfo/208>

ARTICLE PROCESSING CHARGE

<https://www.wjgnet.com/bpg/gerinfo/242>

STEPS FOR SUBMITTING MANUSCRIPTS

<https://www.wjgnet.com/bpg/GerInfo/239>

ONLINE SUBMISSION

<https://www.f6publishing.com>

Retrospective Study

Mucin 1 and interleukin-11 protein expression and inflammatory reactions in the intestinal mucosa of necrotizing enterocolitis children after surgery

Hong-Xia Pan, Chang-Song Zhang, Chia-Hui Lin, Min-Min Chen, Xiao-Zhong Zhang, Nong Yu

ORCID number: Hong-Xia Pan 0000-0002-5597-422X; Chang-Song Zhang 0000-0002-1425-7339; Chia-Hui Lin 0000-0002-7125-5188; Min-Min Chen 0000-0002-4962-8558; Xiao-Zhong Zhang 0000-0002-8015-2148; Nong Yu 0000-0002-3578-5173.

Author contributions: Pan HX and Zhang CS have the same contribution to this article and should be regarded as co-first authors; Pan HX and Zhang CS design the experiment; Lin CH drafted the work, Chen MM, Zhang XZ and Yu N collected the data; Pan HX and Zhang CS interpreted data; Pan HX, Zhang CS and Yu N wrote the article.

Supported by Suzhou Science and Technology Program, No. SLT202005; Suzhou Municipal Commission of Health and Family Planning, No. LCZX202031; Suzhou New District Science and Technology Plan, No. 2019Z009; and Independent Innovation Project of National High Tech Development Zone Hospital, No. SGY2018C03.

Institutional review board statement: This study was approved by the Affiliated BenQ Hospital of Nanjing Medical University Ethics Committee.

Hong-Xia Pan, Min-Min Chen, Department of Clinical Laboratory Medicine, Suzhou BenQ Medical Center, Affiliated BenQ Hospital of Nanjing Medical University, Suzhou 215011, Jiangsu Province, China

Chang-Song Zhang, Department of Clinical Laboratory Medicine, The Affiliated Suzhou Science and Technology Town Hospital, Nanjing Medical University, Suzhou 215153, Jiangsu Province, China

Chia-Hui Lin, General Manager's Office, Suzhou Gallant Biotech Biotechnology Co. Ltd, Suzhou 215163, Jiangsu Province, China

Xiao-Zhong Zhang, Department of Cardiology, National High Tech Development Zone Hospital, Suzhou 215129, Jiangsu Province, China

Nong Yu, Department of Laboratory Medicine, National High Tech Development Zone Hospital, Suzhou 215129, Jiangsu Province, China

Corresponding author: Nong Yu, BM BCh, Chief Technician, Department of Laboratory Medicine, National High Tech Development Zone Hospital, No. 95 Huashan Road, Huqiu District, Suzhou 215129, Jiangsu Province, China. yunong78612@sina.com

Abstract

BACKGROUND

Necrotizing enterocolitis (NEC) of the newborn is a frequently occurring clinical disease in infants. The mortality rate of NEC in premature infants is as high as 50%, and the morbidity rate is on the rise. NEC has already caused serious impacts on newborn survival and poses serious threats to both children and families.

AIM

To investigate the expression and significance of mucin 1 (MUC1) and interleukin-11 (IL-11) in the intestinal mucosa of infants with neonatal NEC after surgery.

METHODS

Forty-eight postoperative intestinal mucosal specimens from children with NEC (NEC group) and twenty-two intestinal mucosal specimens from children with

Informed consent statement: All study participants, or their legal guardian, provided informed written consent prior to study enrollment.

Conflict-of-interest statement: No conflict of interest.

Data sharing statement: No additional data are available.

Open-Access: This article is an open-access article that was selected by an in-house editor and fully peer-reviewed by external reviewers. It is distributed in accordance with the Creative Commons Attribution NonCommercial (CC BY-NC 4.0) license, which permits others to distribute, remix, adapt, build upon this work non-commercially, and license their derivative works on different terms, provided the original work is properly cited and the use is non-commercial. See: <http://creativecommons.org/licenses/by-nc/4.0/>

Manuscript source: Unsolicited manuscript

Specialty type: Pediatrics

Country/Territory of origin: China

Peer-review report's scientific quality classification

Grade A (Excellent): 0
Grade B (Very good): 0
Grade C (Good): C
Grade D (Fair): 0
Grade E (Poor): 0

Received: April 22, 2021

Peer-review started: April 22, 2021

First decision: May 24, 2021

Revised: June 28, 2021

Accepted: July 28, 2021

Article in press: July 28, 2021

Published online: September 6, 2021

P-Reviewer: Kurokawa R

S-Editor: Wang JL

L-Editor: A

P-Editor: Xing YX



congenital intestinal atresia (control group) were collected in our hospital. Immunohistochemical staining and Western blot analysis were used to examine the protein expression of MUC-1 and IL-11 in the two groups. The serum levels of tumor necrosis factor- α (TNF- α) and IL-1 β in the two groups were measured by enzyme-linked immunosorbent assay, and the relationship between MUC-1 and IL-11 protein expression and serum TNF- α and IL-1 β levels was analyzed by the linear correlation method.

RESULTS

The protein expression of MUC-1 and IL-11 in the NEC group was significantly lower than that in the control group, and the difference was statistically significant ($P < 0.05$). The levels of serum TNF- α and IL-1 β in the NEC group were significantly higher than those in the control group ($P < 0.05$). The protein expression of MUC-1 and IL-11 in the NEC group negatively correlated with serum TNF- α and IL-1 β levels ($P < 0.05$). There was a significant negative correlation between the protein expression of MUC-1 and IL-11 and the levels of serum TNF- α and IL-1 β in the NEC group.

CONCLUSION

The protein expression of MUC1 and IL-11 in the intestinal mucosa of children with NEC is significantly downregulated after surgery. This downregulation may be involved in the pathogenesis of this disease and has a certain correlation with inflammatory response factors in children with NEC.

Key Words: Neonatal necrotizing enterocolitis; Mucin 1; Interleukin-11; Inflammation; Intestinal mucosa; Expression

©The Author(s) 2021. Published by Baishideng Publishing Group Inc. All rights reserved.

Core Tip: This study analyzed the expression changes of mucin 1 and interleukin-11 in intestinal mucosa after necrotizing enterocolitis operation in neonatal necrotizing enterocolitis. It may be related to the pathogenesis of the disease, and providing clinical guidance and basis.

Citation: Pan HX, Zhang CS, Lin CH, Chen MM, Zhang XZ, Yu N. Mucin 1 and interleukin-11 protein expression and inflammatory reactions in the intestinal mucosa of necrotizing enterocolitis children after surgery. *World J Clin Cases* 2021; 9(25): 7372-7380

URL: <https://www.wjgnet.com/2307-8960/full/v9/i25/7372.htm>

DOI: <https://dx.doi.org/10.12998/wjcc.v9.i25.7372>

INTRODUCTION

In the clinic, neonatal necrotizing enterocolitis (NEC) is a frequently occurring pediatric intestinal inflammatory disease. The mortality of premature infants with NEC is as high as 50%, and the incidence is increasing, which has serious impacts on the quality of life of these children[1,2].

At present, the etiology and specific pathogenesis of neonatal NEC are not completely known. Thus, it is critical to identify reliable and sensitive molecules or genes to reduce the morbidity and mortality of NEC[3]. At present, intestinal mucus is considered an important component of the intestinal mucosal barrier, and mucin is the main macromolecular substance in intestinal mucus, which is critical in ensuring the stability of bacteria and the intestinal mucosal barrier, but there have been few clinical studies on mucin. Interleukin-11 (IL-11) has good mucosal protective effects against intestinal epithelial cell injury due to several factors. Moreover, IL-11 is involved in signal transduction and mediating inflammatory reactions during the pathogenesis of NEC. This study analyzed changes in the expression of mucin 1 (MUC1) and IL-11 in the intestinal mucosa in infants with neonatal NEC after surgery to provide clinical guidance and a basis for treatment.

MATERIALS AND METHODS

Materials

Intestinal mucosal specimens from 48 children with NEC (NEC group) and 22 patients with congenital intestinal atresia (control group) were collected in our hospital from June 2015 to January 2019. The inclusion criteria were as follows: (1) the NEC diagnosis and grading criteria refer to the indexes in Practical Pediatrics by Zhu Futang; (2) the gestational age of the child was 29-36 wk; (3) the child was delivered in our hospital and was 7-35 days old; and (4) the relevant regulations of the Medical Ethics Committee were followed, and informed consent was obtained from the parents of the children. The exclusion criteria were as follows: (1) the presence of intestinal tumors; (2) chromosomal genetic defects; (3) severe infections (septicemia, meningitis), and (4) major diseases associated with other systems.

The gestational age was 29 to 36 wk in the NEC group, with an average of 32.5 ± 1.8 wk, and the group included 25 males and 23 females; the body mass was 2630.4 ± 225.0 g, and the mean age was 17.9 ± 4.2 d, ranging from 7 to 35 d. The gestational age was 29 to 36 wk in the control group, with an average of 33.0 ± 2.0 wk, and the group included 10 males and 12 females; the body mass was 2604.1 ± 203.9 g, and the age was 7-35 d, with an average of 19.0 ± 6.2 d. There was no significant difference in gestational age, sex, body mass or age between the two groups ($P > 0.05$).

Immunohistochemical analysis

The diseased intestinal tissue was embedded in paraffin. Continuous sections (4- μ m-thick) were obtained, routine hematoxylin and eosin staining was performed, and routine dewaxing and hydration treatment was conducted. In addition, the sections were washed twice with phosphate-buffered saline (PBS) for 5 min each. PBS was used to prepare fresh 3% H_2O_2 , and the sections were sealed at room temperature for 5-10 min. Moreover, we heated the 0.01 mol/L sodium citrate buffer solution in a water bath to approximately 95 °C; the human tissue slices were heated for 10-15 min, cooled to room temperature with tap water, and washed for 5 min with PBS. Then, 5% BSA blocking solution was added and incubated for 15 min, and the primary antibody (1:50 dilution) was added dropwise. After an overnight incubation at 4 °C, the sections were washed 3 times at room temperature and incubated for 45 min. The secondary antibody was added and incubated for 1 h and washed with 3 times with PBS at room temperature for 2 min each. When the target signal of the DAB chromogenic kit was dark and the background was light, the reaction was terminated with distilled water. Hematoxylin was added and incubated for 20 s, and the sections were washed twice with distilled water for 2 min, dehydrated, and placed into 100% dimethylbenzene for 10 min to create a transparent seal. MUC1-positive cells were yellow, brown, and yellowish brown and were located in the cell membrane.

According to the immunohistochemistry results, MUC1 and IL-11 proteins were stained yellow, brown and yellowish brown and were located in the cell membrane. (1) According to the degree of staining, the samples were assessed as unstained (0 points), light yellow staining (1 point), brown staining (2 points), and brown and black staining (3 points). And (2) The percentages of stained cells were assessed as follows: $\leq 10\%$: 1 point; 11%-50%: 2 points; 51%-75%: 3 points; and $> 75\%$: 4 points. The product of the staining degree and positive cell score was calculated, and < 3 points was negative, while ≥ 3 points was positive.

Enzyme-linked immunosorbent assay

Fasting venous blood (3 mL) was extracted and centrifuged at 3000 rpm for 5 min. Forty microliters of sample diluent was added to the sample wells of the enzyme-coated plate, and 10 μ L of the sample was added. The plate was gently shaken and mixed, sealed, and incubated with 30 \times concentrated washing solution at 37 °C for 30 min. The solution was diluted 30 times with distilled water, the sealing film was removed, the liquid was discarded, and the sample was shaken dry. Each well was filled with washing solution and rested for 30 s. This process was repeated 5 times, and 50 μ L of enzyme-labeled reagent was added. After the sealing plate was incubated at 37 °C for 30 min, we removed the sealing film, discarded the liquid, dried the plate, filled each well with washing solution, rested the plate for 30 s, and repeated the process 5 times. Chromogenic agent A (50 μ L) was added, and then chromogenic agent B (50 μ L) was added. The plate was gently shaken and mixed in the dark at 37 °C for 15 min, after which 50 μ L of termination solution was added to stop the reaction, and the absorbance (OD value) of each well was measured at a wavelength of 450 nm. The corresponding concentration was determined from the standard curve and was

multiplied by the dilution factor to determine the actual concentration of the sample according to the OD value.

Statistical analysis

SPSS 21.0 software was used for statistical analysis. The measurement indexes of age, body mass, gestational age, MUC-1 protein expression and IL-11 protein expression in the two groups are expressed as mean \pm SD. In addition, comparisons between the two groups were performed by *t*-tests, the sex of the two groups was compared by the χ^2 test, and correlation analysis was performed by Pearson linear correlation analysis.

RESULTS

Comparison of MUC-1 and IL-11 protein levels between the NEC group and the control group

The protein expression of MUC-1 and IL-11 in the NEC group was significantly lower than that in the control group, and the difference was statistically significant ($P < 0.05$) (Table 1, Figure 1).

Immunohistochemical results

The positive expression rate of MUC-1 in the NEC group (33.33%) was lower than that in the control group (77.27%), and the difference was statistically significant ($P > 0.05$) (Table 2, Figure 2).

The positive expression rate of IL-11 in the NEC group (27.08%) was lower than that in the control group (81.82%), and the difference was statistically significant ($P > 0.05$) (Table 3, Figure 3).

Comparison of serum TNF- α and IL-1 β levels between the NEC group and the control group

The levels of serum tumor necrosis factor- α (TNF- α) and IL-1 β in the NEC group were significantly higher than those in the control group ($P < 0.05$) (Table 4).

Correlation between the protein expression of MUC-1 and IL-11 and the serum levels of TNF- α and IL-1 β in children with NEC

There was a significant negative correlation between the protein expression of MUC-1 and IL-11 and the serum levels of TNF- α and IL-1 β in the NEC group ($P < 0.05$) (Table 5).

DISCUSSION

In the clinic, neonatal NEC is a common clinical disease. The incidence of NEC is increasing, and this disease has recently had serious impacts on the late development and life expectancy of newborns. Factors such as premature delivery, hypoxia, and immune factors impact the intestinal mucosal blood supply and weaken intestinal peristalsis, resulting in the accumulation of food in the intestinal cavity, which affects intestinal function[4,5]. Studies have shown that preterm delivery is an important factor that leads to the occurrence of NEC due to the immature intestinal epithelium, high permeability, underdeveloped immune mechanisms, susceptibility to bacterial translocation, and activated inflammatory cascade reactions, all of which lead to disease. In addition, the development of the intestinal lumen and gastrointestinal peristalsis in premature infants are not perfect, the digestion and hydrolysis of various pathogens and toxins are inadequate, and intestinal peristalsis is slow, which allows food to accumulate in the intestine. This accumulation can lead to gastrointestinal damage, bacterial overgrowth and intestinal flatulence, resulting in the occurrence of NEC[6,7]. On the other hand, studies have shown that hypoxia-ischemia and reperfusion injury to the intestinal wall are also important factors that lead to the occurrence of NEC. To protect the blood vessels of important organs, such as the heart and brain, the gastrointestinal blood supply decreases sharply, and intestinal wall damage is caused by hypoxia. In addition, hypoxia can also cause free radical release and increase local tissue nitric oxide synthesis, leading to organ damage[8,9]. At present, clinical research on the role of cytokines in the pathogenesis of NEC has mainly focused on proinflammatory factors. However, research on protective factors

Table 1 Comparison of mucin 1 protein and interleukin-11 protein between Necrotizing enterocolitis group and control group (mean \pm SD, relative expression intensity)

Groups	<i>n</i>	MUC-1 protein	IL-11 protein
NEC group	48	0.461 \pm 0.108	0.391 \pm 0.085
Control group	22	0.958 \pm 0.177	0.920 \pm 0.204
<i>t</i>		-14.494	-15.381
<i>P</i> value		0.000	0.000

NEC: Necrotizing enterocolitis; MUC-1: Mucin 1; IL-11: Interleukin-11.

Table 2 Comparison of positive expression rate of mucin 1 protein, *n* (%)

Group	<i>n</i>	MUC-1 protein	
		Positive	Negative
NEC group	48	16 (33.33)	32 (66.67)
Control group	22	17 (77.27)	5 (22.73)
χ^2		11.688	
<i>P</i> value		0.001	

NEC: Necrotizing enterocolitis; MUC-1: Mucin 1.

Table 3 Comparison of positive expression rate of interleukin-11 protein, *n* (%)

Groups	<i>n</i>	IL-11 protein	
		Positive	Negative
NEC group	48	13 (27.08)	35 (72.92)
Control group	22	18 (81.82)	4 (18.18)
χ^2		18.317	
<i>P</i> value		0.000	

NEC: Necrotizing enterocolitis; IL-11: Interleukin-11.

Table 4 Comparison of serum tumor necrosis factor- α and interleukin-1 β levels between necrotizing enterocolitis group and control group (mean \pm SD)

Group	<i>n</i>	TNF- α (ng/L)	IL-1 β (ng/mL)
NEC group	48	386.6 \pm 76.4	18.63 \pm 3.02
Control group	22	260.7 \pm 48.8	14.19 \pm 2.50
<i>t</i>		7.080	6.010
<i>P</i> value		0.000	0.000

NEC: Necrotizing enterocolitis; TNF- α : Tumor necrosis factor- α ; IL-1 β : Interleukin-1 β .

has been relatively rare[10].

MUC1 and IL-11 in the intestinal mucosa of infants after NEC surgery were analyzed. IL-11 is a platelet-promoting factor produced by bone marrow-derived cells in primates and can participate in a variety of physiological and pathological processes in the human body[11]. Studies have shown that IL-11 can reduce intestinal injury due to various causes. Exogenous IL-11 can promote crypt cell proliferation, reduce

Table 5 Linear correlation results

Index	Correlation	TNF- α	IL-1 β
MUC-1 protein	<i>r</i>	-0.619	-0.486
	<i>P</i> value	0.000	0.000
IL-11 protein	<i>r</i>	-0.577	-0.528
	<i>P</i> value	0.000	0.000

MUC-1: Mucin 1; IL-11: Interleukin-11; TNF- α : Tumor necrosis factor- α ; IL-1 β : Interleukin-1 β .

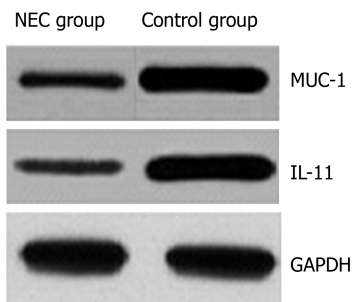


Figure 1 Western-blot results of mucin 1 protein and interleukin-11 protein in necrotizing enterocolitis group and control group. NEC: Necrotizing enterocolitis; MUC-1: Mucin 1; IL-11: Interleukin-11; GAPDH: Glyceraldehyde 3-phosphate dehydrogenase.

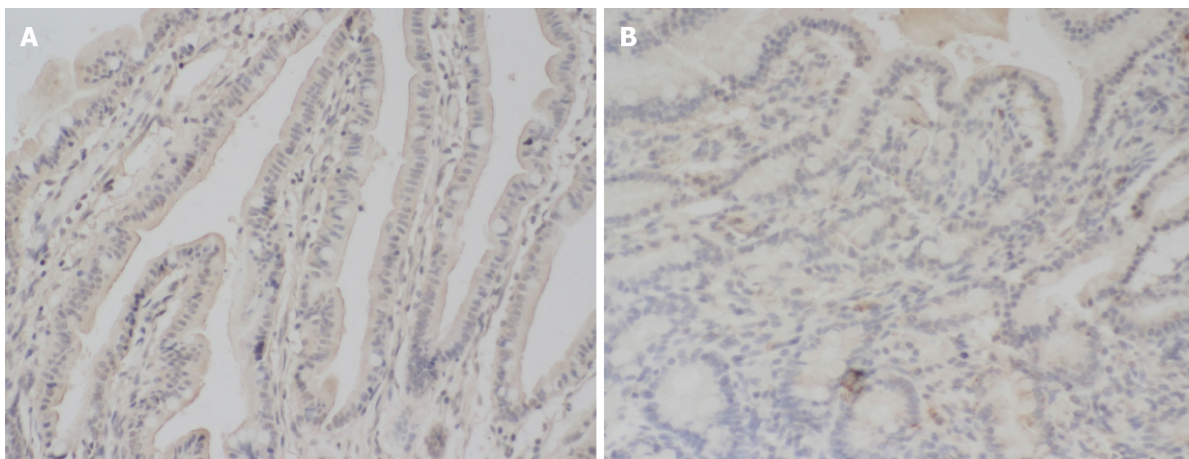


Figure 2 Mucin 1 protein immunohistochemical staining. A: The intestinal mucosal tissue of the control group; B: The necrotizing enterocolitis intestinal mucosal tissue. It can be seen that the coloring is deeper in the control group, and the mucin 1 protein expression intensity is stronger, $\times 200$.

apoptosis, and protect against intestinal injury[12]. The function of human cytokines is to bind to specific receptors on the target cell membrane and transmit signals to the cell to induce signal transduction. The receptor is an important functional protein that mediates the effects of cytokines. IL-11 receptors can form complexes by homologous dimerization and activate intracellular signaling pathways. IL-11 is expressed on the surface of intestinal epithelial cells. The expression of IL-11 on intestinal epithelial cells protects cells and inhibits apoptosis, and enhanced expression of the IL-11 receptor protects cells and inhibits apoptosis, which can delay disease progression[13]. As a consequence, the expression level of IL-11 in NEC-associated intestinal injury is downregulated. This downregulation is not conducive to ligand engagement, can activate the corresponding signaling pathway and plays a protective role in the intestinal tract[14].

As a highly glycosylated transmembrane mucin with a high molecular weight, the structure of MUC1 is highly complex. MUC1 can be expressed in a variety of tissues and organs under normal physiological conditions. MUC1 has a polar distribution and

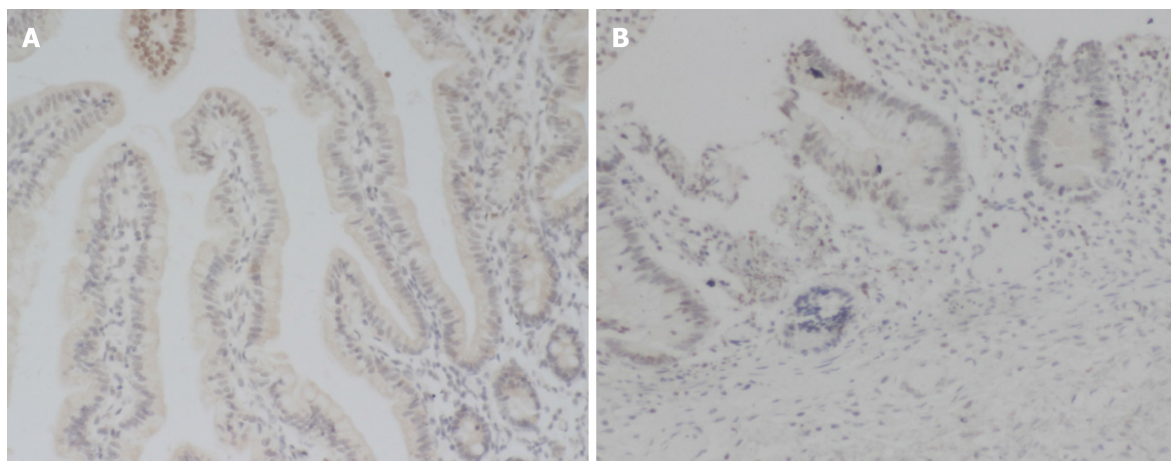


Figure 3 Interleukin-11 protein immunohistochemical staining. A: The intestinal mucosal tissue of the control group; B: The necrotizing enterocolitis intestinal mucosal tissue. It can be seen that the coloring is deeper in the control group, and the interleukin-11 protein expression intensity is stronger, $\times 200$.

is not easily recognized by the immune system. MUC1 plays roles in lubrication, protecting cells, maintaining stickiness, identifying cells and maintaining the functional integrity of epithelial cells. In addition, MUC1 can participate in intercellular signal transduction and immune regulation[15,16]. Studies have shown that damage to and repair of the intestinal mucosa can lead to abnormal glycosylation, weaken intestinal mucosal epithelial barrier function, and lead to the release of large amounts of MUC1[17]. Some scholars have pointed out that the MUC1 protein is an important part of maintaining the stability of the intestinal environment and affects cell proliferation, apoptosis and self-phagocytosis through a variety of signaling pathways. The destruction of MUC1 leads to the formation of an infectious environment, inflammatory diseases or inflammation-related tumors[18]. In addition, MUC1 can regulate the inflammatory response, membrane-bound mucin can regulate inflammation through MUC1, and its extracellular part can bind with bacteria to release its receptor from the cell membrane and activate the nuclear factor kappa B pathway to regulate the inflammatory response. Membrane-bound mucin plays a very important role in regulating the intestinal mucosal barrier, as the last mucin barrier is distributed on the surface of the cell membrane[19,20].

The results showed that the protein expression of MUC-1 and IL-11 in the NEC group was significantly lower than that in the control group. This result indicated that there was a decrease in the protein expression of MUC-1 and IL-11 in children with NEC. The levels of serum TNF- α and IL-1 β in the NEC group were higher than those in the control group. This result indicated that the levels of TNF- α and IL-1 β were significantly increased in children with NEC, and the degree of the inflammatory reaction *in vivo* was exacerbated. There was a significant negative correlation between the protein expression of MUC-1 and IL-11 and the levels of serum TNF- α and IL-1 β in the NEC group. This study confirmed that there was abnormal protein expression of MUC-1 and IL-11 in children with NEC and that there was a negative correlation with the degree of inflammation. This study provides a new basis for reasonable clinical prediction of the pathogenesis and disease progression in children with NEC. However, the follow-up time in this study was short, and there were few cases in the group. As a consequence, it is necessary to expand the sample size and perform long-term follow-up for in-depth analysis.

CONCLUSION

Overall, the protein expression of MUC1 and IL-11 in the intestinal mucosa of children with NEC was significantly downregulated after surgery. This downregulation may be involved in the occurrence of the disease and has a certain correlation with inflammatory response factors in children with NEC.

ARTICLE HIGHLIGHTS

Research background

In the clinic, neonatal necrotizing enterocolitis (NEC) is a frequently occurring pediatric intestinal inflammatory disease. The mortality of premature infants with NEC is as high as 50%, and the incidence shows an increasing trend, which has serious impacts on the quality of life of children.

Research motivation

This study provides help for the clinical diagnosis and treatment of neonatal NEC.

Research objectives

This study aimed to investigate the expression and significance of mucin 1 (MUC1) and interleukin-11 (IL-11) in the intestinal mucosa of children with neonatal NEC after surgery.

Research methods

Total 48 postoperative intestinal mucosal specimens from children with NEC (NEC group) and 22 intestinal mucosal specimens from congenital intestinal atresia (control group) were collected in our hospital. Immunohistochemical staining and Western-blot technique were used to detect the expression of MUC-1 protein and IL-11 protein in the two groups. The serum levels of tumor necrosis factor- α (TNF- α) and interleukin-1 β (IL-1 β) in the two groups were detected by enzyme-linked immunosorbent assay, and the relationship between MUC-1 protein, IL-11 protein and serum TNF- α and IL-1 β was analyzed by linear correlation method.

Research results

The protein expression of MUC-1 and IL-11 in the NEC group was significantly lower than that in the control group, and the difference was statistically significant. The levels of serum TNF- α and IL-1 β in the NEC group were significantly higher than those in the control group. The protein expression of MUC-1 and IL-11 in the NEC group negatively correlated with serum TNF- α and IL-1 β levels. There was a significant negative correlation between the protein expression of MUC-1 and IL-11 and the levels of serum TNF- α and IL-1 β in the NEC group.

Research conclusions

The protein expression of MUC1 and IL-11 in the intestinal mucosa of children with NEC is significantly downregulated after surgery. This down regulation may be involved in the pathogenesis of the disease and has a certain correlation with inflammatory response factors in children with NEC.

Research perspectives

MUC1 and IL-11 proteins may be related to the pathogenesis of the disease and have a certain correlation with inflammatory response factors in children with NEC, which has profound clinical significance.

REFERENCES

- 1 Maheshwari A. Role of platelets in neonatal necrotizing enterocolitis. *Pediatr Res* 2021; **89**: 1087-1093 [PMID: 32601461 DOI: 10.1038/s41390-020-1038-8]
- 2 Evidence-Based Medicine Group. [Clinical guidelines for the diagnosis and treatment of neonatal necrotizing enterocolitis (2020)]. *Zhongguo Dang Dai Er Ke Za Zhi* 2021; **23**: 1-11 [PMID: 33476530 DOI: 10.7499/j.issn.1008-8830.2011145]
- 3 Mattern J, Marin T. Neonatal Microbiome and Its Relationship to Necrotizing Enterocolitis: A Review of the Science. *J Perinat Neonatal Nurs* 2020; **34**: 276-282 [PMID: 32697548 DOI: 10.1097/JPN.0000000000000507]
- 4 El-Abd Ahmed A, Hassan MH, Abo-Halawa N, Abdel-Razik GM, Moubarak FA, Sakhr HM. Lactate and intestinal fatty acid binding protein as essential biomarkers in neonates with necrotizing enterocolitis: ultrasonographic and surgical considerations. *Pediatr Neonatol* 2020; **61**: 481-489 [PMID: 32336643 DOI: 10.1016/j.pedneo.2020.03.015]
- 5 Oldenburg KS, O'Shea TM, Fry RC. Genetic and epigenetic factors and early life inflammation as predictors of neurodevelopmental outcomes. *Semin Fetal Neonatal Med* 2020; **25**: 101115 [PMID: 32444251 DOI: 10.1016/j.siny.2020.101115]

- 6 **Surlis C**, McNamara K, O'Hara E, Waters S, Beltman M, Cassidy J, Kenny D. Birth delivery method affects expression of immune genes in lung and jejunum tissue of neonatal beef calves. *BMC Vet Res* 2017; **13**: 391 [PMID: [29237479](#) DOI: [10.1186/s12917-017-1310-2](#)]
- 7 **Tadesse S**, Corner G, Dhima E, Houston M, Guha C, Augenlicht L, Velcich A. MUC2 mucin deficiency alters inflammatory and metabolic pathways in the mouse intestinal mucosa. *Oncotarget* 2017; **8**: 71456-71470 [PMID: [29069719](#) DOI: [10.18632/oncotarget.16886](#)]
- 8 **Al-Ezzy AIA**. Immunopathological and Modulatory Effects of *Cag A+* Genotype on Gastric Mucosa, Inflammatory Response, Pepsinogens, and Gastrin-17 Secretion in Iraqi Patients infected with *H. pylori*. *Open Access Maced J Med Sci* 2018; **6**: 794-802 [PMID: [29875848](#) DOI: [10.3889/oamjms.2018.178](#)]
- 9 **Nitkin CR**, Rajasingh J, Pisano C, Besner GE, Thébaud B, Sampath V. Stem cell therapy for preventing neonatal diseases in the 21st century: Current understanding and challenges. *Pediatr Res* 2020; **87**: 265-276 [PMID: [31086355](#) DOI: [10.1038/s41390-019-0425-5](#)]
- 10 **Wagener K**, Pothmann H, Prunner I, Peter S, Erber R, Aurich C, Drillich M, Gabler C. Endometrial mRNA expression of selected pro-inflammatory factors and mucins in repeat breeder cows with and without subclinical endometritis. *Theriogenology* 2017; **90**: 237-244 [PMID: [28166974](#) DOI: [10.1016/j.theriogenology.2016.12.013](#)]
- 11 **Mahmutovic Persson I**, Menzel M, Ramu S, Cerps S, Akbarshahi H, Uller L. IL-1 β mediates lung neutrophilia and IL-33 expression in a mouse model of viral-induced asthma exacerbation. *Respir Res* 2018; **19**: 16 [PMID: [29361942](#) DOI: [10.1186/s12931-018-0725-z](#)]
- 12 **Shelby RD**, Raab R, Besner GE, McElroy SJ. Hope on the horizon: promising novel therapies for necrotizing enterocolitis. *Pediatr Res* 2020; **88**: 30-34 [PMID: [32855510](#) DOI: [10.1038/s41390-020-1077-1](#)]
- 13 **Ypsilantis P**, Lambropoulou M, Evagellou A, Papadopoulos N, Simopoulos C. Immune and Inflammatory Responses of the Intestinal Mucosa following Extended Liver Radiofrequency Ablation. *Gastroenterol Res Pract* 2017; **2017**: 3450635 [PMID: [29209365](#) DOI: [10.1155/2017/3450635](#)]
- 14 **Djuric Z**, Turgeon DK, Sen A, Ren J, Herman K, Ramaswamy D, Zhao L, Ruffin MT 4th, Normolle DP, Smith WL, Brenner DE. The Anti-inflammatory Effect of Personalized Omega-3 Fatty Acid Dosing for Reducing Prostaglandin E₂ in the Colonic Mucosa Is Attenuated in Obesity. *Cancer Prev Res (Phila)* 2017; **10**: 729-737 [PMID: [29133307](#) DOI: [10.1158/1940-6207.CAPR-17-0091](#)]
- 15 **Cloots RHE**, Sankaranarayanan S, Poynter ME, Terwindt E, van Dijk P, Lamers WH, Eleonore Köhler S. Arginase 1 deletion in myeloid cells affects the inflammatory response in allergic asthma, but not lung mechanics, in female mice. *BMC Pulm Med* 2017; **17**: 158 [PMID: [29183288](#) DOI: [10.1186/s12890-017-0490-7](#)]
- 16 **Pisano C**, Galley J, Elbahrawy M, Wang Y, Farrell A, Brigstock D, Besner GE. Human Breast Milk-Derived Extracellular Vesicles in the Protection Against Experimental Necrotizing Enterocolitis. *J Pediatr Surg* 2020; **55**: 54-58 [PMID: [31685268](#) DOI: [10.1016/j.jpedsurg.2019.09.052](#)]
- 17 **Vitale S**, Strisciuglio C, Pisapia L, Miele E, Barba P, Vitale A, Cenni S, Bassi V, Maglio M, Del Pozzo G, Troncone R, Staiano A, Gianfrani C. Cytokine production profile in intestinal mucosa of paediatric inflammatory bowel disease. *PLoS One* 2017; **12**: e0182313 [PMID: [28797042](#) DOI: [10.1371/journal.pone.0182313](#)]
- 18 **Ungaro F**, Massimino L, Furfaro F, Rimoldi V, Peyrin-Biroulet L, D'Alessio S, Danese S. Metagenomic analysis of intestinal mucosa revealed a specific eukaryotic gut virome signature in early-diagnosed inflammatory bowel disease. *Gut Microbes* 2019; **10**: 149-158 [PMID: [30252582](#) DOI: [10.1080/19490976.2018.1511664](#)]
- 19 **Sznurkowska K**, Żawrocki A, Sznurkowski J, Iżycka-Świeszewska E, Landowski P, Szlagatys-Sidorkiewicz A, Plata-Nazar K, Kamińska B. Indoleamine 2,3-dioxygenase and regulatory t cells in intestinal mucosa in children with inflammatory bowel disease. *J Biol Regul Homeost Agents* 2017; **31**: 125-131 [PMID: [28337881](#)]
- 20 **Patel AL**, Meier PP, Canvasser J. Strategies to increase the use of mother's own milk for infants at risk of necrotizing enterocolitis. *Pediatr Res* 2020; **88**: 21-24 [PMID: [32855508](#) DOI: [10.1038/s41390-020-1075-3](#)]



Published by **Baishideng Publishing Group Inc**
7041 Koll Center Parkway, Suite 160, Pleasanton, CA 94566, USA

Telephone: +1-925-3991568

E-mail: bpgoffice@wjgnet.com

Help Desk: <https://www.f6publishing.com/helpdesk>

<https://www.wjgnet.com>

