

Percutaneous rheolytic thrombectomy for treatment of acute ...<https://pubmed.ncbi.nlm.nih.gov/15735387>

Case report: A 63-year-old male patient with **renal-artery thrombosis** presented 48 hours after the onset of acute nonradiating flank pain. **Thrombosis** was documented by CT angiography, 99mTc-DTPA, and digital subtraction angiography. A percutaneous **thrombectomy** was performed with the AngioJet catheter. At the end of the procedure, the arterial lumen was ...

Cited by: 17**Author:** Dimitrios Siablis, Evangelos N. Liatsik...**Publish Year:** 2005**Mechanical aspiration thrombectomy in the treatment of ...**<https://www.sciencedirect.com/science/article/pii/S1553838918301398>

Apr 01, 2019 · Acute **renal artery** occlusion is a serious complication after this technique. We **report a case** of acute right **renal artery** occlusion, consequent to a previous chimney-and-periscope technique that was treated urgently by **mechanical aspiration thrombectomy**.

Cited by: 2**Author:** Umberto G. Rossi, Gian Andrea Rolla...**Publish Year:** 2019**[PDF] Ultrasound-guided mechanical thrombectomy of a ...**www.straubmedical.com/userdata/uploads/case-report...

Ultrasound-guided **mechanical thrombectomy** of a moderate External Iliac **Artery** (EIA)-Stenosis with the **mechanical Rotarex**®S 8F catheter system in a complex **case** Dr. med. Christian Jacke Head of the Angiological Department Patricia Lüders Dr. med. Christian Jacke CA Dr. med. Thomas Nowak Alfried Krupp Hospital Rüttenscheid Alfried-Krupp-Straße 21

Acute kidney injury following percutaneous mechanical ...<https://cvirendovasc.springeropen.com/articles/10.1186/s42155-020-00119-0> ▾

Jun 01, 2020 · Percutaneous **mechanical thrombectomy** (PMT) is a well-established technique for treatment of acute arterial and venous **thrombosis** which inevitably leads to intravascular erythrocyte hemolysis, resulting in hemoglobinuria. We present **a case** of 66-year-old Caucasian female with subclavian **artery** aneurysm causing distal embolization and hand ischemia.

ALL IMAGES VIDEOS

10,300 Results Any time ▾

[Percutaneous rheolytic thrombectomy for treatment of acute...](https://pubmed.ncbi.nlm.nih.gov/15735387)

Purpose: We present our experience with percutaneous rheolytic treatment with the AngloJet thrombectomy catheter for acute renal-artery thrombosis. Case report: A 63-year-old male patient with renal-artery thrombosis presented 48 hours after the onset of acute nonradiating flank pain. Thrombosis was documented by CT angiography, 99mTc-DTPA, and digital subtraction angiography.

Cited by: 17 Author: Dimitrios Siablis, Evangelos N. Liatsikos, DL...
Publish Year: 2005

Search Tools

Turn off Hover Translation (关闭取词)

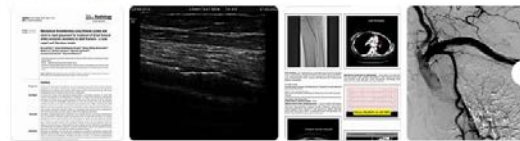
[\[PDF\] CASE REPORT Mechanical Thrombectomy with Rotarex ...](https://www.researchgate.net/profile/Ozgur...)

<https://www.researchgate.net/profile/Ozgur...>

The present case report demonstrates the success of mechanical thrombectomy in a patient with Buerger's vasculitis. Key words: Buerger's disease, mechanical thrombectomy, Rotarex, thromboangiitis

Images of Rotarex Mechanical thrombectomy in Renal Artery thro...

bing.com/images



See all images >

[Mechanical Thrombectomy for Basilar Artery Occlusion ...](https://pubmed.ncbi.nlm.nih.gov/32968302)

<https://pubmed.ncbi.nlm.nih.gov/32968302>

Acute basilar artery occlusion stroke is a rare posterior circulation stroke that needs emergent management. We report the case of a 67-year-old woman who developed an acute basilar artery occlusion. We achieved complete recanalization of the occluded basilar artery and its branches with endovascular mechanical thrombectomy.

Author: Subash Phuyal, Kapil Dawadi, Raju Pau... Publish Year: 2020

国内版

国际版

Rotarex mechanical thrombectomy in renal artery thrombosis: A ca



ALL

IMAGES

VIDEOS

10,300 Results

Any time ▾

Percutaneous rheolytic thrombectomy for treatment of acute ...

<https://pubmed.ncbi.nlm.nih.gov/15735387>

Purpose: We present our experience with percutaneous rheolytic treatment with the AngioJet thrombectomy catheter for acute renal-artery thrombosis. **Case report:** A 63-year-old male patient with renal-artery thrombosis presented 48 hours after the onset of acute nonradiating flank pain. Thrombosis was documented by CT angiography, 99mTc-DTPA, and digital subtraction angiography.

Cited by: 17

Author: Dimitrios Siablis, Evangelos N. Liatsikos,...

Publish Year: 2005

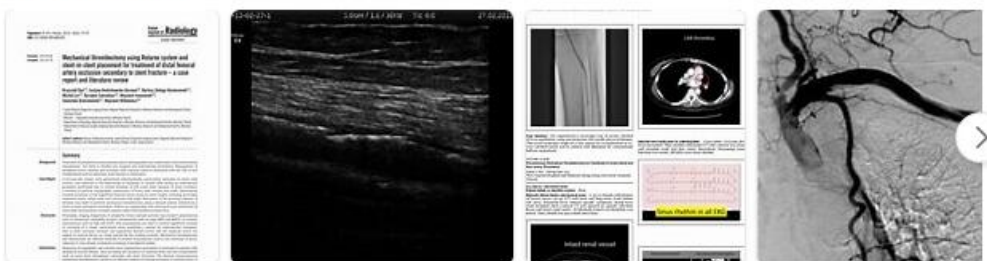
[PDF] CASE REPORT Mechanical Thrombectomy with Rotarex ...

<https://www.researchgate.net/profile/Ozgur...>

The present case report demonstrates the success of mechanical thrombectomy in a patient with Buerger's vasculitis. Key words: Buerger's disease, mechanical thrombectomy, Rotarex...

Images of Rotarex Mechanical thrombectomy in Renal Artery ...

<bing.com/images>



See all images >

Mechanical Thrombectomy for Basilar Artery Occlusion ...

<https://pubmed.ncbi.nlm.nih.gov/32968302>

Acute basilar artery occlusion stroke is a rare posterior circulation stroke that needs emergent management. We report the case of a 67-year-old woman who developed an acute basilar artery