

ALL IMAGES VIDEOS

192,000 Results Any time ▾

(PDF) Oblique Bile Duct Predisposes to the Recurrence of ...<https://www.researchgate.net/publication/235386681...>

Jan 24, 2013 · recurrent common bile duct stones in previous studies [15,16]. Indeed, five of our OCB
patients with a history of more than five ERCPs underwent a resection of the oblique CBD.

Updated guideline on the management of common bile duct ...<https://gut.bmj.com/content/66/5/765>

May 01, 2017 · May 01, 2017 · Several large observational studies have examined the importance of gall
bladder status in Asian patients who have undergone successful endoscopic duct clearance.151–153...

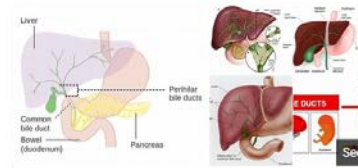
(PDF) Management of Common Bile Duct Stones in the ...<https://www.researchgate.net/publication/237014358...>

Patients and methods The study includes 30 patients diagnosed as having CBD stones proved clinically
and through laboratory investigations in the form of obstructive jaundice and confirmed ...

Management of Common Bile Duct Stones in the Laparoscopic ...europepmc.org/articles/PMC3397180

It treats both gallstones and CBD stones in single stage compared with sequential procedures, and is
performed as a daycare procedure . LCBDE also preserves the function of sphincter of Oddi and hence...

Estimated Reading Time: 7 mins

**Bile duct**

Function Anatomy Facts

A bile duct is any of a number of long tube-like structures that car
and is present in most vertebrates. Bile, required for the digestion
is secreted by the liver into passages that carry bile toward the he
duct, which joins with the cystic duct to form the common bile du
opens into the intestine.

W WikipediaPeople also search for: Common bile duct · Duodenum · Common
bile duct · Common bile duct · Common bile duct · Common bile duct

ALL

IMAGES

VIDEOS

12,100 Results

Any time ▾

Open links in new tab

Biliary Interventions: Benign Biliary Strictures

<https://www.ncbi.nlm.nih.gov/pmc/articles/PMC5088102>

The most **common** causes include iatrogenic **bile duct** injuries following orthotopic liver transplantation (OLT) or cholecystectomy, accounting for up to 80% of all benign strictures in the western world. 2 Autoimmune and inflammatory conditions **associated** with biliary strictures include primary sclerosing cholangitis (PSC), IgG4-related sclerosing cholangitis in isolation or in association with autoimmune ...

Cited by: 10

Author: Ashley Altman, Steven M. Zangan

Publish Year: 2016

Congenital double bile duct presenting as recurrent ...

<https://www.sciencedirect.com/science/article/pii/S2213576615300129>

Dec 01, 2015 · Anatomical variations in the biliary **anatomy** are less commonly seen. But double **common bile duct** (DCBD) is an extremely rare congenital anomaly in which 2 **common bile** ducts exist .This anomaly is of great importance since it is often **associated** with **bile duct stones**, choledochal cyst, anomalous pancreaticobiliary junction (APBJ), cholangitis, pancreatitis and upper gastrointestinal tract ...

Author: K.D. Chakravarty, Jaya Agarwal, A.C. ...

Publish Year: 2015

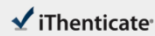PEOPLE ALSO ASK

What are the side effects of common bile duct exploration?

▾

Can a common bile duct stone cause jaundice?

▾



67638_Auto_Edited - check.docx

Quotes Excluded
Bibliography Included4%
Matches

Name of Journal: *World Journal of Clinical Cases*

Manuscript NO: 67638

Manuscript Type: ORIGINAL ARTICLE

Case Control Study

Common bile duct morphology is associated with recurrence of common bile duct stones in billroth II anatomy patients

Ji X *et al.* CBD stones recurrence and CBD morphology

Xu Ji, Wen Jia, Qian Zhao, Yao Wang, Shu-Ren Ma, Lu Xu, Ying Kan, Yang Cao, Bao-Jun Fan, Zhuo Yang

Match Overview

1	Crossref 15 words Ryuichi Yamamoto, Susumu Tazuma, Keshi Kanno, Yoshi non Igarashi et al. "Ursodeoxycholic acid after bile duct st...	<1%
2	Internet 15 words crawled on 29-Jun-2020 jds.amegroups.com	<1%
3	Crossref 14 words Zhen Sun, Wenhui Bo, Ping Jiang, Quan Sun. "Different Ty pes of Periapical Duodenal Diverticula Are Associated	<1%
4	Crossref 13 words Byung Kyu Park, Jeong Hun Seo, Han Ho Jeon, Jung Won Choi et al. "A nationwide population-based study of comm...	<1%
5	Internet 13 words crawled on 12-Sep-2017 www.ncbi.nlm.nih.gov	<1%
6	Internet 12 words crawled on 03-Nov-2017 helsa.helsinki.fi	<1%
7	Internet 12 words crawled on 23-Jul-2021 www.sciencedirect.com	<1%

国内版

国际版

关闭

Common bile duct morphology is associated with recurrence of co



ALL

IMAGES

VIDEOS

12,100 Results

Any time ▾

(PDF) Oblique Bile Duct Predisposes to the Recurrence of ...

<https://www.researchgate.net/publication/235386681...>



Jan 24, 2013 · recurrent common bile duct stones in previous studies [15,16]. Indeed, five of our OCBD patients with a history of more than five ERCPs underwent a resection of the oblique CBD.

[PDF] Updated Guideline on the Management of Common Bile ...

<https://www.bsg.org.uk/wp-content/uploads/2019/12/...>

Common bile duct stones (CBDS) are estimated to be present in 10–20% of individuals with symptomatic ... prevent recurrent episodes. (Moderate-quality evidence, strong recommendation) ... patients with Billroth II anatomy. Where ERCP with a duodeno-scope is difficult, use of a forward viewing endoscope is recom- ...

PEOPLE ALSO ASK

What are the side effects of common bile duct exploration?



Can a bile duct stone be seen on an ultrasound?



What does thick slab on biliary tract look like?



What kind of catheter is used for bile duct clearance?



Feedback

Biliary Interventions: Benign Biliary Strictures

<https://www.ncbi.nlm.nih.gov/pmc/articles/PMC5088102>

The most common causes include iatrogenic bile duct injuries following orthotopic liver transplantation (OLT) or cholecystectomy, accounting for up to 80% of all benign strictures in the western world. 2 Autoimmune and inflammatory conditions associated with biliary strictures include primary sclerosing cholangitis (PSC), IgG4-related sclerosing cholangitis in isolation or in association with autoimmune ...

Cited by: 10

Author: Ashley Altman, Steven M. Zangan

PubMed - 2016