


# World Journal of *Clinical Cases*

*World J Clin Cases* 2021 August 16; 9(23): 6582-6963



## OPINION REVIEW

- 6582 COVID-19 pandemic, as experienced in the surgical service of a district hospital in Spain

*Pérez Lara FJ, Jimenez Martinez MB, Pozo Muñoz F, Fontalba Navas A, Garcia Cisneros R, Garcia Larrosa MJ, Garcia Delgado I, Callejon Gil MDM*

## REVIEW

- 6591 Beta-carotene and its protective effect on gastric cancer

*Chen QH, Wu BK, Pan D, Sang LX, Chang B*

- 6608 Liver transplantation during global COVID-19 pandemic

*Alfishawy M, Nso N, Nassar M, Ariyaratnam J, Bhuiyan S, Siddiqui RS, Li M, Chung H, Al Balakosy A, Alqassieh A, Fülöp T, Rizzo V, Daoud A, Soliman KM*

- 6624 Nonalcoholic fatty pancreas disease: An emerging clinical challenge

*Zhang CL, Wang JJ, Li JN, Yang Y*

## MINIREVIEWS

- 6639 Novel mechanism of hepatobiliary system damage and immunoglobulin G4 elevation caused by *Clonorchis sinensis* infection

*Zhang XH, Huang D, Li YL, Chang B*

- 6654 Intestinal microbiota participates in nonalcoholic fatty liver disease progression by affecting intestinal homeostasis

*Zhang Y, Li JX, Zhang Y, Wang YL*

- 6663 Theory and reality of antivirals against SARS-CoV-2

*Zhao B, Yang TF, Zheng R*

- 6674 Acute acalculous cholecystitis due to infectious causes

*Markaki I, Konsoula A, Markaki L, Spornovasilis N, Papadakis M*

## ORIGINAL ARTICLE

## Case Control Study

- 6686 Innate immunity – the hallmark of *Helicobacter pylori* infection in pediatric chronic gastritis

*Meliş LE, Mărginean CO, Săsară MO, Mocan S, Ghiga DV, Bogliş A, Duicu C*

## Retrospective Study

- 6698 Effects on newborns of applying bupivacaine combined with different doses of fentanyl for cesarean section

*Wang Y, Liu WX, Zhou XH, Yang M, Liu X, Zhang Y, Hai KR, Ye QS*

- 6705** Awake fiberoptic intubation and use of bronchial blockers in ankylosing spondylitis patients  
*Yang SZ, Huang SS, Yi WB, Lv WW, Li L, Qi F*
- 6717** Efficacy of different antibiotics in treatment of children with respiratory mycoplasma infection  
*Zhang MY, Zhao Y, Liu JF, Liu GP, Zhang RY, Wang LM*
- 6725** Expression of caspase-3 and hypoxia inducible factor 1 $\alpha$  in hepatocellular carcinoma complicated by hemorrhage and necrosis  
*Liang H, Wu JG, Wang F, Chen BX, Zou ST, Wang C, Luo SW*
- 6734** Increased morbidity and mortality of hepatocellular carcinoma patients in lower cost of living areas  
*Sempokuya T, Patel KP, Azawi M, Ma J, Wong LL*

**SYSTEMATIC REVIEWS**

- 6747** Safety of pancreatic surgery with special reference to antithrombotic therapy: A systematic review of the literature  
*Fujikawa T, Naito S*
- 6759** What paradigm shifts occurred in the management of acute diverticulitis during the COVID-19 pandemic? A scoping review  
*Gallo G, Ortenzi M, Grossi U, Di Tanna GL, Pata F, Guerrieri M, Sammarco G, Di Saverio S*

**CASE REPORT**

- 6768** Pylephlebitis — a rare complication of a fish bone migration mimicking metastatic pancreatic cancer: A case report  
*Bezerra S, França NJ, Mineiro F, Capela G, Duarte C, Mendes AR*
- 6775** Solitary seminal vesicle metastasis from ileal adenocarcinoma presenting with hematospermia: A case report  
*Cheng XB, Lu ZQ, Lam W, Yiu MK, Li JS*
- 6781** Hepatic abscess caused by esophageal foreign body misdiagnosed as cystadenocarcinoma by magnetic resonance imaging: A case report  
*Pan W, Lin LJ, Meng ZW, Cai XR, Chen YL*
- 6789** 2+0 CYP21A2 deletion carrier — a limitation of the genetic testing and counseling: A case report  
*Xi N, Song X, Wang XY, Qin SF, He GN, Sun LL, Chen XM*
- 6798** Psoriasis treatment using minimally manipulated umbilical cord-derived mesenchymal stem cells: A case report  
*Ahn H, Lee SY, Jung WJ, Pi J, Lee KH*
- 6804** Double intussusception in a teenage child with Peutz-Jeghers syndrome: A case report  
*Chiew J, Sambanthan ST, Mahendran HA*

- 6810** Nedaplatin-induced syndrome of inappropriate secretion of antidiuretic hormone: A case report and review of the literature  
*Tian L, He LY, Zhang HZ*
- 6816** Nasal metastases from neuroblastoma-a rare entity: Two case reports  
*Zhang Y, Guan WB, Wang RF, Yu WW, Jiang RQ, Liu Y, Wang LF, Wang J*
- 6824** Nocardiosis with diffuse involvement of the pleura: A case report  
*Wang P, Yi ML, Zhang CZ*
- 6832** Prenatal diagnosis of triphalangeal thumb-polysyndactyly syndrome by ultrasonography combined with genetic testing: A case report  
*Zhang SJ, Lin HB, Jiang QX, He SZ, Lyu GR*
- 6839** Blue LED as a new treatment to vaginal stenosis due pelvic radiotherapy: Two case reports  
*Barros D, Alvares C, Alencar T, Baqueiro P, Marianno A, Alves R, Lenzi J, Rezende LF, Lordelo P*
- 6846** Diverse microbiota in palatal radicular groove analyzed by Illumina sequencing: Four case reports  
*Tan XL, Chen X, Fu YJ, Ye L, Zhang L, Huang DM*
- 6858** Autism with dysphasia accompanied by mental retardation caused by *FOXP1* exon deletion: A case report  
*Lin SZ, Zhou XY, Wang WQ, Jiang K*
- 6867** *FGFR2-TSC22D1*, a novel *FGFR2* fusion gene identified in a patient with colorectal cancer: A case report  
*Kao XM, Zhu X, Zhang JL, Chen SQ, Fan CG*
- 6872** Trismus originating from rare fungal myositis in pterygoid muscles: A case report  
*Bi L, Wei D, Wang B, He JF, Zhu HY, Wang HM*
- 6879** Retroperitoneal laparoscopic partial nephrectomy for unilateral synchronous multifocal renal carcinoma with different pathological types: A case report  
*Xiao YM, Yang SK, Wang Y, Mao D, Duan FL, Zhou SK*
- 6886** Diffuse large B cell lymphoma originating from the maxillary sinus with skin metastases: A case report and review of literature  
*Usuda D, Izumida T, Terada N, Sangen R, Higashikawa T, Sekiguchi S, Tanaka R, Suzuki M, Hotchi Y, Shimoizawa S, Tokunaga S, Osugi I, Katou R, Ito S, Asako S, Takagi Y, Mishima K, Kondo A, Mizuno K, Takami H, Komatsu T, Oba J, Nomura T, Sugita M, Kasamaki Y*
- 6900** Manifestation of acute peritonitis and pneumonedema in scrub typhus without eschar: A case report  
*Zhou XL, Ye QL, Chen JQ, Li W, Dong HJ*
- 6907** Uterine tumor resembling an ovarian sex cord tumor: A case report and review of literature  
*Zhou FF, He YT, Li Y, Zhang M, Chen FH*
- 6916** Dopamine agonist responsive burning mouth syndrome: Report of eight cases  
*Du QC, Ge YY, Xiao WL, Wang WF*



- 6922** Complete withdrawal of glucocorticoids after dupilumab therapy in allergic bronchopulmonary aspergillosis: A case report  
*Nishimura T, Okano T, Naito M, Tsuji C, Iwanaka S, Sakakura Y, Yasuma T, Fujimoto H, D'Alessandro-Gabazza CN, Oomoto Y, Kobayashi T, Gabazza EC, Ibata H*
- 6929** Sirolimus treatment for neonate with blue rubber bleb nevus syndrome: A case report  
*Yang SS, Yang M, Yue XJ, Tou JF*
- 6935** Combined thoracoscopic and laparoscopic approach to remove a large retroperitoneal compound paraganglioma: A case report  
*Liu C, Wen J, Li HZ, Ji ZG*
- 6943** Menetrier's disease and differential diagnosis: A case report  
*Wang HH, Zhao CC, Wang XL, Cheng ZN, Xie ZY*
- 6950** Post-salpingectomy interstitial heterotopic pregnancy after *in vitro* fertilization and embryo transfer: A case report  
*Wang Q, Pan XL, Qi XR*
- 6956** Ulnar nerve injury associated with displaced distal radius fracture: Two case reports  
*Yang JJ, Qu W, Wu YX, Jiang HJ*

**ABOUT COVER**

Editorial Board Member of *World Journal of Clinical Cases*, Luigi Valentino Berra, MD, Assistant Professor, Neurosurgeon, Department of Neurosurgery, Policlinico Umberto I - Sapienza Università di Roma, Roma 00161, Italy. luigivbe@tin.it

**AIMS AND SCOPE**

The primary aim of *World Journal of Clinical Cases* (WJCC, *World J Clin Cases*) is to provide scholars and readers from various fields of clinical medicine with a platform to publish high-quality clinical research articles and communicate their research findings online.

WJCC mainly publishes articles reporting research results and findings obtained in the field of clinical medicine and covering a wide range of topics, including case control studies, retrospective cohort studies, retrospective studies, clinical trials studies, observational studies, prospective studies, randomized controlled trials, randomized clinical trials, systematic reviews, meta-analysis, and case reports.

**INDEXING/ABSTRACTING**

The WJCC is now indexed in Science Citation Index Expanded (also known as SciSearch®), Journal Citation Reports/Science Edition, Scopus, PubMed, and PubMed Central. The 2021 Edition of Journal Citation Reports® cites the 2020 impact factor (IF) for WJCC as 1.337; IF without journal self cites: 1.301; 5-year IF: 1.742; Journal Citation Indicator: 0.33; Ranking: 119 among 169 journals in medicine, general and internal; and Quartile category: Q3. The WJCC's CiteScore for 2020 is 0.8 and Scopus CiteScore rank 2020: General Medicine is 493/793.

**RESPONSIBLE EDITORS FOR THIS ISSUE**

Production Editor: Jia-Hui Li; Production Department Director: Xiang Li; Editorial Office Director: Jin-Lei Wang.

**NAME OF JOURNAL**

*World Journal of Clinical Cases*

**ISSN**

ISSN 2307-8960 (online)

**LAUNCH DATE**

April 16, 2013

**FREQUENCY**

Thrice Monthly

**EDITORS-IN-CHIEF**

Dennis A Bloomfield, Sandro Vento, Bao-Gan Peng

**EDITORIAL BOARD MEMBERS**

<https://www.wjnet.com/2307-8960/editorialboard.htm>

**PUBLICATION DATE**

August 16, 2021

**COPYRIGHT**

© 2021 Baishideng Publishing Group Inc

**INSTRUCTIONS TO AUTHORS**

<https://www.wjnet.com/bpg/gerinfo/204>

**GUIDELINES FOR ETHICS DOCUMENTS**

<https://www.wjnet.com/bpg/GerInfo/287>

**GUIDELINES FOR NON-NATIVE SPEAKERS OF ENGLISH**

<https://www.wjnet.com/bpg/gerinfo/240>

**PUBLICATION ETHICS**

<https://www.wjnet.com/bpg/GerInfo/288>

**PUBLICATION MISCONDUCT**

<https://www.wjnet.com/bpg/gerinfo/208>

**ARTICLE PROCESSING CHARGE**

<https://www.wjnet.com/bpg/gerinfo/242>

**STEPS FOR SUBMITTING MANUSCRIPTS**

<https://www.wjnet.com/bpg/GerInfo/239>

**ONLINE SUBMISSION**

<https://www.f6publishing.com>



## Combined thoracoscopic and laparoscopic approach to remove a large retroperitoneal compound paraganglioma: A case report

Chang Liu, Jin Wen, Han-Zhong Li, Zhi-Gang Ji

**ORCID number:** Chang Liu 0000-0002-4962-0169; Jin Wen 0000-0001-9509-4668; Han-Zhong Li 0000-0002-3945-8399; Zhi-Gang Ji 0000-0003-2660-0277.

**Author contributions:** Liu C participated in the writing of the manuscript; Wen J contributed to the editing of the manuscript; Li HZ and Ji ZG served as scientific advisors; all authors have read and approved the final manuscript.

**Supported by** the Non-profit Central Research Institute Fund of Chinese Academy of Medical Sciences, No. 2019XK320027; and the Project Management Fund for Foreign Cultural and Educational Experts, No. G20190001645.

**Informed consent statement:** Written informed consent was obtained from the patient for publication of this case report and any accompanying images.

**Conflict-of-interest statement:** The authors declare that they have no competing interests related to this manuscript.

**CARE Checklist (2016) statement:** The authors have read the CARE Checklist (2016), and the manuscript was prepared and revised according to the CARE Checklist (2016).

**Chang Liu**, Department of Surgery, Peking Union Medical College Hospital, Chinese Academy of Medical Sciences and Peking Union Medical College, Beijing 100730, China

**Jin Wen, Han-Zhong Li, Zhi-Gang Ji**, Department of Urology, Peking Union Medical College Hospital, Chinese Academy of Medical Sciences and Peking Union Medical College, Beijing 100730, China

**Corresponding author:** Jin Wen, MD, Associate Professor, Department of Urology, Peking Union Medical College Hospital, Chinese Academy of Medical Sciences and Peking Union Medical College, No. 1 Shuaifuyuan, Dongcheng District, Beijing 100730, China.  
[wjpumch@163.com](mailto:wjpumch@163.com)

### Abstract

#### BACKGROUND

Paragangliomas (PGLs) are rare catecholamine-secreting neuroendocrine tumors, which often present with secondary hypertension. The most common location is the retroperitoneal space. For the first time, we report a rare case of large retroperitoneal compound PGL, and we have innovatively applied a new surgical plan to completely remove the tumor.

#### CASE SUMMARY

A 55-year-old middle-aged man was admitted to the hospital for fluctuating blood pressure for more than 1 year with intermittent headache. He suffered dozens of attacks every day. Blood and urine catecholamines were elevated, somatostatin receptor imaging was positive, and the diagnosis of PGL was clear. The imaging examination revealed a large tumor on the right front of the mediastinal spine at the level of T10-L1 (the posterior space of the right phrenic foot). For the first time in our department, a combined thoracoscopic and laparoscopic operation was used to detect and remove large tumors.

#### CONCLUSION

This is the first reported case of using a thoracoscopic and laparoscopic approach simultaneously to remove a large retroperitoneal compound PGL, which may provide a new surgical approach for similar cases.

**Key Words:** Paraganglioma; Compound paraganglioma; Combined thoracoscopy and laparoscopy; Case report

**Open-Access:** This article is an open-access article that was selected by an in-house editor and fully peer-reviewed by external reviewers. It is distributed in accordance with the Creative Commons Attribution NonCommercial (CC BY-NC 4.0) license, which permits others to distribute, remix, adapt, build upon this work non-commercially, and license their derivative works on different terms, provided the original work is properly cited and the use is non-commercial. See: <http://creativecommons.org/licenses/by-nc/4.0/>

**Manuscript source:** Unsolicited manuscript

**Specialty type:** Urology and nephrology

**Country/Territory of origin:** China

**Peer-review report's scientific quality classification**

Grade A (Excellent): 0  
Grade B (Very good): 0  
Grade C (Good): C  
Grade D (Fair): 0  
Grade E (Poor): 0

**Received:** May 6, 2021

**Peer-review started:** May 6, 2021

**First decision:** June 6, 2021

**Revised:** June 7, 2021

**Accepted:** June 22, 2021

**Article in press:** June 22, 2021

**Published online:** August 16, 2021

**P-Reviewer:** Marickar F

**S-Editor:** Wu YXJ

**L-Editor:** Wang TQ

**P-Editor:** Wang LYT



©The Author(s) 2021. Published by Baishideng Publishing Group Inc. All rights reserved.

**Core Tip:** We report a rare case of large retroperitoneal compound paraganglioma (PGL) for the first time, and a combined thoracoscopic and laparoscopic operation was used to detect and remove the large tumor. This is the first reported case of using a thoracoscopic and laparoscopic approach simultaneously to remove a large retroperitoneal compound PGL.

**Citation:** Liu C, Wen J, Li HZ, Ji ZG. Combined thoracoscopic and laparoscopic approach to remove a large retroperitoneal compound paraganglioma: A case report. *World J Clin Cases* 2021; 9(23): 6935-6942

**URL:** <https://www.wjgnet.com/2307-8960/full/v9/i23/6935.htm>

**DOI:** <https://dx.doi.org/10.12998/wjcc.v9.i23.6935>

## INTRODUCTION

Paragangliomas (PGLs) are rare catecholamine-secreting neuroendocrine tumors, which often present with secondary hypertension[1,2]. PGLs arise from chromaffin cells at the extra-adrenal sites along the sympathetic and/or parasympathetic chain, and they have an incidence of 15%-20%[1,3]. PGLs can be found at any site in the entire body, from the skull to the pelvic floor, and the majority of these tumors occur in the abdomen. Approximately 10% of the tumors are located in the retroperitoneal space[4]. The most common location is the retroperitoneal space, which accounts for up to 77% of tumors often pictured as a mass around the corpora paraaortic[5,6]. However, PGLs that occur in the posterior space of the phrenic angle and are covered by the psoas muscle are extremely rare. After consulting the literature, we found that no similar reports have been presented earlier.

Surgical resection represents the only available curative treatment for these tumors. The close proximity to major vessels and limited accessibility make it difficult to safely remove a retroperitoneal PGL in the abdomen. The laparoscopic approach has proved to be a safe and effective technique for retroperitoneal tumor resection in experienced hands[7,8]. So far, there has been no report in the literature on a combined thoracoscopic approach to detect and remove a PGL.

We herein report a case of combined thoracoscopic and laparoscopic approach to remove a large retroperitoneal compound PGL.

## CASE PRESENTATION

### Chief complaints

A 55-year-old middle-aged man was admitted to the hospital due to hypertension for more than 1 year.

### History of present illness

The blood pressure fluctuated between 220-230/120-130 mmHg. It was relieved when standing in a different position, accompanied by intermittent headaches, which could relieve itself in more than 10 min, and the patient experienced dozens of attacks every day. The general condition was good, and he had no other symptoms.

### History of past illness

The patient had a free previous medical history.

### Personal and family history

The patient had no personal and family history.

### Physical examination

Physical examination revealed no obvious positive signs.

### Laboratory examinations

Laboratory examination showed elevated blood levels of meta-norepinephrine (10.76 nmol/L) and metanephrine (3.39 nmol/L), and 24 h urine catecholamine levels were as follows: Dopamine 341.68 µg/24 h (elevated), norepinephrine 37.03 µg/24 h, and epinephrine 4.58 µg/24 h.

### Imaging examinations

Contrast-enhanced computed tomography (CT) + three-dimensional (3D) reconstruction of the abdomen and pelvis showed the following findings (Figure 1): At about the T10-L1 level, the right front of the posterior mediastinal spine (right posterior space of the phrenic foot) showed an elliptical mixed density shadow with smooth borders and a size of 3.3 cm × 6.9 cm × 8.4 cm, the CT value of the solid part was about 33 Hu during the plain scan, and there was light-to-moderate enhancement after enhancement. The CT values of the arterial phase and portal phase were about 54 Hu and 77 Hu, respectively. The center showed a low-enhancement area and a patchy shadow next to the right lower lung lesion. Somatostatin receptor imaging was performed, and it showed the following findings (Figure 2): A cystic solid space was seen on the right side of the abdominal aorta and behind the inferior vena cava at the level of the T10-L1 vertebral body, with a size of 7.3 cm × 3.6 cm × 9.4 cm and increased radioactive uptake. The patient was prepared for medication (phenoxybenzamine) for 10 mo before the operation. To reproduce the tumor morphology more intuitively, our hospital carried out 3D printing based on the imaging data (Figure 3).

---

## FINAL DIAGNOSIS

---

The final diagnosis of the presented case was PGL.

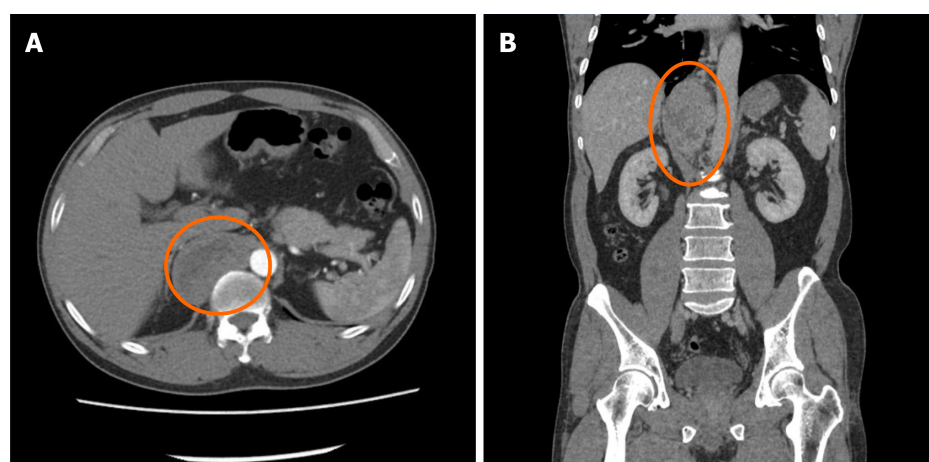
---

## TREATMENT

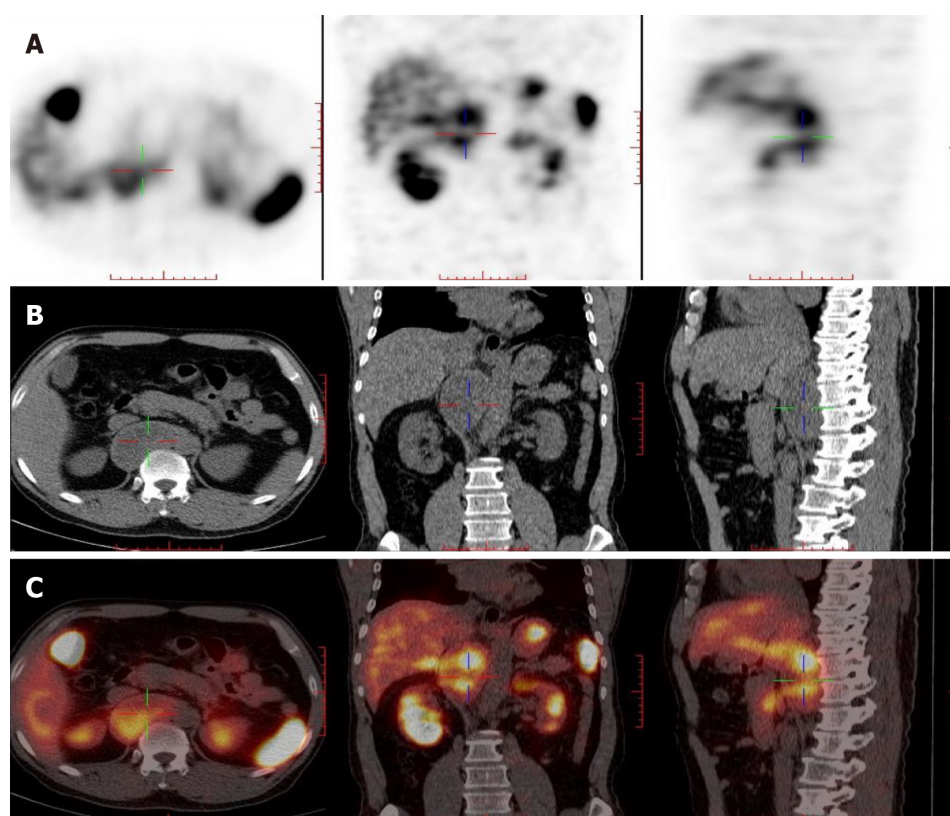
---

After consultations with liver surgery, vascular surgery, orthopedics, thoracic surgery, anesthesiology, and intensive care unit departments, our department and thoracic surgeons formulated a special surgical plan for this case: Thoracoscopic- and laparoscopic-assisted resection of the right retroperitoneal PGL. A double-lumen cannula was used for anesthesia. The patient was placed in the left side lying position, the lumbar bridge was raised, and a total of seven laparoscopic ports were created through the posterior abdominal cavity and thoracic cavity. The laparoscopic puncture holes were as follows: (1) The mid-axillary line 3 cm above the iliac crest; (2) The front axillary line ribs submarginal; (3) Posterior axillary line under the costal margin; and (4) Between (1) and (2). The thoracoscopic puncture holes were as follows: (1) The seventh intercostal space of the anterior axillary line; (2) The eighth intercostal space of the posterior axillary line; and (3) The mid-axillary line ninth in the intercostal area. During laparoscopic surgery, the psoas major muscle of the right phrenic angle was locally uplifted, with a range of about 5 cm × 4 cm. The size of the thoracic cavity was about 3 cm × 4 cm, a large number of tortuous blood vessels could be seen on the surface of the tumor, the capsule was complete, and the tension was high. A thoracoscope and laparoscope were used simultaneously, and the blunt and sharp combination separated the tumor from the posterior chest wall, diaphragm, and psoas muscle along the surface of the tumor. It was seen that the inside of the tumor adhered tightly to the adjacent parts of the vertebral body and inferior vena cava, and multiple bundles of blood vessels penetrated the tumor from the pleural wall and paravertebral body. Much blood was oozing into the surgical field. Between the ninth to twelfth ribs, a combined thoracic-abdominal arc-shaped incision was made, and the skin, subcutaneous tissue, and muscle layers were cut sequentially. The ninth rib was broken, and the diaphragm was cut longitudinally. It could be seen that the tumor and the surrounding tissues adhered extremely, and the ninth, tenth, and eleventh left intercostal arteries passed through the tumor. Then, the tumor supplying blood vessels were separated by the thoracic surgeon one by one, ligated, and sutured (Figure 4). Attention was paid to the protection of adjacent organs and important blood vessels and nerves, and gradually, the tumor and the posterior phrenic angle tissue in the affected right diaphragm were separated and the tumor completely removed (Figure 5). Completeness of the specimen envelope was checked. The wound was rinsed with warm distilled water to fully stop bleeding. The stump of the posterior



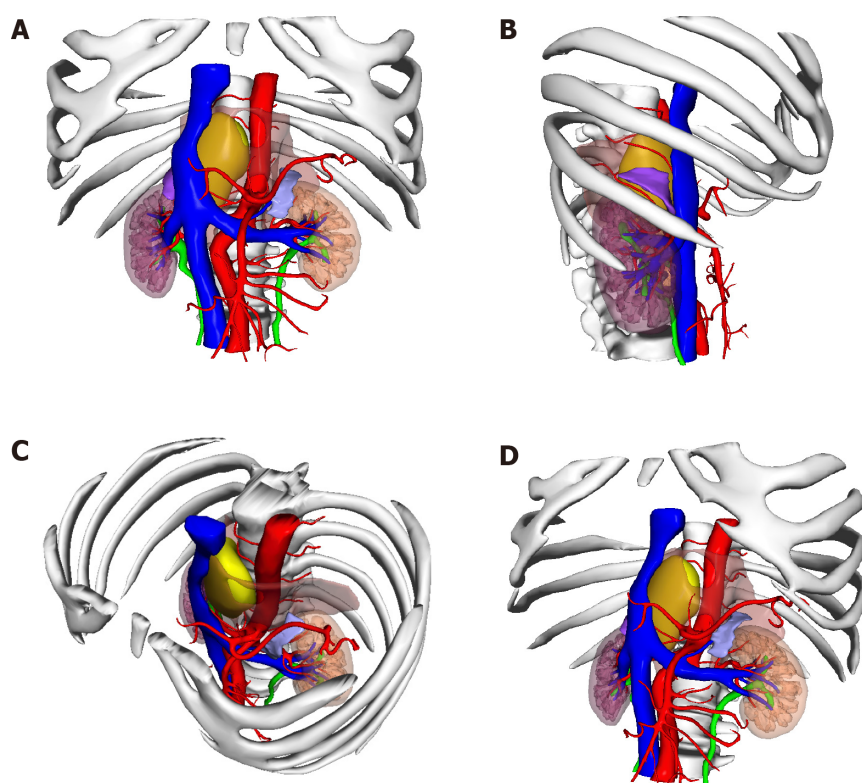


**Figure 1 Contrast-enhanced computed tomography + three-dimensional reconstruction of the abdomen and pelvis.** A: Contrast-enhanced computed tomography; B: Three-dimensional reconstruction. At the T10-L1 level of the posterior mediastinal spine on the right anterior side (posterior space of the right phrenic foot), there is an elliptical mixed density shadow, with smooth borders, and the size is about 3.3 cm × 6.9 cm × 8.4 cm.

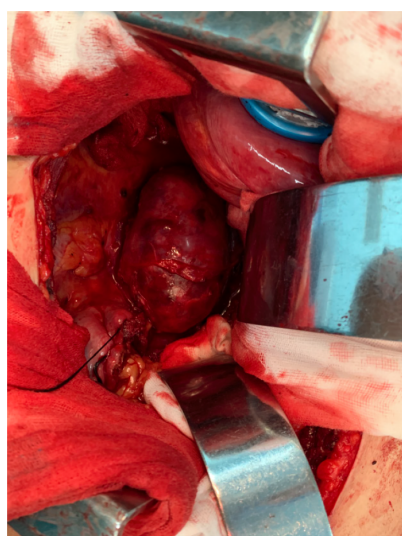


**Figure 2 Somatostatin receptor imaging.** A: Contrast agent imaging; B: Computed tomography; C: Fusion imaging of A and B. At the T10-L1 vertebral level on the right side of the abdominal aorta and behind the inferior vena cava, there is a cystic solid space, measuring 7.3 cm × 3.6 cm × 9.4 cm in size, with increased radioactive uptake.

inner diaphragm was fixed to the posterior mediastinal pleura and intercostal muscles with 1-0 braided thread to reconstruct the diaphragm foot. The ninth rib was fixed end to end to completely close the diaphragm and isolate the thoracic and abdominal cavities. The thoracic cavity and abdominal cavity were drained, and the incision was closed layer by layer. The entire operation time was 310 min, and the blood loss during the operation was about 1100 mL. The patient recovered well after the operation without any serious complications and was discharged 10 d after the operation.



**Figure 3** The position of the tumor shown in 3-dimensional printing. A: Front view; B: Right side view; C: Diagonally above view; D: Diagonally below view. Yellow: Tumor; Orange: Muscle; Blue: Vein; Red: Artery.

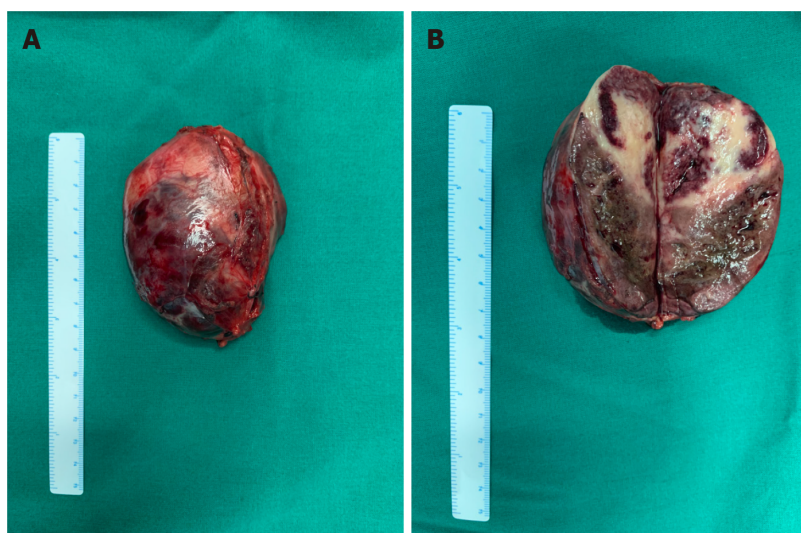

**Figure 4** Surgical procedure. After opening the abdomen, a large retroperitoneal tumor can be seen surrounded by the psoas muscle, with abundant blood supply on the surface.

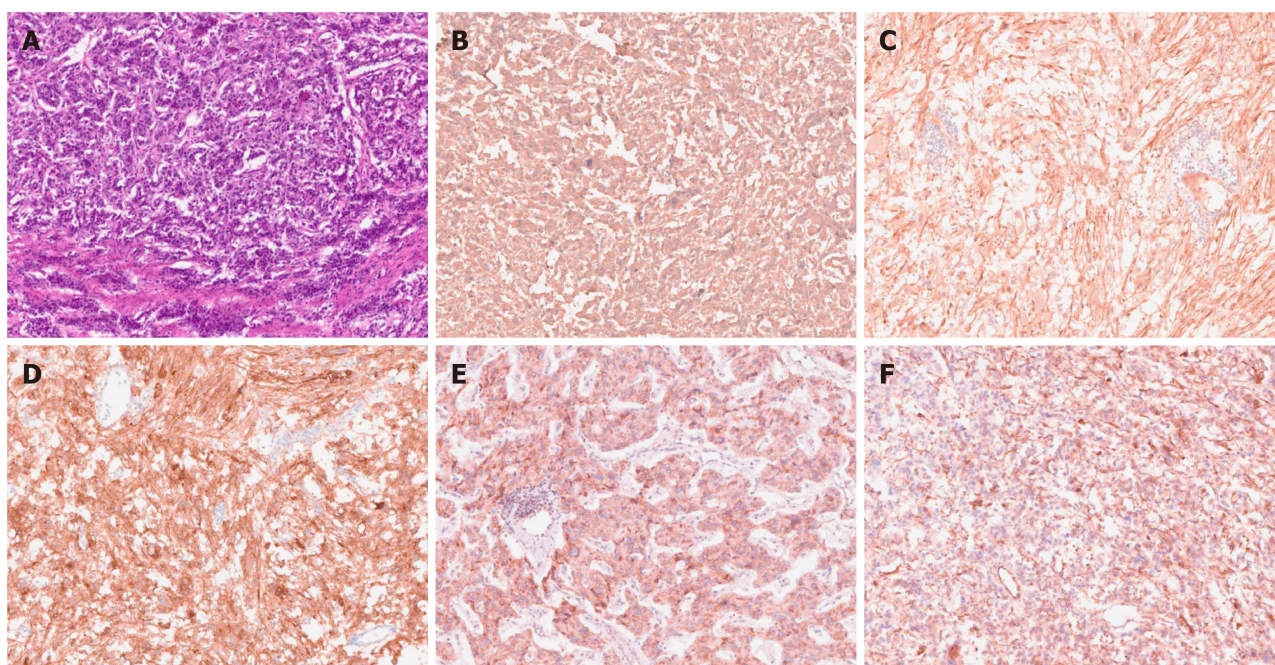
## OUTCOME AND FOLLOW-UP

The postoperative pathological diagnosis was compound paraganglioma (paraganglioma, ganglion cell neurofibroma, and a few ganglion cell neuroblastoma components). Immunohistochemical results were as follows: Melanoma antigen (-), cytokeratin [CK (AE1/AE3)] (-), chromogranin A (+), antigen Ki-67 (index 1%), soluble protein-100 (+),  $\alpha$ -inhibin (-), synaptophysin (+), succinate dehydrogenase B (+), neuron-specific nuclear protein (-), SOX gene family member 10 (-), neuron specific enolase (+), and nuclear factor (-) (Figure 6).





**Figure 5 Specimen of a large tumor.** A: Tumor with intact envelope; B: Tumor after incision.



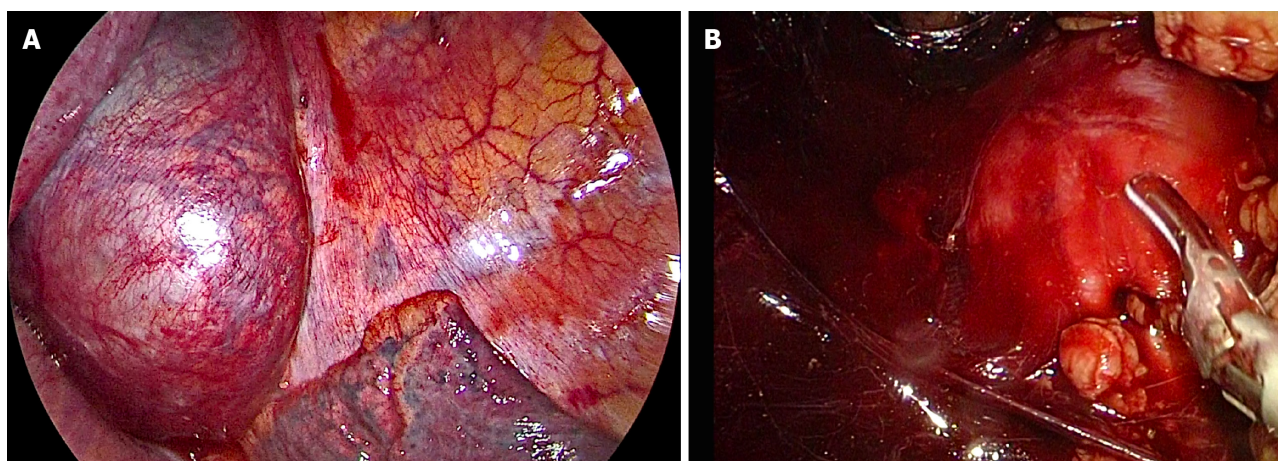
**Figure 6 Pathological photos.** Histological examination: A: HE staining; Immunohistochemistry: B: Chromogranin A (+); C: Soluble protein-100 (+); D: Synaptophysin (+); E: Succinate dehydrogenase B (+); F: Neuron specific enolase (+).

The patient was followed for 6 mo after the operation, and his general condition was good, his blood pressure returned to normal, there were no complications, and his normal life had been restored.

## DISCUSSION

This unique case presented multiple challenges to surgical treatment. PGL most commonly occurs in the sympathetic or parasympathetic nerve chain, and only 10% of these tumors occur in the retroperitoneum. The postoperative pathological diagnosis of this patient was a compound PGL, including PGL and ganglion cells neurofibromatosis, and a few ganglion cell neuroblastoma components were seen. This kind of mixed PGL is extremely rare. No relevant reports were found by reviewing the literature. This is the first reported case of a large mixed PGL in the posterior space of the right diaphragm that is wrapped by the psoas muscle. This patient with PGL had





**Figure 7** Corresponding images in the process of combined thoracic and laparoscopic detection of the mass. A: Thoracoscopic image; B: Laparoscopic image.

typical intermittent hypertension, the laboratory examination of blood and urine catecholamines showed elevated levels, and the somatostatin receptor imaging was positive; thus, it was not difficult to make a clear diagnosis of PGL.

Surgical resection is the first choice for the treatment of PGL, and laparoscopic resection is often suitable for smaller (< 7 cm) tumors[9,10]. In recent years, laparoscopic techniques have been used to successfully remove large retroperitoneal tumors one after another[11-13]. How to design the surgical plan was another great challenge in this case. The tumor grew on the right side of the abdominal aorta at the level of the T10-L1 vertebral body and was located behind the inferior vena cava. Compared with most PGLs, this tumor was located higher, with a maximum length of 10 cm, and it spanned the thoracic cavity and abdomen. The tumor could not be completely removed with a thoracoscope or laparoscope alone. It was close to the spinal nerves, large blood vessels, and liver, and the blood supply was extremely rich.

How to completely remove this large PGL without damaging the spinal nerves and causing paralysis, and avoiding massive bleeding is the focus of our surgery. By combining the successful experience of laparoscopic technology, our department innovatively designed the surgical method: Thoracoscopic and laparoscopic assisted resection of a right retroperitoneal PGL. According to a review of the literature, this is the first time that the thoracoscopic and laparoscopic techniques have been used simultaneously to remove large retroperitoneal tumors. After several case discussions between our department and thoracic surgeons, it was finally decided to adopt the left side decubitus position to obtain the most adequate operating space. During the operation, two sets of endoscopic instruments were used, and they were placed in two different directions. The thoracic surgeon and our surgeon stood, respectively, on the left and right sides of the patient to perform the operation. At the same time, the large tumor was explored and freed from the head and tail ends. With the diaphragm as the boundary in the middle, the two operating spaces were independent (Figure 7). During the operation, the inner side of the tumor was adherent closely to the adjacent parts of the vertebral body and inferior vena cava. It was seen that the blood supply of the tumor was very rich, and the surgical field showed more bleeding. Thus, the operation was converted to open surgery, and the diaphragm was cut longitudinally and gradually separated until the tumor was completely removed. Because the tumor is too large, in the peeling process thoracoscopy or laparoscopy cannot reveal the back of the tumor very well, if adhering to use this combination surgery method, it will greatly prolong the operation time, resulting in unnecessary large amounts of blood loss, so we consider that open surgery could have been safer, better, and lesser time consuming in such a vascular and adherent tumor, compared to the attempts to remove the tumor through thoracoscopic and laparoscopic approaches.

## CONCLUSION

In short, so far, this is the first reported case of a large compound PGL in the posterior space of the right phrenic foot and wrapped by the psoas muscle. It is also the first case

in which thoraco-laparoscopic combined exploration was used to remove the tumor. A clear diagnosis, a detailed surgical plan, adequate drug preparation, and satisfactory cooperation among multiple departments are necessary conditions for successful surgery. This case report may provide a new surgical approach for similar cases in the future.

## REFERENCES

- 1 **Silva I**, Santos MJ, Cardoso R, Carvalho S, Vilaça V, Vasconcelos M. Retroperitoneal Paraganglioma - a rare cause of arterial hypertension. *Galicla Clin* 2017; **78**: 38-41 [DOI: [10.22546/43/1026](https://doi.org/10.22546/43/1026)]
- 2 **Pappachan JM**, Tun NN, Arunagirinathan G, Sodi R, Hanna FWF. Pheochromocytomas and Hypertension. *Curr Hypertens Rep* 2018; **20**: 3 [PMID: [29356966](https://pubmed.ncbi.nlm.nih.gov/29356966/) DOI: [10.1007/s11906-018-0804-z](https://doi.org/10.1007/s11906-018-0804-z)]
- 3 **Lam AK**. Update on Adrenal Tumours in 2017 World Health Organization (WHO) of Endocrine Tumours. *Endocr Pathol* 2017; **28**: 213-227 [PMID: [28477311](https://pubmed.ncbi.nlm.nih.gov/28477311/) DOI: [10.1007/s12022-017-9484-5](https://doi.org/10.1007/s12022-017-9484-5)]
- 4 **Erickson D**, Kudva YC, Ebersold MJ, Thompson GB, Grant CS, van Heerden JA, Young WF Jr. Benign paragangliomas: clinical presentation and treatment outcomes in 236 patients. *J Clin Endocrinol Metab* 2001; **86**: 5210-5216 [PMID: [11701678](https://pubmed.ncbi.nlm.nih.gov/11701678/) DOI: [10.1210/jcem.86.11.8034](https://doi.org/10.1210/jcem.86.11.8034)]
- 5 **Vikas V**, Ahmed Z, Singh O, Pal SS, Songra MC. Primary Retroperitoneal Inter-aorto-Caval Paraganglioma of the Organ of Zuckerkandl. *J Clin Diagn Res* 2014; **8**: ND06-ND07 [PMID: [25177602](https://pubmed.ncbi.nlm.nih.gov/25177602/) DOI: [10.7860/JCDR/2014/6773.4619](https://doi.org/10.7860/JCDR/2014/6773.4619)]
- 6 **Purnell S**, Sidana A, Maruf M, Grant C, Agarwal PK. Genitourinary paraganglioma: Demographic, pathologic, and clinical characteristics in the surveillance, epidemiology, and end results database (2000-2012). *Urol Oncol* 2017; **35**: 457.e9-457.e14 [PMID: [28325651](https://pubmed.ncbi.nlm.nih.gov/28325651/) DOI: [10.1016/j.urolonc.2017.02.006](https://doi.org/10.1016/j.urolonc.2017.02.006)]
- 7 **Abe T**, Sazawa A, Harabayashi T, Oishi Y, Miyajima N, Tsuchiya K, Maruyama S, Okada H, Shinohara N. Laparoscopic resection of paraaortic/paracaval neurogenic tumors: surgical outcomes and technical tips. *Surg Endosc* 2016; **30**: 4640-4645 [PMID: [26715023](https://pubmed.ncbi.nlm.nih.gov/26715023/) DOI: [10.1007/s00464-015-4740-6](https://doi.org/10.1007/s00464-015-4740-6)]
- 8 **Ping W**, HongZhou M, Jie Q, TaiLe J, Hao P, Dan X, Jun C, Shuo W. Laparoscopic Resection of Retroperitoneal Paragangliomas: A Comparison with Conventional Open Surgical Procedures. *J Endourol* 2016; **30**: 69-74 [PMID: [26218171](https://pubmed.ncbi.nlm.nih.gov/26218171/) DOI: [10.1089/end.2015.0399](https://doi.org/10.1089/end.2015.0399)]
- 9 **Barfield R**, Hill DA, Hoffer FA, Tekautz T, Spunt SL. Retroperitoneal paraganglioma. *Med Pediatr Oncol* 2002; **39**: 120-124 [PMID: [12116060](https://pubmed.ncbi.nlm.nih.gov/12116060/) DOI: [10.1002/mpo.10099](https://doi.org/10.1002/mpo.10099)]
- 10 **Edström Elder E**, Hjelm Skog AL, Höög A, Hamberger B. The management of benign and malignant pheochromocytoma and abdominal paraganglioma. *Eur J Surg Oncol* 2003; **29**: 278-283 [PMID: [12657240](https://pubmed.ncbi.nlm.nih.gov/12657240/) DOI: [10.1053/ejso.2002.1413](https://doi.org/10.1053/ejso.2002.1413)]
- 11 **Radfar MH**, Shakiba B, Afyouni A, Hoshyar H. Laparoscopic management of paraganglioma in a pregnant woman: a case report. *Int Braz J Urol* 2018; **44**: 1032-1035 [PMID: [29570256](https://pubmed.ncbi.nlm.nih.gov/29570256/) DOI: [10.1590/S1677-5538.IBJU.2017.0698](https://doi.org/10.1590/S1677-5538.IBJU.2017.0698)]
- 12 **Ren X**, Shang J, Ren R, Zhang H, Yao X. Laparoscopic resection of a large clinically silent paraganglioma at the organ of Zuckerkandl: a rare case report and review of the literature. *BMC Urol* 2020; **20**: 156 [PMID: [33028271](https://pubmed.ncbi.nlm.nih.gov/33028271/) DOI: [10.1186/s12894-020-00732-0](https://doi.org/10.1186/s12894-020-00732-0)]
- 13 **Chung HS**, Kim MS, Yu HS, Hwang EC, Kim SO, Oh KJ, Jung SI, Kang TW, Park K, Kwon DD. Laparoscopic adrenalectomy using the lateral retroperitoneal approach: Is it a safe and feasible treatment option for pheochromocytomas larger than 6 cm? *Int J Urol* 2018; **25**: 414-419 [PMID: [29478297](https://pubmed.ncbi.nlm.nih.gov/29478297/) DOI: [10.1111/iju.13524](https://doi.org/10.1111/iju.13524)]





Published by **Baishideng Publishing Group Inc**  
7041 Koll Center Parkway, Suite 160, Pleasanton, CA 94566, USA

**Telephone:** +1-925-3991568

**E-mail:** [bpgoffice@wjgnet.com](mailto:bpgoffice@wjgnet.com)

**Help Desk:** <https://www.f6publishing.com/helpdesk>

<https://www.wjgnet.com>

