




国内版国际版

Microsoft Bing

Combined thoracoscopic and laparoscopic approach to remove a la



ALLIMAGESVIDEOS

39,100 ResultsAny time ▾

Thoracoscopic resection of functional thoracic paraganglioma
https://www.researchgate.net/publication/225555665_Thoracoscopic_resection_of...
We **report** a rare **case** of functional thoracic **paraganglioma**, which was successfully excised thoracoscopically. ... The **laparoscopic approach** is the procedure of choice for adrenalectomy except i...

Laparoscopic management of a large primary retroperitoneal ...
<https://www.researchgate.net/publication/226717480...>
Laparoscopic management of a **large** primary **retroperitoneal** hydatid cyst. ... We **report** the use of a **laparoscopic approach** for cysts located in the liver, lung, and retroperitoneum. ... We **report** a ...

"What Goes Up Must Come Down": Laparoscopic Retrieval of ...
<https://www.ncbi.nlm.nih.gov/pmc/articles/PMC6100698>
Aug 01, 2018 · Before surgery, advice from cardiothoracic surgeons was sought to identify the most suitable **laparoscopic approach** (intra-abdominal vs **thoracoscopic**). Due to difficulty in identifying re...
Author: Nisha Pindoria, Jonathan Makanjuola,... **Publish Year:** 2018

Thoracoscopic Removal of Intrathoracic Neurogenic Tumors ...
<https://www.researchgate.net/publication/12414937...>
The use of a **thoracoscopic approach** for resection of posterior mediastinal tumors was first reported by Landreneau et al. (10) in 1992, and use of this technique has since been growing in ...

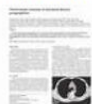(PDF) Combined Cervical and Video-assisted Thoracoscopic ...

ALL IMAGES VIDEOS

41,000 Results

Any time ▼

[Thoracoscopic resection of functional thoracic paraganglioma](https://www.researchgate.net/publication/225555665...)

<https://www.researchgate.net/publication/225555665...>

We **report** a rare **case** of functional thoracic **paraganglioma**, which was successfully excised thoracoscopically. ... The **laparoscopic approach** is the procedure of choice for adrenalectomy except in ...

[\(PDF\) Combined Cervical and Video-assisted Thoracoscopic ...](https://www.researchgate.net/publication/51661910...)

<https://www.researchgate.net/publication/51661910...>

As an alternative to conventional sternotomy, we herein describe a **combined** anterior **thoracoscopic** and transcervical **approach** to **large** mediastinal thyroid goiters.

[Laparoscopic management of a large primary retroperitoneal ...](https://www.researchgate.net/publication/226717480...)

<https://www.researchgate.net/publication/226717480...>

Laparoscopic management of a **large** primary **retroperitoneal** hydatid cyst. ... We **report** the use of a **laparoscopic approach** for cysts located in the liver, lung, and retroperitoneum. ... We **report** a ...

["What Goes Up Must Come Down": Laparoscopic Retrieval of a ...](https://www.ncbi.nlm.nih.gov/pmc/articles/PMC6100698)

<https://www.ncbi.nlm.nih.gov/pmc/articles/PMC6100698>

Aug 01, 2018 · Before surgery, advice from cardiothoracic surgeons was sought to identify the most suitable **laparoscopic approach** (intra-abdominal vs **thoracoscopic**). Due to difficulty in identifying renal...

Author: Nisha Pindoria, Jonathan Makanjuola, ... **Publish Year:** 2018

[Laparoscopic Excision of a Retroperitoneal Hydatid Cyst](#)

国内版 国际版

Combined thoracoscopic and laparoscopic approach to remove a la



ALL IMAGES VIDEOS

41,300 Results

Any time ▾

[“What Goes Up Must Come Down”: Laparoscopic Retrieval of a ...](#)

<https://www.ncbi.nlm.nih.gov/pmc/articles/PMC6100698>

Aug 01, 2018 · Before surgery, advice from [cardiothoracic](#) surgeons was sought to identify the most suitable **laparoscopic approach** (intra-abdominal vs **thoracoscopic**). Due to difficulty in identifying renal...

Author: Nisha Pindoria, Jonathan Makanjuola, ... **Publish Year:** 2018

[Laparoscopic Excision of a Paraganglioma Located in the ...](#)

<https://benthamopen.com/FULLTEXT/TOUNJ-1-40> ▾

Laparoscopic resection of periaortic paragangliomas Am Surg 2005; 71: 450-5.]. Here we **report** the case of a 60-year-old woman with a solitary kidney who was accidentally found to have a **paraganglioma**...

Author: Eugene Lin, Ho Lin, Mao-Sheng Lin, Jun... **Publish Year:** 2008

[Guidelines for the Minimally Invasive Treatment of Adrenal ...](#)

<https://www.sages.org/publications/guidelines/...> ▾

The guidelines for the minimally invasive surgical treatment of adrenal pathology are a series of systematically developed statements to educate and guide the surgeon (and patient) in the appropriate...

Estimated Reading Time: 7 mins

[Paraganglioma in the posterior mediastinum: a case report ...](#)

<https://bmccardiovascdisord.biomedcentral.com/...> ▾

Nov 23, 2020 · Paragangliomas are tumors that arise from extra-adrenal chromaffin cells. Herein, we present a rare **case** of a functional **paraganglioma** in the posterior mediastinum. A 36-year-old man...

Author: Jong-Ho Nam, Jong-Seon Park, Joon H... **Publish Year:** 2020

[Surgical resection for pelvic retroperitoneal Castleman's ...](#)

<https://www.spandidos-publications.com/10.3892/br.2021.1405> ▾

Castleman's disease (CD) is a rare atypical lymphoproliferation disorder first reported in 1954. Clinically, CD is classified as unicentric or multicentric CD based on anatomical distribution. Unicentric CD primaril...

Author: Masatoshi Kitakaze, Norikatsu Miyoshi,... **Publish Year:** 2021

[Retroperitoneoscopic resection of a T11-L2 right-sided ...](#)

<https://www.sciencedirect.com/science/article/pii/S0022346819301952>

Aug 01, 2019 · Fig. 1. Magnetic resonance imaging scan of right-sided paraspinal mass. The patient was