

World Journal of *Gastroenterology*

World J Gastroenterol 2022 April 14; 28(14): 1384-1502



Contents

Weekly Volume 28 Number 14 April 14, 2022

EDITORIAL

- 1384** Hepatocellular adenoma: Where are we now?
Wang X, Zhang X

OPINION REVIEW

- 1394** Endoluminal vacuum-assisted therapy to treat rectal anastomotic leakage: A critical analysis
Vignali A, De Nardi P

REVIEW

- 1405** Viral hepatitis: Past, present, and future
Odenwald MA, Paul S
- 1430** Osteosarcopenia in autoimmune cholestatic liver diseases: Causes, management, and challenges
Pugliese N, Arcari I, Aghemo A, Lania AG, Lleo A, Mazzotti G

ORIGINAL ARTICLE

Basic Study

- 1444** Syngeneic implantation of mouse hepatic progenitor cell-derived three-dimensional liver tissue with dense collagen fibrils
Tamai M, Adachi E, Kawase M, Tagawa YI

Retrospective Cohort Study

- 1455** Clinical classification of symptomatic heterotopic pancreas of the stomach and duodenum: A case series and systematic literature review
LeCompte MT, Mason B, Robbins KJ, Yano M, Chatterjee D, Fields RC, Strasberg SM, Hawkins WG

Retrospective Study

- 1479** Radiomics signature: A potential biomarker for β -arrestin1 phosphorylation prediction in hepatocellular carcinoma
Che F, Xu Q, Li Q, Huang ZX, Yang CW, Wang LY, Wei Y, Shi YJ, Song B

LETTER TO THE EDITOR

- 1494** Comment on review article: Chronic hepatitis C virus infection cascade of care in pediatric patients
Bouare N, Keita M, Delwaide J
- 1499** Comments on "Effect of type 2 diabetes mellitus in the prognosis of acute-on-chronic liver failure patients in China"
Wang W, Pan CC, Zhao WY, Sheng JY, Wu QQ, Chen SS

ABOUT COVER

Editorial Board Member of *World Journal of Gastroenterology*, Sung-Chul Lim, MD, PhD, Professor, Head, Department of Pathology, Chosun University Hospital, 365 Pilmun-daero, Dong-gu, Gwangju 61453, South Korea. sclim@chosun.ac.kr

AIMS AND SCOPE

The primary aim of *World Journal of Gastroenterology* (WJG, *World J Gastroenterol*) is to provide scholars and readers from various fields of gastroenterology and hepatology with a platform to publish high-quality basic and clinical research articles and communicate their research findings online. WJG mainly publishes articles reporting research results and findings obtained in the field of gastroenterology and hepatology and covering a wide range of topics including gastroenterology, hepatology, gastrointestinal endoscopy, gastrointestinal surgery, gastrointestinal oncology, and pediatric gastroenterology.

INDEXING/ABSTRACTING

The WJG is now indexed in Current Contents®/Clinical Medicine, Science Citation Index Expanded (also known as SciSearch®), Journal Citation Reports®, Index Medicus, MEDLINE, PubMed, PubMed Central, and Scopus. The 2021 edition of Journal Citation Report® cites the 2020 impact factor (IF) for WJG as 5.742; Journal Citation Indicator: 0.79; IF without journal self cites: 5.590; 5-year IF: 5.044; Ranking: 28 among 92 journals in gastroenterology and hepatology; and Quartile category: Q2. The WJG's CiteScore for 2020 is 6.9 and Scopus CiteScore rank 2020: Gastroenterology is 19/136.

RESPONSIBLE EDITORS FOR THIS ISSUE

Production Editor: Hua-Ge Yin, Production Department Director: Xu Guo, Editorial Office Director: Ze-Mao Gong.

NAME OF JOURNAL

World Journal of Gastroenterology

ISSN

ISSN 1007-9327 (print) ISSN 2219-2840 (online)

LAUNCH DATE

October 1, 1995

FREQUENCY

Weekly

EDITORS-IN-CHIEF

Andrzej S Tarnawski

EDITORIAL BOARD MEMBERS

<http://www.wjgnet.com/1007-9327/editorialboard.htm>

PUBLICATION DATE

April 14, 2022

COPYRIGHT

© 2022 Baishideng Publishing Group Inc

INSTRUCTIONS TO AUTHORS

<https://www.wjgnet.com/bpg/gerinfo/204>

GUIDELINES FOR ETHICS DOCUMENTS

<https://www.wjgnet.com/bpg/GerInfo/287>

GUIDELINES FOR NON-NATIVE SPEAKERS OF ENGLISH

<https://www.wjgnet.com/bpg/gerinfo/240>

PUBLICATION ETHICS

<https://www.wjgnet.com/bpg/GerInfo/288>

PUBLICATION MISCONDUCT

<https://www.wjgnet.com/bpg/gerinfo/208>

ARTICLE PROCESSING CHARGE

<https://www.wjgnet.com/bpg/gerinfo/242>

STEPS FOR SUBMITTING MANUSCRIPTS

<https://www.wjgnet.com/bpg/GerInfo/239>

ONLINE SUBMISSION

<https://www.f6publishing.com>



Endoluminal vacuum-assisted therapy to treat rectal anastomotic leakage: A critical analysis

Andrea Vignali, Paola De Nardi

Specialty type: Gastroenterology and hepatology

Provenance and peer review:

Invited article; Externally peer reviewed.

Peer-review model: Single blind

Peer-review report's scientific quality classification

Grade A (Excellent): 0
Grade B (Very good): 0
Grade C (Good): C
Grade D (Fair): 0
Grade E (Poor): 0

P-Reviewer: Bencurik V, Czech Republic

Received: May 10, 2021

Peer-review started: May 10, 2021

First decision: June 23, 2021

Revised: July 7, 2021

Accepted: March 4, 2022

Article in press: March 4, 2022

Published online: April 14, 2022



Andrea Vignali, Paola De Nardi, Department of Gastrointestinal Surgery, IRCCS San Raffaele Scientific Institute, Milano 20132, Italy

Andrea Vignali, Department of Surgery, Vita-Salute University, Milano 20132, Italy

Corresponding author: Paola De Nardi, FASCRS, MD, Staff Physician, Surgeon, Department of Gastrointestinal Surgery, IRCCS San Raffaele Scientific Institute, via Olgettina 60, Milano 20132, Italy. denardi.paola@hsr.it

Abstract

Endoluminal vacuum-assisted therapy (EVT) has been introduced recently to treat colorectal anastomotic leaks in clinically stable non-peritonitic patients. Its application has been mainly reserved to low colorectal and colo-anal anastomoses. The main advantage of this new procedure is to ensure continuous drainage of the abscess cavity, to promote and to accelerate the formation of granulation tissue resulting in a reduction of the abscess cavity. The reported results are promising allowing a higher preservation of the anastomosis when compared to conventional treatments that include trans-anastomotic tube placement, percutaneous drainage, endoscopic clipping of the anastomotic defect or stent placement. Nevertheless, despite this procedure is gaining acceptance among the surgical community, indications, inclusion criteria and definitions of success are not yet standardized and extremely heterogeneous, making it difficult to reach definitive conclusions and to ascertain which are the real benefits of this new procedure. Moreover, long-term and functional results are poorly reported. The present review is focused on critically analyzing the theoretical benefits and risks of the procedure, short- and long-term functional results and future direction in the application of EVT.

Key Words: Anastomotic leakage; Rectal surgery; Endoluminal vacuum therapy; Endosponge; Complications

©The Author(s) 2022. Published by Baishideng Publishing Group Inc. All rights reserved.

Core Tip: Endoluminal vacuum therapy for the treatment of rectal anastomotic leakage, in clinically stable patients, has been reported to be promising, in term of high rate of anastomotic salvage and length of hospital stay. Nevertheless, inclusion criteria, definition of success and complications, are heterogeneous. Moreover, long-term anorectal function is poorly reported. This opinion review aims at clarify, through a critical analysis, all the raised points to stimulate the surgical community to a more standardized approach and algorithm of treatment, and to further study the long-term consequences of this technique.

Citation: Vignali A, De Nardi P. Endoluminal vacuum-assisted therapy to treat rectal anastomotic leakage: A critical analysis. *World J Gastroenterol* 2022; 28(14): 1394-1404

URL: <https://www.wjgnet.com/1007-9327/full/v28/i14/1394.htm>

DOI: <https://dx.doi.org/10.3748/wjg.v28.i14.1394>

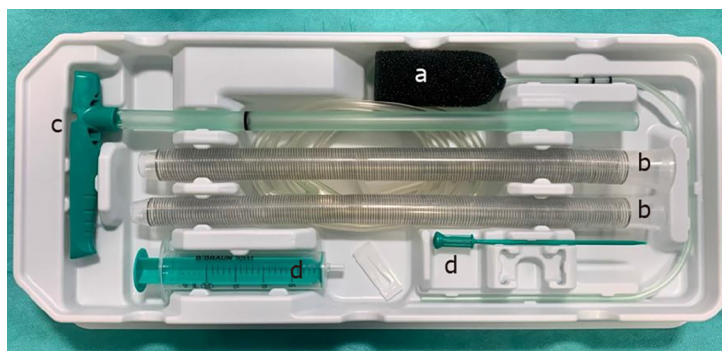
INTRODUCTION

Anastomotic leak (AL) still represents the most dreaded complication following colorectal resection due to its consequences that could severely affect functional and oncological outcome[1,2]. The gravity of the phenomenon is amplified when rectal cancer only is considered, with reported leakage rate ranging from 3% to 19%[3] and a mortality rate varying from 1.7% to 16.4%[4]. The choice of the treatment is strictly influenced by the patient general condition and by the dimension of the anastomotic defect[5]. In 2007, the international rectal cancer study group, which includes expert colorectal surgeons and interventional radiologists from several regions in the world, proposed a standardized algorithm for treating ALs. Treatment options varies according to the location of the anastomosis, dimension of the abscess, and patient's clinical conditions[6]. In patients in whom a diffuse peritonitis has occurred, a laparotomy and takedown of the anastomosis is the suggested surgical treatment. More conservative treatments including the salvage of the anastomosis could be an option in patients who remain clinically stable or in presence of a small defect. Different options have been reported including trans-anastomotic tube drainage, percutaneous drainage of the peri-anastomotic abscess in association with fecal diversion, if not fashioned at primary operation, placement of stent or endoscopic clipping of the defect [4,6]. Nevertheless, in presence of a large defect, even in a clinically stable patient, the healing process is extremely long, resulting in a delay of diverting stoma and devastating future function of the neorectum, in particular when an extra-peritoneal anastomosis is taken into consideration. In the early 2000s, an endoluminal vacuum-assisted therapy (EVT) was introduced to treat presacral anastomotic abscesses in stable, non-peritonitic patients[7]. The principle is based on the application of topic negative pressure in order to drain, to clean, to induce the collapse of the cavity, and to prevent the development of chronic sinus. Several case reports papers, reviews, and meta-analyses[7-20] have been published so far with promising results. Nevertheless, the majority of papers are heterogeneous both in term of success rate definition, salvage and long-term results, paucity of comparative studies and thus definitive conclusions are not warranted at present time. In particular, the majority of the studies were focused on success rate, healing time and stoma closure rates, while only few papers dealt with long-term anastomotic function and complications that play a pivotal role when the issue of the efficacy of a novel treatment is taken into consideration. In this narrative review, we aim to critically appraise the literature with regard to the results of the EVT in term of success rate and complications and to evaluate the long-term functional results of this novel treatment.

EVT DEVICE DESCRIPTION

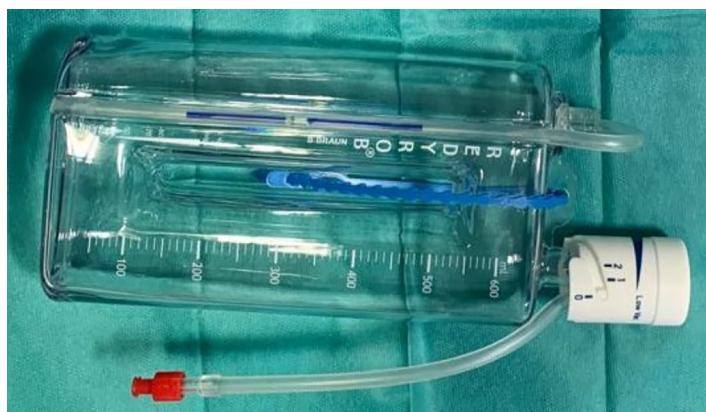The endoscopic vacuum device consists of an open-cell polyurethane sponge measuring 7 cm × 3 cm, which can be cut down until minimum size, depending on the size of the cavity. The sponge dressing is placed into the abscess cavity using a specially developed introducer system. The end of the evacuation probe is connected to a vacuum wound drainage system *via* a variable drain connector (Figure 1).

In the majority of available studies the evacuation probe was connected to a low vacuum suction bottle (Redyrob® Trans Plus bottle with variable vacuum) (Figure 2), creating a constant negative vacuum pressure of 125-150 mmHg[20]. Higher values were reported by Arezzo *et al*[15] who connected the tube to a vacuum system producing continuum negative pressure up to 700 mmHg when in hospital, and a portable system producing continuum negative pressure up to 200 mmHg when discharged.



DOI: 10.3748/wjg.v28.i14.1394 Copyright © The Author(s) 2022.

Figure 1 Endo-SPONGE® kit including open-pore sponge drain (a), two silicon overtubes (b), the sponge pusher (c), and the irrigation set (d).



DOI: 10.3748/wjg.v28.i14.1394 Copyright © The Author(s) 2022.

Figure 2 Redyrob® Trans Plus vacuum bottle: this device is meant to be used connected to the Endo-SPONGE drain.

INCLUSION CRITERIA

The main indication to the use of EVT was represented by the presence of an extraperitoneal leak confirmed by flexible endoscopy \pm computed tomography scan (CT) and on clinical and/or laboratory deterioration and drain secretion. Only patients in stable condition with no sign or only localized peritonitis were included. In the majority of patients, a leak following colorectal resection for cancer was considered. Table 1 reports the inclusion criteria of the available studies. The table shows up the lack of standardization in the inclusion criteria, some including both benign and malignant, some purely malignant or pure benign disease, to the different anastomotic heights, surgical approach, including both PME and TME, or in the different indications to EVT therapy, including Hartmann "stump insufficiency" or rectal perforation, as well as leaks following a proctectomy with a J-pouch ileoanal anastomosis. These data lead us to extreme caution in their interpretation, in the effort to make a critical analysis of the reported results. Moreover, a strong clinical heterogeneity has been reported with respect to initial cavity size ranging from 4.9 cm to 10 cm among the reported series[8-22]. Limitations to inclusion with respect to the initial cavity dimension have been reported only in one study[23].

Recently, it has been reported on the intraoperative use of indocyanine green (ICG) fluorescence from the luminal side *via* a trans-anal approach which enables to evaluate the whole circumference of anastomosis in the proximal and distal intestines[24]. Results showed that in patients in whom the vessels were not depicted by the ICG, a higher incidence of AL was observed. This finding is of relevance and it will be probably useful in selecting patients who will benefit of EVT *vs* patients in whom a more aggressive operative strategy is recommended. Possible future applications of this technique combined with endoscopy, will be the evaluation in patients with suspected leak, in order to confirm the presence of a leak and to evaluate local perfusion over the entire circumference of anastomosis in real time.

Table 1 Inclusion criteria among different studies

Ref.	# Patients	Anastomosis location	Inclusion criteria	Type of disease (n)	Neoadjuvant therapy (%)
Weidenhagen <i>et al</i> [7], 2008	29	Lower rectum; Middle rectum	Local peritonitis (20); General peritonitis (9)	Cancer of the rectum (22); Rectosigmoid cancer (3); Benign disease (4)	9 (40.9)
von Bernstorff <i>et al</i> [27], 2009	26	Lower rectum; Ileorectal	Local peritonitis	Cancer of the rectum + rectosigmoid	14 (54)
Riss <i>et al</i> [30], 2010	20	Lower rectum; Middle rectum	Not reported	Cancer of the rectum	6 (30)
van Koperen <i>et al</i> [8], 2009	16	Lower rectum; Ileo-anal	Not reported	Cancer (13); Ulcerative colitis (3)	9 (56)
Nerup <i>et al</i> [25], 2013	13	Lower rectum	Local peritonitis	Cancer	6 (46.1)
Mees <i>et al</i> [23], 2008	5	Lower rectum	Local peritonitis Abscess (> 3 cm × 3 cm, or < 10 cm × 10 cm)	Cancer of the rectum	No
Arezzo <i>et al</i> [15], 2015	14	Lower rectum	Local peritonitis	Cancer of the rectum (7); Other (1)	7 (50)
Strangio <i>et al</i> [11], 2015	25	Lower rectum (19); Middle rectum (5); Ileoanal (1)	Local peritonitis Anastomotic leak less than 270	Rectal cancer (18); Endometriosis (1); Left sided colon cancer (4); Diverticulitis (1); Ulcerative colitis (1)	18 (84)
Mussetto <i>et al</i> [31], 2017	11	Lower rectum(8); Middle (3)	Local peritonitis	Rectal cancer	5 (45)
Keskin <i>et al</i> [13], 2015	15	3 (20)	Local peritonitis	Rectal cancer (12); Other (3)	NR
Milito <i>et al</i> [16], 2017	14	Lower rectum	Local peritonitis	Cancer of the rectum	14 (100)
Srinivasamurthy <i>et al</i> [14], 2013	8	Lower rectum; Ileoanal	Not reported	Ulcerative colitis (1); Cancer of the rectum (8)	8 (100)
Abdalla <i>et al</i> [24], 2020	47	Middle (5); Lower (42)	Local peritonitis + asymptomatic leak	Cancer of the rectum (44); Other (3)	27 (57.4)
Kühn <i>et al</i> [28], 2021	281	Lower rectum; Ileoanal; Middle rectum	Local peritonitis extraperitoneal anastomotic leak; Rectal defect	Sigmoid or rectal cancer 183 (65); Other malignancies 50 (18); Diverticular disease 17 (6); Inflammatory bowel disease 12 (4); Perforation 8 (3); Benign/malignant diseases 11 (4)	84 (30)

EVT THERAPY RESULTS

EVT has been identified as a successful method in order to treat AL in clinically stable and non-peritonitic patients with reported figures ranging from 60% to 100% and a rate of diverting stoma closure ranging between 31% to 100%, as emerged by recently published systematic reviews on this issue[20,21]. The rate of success was significantly influenced by early therapy start (within 6 wk from onset) with summarized odds ratio of 3.48 as reported by Mahendran *et al* [18] in their review paper including 266 patients from 16 studies. Nevertheless, data extracted from the same paper underlined that an additional treatment was needed in 12.8% of patients, due to the persistence of the abscess cavity, including fibrin glue application, sutures under general anesthesia, clips placing over the scope or a combination of different techniques. Treatment duration, in current literature, varies between 11 and 244 d. Data are encouraging and promising showing that approximately 67% of the patients had their anastomosis saved with no need of abdominal surgery[9]. Moreover, in selected cases, the EVT treatment could be performed without the need of a diverting stoma[7]. These percentages favorably compares with results reported by Kühn *et al* [21] in the largest comparative study recently published including 21 patients treated with EVT *vs* 41 historical controls treated with conventional management. The authors reported a significant higher preservation of the intestinal continuity in the EVT *vs* conventional group (86.7% *vs* 37.5%; $P = 0.001$) and shorter duration of hospital stay. Similarly, Nagell and Holte[22], who compared 4 patients treated with EVT with 10 historical controls, reported favorable results in healing time and length of stay in the EVT group when compared to conventional treatment. Mees *et al* [23] also reported a significantly shorter time for closure and reduced length of stay in the EVT group.

DEFINITION OF SUCCESS

Another point of discussion is represented by a lack of a standardization in the definition of success of the EVT treatment. In particular, data from the two large series (CLEAN study and GRECCAR study) including 39 and 47 patients respectively, defined the success rate as the absence of extravasation of contrast during abdominal CT or the presence of an intact anastomosis on endoscopy[17,25]. Other authors identified the cavity size, associated or not with the presence of granulating healthy tissue, to define the success rate, with figures ranging from 0.5 cm to 3 cm with no consensus among authors[7,9, 26-28]. Kühn *et al*[28], in the largest monocentric series recently published, including both AL and rectal stump leak, defined success as granulating closure of the cavity, more than 90% clean and granulating tissue, decreasing wound secretion, reduction of fibrinous tissue, and no interventional or surgical procedure required in the further course.

FACTORS INFLUENCING SUCCESS

Different variables could potentially influence the success rate such as neoadjuvant therapy, presence of diverting stoma during the treatment, and length of follow-up[7-24]. von Bernstorff *et al*[27] first evaluated the effect of radiotherapy on the healing process following EVT therapy. The aforementioned author, and others later, reported a longer duration of therapy, more endoscopies, more sponge exchanges, and longer time to close the abscess cavity in patients who underwent neo-adjuvant treatment[7,15,27,29]. In contrast, others did not find any correlation of neo-adjuvant treatment on healing time and success rate[26,30]. A definitive answer to this topic has come from a subgroup analysis on the radiotherapy subject including eight studies, extrapolated from a meta-analysis, which reported a negative effect of radiotherapy on healing and success rate with a odds ratio of 0.56[20]. Similarly, Shalaby *et al*[9] in a cumulative analysis, encompassing more than 300 patients, identified preoperative radiotherapy ($P = 0.018$), development of complications ($P = 0.002$), male sex ($P = 0.014$) and absence of diverting stoma before treatment, as predictive factors for failure. This latter point deserves some consideration since, intuitively, the presence of a stoma plays a main role in the healing process, nevertheless, to the best of our knowledge, there is no paper or meta-analysis specifically addressing its role and future subgroup analyses will be advisable. In particular, to further clarify this issue, a detailed report of the stoma formation differentiating patients receiving a stoma at primary operation or after the leak was diagnosed will be mandatory, which actually is not fully available from the reported studies as recently stressed by Sharp *et al*[19] in their meta-analysis. Despite stoma reversal was considered by the majority of authors as a marker of success, concern has been expressed by some authors due to the complexity of this variable and to the fact that its closure could be influenced by different factors such as severe co-morbidity, insufficiency of the anal sphincter, chronic pre-sacral sinus, or local recurrence and malignancy[18,20].

Finally, with respect to the duration of follow-up, the latter is of pivotal importance since, as emerged by the multicenter study of Riss *et al*[30], more than 25% of the patients developed a recurrent abscess after a median follow-up of 17 mo. However, data extrapolated from the three recent meta-analyses published in the international literature, show that some of the included studies do not comprise follow-up data, or reported figures ranging within 1 and 4 mo, while less than 50% of the studies report a follow-up time longer than 12 mo, ranging between 14 and 41[18-20].

COMPLICATIONS

The overall EVT-related complication rate among the published series ranges from 0% to 34.5%, with a mean of 11.1% (96 per cent confidence interval 6.0 to 16.2) as recently reported by Shalaby *et al*[9]. However not all the available studies report on this variable. The complication issue has been recently analyzed and discussed in two systematic reviews on EVT for rectal anastomotic leakage, including 295 and 335 patients respectively[20,21]. According to the review of Nagell and Holte[22], the most common complication is represented by pelvic abscess accounting for 11.5% of cases. Shalaby *et al*[9] reached similar conclusions in another review paper. The majority of abscesses were managed with a conservative treatment or *via* repeated EVT with success rate of 71%-75%, while in case of failure Hartmann's or Miles operation were performed (Table 2). From a more accurate analysis it emerged that in 1% of cases, the abscess occurred early and it should be considered as a treatment failures, while in 10% they were recurrent and thus they should be considered as a relapse after a primary healing has occurred [20]. According to these findings, could we still consider them as a complication or it would be more appropriate to classify them as a treatment failure? The same question spontaneously arises for the fistula issue. According to data extracted from studies reporting complications, overall 13 cases of fistulas were reported, of which 7 in a single series (Table 3). The majority of them were managed with Hartmann's procedure. Of note, the high incidence of fistulas recently reported by Kühn *et al*[28] in their series including 281 patients. In the aforementioned paper, all the fistulas were recto-vaginal in their

Table 2 Reported complications and treatment among studies reporting complications

Ref.	# Patients	Overall complications <i>n</i> (%)	Type of complication	Treatment	Ileostomy closure %
Weidenhagen <i>et al</i> [7], 2008	29	10 (34.5)	10 anastomotic stenosis; 2 fistulas	Bougienage/balloon dilatation (<i>n</i> = 10); Hartmann procedure for persistent fistula (<i>n</i> = 1)	88
von Bernstorff <i>et al</i> [27], 2009	26	2 (7.7)	2 intra-abdominal fistulas	Hartmann procedures (<i>n</i> = 2)	NR
Riss <i>et al</i> [30], 2010	23	6 (23)	1 stenosis; 5 recurrent abscess	Dilatation for stenosis (<i>n</i> = 1); Hartmann's procedure (<i>n</i> = 3); CT-guided drainage (<i>n</i> = 1); No further action (<i>n</i> = 1)	76.5
van Koperen <i>et al</i> [8], 2009	16	4 (25)	2 abscesses; 1 bleeding; 1 severe pain; 1 anastomotic stenosis	Hartmann procedure for recurrent abscess (<i>n</i> = 2); 1 stopped treatment for pain; 1 dilatation for stenosis	55.6
Nerup <i>et al</i> [25], 2013	13	1 (7.7)	1 anastomotic stenosis	Permanent colostomy (<i>n</i> = 1)	91
Mees <i>et al</i> [23], 2008	5	1 (20)	1 anastomotic stenosis	Dilatation (<i>n</i> = 1)	20
Arezzo <i>et al</i> [15], 2015	14	1 (14)	1 peritonitis; 2 poor compliance	Fibrin glue injection	NR
Strangio <i>et al</i> [11], 2015	25	3 (12)	2 fistulas (1 ureteric, 1 ileal); 1 recurrent abscess	Surgery (<i>n</i> = 3)	84.6
Mussetto <i>et al</i> [31], 2017	11	2 (18)	2 anastomotic stricture	1 endoscopic dilatation; 1 stent placement	91
Keskin <i>et al</i> [13], 2015	15	3 (20)	2 pelvic sepsis; 1 bleeding	Treatment discontinued	71
Milito <i>et al</i> [16], 2017	14	5 (36)	Moderate pain	None	NR
Srinivasamurthy <i>et al</i> [14], 2013	8	1 (12)	Iatrogenic injury during sponge placement	End stoma	64
Abdalla <i>et al</i> [24], 2020	47	4 (8.5)	1 intractable pelvic pain; 3 anastomotic stenosis	Treatment discontinued (pain); Endoscopic dilatation	NR
Kühn <i>et al</i> [28], 2021	281	27 (10)	10 anastomotic stenosis; 7 rectovaginal fistulas; 4 bleeding	Endoscopic dilatation (<i>n</i> = 10); Surgery (<i>n</i> = 7); Endoscopic haemostasis (<i>n</i> = 3); Surgery for intractable beeldding (<i>n</i> = 1)	62

NR: Not reported.

nature, occurred in the early phase of EVT treatment, and the majority of the patients had initial surgery involving partial resection of the vagina or the uterus, suggesting that EVT might have either prompted or revealed a vaginal leak. In other series, fistulas were classified as abdominal, colovesical, ileal or ureteric, thus suggesting a progression of the leakage process and thus a failure of the treatment more than a complication[7,11,28].

Other complications of endoscopic vacuum treatment include anastomotic stenosis, with an estimated incidence of 4.4% in the cumulative analysis by Popivanov *et al* [20]. Widenhagen reported the occurrence of anastomotic stenosis in 33% of patients in a retrospective analysis of 29 cases. Stenoses were managed with bougienage or balloon dilatation[7]. In the series of Mussetto *et al* [31], including 11 patients, anastomotic stenosis accounted for 16%, while figures ranging from 6% to 11% were reported by others[26,32,33]. Nevertheless, the real incidence of the phenomenon is difficult to establish due to the limited follow-up period in a large percentage of the published studies. Moreover, anastomotic stenosis can also normally occur because of chronic inflammation related to the anastomotic leakage itself not as a direct consequence of EVT treatment, and thus considering purely as an EVT complication is questionable. Under this view, a comparative study with adequate follow-up period with patients who had received conventional treatment should be advisable to reach definitive conclusions.

The occurrence of moderate pain was a common complication in the series by Milito *et al* [16], accounting for 36% (5/14 patients), while intractable pain leading to a discontinuation of the EVT treatment been reported in two cases only[8,16,25]. The phenomenon is rare, 2%, for moderate pain and 0.4% for severe pain as emerged by data derived from the systematic review of Popivanov *et al* [20]. Other reported complications were bleeding from the cavity, which generally occurs in the act of changing the sponge. In the majority of cases, an endoscopic management has been successful, with only one case requiring conventional surgery. Migration of the sponge into the abdominal cavity has been also reported with an estimated overall incidence of 1% [20].

Table 3 Assessment of ano-rectal function after treatment of anastomotic leak with endoluminal vacuum-assisted therapy

Ref.	# Patients	# Patients with functional assessment	Follow-up time	Instrument to evaluate ano-rectal function	Results
Borstlap <i>et al</i> [17], 2018	30	15	6, 9, 12 mo	LARS score; COREFO	81% major LARS; 13% minor LARS
Huisman <i>et al</i> [36], 2019	20	13	2.6 (0.8-3.5) yr	LARS score	77% major LARS; 23% minor LARS
Katz <i>et al</i> [42], 2018	6	4	Not reported	None	Reasonable function
Srinivasamurthy <i>et al</i> [14], 2013	8	6	41 (10-45) mo	None	Good or reasonable function
Abdalla <i>et al</i> [24], 2020	47	17	14.8 ± 8.9 mo	LARS score	47.1% major LARS; 52.9% no or minor LARS
Rottoli <i>et al</i> [12], 2018	8 (pouch)	7	11.6 (6-18) mo	None	No feces or gas incontinence; BM: Daytime: 5 (3-8); Nighttime: 1.7 (1-4)
Weréén <i>et al</i> [43], 2020	14	6	5.9 (0.53-13) yr	LARS score	67% major LARS

LARS: Low anterior resection syndrome score; COREFO: Colorectal functional outcome; BM: Bowel movements.

CHRONIC SINUS AND ABSCESS RECURRENCE

One of the long-term sequelae of anastomotic failure is the development of chronic sinus. The true incidence is unknown, however, a large multicenter retrospective study on 1063 patients, reporting an incidence of 6.4% of anastomotic leakage after colorectal anastomosis or restorative proctocolectomy, 36% of whom developed a chronic sinus[34]. The occurrence of chronic sinus involves multiple interventions and a high risk of permanent stoma[35]. A proportion of chronic sinuses may heal spontaneously over time, nevertheless when sinus eventually resolves, it is associated with poor functional outcome[36]. The occurrence of chronic sinuses after AL treatment with EVT is poorly studied. Borstlap *et al*[17] reported a 34% rate after a 6 mo follow-up. Comparing patients who underwent early treatment (before 3 wk) *vs* late treatment (after 3 wk), they observed a higher rate (47%) in the latter group *vs* 21% in the former. Accordingly, the diverting ileostomy could be reversed in 60% of the patients in the late group as compared to 73% in the early group[37]. The authors argued that a late starting could lead to excessive fibrosis of the bowel thus hampering fistula closure.

Time for beginning EVT treatment was evaluated as prognostic factors by other authors with conflicting results. Huisman *et al*[36] reported that 3/20 patients (15%) experienced a chronic sinus, after a median follow-up of 10 mo, and all three received a permanent stoma because of the sinus. They grouped the patients according to start of EVT, before or after 20 d from surgery, but no significant difference between the early and late treatment groups were found.

Another important issue is recurrent leak after the anastomosis is healed. Riss *et al*[30] studied 20 patients treated by rectal resection for rectal cancer and by successful endoscopic EVT of AL (17 patients) or insufficiency of the rectal stump after Hartmann's procedure (3 patients). The patients received annual routine visits and colonoscopy. Five patients (25%) developed a recurrent pelvic abscess, three of them underwent surgery (Hartmann's procedure) and one to CT guided drainage; the treatment for the last patient was still under discussion at the time of publication. Interestingly, the authors did not identify any demographic, therapeutic, or temporal related significant factors that could predict the occurrence of late leak recurrence. The authors concluded that a surveillance of at least 2 years would be recommended for early identification and treatment of this problem. Actually, treatment of chronic sinus is challenging, since its presence precludes the closure of the ileostomy or dictates other surgical treatments such as Hartmann's procedure with closure of the ileostomy, and creation of a permanent colostomy, in the majority of the patients[7,28]. Jagielski *et al*[37] reported a different experience. They treated two patients, with recurrent abscess and anastomotic fistula, once more with EVT. The treatment duration was 15 d with four endosponge changes; they obtained fistula healing without need of major surgery. The authors also underlined that the endoscopic treatment could be interrupted as far as the cavity reached 30 mm with granulation tissue on the wall, without waiting for complete healing; this approach allowed faster endoluminal treatment with no impact on recovery.

In conclusion, despite endoscopic vacuum-assisted treatment allows successful treatment of AL, persistent sinus or recurrent fistula and abscess may occur. A constant follow-up is advisable for early diagnosis and care. Therapy often entails surgical treatment; however, a conservative treatment might also be attempted in selected cases.

FUNCTIONAL RESULTS

After restorative anterior rectal resection, bowel function could be impaired, which adversely affects quality of life. Low anterior resection syndrome (LARS), including incontinence, urgency, diarrhea, frequency and clustering of bowel motions, is being increasingly recognized[38]. The scores are categorized into three groups: 1- no LARS (0-20 points), 2- minor LARS (21-30 points) or 3- major LARS (31-42 points). Although an altered function could be present, in patients with rectal cancer, before any treatment, radiotherapy and surgery represent detrimental factors since they can affect both internal and external anal sphincter function as well as rectal compliance and sensory thresholds[39]. Recently a patient-reported outcome measure on bowel related quality of life showed that 85% of patients had some degree of impairment up to 5 years after surgery. Moreover the degree of quality of life impairment increased as the LARS and Wexner fecal incontinence scores increased, indicating that severity of quality of life impairment reflects severity of bowel dysfunction[40]. Bowel function can improve up to 18 mo after surgery or stoma reversal, however, after that time, further recovery is unlikely. A recent systematic review on 11 studies on rectal cancer patients who underwent low anterior rectal resection and completed a LARS score, with a mean or median follow-up of at least 18 mo, found a prevalence of major LARS of 41%, ranging between 18% to 56%. Radiotherapy and tumor height were the most significant factors for LARS development; AL, diverting ileostomy, and having a stoma for prolonged period, were also associated with increased risk of developing major LARS[41].

Articles on the EVT treatment of rectal AL mainly focus on leak resolution and preservation/restoration of the intestinal continuity. Very few assess long-term functional results, and the majority of them did not employ validated score systems or systematic search of the functional outcomes. Two small series observed "reasonable function", both in 5 patients who underwent stoma closure, after a mean follow-up of 28 and 41 mo respectively[14,42]. However, no score was used to grade bowel function. In another study, of the seven patients who had the ileostomy reversed, none reported incontinence to feces or gas after 11.6 mean follow-up, though it is not described if these symptoms were systematically explored[12].

Intestinal function was evaluated with the LARS questionnaires by few authors. Abdalla *et al*[24] studied 17 patients (out of 26 who had successful EVT treatment) after 14 mo on average following stoma reversal or AL healing, and reported 47.1% with major LARS.

The more complete assessment of postoperative function and related quality of life was performed by Borstlap *et al*[17]. The authors evaluated the LARS score, the colorectal functional outcome (COREFO) scale, the short form 36 (SF-36), the gastrointestinal quality of life index (GIQLI) questionnaire and the EQ-5D-5L at fixed time points. Eighty-one per cent of the patients experienced major LARS, 13% minor-LARS and only 6% did not report any functional problem. Analysis of the COREFO showed that function did not improve from 6 mo to 12 mo postoperatively. On the other hand improvement of the EQ-5D-5 L, GIQLI and SF-36 scores was noted during follow-up.

Only one study compared functional outcome in patients with AL treated with EVT with a group of patients without AL, after rectal resection[37]. A worse LARS score was found in the EVT group (37, range 23-42 points) with respect to the control group (30, range 4-41) points ($P = 0.009$), with 77% of patients reporting major LARS in the EVT group as compared with 48% in the control group. This study supports the impairment of long-term anorectal function caused by anastomotic dehiscence, possibly due to fibrosis and reduced rectal compliance. However, the question whether EVT treatment could improve functional results in patients with AL remain unanswered.

CONCLUSION

Our narrative review shows, with all the limitations related to the nature of the available studies from international literature, that EVT represents, in clinically stable non-peritonitic patients, a valid alternative to conservative approach (diverting stoma, drain) with relatively low percentage of complications, higher rate of stoma closure, and shorter length of hospital stay. Some questions currently remain unanswered, in particular with respect to quality of life and functional results following EVT treatment. Moreover, it seems to us extremely difficult to identify patients who will benefit most of these new treatment, due to strong heterogeneous inclusion criteria, different materials and treatment algorithms.

Objectively a randomized trial would be advisable to assess the real efficacy of a new therapy, nevertheless due to ethical considerations and to the "fragile" status of these patients, may prove difficult to perform. A possible alternative could be represented by a well-designed multicenter control study with standardized inclusion criteria, standardized definition of success, and adequate follow-up period and control group. These latter two points, in our opinion, are of pivotal importance in order to give a definitive answer on the diverting stoma closure issue, which identification as a marker of success, due to its complexity, should be re-considered.

FOOTNOTES

Author contributions: Vignali A conceived the idea for the manuscript; Vignali A and De Nardi P reviewed the literature and drafted the manuscript.

Conflict-of-interest statement: The authors declare no conflict of interests.

Open-Access: This article is an open-access article that was selected by an in-house editor and fully peer-reviewed by external reviewers. It is distributed in accordance with the Creative Commons Attribution NonCommercial (CC BY-NC 4.0) license, which permits others to distribute, remix, adapt, build upon this work non-commercially, and license their derivative works on different terms, provided the original work is properly cited and the use is non-commercial. See: <https://creativecommons.org/licenses/by-nc/4.0/>

Country/Territory of origin: Italy

ORCID number: Andrea Vignali 0000-0002-7887-4088; Paola De Nardi 0000-0002-9337-6765.

S-Editor: Gao CC

L-Editor: A

P-Editor: Gao CC

REFERENCES

- 1 **Mirnezami A**, Mirnezami R, Chandrakumaran K, Sasapu K, Sagar P, Finan P. Increased local recurrence and reduced survival from colorectal cancer following anastomotic leak: systematic review and meta-analysis. *Ann Surg* 2011; **253**: 890-899 [PMID: 21394013 DOI: 10.1097/SLA.0b013e3182128929]
- 2 **Branagan G**, Finnis D; Wessex Colorectal Cancer Audit Working Group. Prognosis after anastomotic leakage in colorectal surgery. *Dis Colon Rectum* 2005; **48**: 1021-1026 [PMID: 15789125 DOI: 10.1007/s10350-004-0869-4]
- 3 **Rullier E**, Laurent C, Garrelon JL, Michel P, Saric J, Parneix M. Risk factors for anastomotic leakage after resection of rectal cancer. *Br J Surg* 1998; **85**: 355-358 [PMID: 9529492 DOI: 10.1046/j.1365-2168.1998.00615.x]
- 4 **Blumetti J**, Chaudhry V, Cintron JR, Park JJ, Marecik S, Harrison JL, Prasad LM, Abcarian H. Management of anastomotic leak: lessons learned from a large colon and rectal surgery training program. *World J Surg* 2014; **38**: 985-991 [PMID: 24305917 DOI: 10.1007/s00268-013-2340-y]
- 5 **Bakker IS**, Grossmann I, Henneman D, Havenga K, Wiggers T. Risk factors for anastomotic leakage and leak-related mortality after colonic cancer surgery in a nationwide audit. *Br J Surg* 2014; **101**: 424-32; discussion 432 [PMID: 24536013 DOI: 10.1002/bjs.9395]
- 6 **Phitayakorn R**, Delaney CP, Reynolds HL, Champagne BJ, Heriot AG, Neary P, Senagore AJ; International Anastomotic Leak Study Group. Standardized algorithms for management of anastomotic leaks and related abdominal and pelvic abscesses after colorectal surgery. *World J Surg* 2008; **32**: 1147-1156 [PMID: 18283511 DOI: 10.1007/s00268-008-9468-1]
- 7 **Weidenhagen R**, Gruetzner KU, Wiecken T, Spelsberg F, Jauch KW. Endoscopic vacuum-assisted closure of anastomotic leakage following anterior resection of the rectum: a new method. *Surg Endosc* 2008; **22**: 1818-1825 [PMID: 18095024 DOI: 10.1007/s00464-007-9706-x]
- 8 **van Koperen PJ**, van Berge Henegouwen MI, Rosman C, Bakker CM, Heres P, Slors JF, Bemelman WA. The Dutch multicenter experience of the endo-sponge treatment for anastomotic leakage after colorectal surgery. *Surg Endosc* 2009; **23**: 1379-1383 [PMID: 19037698 DOI: 10.1007/s00464-008-0186-4]
- 9 **Shalaby M**, Emile S, Elfeki H, Sakr A, Wexner SD, Sileri P. Systematic review of endoluminal vacuum-assisted therapy as salvage treatment for rectal anastomotic leakage. *BJS Open* 2019; **3**: 153-160 [PMID: 30957061 DOI: 10.1002/bjs.5.50124]
- 10 **Kuehn F**, Janisch F, Schwandner F, Alsfasser G, Schiffmann L, Gock M, Klar E. Endoscopic Vacuum Therapy in Colorectal Surgery. *J Gastrointest Surg* 2016; **20**: 328-334 [PMID: 26597270 DOI: 10.1007/s11605-015-3017-7]
- 11 **Strangio G**, Zullo A, Ferrara EC, Anderloni A, Carlino A, Jovani M, Piscato C, Hassan C, Repici A. Endo-sponge therapy for management of anastomotic leakages after colorectal surgery: A case series and review of literature. *Dig Liver Dis* 2015; **47**: 465-469 [PMID: 25769505 DOI: 10.1016/j.dld.2015.02.007]
- 12 **Rottoli M**, Di Simone MP, Vallicelli C, Vittori L, Liguori G, Boschi L, Poggioli G. Endoluminal vacuum-assisted therapy as treatment for anastomotic leak after ileal pouch-anal anastomosis: a pilot study. *Tech Coloproctol* 2018; **22**: 223-229 [PMID: 29502228 DOI: 10.1007/s10151-018-1762-9]
- 13 **Keskin M**, Bayram O, Bulut T, Balik E. Effectiveness of Endoluminal Vacuum-assisted Closure Therapy (Endosponge) for the Treatment of Pelvic Anastomotic Leakage After Colorectal Surgery. *Surg Laparosc Endosc Percutan Tech* 2015; **25**: 505-508 [PMID: 26551234 DOI: 10.1097/SLE.0000000000000216]
- 14 **Srinivasamurthy D**, Wood C, Slater R, Garner J. An initial experience using transanal vacuum therapy in pelvic anastomotic leakage. *Tech Coloproctol* 2013; **17**: 275-281 [PMID: 23111399 DOI: 10.1007/s10151-012-0911-9]
- 15 **Arezzo A**, Verra M, Passera R, Bullano A, Rapetti L, Morino M. Long-term efficacy of endoscopic vacuum therapy for the treatment of colorectal anastomotic leaks. *Dig Liver Dis* 2015; **47**: 342-345 [PMID: 25563812 DOI: 10.1016/j.dld.2014.12.003]
- 16 **Milito G**, Lisi G, Venditti D, Campanelli M, Aronadio E, Grande S, Cabry F, Grande M. Endoluminal Vacuum Therapy as Treatment for Anastomotic Colorectal Leakage. *Surg Technol Int* 2017; **30**: 125-130 [PMID: 28072899]

- 17 **Borstlap WAA**, Musters GD, Stassen LPS, van Westreenen HL, Hess D, van Dieren S, Festen S, van der Zaag EJ, Tanis PJ, Bemelman WA. Vacuum-assisted early transanal closure of leaking low colorectal anastomoses: the CLEAN study. *Surg Endosc* 2018; **32**: 315-327 [PMID: [28664443](#) DOI: [10.1007/s00464-017-5679-6](#)]
- 18 **Mahendran B**, Rossi B, Coleman M, Smolarek S. The use of Endo-SPONGE® in rectal anastomotic leaks: a systematic review. *Tech Coloproctol* 2020; **24**: 685-694 [PMID: [32377984](#) DOI: [10.1007/s10151-020-02200-1](#)]
- 19 **Sharp G**, Steffens D, Koh CE. Evidence of negative pressure therapy for anastomotic leak: a systematic review. *ANZ J Surg* 2021; **91**: 537-545 [PMID: [33480168](#) DOI: [10.1111/ans.16581](#)]
- 20 **Popivanov GI**, Mutafchiyski VM, Cirocchi R, Chipeva SD, Vasilev VV, Kjossev KT, Tabakov MS. Endoluminal negative pressure therapy in colorectal anastomotic leaks. *Colorectal Dis* 2020; **22**: 243-253 [PMID: [31274227](#) DOI: [10.1111/codi.14754](#)]
- 21 **Kühn F**, Janisch F, Schwandner F, Gock M, Wedermann N, Witte M, Klar E, Schiffmann L. Comparison Between Endoscopic Vacuum Therapy and Conventional Treatment for Leakage After Rectal Resection. *World J Surg* 2020; **44**: 1277-1282 [PMID: [31965274](#) DOI: [10.1007/s00268-019-05349-5](#)]
- 22 **Nagell CF**, Holte K. Treatment of anastomotic leakage after rectal resection with transrectal vacuum-assisted drainage (VAC). A method for rapid control of pelvic sepsis and healing. *Int J Colorectal Dis* 2006; **21**: 657-660 [PMID: [16447032](#) DOI: [10.1007/s00384-005-0083-4](#)]
- 23 **Mees ST**, Palmes D, Mennigen R, Senninger N, Haier J, Bruewer M. Endo-vacuum assisted closure treatment for rectal anastomotic insufficiency. *Dis Colon Rectum* 2008; **51**: 404-410 [PMID: [18197452](#) DOI: [10.1007/s10350-007-9141-z](#)]
- 24 **Abdalla S**, Cotte E, Epin A, Karoui M, Lefevre JH, Berger A, Marchal F, Denost Q, Penna C, Benoist S, Brouquet A; on behalf the French GRECCAR group. Short-term and Long-term Outcome of Endoluminal Vacuum Therapy for Colorectal or Coloanal Anastomotic Leakage: Results of a Nationwide Multicenter Cohort Study From the French GRECCAR Group. *Dis Colon Rectum* 2020; **63**: 371-380 [PMID: [31842165](#) DOI: [10.1097/DCR.0000000000001560](#)]
- 25 **Nerup N**, Johansen JL, Alkhefagie GA, Maina P, Jensen KH. Promising results after endoscopic vacuum treatment of anastomotic leakage following resection of rectal cancer with ileostomy. *Dan Med J* 2013; **60**: A4604 [PMID: [23651714](#)]
- 26 **Glitsch A**, von Bernstorff W, Seltrecht U, Partecke I, Paul H, Heidecke CD. Endoscopic transanal vacuum-assisted rectal drainage (ETVARD): an optimized therapy for major leaks from extraperitoneal rectal anastomoses. *Endoscopy* 2008; **40**: 192-199 [PMID: [18189215](#) DOI: [10.1055/s-2007-995384](#)]
- 27 **von Bernstorff W**, Glitsch A, Schreiber A, Partecke LI, Heidecke CD. ETVARD (endoscopic transanal vacuum-assisted rectal drainage) leads to complete but delayed closure of extraperitoneal rectal anastomotic leakage cavities following neoadjuvant radiochemotherapy. *Int J Colorectal Dis* 2009; **24**: 819-825 [PMID: [19241081](#) DOI: [10.1007/s00384-009-0673-7](#)]
- 28 **Kühn F**, Wirth U, Zimmermann J, Beger N, Hasenhütl SM, Drefs M, Heiliger C, Burian M, Werner J, Schiergens TS. Endoscopic vacuum therapy for in- and outpatient treatment of colorectal defects. *Surg Endosc* 2021; **35**: 6687-6695 [PMID: [33259019](#) DOI: [10.1007/s00464-020-08172-5](#)]
- 29 **Verlaan T**, Bartels SA, van Berge Henegouwen MI, Tanis PJ, Fockens P, Bemelman WA. Early, minimally invasive closure of anastomotic leaks: a new concept. *Colorectal Dis* 2011; **13** Suppl 7: 18-22 [PMID: [22098512](#) DOI: [10.1111/j.1463-1318.2011.02775.x](#)]
- 30 **Riss S**, Stift A, Kienbacher C, Dauser B, Haunold I, Kriwanek S, Radlsbock W, Bergmann M. Recurrent abscess after primary successful endo-sponge treatment of anastomotic leakage following rectal surgery. *World J Gastroenterol* 2010; **16**: 4570-4574 [PMID: [20857528](#) DOI: [10.3748/wjg.v16.i36.4570](#)]
- 31 **Mussetto A**, Arena R, Buzzi A, Fuccio L, Dari S, Brancaccio ML, Triossi O. Long-term efficacy of vacuum-assisted therapy (Endo-SPONGE®) in large anastomotic leakages following anterior rectal resection. *Ann Gastroenterol* 2017; **30**: 649-653 [PMID: [29118559](#) DOI: [10.20524/aog.2017.0194](#)]
- 32 **van Koperen PJ**, van der Zaag ES, Omluo JM, Slors JF, Bemelman WA. The persisting presacral sinus after anastomotic leakage following anterior resection or restorative proctocolectomy. *Colorectal Dis* 2011; **13**: 26-29 [PMID: [20649900](#) DOI: [10.1111/j.1463-1318.2010.02377.x](#)]
- 33 **Sloothaak DA**, Buskens CJ, Bemelman WA, Tanis PJ. Treatment of chronic presacral sinus after low anterior resection. *Colorectal Dis* 2013; **15**: 727-732 [PMID: [23216939](#) DOI: [10.1111/codi.12094](#)]
- 34 **Borstlap WAA**, Westerduin E, Aukema TS, Bemelman WA, Tanis PJ; Dutch Snapshot Research Group. Anastomotic Leakage and Chronic Presacral Sinus Formation After Low Anterior Resection: Results From a Large Cross-sectional Study. *Ann Surg* 2017; **266**: 870-877 [PMID: [28746154](#) DOI: [10.1097/SLA.0000000000002429](#)]
- 35 **Sturiale A**, Martellucci J, Zurli L, Vaccaro C, Bruscianno L, Limongelli P, Docimo L, Valeri A. Long-term functional follow-up after anterior rectal resection for cancer. *Int J Colorectal Dis* 2017; **32**: 83-88 [PMID: [27695976](#) DOI: [10.1007/s00384-016-2659-6](#)]
- 36 **Huisman JF**, van Westreenen HL, van der Wouden EJ, Vasen HFA, de Graaf EJR, Doornebosch PG, Tang TJ, Schot I, Brohet RM, de Vos Tot Nederveen Cappel WH, Vermaas M. Effectiveness of endosponge therapy for the management of presacral abscesses following rectal surgery. *Tech Coloproctol* 2019; **23**: 551-557 [PMID: [31338710](#) DOI: [10.1007/s10151-019-02007-9](#)]
- 37 **Jagielski M**, Piątkowski J, Jarczyk G, Jackowski M. Transrectal endoscopic drainage with vacuum-assisted therapy in patients with anastomotic leaks following rectal cancer resection. *Surg Endosc* 2022; **36**: 959-967 [PMID: [33650007](#) DOI: [10.1007/s00464-021-08359-4](#)]
- 38 **Emmertsen KJ**, Laurberg S. Low anterior resection syndrome score: development and validation of a symptom-based scoring system for bowel dysfunction after low anterior resection for rectal cancer. *Ann Surg* 2012; **255**: 922-928 [PMID: [22504191](#) DOI: [10.1097/SLA.0b013e31824f1c21](#)]
- 39 **De Nardi P**, Testoni SG, Corsetti M, Andreoletti H, Giollo P, Passaretti S, Testoni PA. Manometric evaluation of anorectal function in patients treated with neoadjuvant chemoradiotherapy and total mesorectal excision for rectal cancer. *Dig Liver Dis* 2017; **49**: 91-97 [PMID: [27720700](#) DOI: [10.1016/j.dld.2016.09.005](#)]
- 40 **Croese AD**, Lonie JM, Trollope AF, Vangaveti VN, Ho YH. A meta-analysis of the prevalence of Low Anterior Resection Syndrome and systematic review of risk factors. *Int J Surg* 2018; **56**: 234-241 [PMID: [29936195](#) DOI: [10.1016/j.ijsu.2018.05.015](#)]

- 10.1016/j.ijssu.2018.06.031]
- 41 **Emmertsen KJ**, Laurberg S; Rectal Cancer Function Study Group. Impact of bowel dysfunction on quality of life after sphincter-preserving resection for rectal cancer. *Br J Surg* 2013; **100**: 1377-1387 [PMID: 23939851 DOI: 10.1002/bjs.9223]
 - 42 **Katz E**, White I, Shpitz B, Ghinea R, Avital S. Different approaches for Endo-SPONGE® insertion to treat rectal anastomotic leaks. *Tech Coloproctol* 2018; **22**: 231-233 [PMID: 29480425 DOI: 10.1007/s10151-018-1764-7]
 - 43 **Weréén A**, Dahlberg M, Heinius G, Pieniowski E, Saraste D, Eklöv K, Nygren J, Pekkari K, Everhov ÅH. Long-Term Results after Anastomotic Leakage following Rectal Cancer Surgery: A Comparison of Treatment with Endo-Sponge and Transanal Irrigation. *Dig Surg* 2020; **37**: 456-462 [PMID: 32829324 DOI: 10.1159/000508935]



Published by **Baishideng Publishing Group Inc**
7041 Koll Center Parkway, Suite 160, Pleasanton, CA 94566, USA

Telephone: +1-925-3991568

E-mail: bpgoffice@wjgnet.com

Help Desk: <https://www.f6publishing.com/helpdesk>

<https://www.wjgnet.com>

