

ALL IMAGES VIDEOS

53,100 Results Any time ▾

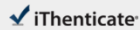
[Adenocarcinoma arising from a heterotopic pancreas in the ...](https://surgicalcasereports.springeropen.com/...)<https://surgicalcasereports.springeropen.com/...>

Jun 18, 2020 · We herein report a case of adenocarcinoma arising from the HP in the first portion of the duodenum. A 77-year-old Japanese man presented to our hospital with epigastric pain. Despite having undergone laparoscopic surgery for early sigmoid colon cancer a month earlier, serum levels of tumor-specific antigens, such as CA19-9, were elevated.

Author: Teruya Minami, Takuro Terada, Takes... Publish Year: 2020

Estimated Reading Time: 8 mins





67948_Auto_Edited-check.docx

Quotes Excluded
Bibliography Excluded

7%
SIMILAR

Name of Journal: *World Journal of Gastroenterology*

Manuscript NO: 67948

Manuscript Type: CASE REPORT

HER2-positive adenocarcinoma arising from heterotopic pancreas tissue in the duodenum: A case report

Hirokawa YS *et al.* HER2-positive duodenal cancer heterotopic pancreas tissue

Yoshirumi S Hirokawa, Takashi Iwata, Yoshinaga Okugawa, Koji Tanaka, Hiroyuki Sakurai, Masatoshi Watanabe

Abstract

BACKGROUND

Adenocarcinoma originating from heterotopic pancreas tissue is a rare disease. Furthermore, to our knowledge, no HER2-positive cases have been reported in the scientific literature nor has the efficacy of trastuzumab treatment for the disease been reported.

Match Overview

- | | | |
|---|---|----|
| 1 | Internet 54 words
crawled on 27-Mar-2021
www.esgnet.com | 3% |
| 2 | Crossref 46 words
Yao Xiong, Yue Xin, Dan-Dan Jin, Xin-Ying Wang "Heteric-
ity pleurocetes adenocarcinoma in the stomach: A case report | 2% |
| 3 | Crossref 18 words
Hisashi Yaguchi, Akiochi Mitsuaki, Kazuhisa Karamoto, Te
moysa Kurimoto, Akiko Nakai "Primary testicular uterine ad | 1% |
| 4 | Crossref 14 words
Bianchini F, N. M. Whithroft; A. Canas, K. King, and J. T
conjugate "Pleurocetes Treated with Didanosine and Tenofo | 1% |
| 5 | Crossref 12 words
Nakaseki K, et al. "Large-cell carcinoma of the lung with a c
a remarkable preoperative elevation of serum carcinoembryo | 1% |

国内版

国际版

HER2-positive adenocarcinoma arising from heterotopic pancreas



ALL

IMAGES

VIDEOS

12,200 Results

Any time ▾

Adenocarcinoma arising from a heterotopic pancreas in the ...

<https://pubmed.ncbi.nlm.nih.gov/32556717>

We herein report a case of adenocarcinoma arising from the HP in the first portion of the duodenum. Case presentation: A 77-year-old Japanese man presented to our hospital with epigastric pain. Despite having undergone laparoscopic surgery for early sigmoid colon cancer a month earlier, serum levels of tumor-specific antigens, such as CA19-9, were elevated.

Author: Teruya Minami, Takuro Terada, Takesh... Publish Year: 2020

Adenocarcinoma arising from intrahepatic heterotopic ...

<https://www.ncbi.nlm.nih.gov/pmc/articles/PMC3374996>

Jun 14, 2012 · Heterotopic pancreas is mostly found incidentally, and adenocarcinoma arising from heterotopic pancreas appears to be extremely rare. A case of a 46-year-old woman with adenocarcinoma arising from intrahepatic heterotopic pancreas is reported herein. Computed tomography demonstrated a mass located in the bile duct of the left hepatic lobe.

Cited by: 17

Author: Mao-Lin Yan, Yao-Dong Wang, Yi-Feng Ti...

Publish Year: 2012

PEOPLE ALSO ASK

Where are adenocarcinoma found in the duodenum? ▾

What is heterotopic pancreas in the duodenum? ▾

Are there any cases of adenocarcinoma arising from an ectopic pancreas? ▾

What is the CT scan of the duodenum? ▾

Feedback

Adenocarcinoma arising from a heterotopic pancreas in the ...

<https://surgicalcasereports.springeropen.com/...> ▾

Jun 18, 2020 · We herein report a case of adenocarcinoma arising from the HP in the first portion of the duodenum. A 77-year-old Japanese man presented to our hospital with epigastric pain. Despite having undergone laparoscopic surgery for early sigmoid colon cancer a month earlier, serum levels of