

ALL IMAGES VIDEOS

3,570,000 Results Any time ▾

### A rare case of scrotal angioliipoma and the literature ...

<https://www.sciencedirect.com/science/article/pii/S2214442020301054>

Sep 01, 2020 · Angiolipoma has been reported in many cases, which often occurring subcutaneously in the trunk and limbs. However, angiolipoma rarely occurs in the scrotum. In order to better understand its biological characteristics, clinical features and prognosis, in this case, a 41-year-old male with painful angiolipoma in the scrotum was reported.

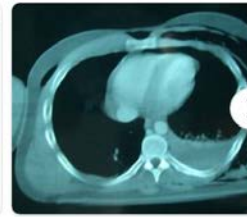
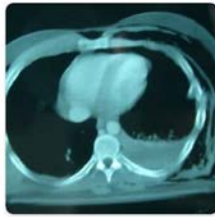
Author: Yu Zhang, Jing Yang, An Xu, Dong Li, Ga... Publish Year: 2020

### (PDF) A rare case of scrotal angioliipoma and the ...

<https://www.researchgate.net/publication/340903955...>

Apr 01, 2020 · Angiolipoma has been reported in many cases, which often occurring subcutaneously in the trunk and limbs. However, angiolipoma rarely occurs in the scrotum.


### Images of Subcutaneous Angioliipoma in the scrotum a Case Report

<bing.com/images>

ALL IMAGES VIDEOS

3,220,000 Results

Any time ▾

Open links in new tab 

### [Intratesticular Angiolipoma: A Rare Case of Adipose Tissue ...](https://www.ncbi.nlm.nih.gov/pmc/articles/PMC6942722)

<https://www.ncbi.nlm.nih.gov/pmc/articles/PMC6942722>

Dec 23, 2019 · Angiolipomas are **benign tumors**, commonly occurring in the **subcutaneous** tissue. This is the first recorded case of an intratesticular, noninfiltrating type angiolipoma which was treated by organ-sparing surgery. Two years after the procedure, there were no recurrences.

**Author:** V. Kalyvas, C. Gkekas, D. Papadopoul...**Publish Year:** 2019**FSH:** 2.17 mIU/ml**LH:** 3.7 mIU/ml

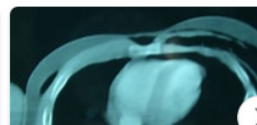### [A rare case of scrotal angiolipoma and the literature ...](https://www.sciencedirect.com/science/article/pii/S2214442020301054)

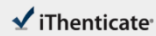<https://www.sciencedirect.com/science/article/pii/S2214442020301054>

Sep 01, 2020 · Angiolipoma has been **reported** in many **cases**, which often occurring **subcutaneously** in the trunk and limbs. However, **angiolipoma** rarely occurs in the **scrotum**. In order to better understand its biological characteristics, clinical features and prognosis, in this **case**, a 41-year-old male with painful **angiolipoma in the scrotum** was **reported**.

**Author:** Yu Zhang, Jing Yang, An Xu, Dong Li, ...**Publish Year:** 2020

### [Images of Subcutaneous Angiolipoma in the scrotum a Case ...](https://www.bing.com/images)

[bing.com/images](https://www.bing.com/images)



68277\_Auto\_Edited - check.docx

Quotes Excluded  
Bibliography Included

4%  
SEILAR

11

### Match Overview

**Name of Journal:** *World Journal of Clinical Cases*

Manuscript NO: 68277

Manuscript Type: CASE REPORT

### Subcutaneous angioliipoma in the scrotum: A case report

Li SL *et al.* Subcutaneous angiolipoma in the scrotum

Shu-Lin Li, Jia-Wei Zhang, Yu-Qi Wu, Ke-Shi Lu, Pei Zhu, Xiang-Wei Wang

国内版

国际版

Subcutaneous angioliipoma in the scrotum: A case report



ALL

IMAGES

VIDEOS

3,520,000 Results

Any time ▾

### [A rare case of scrotal angioliipoma and the literature ...](#)

<https://www.sciencedirect.com/science/article/pii/S2214442020301054>

Sep 01, 2020 · Angiolipoma has been reported in many cases, which often occurring subcutaneously in the trunk and limbs. However, angiolipoma rarely occurs in the scrotum. In order to better understand its biological characteristics, clinical features and prognosis, in this case, a 41-year-old male with painful angiolipoma in the scrotum was reported.

Author: Yu Zhang, Jing Yang, An Xu, Dong Li, ... Publish Year: 2020

### [Intratesticular Angiolipoma: A Rare Case of Adipose Tissue ...](#)

<https://www.ncbi.nlm.nih.gov/pmc/articles/PMC6942722>

Dec 23, 2019 · Angiolipomas are benign tumors, commonly occurring in the subcutaneous tissue. This is the first recorded case of an intratesticular, noninfiltrating type angiolipoma which was treated by organ-sparing surgery. Two years after the procedure, there were no recurrences.

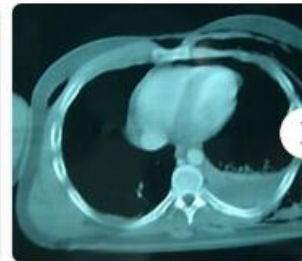
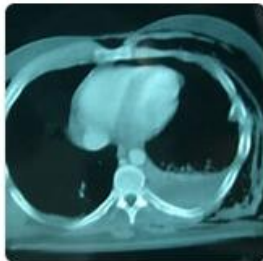Author: V. Kalyvas, C. Gkekas, D. Papadopou... Publish Year: 2019

FSH: 2.17 mIU/ml

LH: 3.7 mIU/ml

### [Images of Subcutaneous Angiolipoma in the scrotum A Case ...](#)

[bing.com/images](https://bing.com/images)



See all images >

### [Preoperative diagnosis of scrotal angiolipoma: A case report](#)