

ALL

IMAGES

VIDEOS

115,000 Results

Any time ▾

### Fat embolism syndrome after femur fracture fixation: a ...

<https://pubmed.ncbi.nlm.nih.gov/25328460>

Fat embolism syndrome after femur fracture fixation: a case report. Fat embolism syndrome (FES) is a multi-organ disorder with potentially serious sequelae that is commonly seen in the orthopaedic patient population after femur fractures. The major clinical features of FES include hypoxia, pulmonary dysfunction, mental status changes, petechiae, tachycardia, fever, ....

Cited by: 12

Author: Craig C Akoh, Cameron Schick, Jesse Oter...

Publish Year: 2014

### Fat Embolism Syndrome: A Case Report and Review Literature

<https://www.hindawi.com/journals/crim/2018/1479850> ▾**Abstract**

Introduction

Case Presentation

Discussion

Conclusion

Fat embolism syndrome (FES) is a life-threatening complication in patients with orthopedic trauma, especially long bone fractures. The diagnosis of fat embolism is made by clinical features alone with no specific laboratory findings. FES has no specific treatment and requires supportive care, although it can be prevented by early fixation of bone fractures. Here, we report a case of FES in a patient with right femoral neck fracture, which was **diagnosed initially by Gurd's criteria and subsequently confirmed by t...**

[See more on hindawi.com](#)

Cited by: 7

Author: Nattaphol Uransilp, Sombat Muengtaweep...

Publish Year: 2018

PEOPLE ALSO ASK

## Fat embolism syndrome after femur fracture fixation: a ...

<https://pubmed.ncbi.nlm.nih.gov/25328460>

**Fat embolism syndrome** (FES) is a multi-organ disorder with potentially serious sequelae that is commonly seen in the orthopaedic patient population after **femur fractures**. The major clinical features of FES include hypoxia, pulmonary dysfunction, mental status changes, petechiae, tachycardia, fever, thrombocytopenia, and anemia.

**Cited by:** 13

**Author:** Craig C Akoh, Cameron Schick, Jesse Ot...

**Publish Year:** 2014

## [PDF] Fat Embolism Syndrome Due to Fracture Right Femur: A ...

[https://applications.emro.who.int/imemrf/Egypt\\_J...](https://applications.emro.who.int/imemrf/Egypt_J...)

**Fat embolism syndrome** (FES) is usually associated with fractures of long bones and pelvis. Symptoms usually occurs hours to days after injury. We present a **case** with **fat embolism syndrome** due to fracture femur. Prompt supportive treatment of patient's respiratory system and additional pharmaceutical treatment provides the positive outcome. There is no specific therapy

### PEOPLE ALSO ASK

How did fat embolism syndrome develop after femur fracture?



What are the symptoms of fat embolism syndrome?



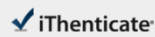
When does fat embolization occur in an orthopedic patient?



Is there a cure for fat embolism syndrome?



Feedback



68328\_Auto\_Edited.docx

Quotations Excluded  
Bibliography Included11%  
(0.00%)**Name of Journal:** *World Journal of Clinical Cases***Manuscript NO:** 68328**Manuscript Type:** CASE REPORT**Early acute fat embolism syndrome caused by femoral fracture: A case report**Yang J *et al.* Early acute FES caused by femoral fractureJia Yang, Zhong-Ning Cui, Jia-Nan Dong, Wen-Bo Lin, Jiang-Tao Jin, Xiao-Jie Tang,  
Xiao-Bo Guo, Shao-Bo Cui, Ming Sun, Chen-Chen Ji

## All Sources

Match 1 of 5

Internet - 20 sources	103 words	5%
● crawled on 06-May-2021		
www.vjgnet.com		
Crossref - 65 sources	65 words	3%
● Jin Shao, De-Ce Hong, Xin-tui Zheng, Tian-Ning Chen, Tie-Yi Yang "Postoperative complications of concomitant fat e		
Crossref - 2 sources	51 words	2%
● Janelle-Chen A, Miller, Carrie Watson, John M. Cam, Joshua a Hagen et al. "An Early Case of Fat Embolism Syndrom		
Crossref - 38 words		2%
● Timon C, Keady C, Murphy CG. "Fat Embolism Syndrome -- A Qualitative Review of its Incidence, Presentation, Pat		
Internet - 38 words		2%
● crawled on 02-Jun-2021		
www.mothjy.org		
Crossref - 2 sources	29 words	1%
● Chen-Kai Huang, Chih-Yuan Huang, Chia-Lung Li, Jui-Ming Yang, Chen-Hsien Wu, Chih-Hui Chen, Po-Ting Wu "Isolate		
Internet - 29 words		1%
● crawled on 15-Jan-2020		

国内版

国际版

Early acute fat embolism syndrome caused by femoral fracture: A c



ALL

IMAGES

VIDEOS

26,400 Results

Any time ▾

### [Fat embolism syndrome after femur fracture fixation: a ...](#)

<https://pubmed.ncbi.nlm.nih.gov/25328460>

Fat embolism syndrome (FES) is a multi-organ disorder with potentially serious sequelae that is commonly seen in the orthopaedic patient population after **femur fractures**. The major clinical features of FES include hypoxia, pulmonary dysfunction, mental status changes, petechiae, tachycardia, fever, thrombocytopenia, and anemia.

Cited by: 13

Author: Craig C Akoh, Cameron Schick, Jesse Ot...

Publish Year: 2014

### [\[PDF\] Fat Embolism Syndrome Due to Fracture Right Femur: A ...](#)

[https://applications.emro.who.int/imemrf/Egypt\\_J...](https://applications.emro.who.int/imemrf/Egypt_J...)

Fat embolism syndrome (FES) is usually associated with fractures of long bones and pelvis. Symptoms usually occurs hours to days after injury. We present a **case with fat embolism syndrome** due to fracture femur. Prompt supportive treatment of patient's respiratory system and additional pharmaceutical treatment provides the positive outcome. There is no specific therapy

#### PEOPLE ALSO ASK

Can a femur fracture cause cerebral fat embolism?



What are the symptoms of fat embolism syndrome?



When does fat embolization occur in an orthopedic patient?



Is there a cure for fat embolism syndrome?



[Feedback](#)

### [Fat embolism syndrome - PubMed Central \(PMC\)](#)

<https://www.ncbi.nlm.nih.gov/pmc/articles/PMC3665122>

Over 150 years ago, Zenker described the **first case of fat embolism syndrome (FES)** in a patient suffering from crush injury. While FES was later clinically diagnosed and often reported in the literature over the next 100 years, Gurd's clinical description of the FES renewed interest in ...

Cited by: 70

Author: Michael E Kwiatt, Mark J Seamon