

# World Journal of *Gastroenterology*

*World J Gastroenterol* 2021 December 28; 27(48): 8201-8377





### FRONTIER

- 8201** Palmitoylation in Crohn's disease: Current status and future directions  
*Cheng WX, Ren Y, Lu MM, Xu LL, Gao JG, Chen D, Kalyani FS, Lv ZY, Chen CX, Ji F, Lin HN, Jin X*
- 8216** New era of electrochemotherapy in treatment of liver tumors in conjunction with immunotherapies  
*Trotošek B, Djokić M, Čemažar M, Serša G*
- 8227** Magnetic challenge against gastroesophageal reflux  
*Bortolotti M*

### REVIEW

- 8242** Emerging therapeutic options in inflammatory bowel disease  
*Yamamoto-Furusho JK, Parra-Holguín NN*
- 8262** Issues of origin, morphology and clinical significance of tumor microvessels in gastric cancer  
*Senchukova MA*
- 8283** Reciprocal interactions between gut microbiota and autophagy  
*Lapaquette P, Bizeau JB, Acar N, Bringer MA*

### ORIGINAL ARTICLE

#### Basic Study

- 8302** Hepatitis B core antigen modulates exosomal miR-135a to target vesicle-associated membrane protein 2 promoting chemoresistance in hepatocellular carcinoma  
*Wei XC, Xia YR, Zhou P, Xue X, Ding S, Liu LJ, Zhu F*
- 8323** Dual therapy with zinc acetate and rifaximin prevents from ethanol-induced liver fibrosis by maintaining intestinal barrier integrity  
*Fujimoto Y, Kaji K, Nishimura N, Enomoto M, Murata K, Takeda S, Takaya H, Kawaratani H, Moriya K, Namisaki T, Akahane T, Yoshiji H*

#### Case Control Study

- 8343** Combination of squamous cell carcinoma antigen immunocomplex and alpha-fetoprotein in mid- and long-term prediction of hepatocellular carcinoma among cirrhotic patients  
*Gil-Gómez A, Rojas Á, Liu CH, Gallego-Duran R, Muñoz-Hernandez R, Fassina G, Pontisso P, Ampuero J, Romero-Gómez M*

#### Retrospective Study

- 8357** New prognostic model for patients with advanced gastric cancer: Fluoropyrimidine/platinum doublet for first-line chemotherapy  
*Koo DH, Ryu MH, Lee MY, Moon MS, Kang YK*

**LETTER TO THE EDITOR**

- 8370** Strategy for the control of drug-induced liver injury due to investigational treatments/drugs for COVID-19

*Sato K, Yamazaki Y, Uraoka T*

- 8374** Use of oral contraceptives and risk of pancreatic cancer in women: A recalculated meta-analysis of prospective cohort studies

*Bae JM*

**ABOUT COVER**

Editorial Board Member of *World Journal of Gastroenterology*, Jakob Robert Izbicki, MD, Professor, Chairman, Department of General, Visceral and Thoracic Surgery, University of Hamburg, Martinistr. 52, Hamburg D-20246, Germany. [izbicki@uke.de](mailto:izbicki@uke.de)

**AIMS AND SCOPE**

The primary aim of *World Journal of Gastroenterology* (WJG, *World J Gastroenterol*) is to provide scholars and readers from various fields of gastroenterology and hepatology with a platform to publish high-quality basic and clinical research articles and communicate their research findings online. WJG mainly publishes articles reporting research results and findings obtained in the field of gastroenterology and hepatology and covering a wide range of topics including gastroenterology, hepatology, gastrointestinal endoscopy, gastrointestinal surgery, gastrointestinal oncology, and pediatric gastroenterology.

**INDEXING/ABSTRACTING**

The WJG is now indexed in Current Contents®/Clinical Medicine, Science Citation Index Expanded (also known as SciSearch®), Journal Citation Reports®, Index Medicus, MEDLINE, PubMed, PubMed Central, and Scopus. The 2021 edition of Journal Citation Report® cites the 2020 impact factor (IF) for WJG as 5.742; Journal Citation Indicator: 0.79; IF without journal self cites: 5.590; 5-year IF: 5.044; Ranking: 28 among 92 journals in gastroenterology and hepatology; and Quartile category: Q2. The WJG's CiteScore for 2020 is 6.9 and Scopus CiteScore rank 2020: Gastroenterology is 19/136.

**RESPONSIBLE EDITORS FOR THIS ISSUE**

Production Editor: Jia-Hui Li; Production Department Director: Yu-Jie Ma; Editorial Office Director: Ze-Mao Gong.

**NAME OF JOURNAL**

*World Journal of Gastroenterology*

**ISSN**

ISSN 1007-9327 (print) ISSN 2219-2840 (online)

**LAUNCH DATE**

October 1, 1995

**FREQUENCY**

Weekly

**EDITORS-IN-CHIEF**

Andrzej S Tarnawski

**EDITORIAL BOARD MEMBERS**

<http://www.wjgnet.com/1007-9327/editorialboard.htm>

**PUBLICATION DATE**

December 28, 2021

**COPYRIGHT**

© 2022 Baishideng Publishing Group Inc

**INSTRUCTIONS TO AUTHORS**

<https://www.wjgnet.com/bpg/gerinfo/204>

**GUIDELINES FOR ETHICS DOCUMENTS**

<https://www.wjgnet.com/bpg/GerInfo/287>

**GUIDELINES FOR NON-NATIVE SPEAKERS OF ENGLISH**

<https://www.wjgnet.com/bpg/gerinfo/240>

**PUBLICATION ETHICS**

<https://www.wjgnet.com/bpg/GerInfo/288>

**PUBLICATION MISCONDUCT**

<https://www.wjgnet.com/bpg/gerinfo/208>

**ARTICLE PROCESSING CHARGE**

<https://www.wjgnet.com/bpg/gerinfo/242>

**STEPS FOR SUBMITTING MANUSCRIPTS**

<https://www.wjgnet.com/bpg/GerInfo/239>

**ONLINE SUBMISSION**

<https://www.f6publishing.com>



## Magnetic challenge against gastroesophageal reflux

Mauro Bortolotti

**ORCID number:** Mauro Bortolotti  
[0000-0002-5273-9013](https://orcid.org/0000-0002-5273-9013).

**Author contributions:** Bortolotti M drafted the manuscript and revised the manuscript.

**Conflict-of-interest statement:** The author declares no conflict of interest.

**Country/Territory of origin:** Italy

**Specialty type:** Gastroenterology and hepatology

**Provenance and peer review:** Invited article; Externally peer reviewed

**Peer-review model:** Single blind

**Peer-review report's scientific quality classification**

Grade A (Excellent): 0  
Grade B (Very good): B  
Grade C (Good): C, C, C, C  
Grade D (Fair): 0  
Grade E (Poor): 0

**Open-Access:** This article is an open-access article that was selected by an in-house editor and fully peer-reviewed by external reviewers. It is distributed in accordance with the Creative Commons Attribution NonCommercial (CC BY-NC 4.0) license, which permits others to distribute, remix, adapt, build upon this work non-commercially, and license their derivative works

**Mauro Bortolotti**, Department of Internal Medicine and Gastroenterology, S. Orsola-Malpighi Polyclinic, University of Bologna, Bologna 40138, Italy

**Mauro Bortolotti**, Via Massarenti 48, Bologna 40138, Italy

**Corresponding author:** Mauro Bortolotti, MD, Via Massarenti 48, Bologna 40138, Italy.  
[bormau@tin.it](mailto:bormau@tin.it)

### Abstract

Almost 15 years have passed since the first paper on the possibility of using magnets to prevent gastro-esophageal reflux (GER) was published and so it is time to assess the results obtained with the first magnetic device available on the market, the Linx magnetic sphincter augmentation (MSA) and to consider what other options are forthcoming. MSA demonstrated an anti-reflux activity similar to that of Nissen fundoplication, considered the "gold standard" surgical treatment for GER disease, and caused less gas-bloating and a better ability to allow vomiting and belching. However, unlike Nissen fundoplication, this magnetic device is burdened by complications, which are roughly similar to those of the non-magnetic anti-reflux Angelchik prosthesis, that, after considerable use in the eighties, was shelved due to these complications. It is interesting to note that some of these complications show the same pathophysiological mechanism in both devices. The upcoming new magnetic devices should avoid these complications, as their anti-reflux magnetic mechanism is completely different. The experiments in animals regarding these new magnetic appliances were examined, remarking their advantages and drawbacks, but the way to apply them in surgical practice is long and difficult, although worthy, as they represent the future of magnetic surgery.

**Key Words:** Gastro-esophageal reflux disease; Magnetic sphincter augmentation device; Nissen fundoplication; Angelchik prosthesis; Lower esophageal sphincter; Dysphagia

©The Author(s) 2021. Published by Baishideng Publishing Group Inc. All rights reserved.

**Core Tip:** The idea of a magnetic device aimed to prevent gastroesophageal reflux was conceived and realized more or less 15 years ago, for which it is time to take stock and consider its future. The first and only device available nowadays in the market is the Linx magnetic sphincter augmentation. Its effectiveness was examined and compared

on different terms, provided the original work is properly cited and the use is non-commercial. See: <http://creativecommons.org/licenses/by-nc/4.0/>

**Received:** May 27, 2021

**Peer-review started:** May 27, 2021

**First decision:** June 21, 2021

**Revised:** July 7, 2021

**Accepted:** December 3, 2021

**Article in press:** December 3, 2021

**Published online:** December 28, 2021

**P-Reviewer:** Morozov S, Sawada A, Sweis R, Tustumi F

**S-Editor:** Wang JJ

**L-Editor:** Webster JR

**P-Editor:** Wang JJ



to that of Nissen fundoplication, whereas its complications, similar to those of the Angelchik prosthesis, were described and their pathophysiology discussed. Furthermore, the pros and cons of the upcoming magnetic anti-reflux devices were examined, underlining the fact that, working with a mechanism completely different to that of the first device, many of its complications could be avoided.

**Citation:** Bortolotti M. Magnetic challenge against gastroesophageal reflux. *World J Gastroenterol* 2021; 27(48): 8227-8241

**URL:** <https://www.wjgnet.com/1007-9327/full/v27/i48/8227.htm>

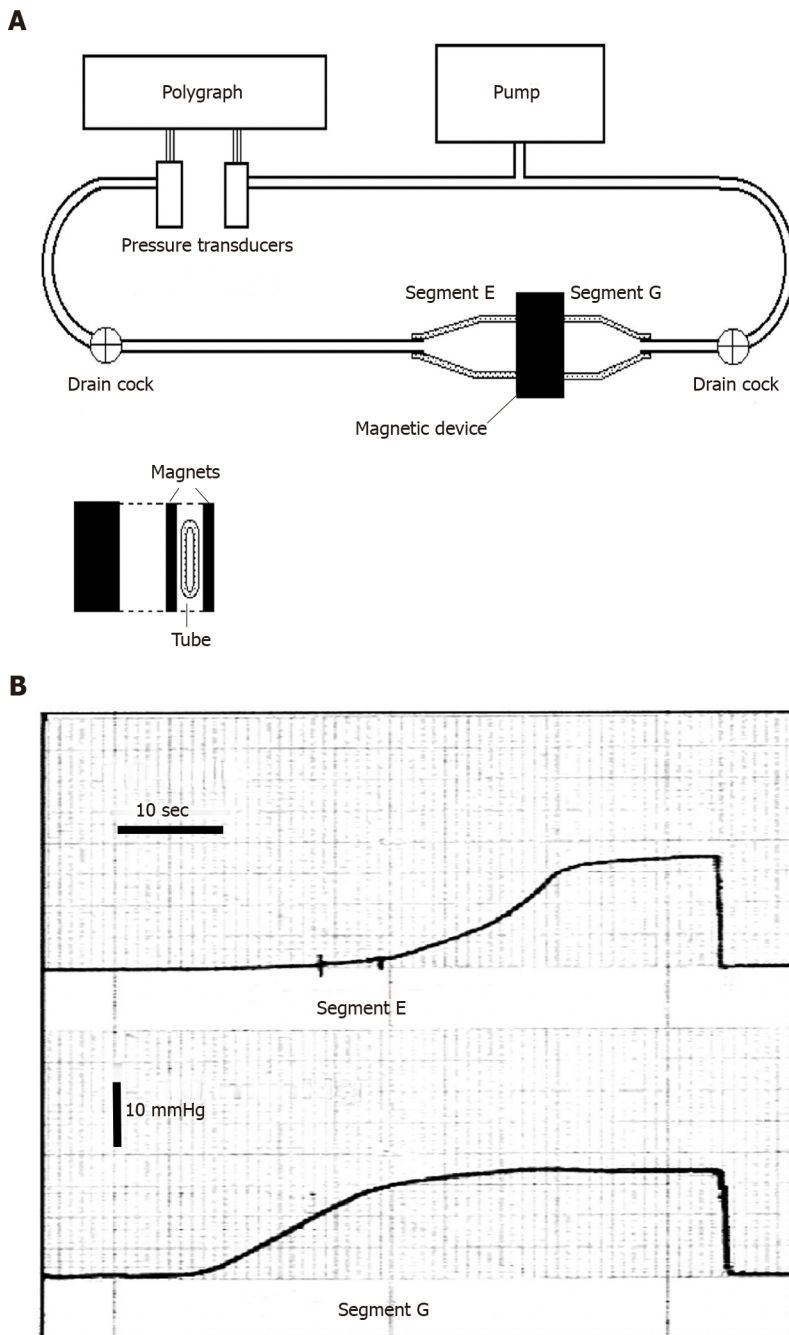
**DOI:** <https://dx.doi.org/10.3748/wjg.v27.i48.8227>

## INTRODUCTION

It is well known that gastrointestinal sphincters may undergo a weakening in their function of blocking the retrograde flux of contents as at the gastro-esophageal junction level, giving rise to the gastro-esophageal reflux (GER) and the antegrade flux, as at the anal level, causing fecal incontinence. Researchers have tried to strengthen these sphincters by means of medical and surgical treatments, with varying success, and in these last few years they have started using magnets.

Until a few years ago magnetic devices were used only in laparoscopic and endoscopic surgery, providing alternatives for retraction, anchoring, compression, mobilization, and anastomosis[1]. In particular, circular magnets applied face to face have been used to create an “anastomosis” between two adjacent intestinal loops, through necrosis of the compressed tissues, in order to bypass the stop caused by scarring stenosis or by an inoperable cancer obstructing the intestinal lumen[2]. This latter appliance of the magnetic force made me think that the reciprocal attraction of a couple of low power magnets placed face to face outside the opposite walls of a sphincter, may squeeze it, thereby closing the lumen. Thus, some fifteen years ago I described in a bench-top experiment this novel idea of strengthening a gut sphincter with magnets and sent the article to the Journal of Biomechanics in 2003, but “oddly” the article was only published in 2006[3]. As illustrated in Figure 1 in this study a couple of magnetic plaques were applied with the opposite polarities facing each other on the opposite sides of a flaccid tube perfused with water by means of a pump at a certain pressure. The plaques, which attract one another, squeeze the lumen of the tube thereby blocking the flux of the content (like a sphincter that prevents reflux). When the endoluminal pressure is increased above the attraction force of the magnets, the plaques detach themselves, allowing the flow to resume (like a sphincter that opens). On the other hand, when the endoluminal pressure is decreased, the attraction force again prevails and the plaques again squeeze the lumen (to prevent reflux). Furthermore, the force of closure of the plaques can be increased or decreased as desired using magnets with a different force of attraction.

A few years after the aforementioned publication, an increasing number of papers from 2008 to today on the use of magnets to strengthen gut sphincters, and in particular the lower esophageal sphincter (LES), became available. The first magnetic device available on the market to strengthen a weak LES, called Linx magnetic sphincter augmentation (MSA), appeared in an article[4] approximately 13 years ago and represented a clever evolution of the first idea previously published in 2006[3]. This paper was followed by many other studies and so today it is time to consider the surgical magnetic story, assess its successes and failures, as well as drawbacks and complications, and look to the future with the upcoming magnetic devices. A literature search was carried out essentially in the PubMed database, with the following search terms: “magnetic sphincter augmentation device”; “Linx reflux management system”; and “antireflux magnetic devices”. From the articles thus found, the most significant and representative were chosen to fulfil the aim of the study. However, a systematic review is not the purpose of this study, but, starting from state-of-the art, I have tried to provide a perspective for future research.



**Figure 1 Benchtop experiment to demonstrate the possibility of creating a sphincter with two magnetic plaques.** A: Schematic illustration of the bench model used to study the new anti-reflux device based on magnets. On the right there is a flaccid polyethylene tube 2.8 cm in diameter, mimicking the gastro-esophageal junction. It is squeezed perpendicularly by two rectangular magnets made of plastroferrite (Flexo) 2 cm × 4 cm × 0.5 cm with an attraction force of 0.36 N/cm<sup>2</sup>, when in contact and 0.16 N/cm<sup>2</sup>, at a distance of 7 mm. It creates a high pressure zone 2 cm wide, that divides the tube in segment E (esophagus) and G (stomach). The tube is perfused with water by a pump and the pressure variations in each segment are detected with 2 pressure transducers and recorded by a polygraph; B: Intraluminal pressure variations in segment G (bottom) and E (top). The pressure in segment G (stomach) was progressively increased by the pump and when it reached approximately 11.5 mmHg, the magnets, simulating the sphincter, get detached, so that the pressure in segment E (esophagus) starts to increase, mimicking a gastro-esophageal reflux and reaching the level of the segment G. Once the pump stops the pressure falls and the magnets adhere again, closing the passage. Exchanging the letter E for G and G for E, this sequence of events may represent the passage of a bolus through the zone squeezed by the magnets. A-B: Citation: Bortolotti M. A novel anti-reflux device based on magnets. *J Biomech* 2006; 39: 564-7. Copyright© The Authors 2020. Published by Elsevier. The authors obtained permission for use of the figure from the Elsevier Publishing Group (Supplementary material).

## THE MSA DEVICE

The first MSA device to prevent GER (LINX Reflux Management System) was produced by Torax Medical, Inc., Shore View, MN, United States, and was utilized in a 2008 study by Bonavina *et al*[4]. It consisted of a “collar” of titanium beads with a magnetic core of neodymium interlinked along an independent flexible titanium wire



(Figure 2). The magnets were allowed to slide against one another along the wire, self-attracting by their magnetic force and self-detaching under the action of an opposing force, as the expanding pressure that dilates the “collar”. In this manner they can attach and detach each other, thereby tightening or widening the collar which, consequently, closes and opens the esophageal lumen below. This “magnetic collar” is placed around the abdominal esophagus at the patient’s LES level, by adapting its circumference by increasing or decreasing the number of magnetic beads.

### **Effectiveness of the Linx MSA device (“magnetic collar”) in preventing GER**

The first clinical trial[4] with the “magnetic collar” MSA, carried out in 2008 on 38 GERD patients, reported that, after a mean follow-up of 209 d, the GERD-Health Related Quality of Life (HRQL) score significantly decreased from 26.0 to 1.0, whereas, 3 mo after insertion, 89% of patients were off anti-reflux medications, and 79% had a normal 24-h pH recording test. Mild dysphagia occurred in 45% of patients. A subsequent study[5] performed in 2013 on 100 patients showed that at the 1-year follow-up there was a normalization or a 50% or greater reduction in esophageal acid exposure at 24-h pH test in 64% of patients, together with an improvement of 50% or more in GERD-HRQL scores in 92% of patients. In addition, there was a 50% or greater reduction in the use of proton-pump inhibitors (PPIs) and a significant increase in LES pressure. However, 36% of patients did not reach the normal esophageal acid exposure, whereas at the 1-year follow-up, esophagitis was still present in 10% of patients and had developed in 8%.

More or less similar results regarding the effectiveness in preventing GER were obtained by other investigators[6-11] in the following years up to 2020. One of the recent most complete studies from a single referral center was that of Ferrari *et al*[12], who followed up 124 patients for six up to 12 years (median 9 years) after insertion of the MSA device. The mean total GERD-HRQL score significantly improved from 19.9 to 4.01, PPIs were discontinued by 79% of patients, the mean total percent time with pH < 4 at 24-h pH recording significantly decreased from 9.6% to 4.1% and 89% of patients achieved intra-esophageal pH normalization. However, the term normalization is inexact, being only an improvement. In fact, although there was a significant decrease in the total % time pH < 4, the total number of reflux episodes, and particularly of those longer than 5 min, did not significantly decrease (Table 1)[12]. This indicates that the MSA device may not completely seal the gastro-esophageal junction and explains why in this study gastrointestinal endoscopy after a follow-up of 6 years revealed a grade A esophagitis in 4.7% of patients and incomplete intestinal metaplasia in 2.8%. In addition, the fact that the number of reflux episodes was not significantly decreased, whereas the total % time of acid exposure was significantly decreased, indicates that the mean duration of each reflux episode is decreased. However, this short duration does not depend on the closure of the gastro-esophageal junction by the MSA device, but it is due to an improved peristaltic clearance activity of the distal esophagus, which rapidly cleanses the mucosa from the refluxed acid[13]. In conclusion, after MSA device insertion the number of reflux episodes does not change significantly, but esophageal acid exposure after each reflux decreases with some benefits for the mucosa.

### **Comparison between MSA and Nissen fundoplication**

The clinical results of MSA are not overwhelming when compared to those of Nissen fundoplication, which is considered paramount in GER surgical treatment. Nissen fundoplication showed excellent GER symptom control, low rates of complications and reoperations in long-term follow-up studies[14], whereas only 15% of patients reported recurrent symptoms[15]. In a review of studies with a long-term outcome [16], the control of reflux symptoms, such as heartburn and regurgitation, was achieved in 84% to 97% of patients, and in another similar review[17] good and excellent results were reported in 85%-95% of patients, with reflux recurrence in only 1%-8.5%, and dysphagia in 0%-10%.

Of great interest are the comparative studies of MSA *vs* Nissen fundoplication (Table 2). In two studies of a systematic review and meta-analysis, one with 1211 patients[18], and the other with 688 patients[19], postoperative GERD-HRQL and PPI suspension were similar in both the MSA and fundoplication groups, but MSA resulted in less gas-bloating and a greater ability to belch and vomit. Similar results were obtained in other comparative studies[20-23]. However, Riegler *et al*[20] found that the percentage of MSA patients with PPI suspension was significantly higher than that of fundoplication patients, whereas Warren *et al*[23] found the opposite results. Skubleny *et al*[19] noted that the occurrence of gas-bloating was not statistically different between the two treatments. In addition, Aiolfi *et al*[18] reported the



Table 1 Esophageal pH measurements (mean  $\pm$  SD) off proton pump inhibitors[12]

Measure	Baseline	6-12 yr	P value
	n = 124	n = 91	
Total time (%)			
pH < 4	9.7 (6.4)	4.2 (4.9)	< 0.001
Upright	9.7 (7.8)	4.6 (4.9)	< 0.001
Supine	8.3 (9.6)	3.3 (7.4)	< 0.001
Reflux episodes			
Total number	92.2 (92.2)	71.5 (67.7)	0.125
Number lasting > 5 min	6.1 (6.0)	4.3 (5.8)	0.036
Longest (min)	32.9 (34.2)	19.6 (31.5)	0.005
DeMeester score	40.7 (26.5)	16.3 (18.8)	< 0.001

occurrence, although not statistically significant, of dysphagia requiring endoscopic dilatation in 9.3% of patients of the MSA group *vs* 6.6% of the fundoplication group, whereas Warren *et al*[23] observed that mild dysphagia was significantly more frequent in MSA patients. Skubleny *et al*[19] found a trend with 24% of MSA patients requiring dilatation *vs* 3.3% in those with fundoplication. In addition, Sheu *et al*[24] stated that dysphagia associated with MSA lasted longer, was more severe and required dilatation more frequently compared with fundoplication. The operative time in patients with MSA was shorter than in those with fundoplication[18,19,21,23]. Finally, both the MSA intervention[25] and fundoplication[26] were followed by the regression of intestinal metaplasia. In conclusion, although there are no randomized controlled trials to more properly compare MSA results with those of Nissen fundoplication, it can be said that both systems are roughly similar in preventing GER. However, on the one hand MSA has the advantage of less gas bloating and greater ability to vomit and belch, while on the other hand it has the disadvantage of a more prolonged and severe dysphagia, requiring more frequent endoscopic dilatation and, in some cases, device removal, as we will see later, along with other complications.

### MSA complications and their pathophysiology

The most frequent complication after MSA device insertion was dysphagia; however, its occurrence was highly variable. Ganz *et al*[5] reported that 68% of patients developed dysphagia in the immediate postoperative period, which decreased to 11% after 1 year. Twenty seven percent of these patients underwent esophageal dilatation and 3% required device removal, whereas in the remaining patients dysphagia spontaneously improved after some months. In a review of 35 studies[27], the most common postoperative complication was dysphagia ranging between 6% and 83%, whereas Ayazi *et al*[28] reported a 15.5% rate of persistent postoperative dysphagia in a group of 380 patients who underwent MSA device insertion. Thirty-one percent of these patients required at least one dilatation due to dysphagia or chest pain and the overall positive response rate to this procedure was 67%, whereas 1.8% required device removal. Schwameis *et al*[29] compared to pseudoachalasia the difficult transit at the level of the esophago-gastric junction caused by the MSA device, because it mimics the clinical and pathophysiological manifestations of idiopathic achalasia.

The occurrence of dysphagia or incomplete GER prevention may have various explanations. The length of the “magnetic collar” (MSA) circumference, which must be adapted to each patient by adding or removing some beads, may increase exposure risk due to an incorrect measurement. Furthermore, sometimes by adding a bead, the collar may be too large, giving rise to incomplete GER prevention, whereas, by not adding the bead, the collar may be too tight, causing dysphagia. This phenomenon could occur in patients with smaller esophageal circumferences. Dysphagia and uncontrolled GER, which appear some time after surgery, could also be explained in a different way. The MSA device, as the months go by, may be “encapsulated” by fibrous tissue, as demonstrated by necropsy performed in a porcine model 11 mo after MSA implantation[30]. This “encapsulation” of the MSA device due to a fibrotic reaction was also confirmed in patients, in whom the “magnetic collar” was explanted because of complications[31,32]. The fibrosis around the magnetic mechanisms of the

Table 2 Comparison of magnetic sphincter augmentation and fundoplication

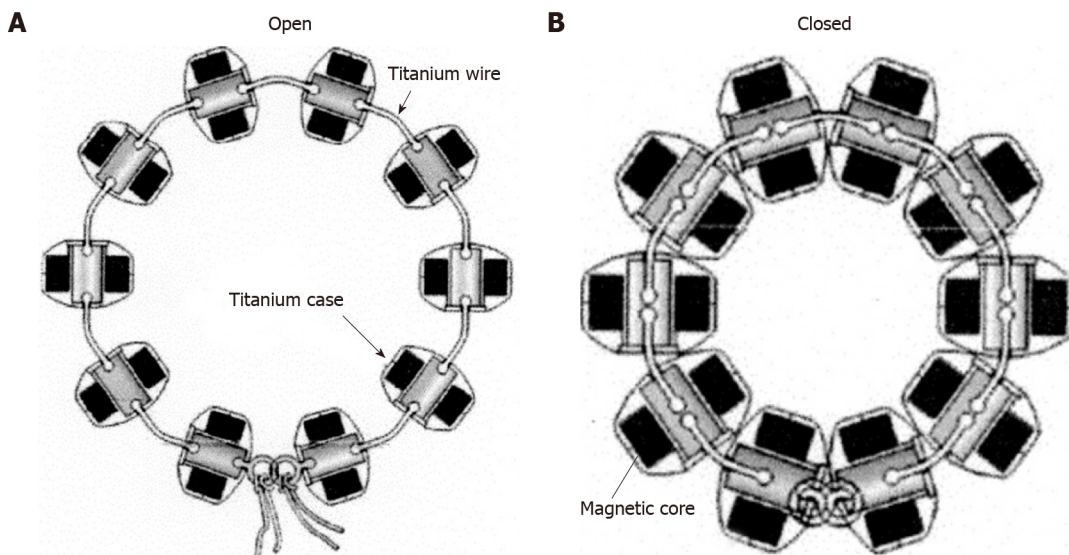
	Aiolfi et al[18]			Skubleny et al[19]			Riegler et al[20]			Reynolds et al[21]			Guidozzi et al[22]			Warren et al[23]		
	MSA	FUNDO	P value	MSA	FUNDO	P value	MSA	FUNDO	P value	MSA	FUNDO	P value	MSA	FUNDO	P value	MSA	FUNDO	P value
Type of study	Systematic review and meta-analysis			Systematic review and meta-analysis			O. prospective multicenter study			O. retrospective review from a single center			Systemic review and meta-analysis			Multi institutional retrospective cohort study		
N. patients (n)	686	525		415	273		202	47		52	67		632	467		169	185	
Follow-up (mo)	6-12	6-12		7-12	7-16		12	12		12	12		15.5	15.8		12	12	
GERD-HRQL score	POR = 0.48		0.101	20.5 vs 3 19.7 vs 3.2		NS	20 vs 3 23 vs 3.5		0.177	4.3 p. 5.1 p.		0.47	WMD = 0.34		0.525	21 vs 3 19 vs 4		0.17
PPI suspension	POR = 0.81		0.548	81.4% <sup>1</sup> 81.5% <sup>1</sup>		0.68	81.8% 63.0%		0.009	85% 92%		0.37	POR = 1.08		0.877	76% 88%		0.02
Gas/bloating	POR = 0.39		< 0.001	26.7% <sup>1</sup> 53.4% <sup>1</sup>		0.06	10.0% 31.9%		< 0.001	23% 53%		< 0.01	POR = 0.34		0.004	47% 59%		0.008
Ability to vomit	POR = 10.1		< 0.001	93.5% <sup>1</sup> 49.5% <sup>1</sup>		< 0.0001	91.3% 44.4%		< 0.001	4% 19%		< 0.01				95% 43%		< 0.001
Ability to belch	POR = 5.53		< 0.001	95.2% <sup>1</sup> 65.9% <sup>1</sup>		< 0.00001	98.4% 88.9%		0.007	10.0% 36%		< 0.01	POR = 12.34		< 0.001	96.5% 69.2%		< 0.001
Dysphagia	POR = 1.56		0.119	33.9% <sup>1</sup> 47.1% <sup>1</sup>		0.43	7% 10.6%		0.373	46% 56%		0.25	POR = 0.94		0.822	58% 47%		0.31
Operative time (min)	42-73 76-118			63.7 76.8						66 82		< 0.01				60 76		< 0.001

<sup>1</sup>Weighted mean percent values. MSA: Magnetic sphincter augmentation; FUNDO: Fundoplication; O.: Observational; WMD: Weighted mean difference; POR: Pooled odds ratio; NS: Not statistically significant; vs: Signifies preoperative versus postoperative score; p.: Postoperative.

MSA device could hamper the detachment and reattachment of the magnetic beads, which should slip along the wires, when the “collar” has to open or close, causing dysphagia or GER, respectively. Another cause of dysphagia is described in the subheading below.

### MSA complications similar to those of the Angelchik prosthesis

Even if the “magnetic collar”, hypothetically speaking, is blocked in the open position by fibrotic “encapsulation”, it could maintain its ability to prevent GER and could continue to perform a sort of barrier function against GER. The explanation of this phenomenon could be sought in a mechanism similar to that of another anti-reflux collar, which is unable to tighten or dilate: The “notorious” Angelchik prosthesis[33]. This prosthesis consisted of a collar with a circular section made of silicone that was surgically placed around the abdominal esophagus to prevent GER in the eighties of last century. The Angelchik prosthesis was used for almost 15 years, due to good results against reflux obtained in several studies[34-36]. Some prospective randomized trials demonstrated that the Angelchik prosthesis was as effective in preventing GER,



**Figure 2** Schematic drawing of the Linx magnetic augmentation device to insert around the abdominal portion of the esophagus in the open and closed position. A: Open position; B: Closed position. A-B: Citation: Bonavina L, Saino GI, Bona D, Lipham J, Ganz RA, Dunn D, DeMeester T. Magnetic augmentation of the lower esophageal sphincter: results of a feasibility clinical trial. *J Gastrointest Surg* 2008; 12: 2133-40. Copyright© The Authors 2020. Published by Springer Nature. The authors obtained permission for use of the figure from Springer Nature (Supplementary material).

as the Nissen fundoplication[37], and with similar 24-h pH monitoring results[38]. The anti-reflux mechanism of this device occurs through the prevention of LES unfolding, when challenged by an increase in intragastric pressure[39] and, mostly, through the “padding” action against the posterior wall of the abdominal esophagus, which creates a barrier to GER[40]. In this way it causes a high pressure zone at the LES level, which can be detected by manometry[34,36]. The “magnetic collar” MSA, just in the hypothesis that its function is hindered by fibrosis, could resemble a sort of Angelchik prosthesis made of metal, which would produce with its weight, a continuous pressure against the posterior wall of the abdominal esophagus, closing the lumen to reflux. However, this mechanism of the Angelchik prosthesis, on the one hand, could help to control GER, but, on the other hand, could represent an obstacle to bolus transit, causing persistent, and sometimes severe dysphagia[41]. This fact required the removal of the prosthesis in some cases[36,42] and was also responsible for some other more severe complications. In fact, a continuous compression of the plastic collar, leaning on the esophageal wall, in some cases also caused erosions, fistulas and perforations of the esophagus and stomach, that sometimes were followed by migration of the device into the gastric lumen[43-48]. These complications began to appear years after insertion of the prosthesis, but despite this, it continued to be implanted for years. In the first decade of the current century the Angelchik prosthesis, which had seemed to be a good alternative to Nissen fundoplication, was definitely shelved.

In a manner similar to that of the Angelchik prosthesis the MSA “magnetic collar” too, leaning on the distal esophageal wall, being also heavier, may induce ischemia and consequently may cause erosion of the wall. The latter complication may be revealed by persistent severe dysphagia[49,50] or odinophagia[51]. In some cases the device may protrude more or less deeply into the esophageal lumen[50-54]. The appearance of these complications requires device removal. In addition, a prolonged leaning of the MSA device against the esophageal wall was suspected, but without clear proof of being responsible, probably through a chronic foreign body reaction, for an adenocarcinoma found in the distal esophagus of a patient with the MSA device [55].

### **Causes and timing of MSA device removal**

MSA device removal, however, has been performed not only for the occurrence of erosions and device protrusion, but also for severe dysphagia, recurrent GER and epigastric pain. In a retrospective review[54], 5.5% of 435 patients undergoing MSA device implantation from 2009 to 2017 in a single institution, required removal, the most common reasons being recurrent GER (54%), dysphagia (38%), or erosion (8%). In a single referral center[12], 124 patients were followed up for 6 up to 12 years (median 9 years) after insertion of the MSA device, and 9.2% of patients required laparoscopic device removal for various reasons: The most frequent were erosions,

regurgitation, heartburn, and dysphagia, but also foreign body sensation, odinophagia, pharyngodynia, chronic cough and even the need for a magnetic resonance study. In another retrospective single center cohort study[31], after a median follow-up of 48 mo 6.7% of 164 patients were explanted. In almost half of cases this occurred due to recurrence of heartburn or regurgitation, followed by dysphagia, and, in the remainder of cases, due to chest pain and full-thickness erosion of the esophageal wall with partial penetration of the device. The majority of the removals occurred within two years after implantation[31], whereas for other investigators most cases of removal for erosion occurred between 1 and 4 years after device placement [56]. According to the commercial registries in the United States and Europe, the worldwide clinical experience of 497 magnetic implants established that the median duration was 2.9 years[5]. In another study[57], the median duration was 274 d in the first 1000 MSA implanted patients in 82 institutions, whereas Smith *et al*[58], consulting the MAUDE database from 2012 to 2016 regarding 3283 implanted patients, found that the median duration was 1.4 years and more than half of the removals occurred within the first year. In conclusion, removal was required in 5% to 9.2% of patients and occurred in the first few years after device placement mainly for dysphagia, recurrence of GERD symptoms and erosions and the duration varied from 274 d to 2.9 years. These differences in implant removal, as well as in the occurrence of adverse events, may be due to the fact that the number increases with time, and therefore the real number in retrospective reviews, likely depends on the follow-up duration. Moreover, it should also be kept in mind that different sizing protocols may play an important role in producing important data differences.

### **Procedures and consequences of the removal**

Furthermore, the operative management of the MSA device removal and especially its pathophysiologic consequences must be considered. The removal of the device was carried out using a single stage procedure[31], or, more rarely, in two stages: First endoscopically for the visible beads, then laparoscopically for the remaining beads within 3 mo after complete healing[51]. Tatum *et al*[53] reported that the MSA devices were removed through laparotomy (4%), laparoscopically (88%), or through a combination of endoscopy and laparoscopy (8%). After removal, these patients underwent repeated MSA (33%), fundoplication (21%), gastrectomy (4%), or no additional procedure (42%). Symptoms prompting removal of the MSA device were eliminated in 52% of patients and improved in an additional 35%, whereas in 13% of cases the symptoms persisted. As removal of the MSA device is followed not only by recurrent GER, but also by a delayed gastric emptying, prokinetics should be added to the medical therapy with a PPI[49] or surgical treatment with fundoplication[52]. The onset of delayed gastric emptying after removal may be easily explained by damage to the right branch of the vagus nerve, which runs along the posterior part of the abdominal esophagus. This is the region where the penetration and removal of the MSA device usually takes place. Apart from the occurrence of erosion and removal, the continuous friction and pressure of the rather heavy MSA “collar”, as well as the creation of the tunnel around the abdominal esophagus to insert it, both could damage or irritate the area of vagus nerve passage, with possible motor dysfunction of the stomach and intestine. A delay in gastric emptying induced by a lesion to the vagus nerve was found at the 6 mo follow-up in 125 patients after anti-reflux surgery[59]. Consequently, it would be interesting to perform a gastric emptying test before and 6 mo after the insertion of the MSA device in a group of patients undergoing the procedure, or at least in those complaining of dysphagia.

In conclusion, in patients subjected to MSA device insertion there are complications and adverse events, the occurrence of which shows great variability from one study to another. A possible explanation for this can be found in the different sizing protocols as well as in the duration of the follow-up. Some complications, such as dysphagia or GER could be considered related to a not so perfect adjustment of the MSA collar length or, when they appear or worsen after months, might perhaps be due to wrapping of the working mechanism of the device by a coating of fibrous tissue, which stiffens with time. Dysphagia may also be linked to the “collar” shape of the MSA device pressing with its weight on the posterior wall of the distal esophagus, as the Angelchik prosthesis does. This leaning of the “magnetic collar” on the distal esophageal wall may be responsible for more severe complications, which manifest themselves over time, such as erosions and device penetration through the esophageal wall. The consequent MSA device removal also leaves a functional aftermath at the gastro-esophageal junction as well as the stomach. Considering the trend over time of these latter complications, which in some way could recall to mind those of the Angelchik prosthesis, although much less severe, one might wonder if there may be a



risk that the the story of the latter will repeat itself with the “magnetic collar”, as was feared in an article in 2014[60]. However, I do not think this could happen, as the power of technology will not allow it.

## OTHER MAGNETIC TECHNIQUES TO PREVENT GER

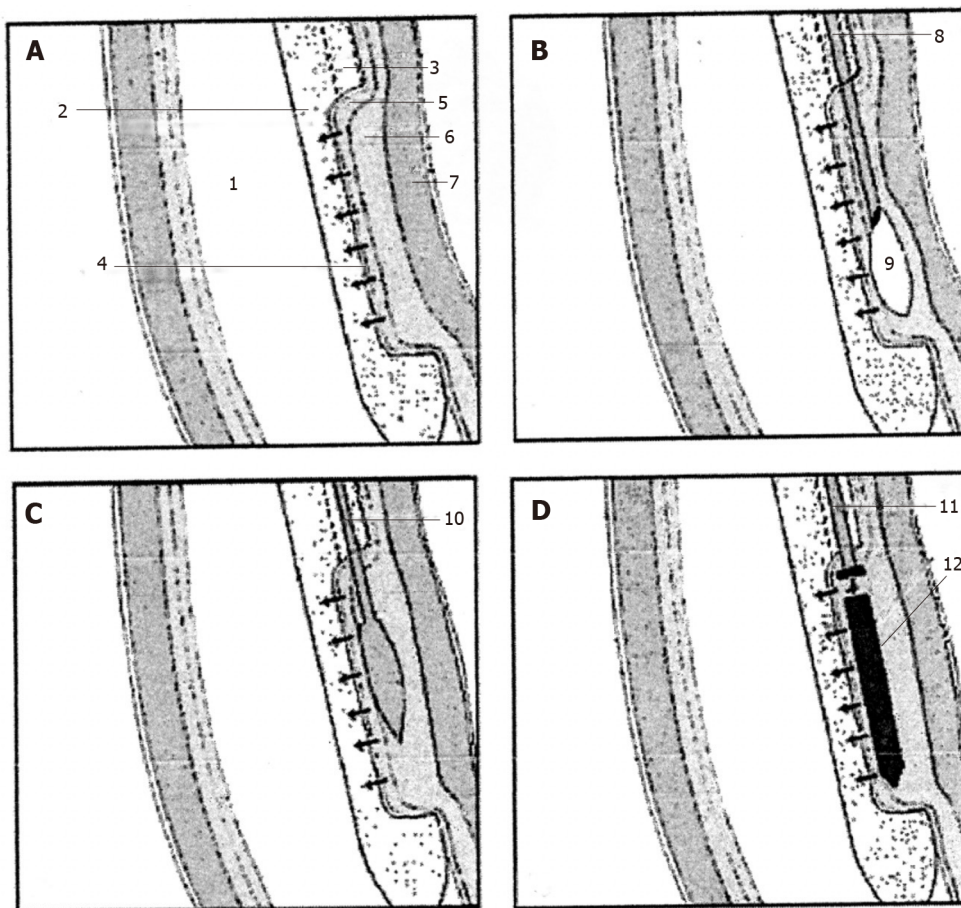
As previously mentioned, another way of exploiting magnetic force to prevent GER was devised in a bench-top study published in 2006[3]. As previously described, this system consisted of two small magnetic plaques, that, when applied in opposite positions around the abdominal esophagus, should attract each other, squeezing the LES, to prevent GER. These magnetic plaques are also capable of detaching themselves, when the endoluminal pressure increases above a determined value, to allow transit of the bolus. The pair of plaques should be surgically inserted at the LES level to form a magnetic valve with a dynamic closure that should be sufficient to prevent the reflux of contents, without the risk of fibrosis that blocks them in the open or closed position, since they are separated by the esophageal lumen.

Another experimental study was subsequently performed to evaluate the feasibility of this method[61]. Two small magnetic plaques (5 mm × 20 mm × 1.5 mm) made of plastroferrite were implanted by means of a special endoesophageal device (Figure 3) in two submucosal longitudinal tunnels in the opposite parts of the distal esophagus of esophago-gastric specimens taken from an “*ex vivo*” swine. The magnetic plaques with the opposite polarities facing, through a reciprocal attraction closed the esophageal lumen (Figure 4), creating a high-pressure zone. The latter was measured by a manometric catheter passed through the gastroesophageal junction, showing after five pull-throughs, a mean pressure ± SD of 14.2 ± 1.27 mmHg, which was significantly higher than the basal pressure of 1.5 ± 0.26 mmHg. This preliminary study suggests that it could be possible to create functional closure at the LES level with a pressure sufficient to prevent GER with a couple of magnetic plaques with various attraction forces, using a safe and simple endoscopic procedure.

A technique inspired by the one just described was devised by Dobashi *et al*[62]. In porcine models first “*ex vivo*” and then “*in vivo*”, two magnets of neodymium (3 mm × 12 mm) were endoscopically inserted with opposite polarities into two opposite sub-adventitial tunnels of the distal esophagus, with the aim of closing the lumen with their reciprocal attraction (Figure 5). The tunnels were created with the aid of blunt dissection by means of a biliary balloon catheter. Unfortunately, the tunnels “*in vivo*” were successful in only five of 10 pigs and the magnet augmentation device was functionally active in only 4 of them. In another study by the same investigator[63] neodymium ring magnets (4.8 OD × 1.6 ID mm and 1.6 mm thick) were endoscopically anchored to the esophageal mucosa with a suture anchor from a needle arm fixed full-thickness to the esophageal wall, to create a flap. Two to three magnets were placed in opposite positions at the LES level, to induce closure of the lumen with reciprocal attraction. This procedure was performed both in nine cadaveric and six surviving pigs. In the latter animals the mean LES pressure increased from 8.4 to 32.4 mmHg just after device placement. Repeated endoscopy after two weeks showed intact magnets in four of 6 animals with a persistent increase in LES pressure. These magnets can be easily removed, but low durability is expected and it is not known whether these magnetic rings are really capable of completely sealing the lumen. In conclusion, the first applications “*in vivo*” of these different endoluminal magnetic systems did not yield outstanding results and they clearly require further development. This deserves to be performed, as they present various advantages with respect to the “magnetic collar”.

### Advantages and shortcomings of the “two plaques system”

With regard to the working mechanism, the system based on a “collar” of magnets in the MSA device seems perfect at the work-bench, but, once inserted into a living organism, things change. In fact, the biological reaction could trouble its perfect functioning, wrapping the device by a coating of fibrous tissue, that with time become stiffer and could cause thus dysphagia or GER. The mechanism of the two magnetic plaques, instead is not subject to this possible drawback, because it does not have mechanical sliding parts, which could be blocked by the deposition of fibrin, possibly hindering the to and fro movements of the magnets. In fact, the attraction force acts through the lumen of the esophagus, so that the magnets are free to approach and separate. The fibrous coating on the magnets may also contribute to securing them in their crevice in the esophageal wall. Naturally, the magnetic plaques should be



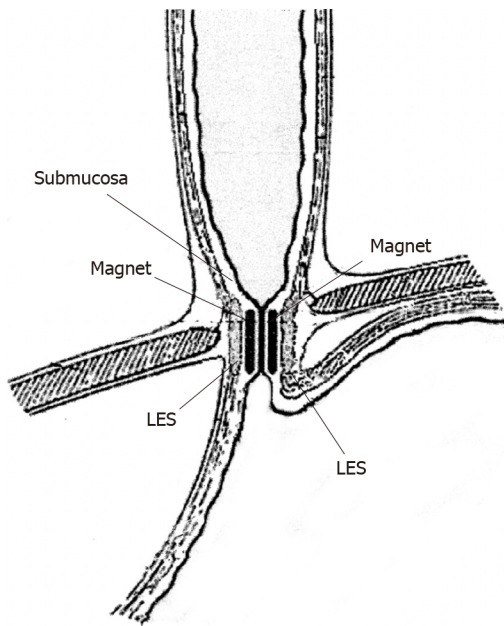
**Figure 3** Extremity of the special endoesophageal probe positioned at the LES level in a sequence of operations for the deployment of a magnetic plaque seen in profile. A: The mucosa of the distal esophagus is sucked onto the perforated wall of the operative chamber; B: The needle injects milliliters of saline solution to create a blister in the submucosa; C: The end of the catheter with a blunted bolt creates a pouch in the submucosa; D: The magnetic plaque (seen in profile) is pushed into the pouch. 1: Esophageal lumen; 2: Delivery probe; 3: Deployment channel; 4: Perforated wall of the aspiration chamber; 5: Mucosal layer; 6: Submucosal layer; 7: Muscular layer; 8: Needle-catheter; 9: Saline solution; 10: Bolt-catheter; 11: Magnetic plaque seen in profile. A-D: Citation: Bortolotti M, Grandis A, Mazzero G. A novel endoesophageal magnetic device to prevent gastroesophageal reflux. *Surg Endosc* 2009; 4: 885-9. Copyright© The Authors 2020. Published by Springer Nature. The authors obtained permission for use of the figure from Springer Nature (Supplementary material).

covered by a soft biomaterial to avoid undesirable reactions of the surrounding tissues and must have an appropriate force of attraction to close the lumen without causing ischemia and erosions of the underlying compressed tissues.

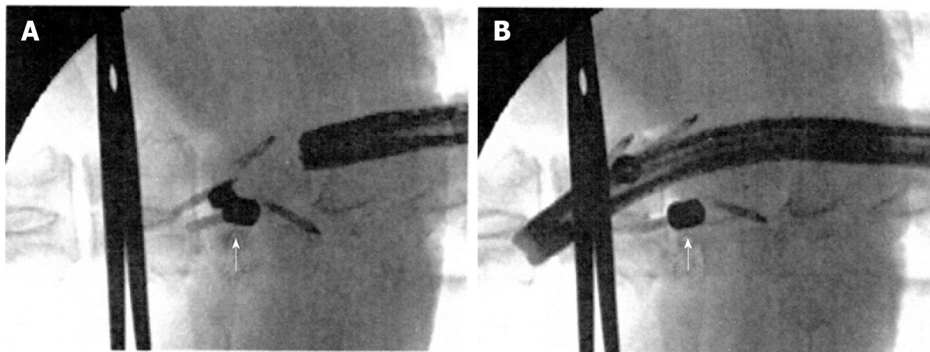
In this regard another advantage of the “two plaques system”, unlike the “magnetic collar” MSA, lies in the possibility of accurately establishing the force of closure by choosing magnets with different attraction forces for different conditions. In fact, the distance between the two plaques may vary from patient to patient and, therefore, their force of attraction varies with the square of the distance. Consequently, plaques with greater attraction force are required for greater distances, and *vice versa*. This system offers the possibility of choosing, even during insertion, the most suitable plaques by measuring with a manometric probe or other systems the endoluminal pressure obtained. The MSA “magnetic collar”, instead, always exerting the same force of attraction between the beads, could become less effective when the area to surround is large, thus facilitating reflux. The reverse could occur for small circumferences, with the creation of an obstacle to content transit and consequent dysphagia.

Furthermore, with the “two plaques system” it is possible to realize an anti-reflux device that can be inserted endoscopically, as described above. This possibility, assuming it works with the magnetic plaques, would cost much less than laparoscopy and the MSA device.

The drawback of this system lies in the fact that at the present time it is difficult to obtain a stable insertion of the plaques in the esophageal wall. The system by Dobashi *et al* [62] with a sub-adventitial tunnel seems to provide excellent fixing, but was followed by functional success in only four of 10 cases. The other system by Dobashi *et al* [63] with 2-3 ring magnets anchored to the distal esophageal wall like a flap was



**Figure 4** Schematic section following a vertical frontal plane through the lower portion of the esophago-gastric wall showing in profile the two magnetic plaques inserted face to face in the submucosal position at the lower esophageal sphincter level; these attracting each other close the gastro-esophageal junction. Citation: Bortolotti M, Grandis A, Mazzero G. A novel endoesophageal magnetic device to prevent gastroesophageal reflux. *Surg Endosc* 2009; 4: 885-9. Copyright© The Authors 2020. Published by Springer Nature. The authors obtained permission for use of the figure from Springer Nature ([Supplementary material](#)).



**Figure 5** Fluoroscopic view after insertion of the magnets. A: Magnets in the sub-adventitial space opposing the respective esophageal walls. A surgical clamp indicates the level of the esophago-gastric junction and the arrow indicates the magnets attracted to one another and closing the lumen; B: Magnets separated by the passage of the endoscope. The arrow indicates one of the magnets separated from the other. A-B: Citation: Modified from: Dobashi A, Wu SW, Deters JL, Miller CA, Knipschild MA, Cameron GP, Lu L, Rajan E, Gostout CJ. Endoscopic magnet placement into subadventitial tunnels for augmenting the lower esophageal sphincter using submucosal endoscopy: ex vivo and in vivo study in a porcine model (with video). *Gastrointest Endosc* 2019; 89: 422-428. Copyright© The Authors 2020. Published by Elsevier. The authors obtained permission for use of the figure from Elsevier ([Supplementary material](#)).

successful in only four of 6 surviving pigs after 2 wk. Furthermore, although it obtained a high endoluminal pressure, it may give the impression of not completely seal the esophageal lumen against reflux. The insertion of magnets in submucosal tunnels, chosen by Bortolotti *et al*[60], by means of a special endoesophageal device is easy to perform, but it requires a more stable fixing of the devices to the esophageal wall. A biologic glue and closure of the proximal mucosal opening by a surgical stitch, could avoid loss of the magnets. To date, no one has attempted to apply the couple of magnetic plaques outside the esophageal wall, in areas where the vagus nerve does not pass. Indeed, this idea poses considerable problems in fixing these plaques. The solution could be obtained by various expedients, such as suture anchors, surgical stitches and biological glue, whereas the magnetic plaques should have particular shapes, with hooks, holes for surgical threads *etc*. I am confident that a good solution for fixing the plaques outside the esophageal wall will be found by a skilled surgeon.

Please note that this system with two plaques could also be easily used to prevent fecal incontinence. A couple of the plaques may be surgically positioned on the right and left sides of the incontinent anal sphincter, with the opposite polarities facing each other, so that, by self-attracting they could keep the anal canal closed[64].

## CONCLUSION

Considering the clinical effectiveness and occurrence of more or less severe complications, one might wonder whether the magnetic anti-reflux device MSA actually represents an extraordinary progress with respect to Nissen fundoplication. One of the major criticisms to MSA studies is that up to now there has not been any randomized controlled trial which correctly compared the MSA results with those of Nissen fundoplication. However, considering the available studies, it can be said that the MSA system achieves a GER control roughly similar to that of fundoplication with the advantage of less gas bloating and a greater ability to vomit and belch. On the other hand, it has the disadvantage of more prolonged and severe dysphagia, requiring endoscopic dilatation more frequently and, in some cases, device removal[11]. The latter may also be necessary for some other severe complications, which are fortunately infrequent, such as mucosal erosions and device penetration through the esophageal wall.

It would be of concern if this “magnetic way” for GER treatment could meet the same fate as the Angelchik prosthesis, which tried to replace fundoplication, but after 15 years it was shelved due to numerous and severe complications. I believe this will not happen in this case, as “magnetic sphincters” represent a real progress in the surgical treatment of GER. I am convinced that the magnetic technique is not a spark in the dark followed by the full return of fundoplication for the following reasons: The MSA device is relatively easier to insert, whereas fundoplication, on the other hand, requires an expert surgeon for its perfect realization. In addition, I also believe that the upcoming “two magnetic plaques system” with submucosal or sub-adventitial tunnels, could be the future of the magnetic era. It is unfortunate that this magnetic system, which presents many advantages, is not yet available and calls for further experiments on animals and clinical trials in selected patients, to achieve sufficient reliability in order to enter into surgical practice. This new road appears to be a long one filled with obstacles, but I think it is worthwhile trying to continue, unless one wants to go further into the future by studying the possibility of biocompatible magnetic nanoparticles to be injected into two longitudinal sections of a weak sphincter facing one another and then magnetically oriented for the purpose to attract themselves along with the surrounding muscle, thus closing the lumen. Unfortunately this is still a dream, but dreams can sometimes come true.

## ACKNOWLEDGEMENTS

The author thanks Romano Bragaglia MD and Henry Monaco BA (Hons) for assistance in the English language and Andrea Lugli MSc for help with Tables and Figures composition.

## REFERENCES

- 1 **Diaz R**, Davalos G, Welsh LK, Portenier D, Guerron AD. Use of magnets in gastrointestinal surgery. *Surg Endosc* 2019; **33**: 1721-1730 [PMID: 30805789 DOI: 10.1007/s00464-019-06718-w]
- 2 **Chen H**, Ma T, Wang Y, Zhu HY, Feng Z, Wu RQ, Lv Y, Dong DH. Fedora-type magnetic compression anastomosis device for intestinal anastomosis. *World J Gastroenterol* 2020; **26**: 6614-6625 [PMID: 33268950 DOI: 10.3748/wjg.v26.i42.6614]
- 3 **Bortolotti M**. A novel antireflux device based on magnets. *J Biomech* 2006; **39**: 564-567 [PMID: 16309688 DOI: 10.1016/j.jbiomech.2004.10.035]
- 4 **Bonavina L**, Saino GI, Bona D, Lipham J, Ganz RA, Dunn D, DeMeester T. Magnetic augmentation of the lower esophageal sphincter: results of a feasibility clinical trial. *J Gastrointest Surg* 2008; **12**: 2133-2140 [PMID: 18846406 DOI: 10.1007/s11605-008-0698-1]
- 5 **Ganz RA**, Peters JH, Horgan S, Bemelman WA, Dunst CM, Edmundowicz SA, Lipham JC, Luketich JD, Melvin WS, Oelschlager BK, Schlack-Haerer SC, Smith CD, Smith CC, Dunn D, Taiganides PA. Esophageal sphincter device for gastroesophageal reflux disease. *N Engl J Med* 2013; **368**: 719-727 [PMID: 23425164 DOI: 10.1056/NEJMoa1205544]



- 6 **Saino G**, Bonavina L, Lipham JC, Dunn D, Ganz RA. Magnetic Sphincter Augmentation for Gastroesophageal Reflux at 5 Years: Final Results of a Pilot Study Show Long-Term Acid Reduction and Symptom Improvement. *J Laparoendosc Adv Surg Tech A* 2015; **25**: 787-792 [PMID: [26437027](#) DOI: [10.1089/lap.2015.0394](#)]
- 7 **Ganz RA**, Edmundowicz SA, Taiganides PA, Lipham JC, Smith CD, DeVault KR, Horgan S, Jacobsen G, Luketich JD, Smith CC, Schlack-Haerer SC, Kothari SN, Dunst CM, Watson TJ, Peters J, Oelschlagel BK, Perry KA, Melvin S, Bemelman WA, Smout AJ, Dunn D. Long-term Outcomes of Patients Receiving a Magnetic Sphincter Augmentation Device for Gastroesophageal Reflux. *Clin Gastroenterol Hepatol* 2016; **14**: 671-677 [PMID: [26044316](#) DOI: [10.1016/j.cgh.2015.05.028](#)]
- 8 **Rona KA**, Reynolds J, Schwameis K, Zehetner J, Samakar K, Oh P, Vong D, Sandhu K, Katkhouda N, Bildzukewicz N, Lipham JC. Efficacy of magnetic sphincter augmentation in patients with large hiatal hernias. *Surg Endosc* 2017; **31**: 2096-2102 [PMID: [27553803](#) DOI: [10.1007/s00464-016-5204-3](#)]
- 9 **Schwameis K**, Nikolic M, Morales Castellano DG, Steindl A, Macheck S, Kristo I, Zörner B, Schoppmann SF. Results of Magnetic Sphincter Augmentation for Gastroesophageal Reflux Disease. *World J Surg* 2018; **42**: 3263-3269 [PMID: [29619511](#) DOI: [10.1007/s00268-018-4608-8](#)]
- 10 **Louie BE**, Smith CD, Smith CC, Bell RCW, Gillian GK, Mandel JS, Perry KA, Birkenhagen WK, Taiganides PA, Dunst CM, McCollister HM, Lipham JC, Khaitan LK, Tsuda ST, Jobe BA, Kothari SN, Gould JC. Objective Evidence of Reflux Control After Magnetic Sphincter Augmentation: One Year Results From a Post Approval Study. *Ann Surg* 2019; **270**: 302-308 [PMID: [29697454](#) DOI: [10.1097/SLA.0000000000002789](#)]
- 11 **Sheu EG**, Rattner DW. Evaluation of the LINX antireflux procedure. *Curr Opin Gastroenterol* 2015; **31**: 334-338 [PMID: [26039726](#) DOI: [10.1097/MOG.0000000000000189](#)]
- 12 **Ferrari D**, Asti E, Lazzari V, Siboni S, Bernardi D, Bonavina L. Six to 12-year outcomes of magnetic sphincter augmentation for gastroesophageal reflux disease. *Sci Rep* 2020; **10**: 13753 [PMID: [32792508](#) DOI: [10.1038/s41598-020-70742-3](#)]
- 13 **Kahrilas PJ**, Dodds WJ, Hogan WJ. Effect of peristaltic dysfunction on esophageal volume clearance. *Gastroenterology* 1988; **94**: 73-80 [PMID: [3335301](#) DOI: [10.1016/0016-5085\(88\)90612-9](#)]
- 14 **Simorov A**, Ranade A, Jones R, Tadaki C, Shostrom V, Boilesen E, Oleynikov D. Long-term patient outcomes after laparoscopic anti-reflux procedures. *J Gastrointest Surg* 2014; **18**: 157-62; discussion 162 [PMID: [24234243](#) DOI: [10.1007/s11605-013-2401-4](#)]
- 15 **Bathla L**, Legner A, Tsuboi K, Mittal S. Efficacy and feasibility of laparoscopic redo fundoplication. *World J Surg* 2011; **35**: 2445-2453 [PMID: [21915744](#) DOI: [10.1007/s00268-011-1250-0](#)]
- 16 **Richards KF**, Fisher KS, Flores JH, Christensen BJ. Laparoscopic Nissen fundoplication: cost, morbidity, and outcome compared with open surgery. *Surg Laparosc Endosc* 1996; **6**: 140-143 [PMID: [8680637](#)]
- 17 **Fuchs KH**, Breithaupt W, Fein M, Maroske J, Hammer I. Laparoscopic Nissen repair: indications, techniques and long-term benefits. *Langenbecks Arch Surg* 2005; **390**: 197-202 [PMID: [15235916](#) DOI: [10.1007/s00423-004-0489-4](#)]
- 18 **Aiolfi A**, Asti E, Bernardi D, Bonitta G, Rausa E, Siboni S, Bonavina L. Early results of magnetic sphincter augmentation versus fundoplication for gastroesophageal reflux disease: Systematic review and meta-analysis. *Int J Surg* 2018; **52**: 82-88 [PMID: [29471155](#) DOI: [10.1016/j.ijssu.2018.02.041](#)]
- 19 **Skubleny D**, Switzer NJ, Dang J, Gill RS, Shi X, de Gara C, Birch DW, Wong C, Hutter MM, Karmali S. LINX® magnetic esophageal sphincter augmentation versus Nissen fundoplication for gastroesophageal reflux disease: a systematic review and meta-analysis. *Surg Endosc* 2017; **31**: 3078-3084 [PMID: [27981382](#) DOI: [10.1007/s00464-016-5370-3](#)]
- 20 **Riegler M**, Schoppman SF, Bonavina L, Ashton D, Horbach T, Kemen M. Magnetic sphincter augmentation and fundoplication for GERD in clinical practice: one-year results of a multicenter, prospective observational study. *Surg Endosc* 2015; **29**: 1123-1129 [PMID: [25171881](#) DOI: [10.1007/s00464-014-3772-7](#)]
- 21 **Reynolds JL**, Zehetner J, Nieh A, Bildzukewicz N, Sandhu K, Katkhouda N, Lipham JC. Charges, outcomes, and complications: a comparison of magnetic sphincter augmentation versus laparoscopic Nissen fundoplication for the treatment of GERD. *Surg Endosc* 2016; **30**: 3225-3230 [PMID: [26541730](#) DOI: [10.1007/s00464-015-4635-6](#)]
- 22 **Guidozzi N**, Wiggins T, Ahmed AR, Hanna GB, Markar SR. Laparoscopic magnetic sphincter augmentation versus fundoplication for gastroesophageal reflux disease: systematic review and pooled analysis. *Dis Esophagus* 2019; **32** [PMID: [31069388](#) DOI: [10.1093/dote/doz031](#)]
- 23 **Warren HF**, Reynolds JL, Lipham JC, Zehetner J, Bildzukewicz NA, Taiganides PA, Mickley J, Aye RW, Farivar AS, Louie BE. Multi-institutional outcomes using magnetic sphincter augmentation versus Nissen fundoplication for chronic gastroesophageal reflux disease. *Surg Endosc* 2016; **30**: 3289-3296 [PMID: [26541740](#) DOI: [10.1007/s00464-015-4659-y](#)]
- 24 **Sheu EG**, Nau P, Nath B, Kuo B, Rattner DW. A comparative trial of laparoscopic magnetic sphincter augmentation and Nissen fundoplication. *Surg Endosc* 2015; **29**: 505-509 [PMID: [25012804](#) DOI: [10.1007/s00464-014-3704-6](#)]
- 25 **Alicuben ET**, Tatum JM, Bildzukewicz N, Samakar K, Samaan JS, Silverstein EN, Sandhu K, Houghton CC, Lipham JC. Regression of intestinal metaplasia following magnetic sphincter augmentation device placement. *Surg Endosc* 2019; **33**: 576-579 [PMID: [30046950](#) DOI: [10.1007/s00464-018-6367-x](#)]
- 26 **Simonka Z**, Paszt A, Abrahám S, Pieler J, Tajti J, Tiszlavicz L, Németh I, Izbéki F, Rosztóczy A,

- Wittmann T, Rárosi F, Lázár G. The effects of laparoscopic Nissen fundoplication on Barrett's esophagus: long-term results. *Scand J Gastroenterol* 2012; **47**: 13-21 [PMID: [22150083](#) DOI: [10.3109/00365521.2011.639081](#)]
- 27 **Schizas D**, Mastoraki A, Papoutsis E, Giannakoulis VG, Kanavidis P, Tsilimigras D, Ntourakis D, Lyros O, Liakakos T, Moris D. LINX® reflux management system to bridge the "treatment gap" in gastroesophageal reflux disease: A systematic review of 35 studies. *World J Clin Cases* 2020; **8**: 294-305 [PMID: [32047777](#) DOI: [10.12998/wjcc.v8.i2.294](#)]
  - 28 **Ayazi S**, Zheng P, Zaidi AH, Chovanec K, Chowdhury N, Salvitti M, Komatsu Y, Omstead AN, Hoppo T, Jobe BA. Magnetic Sphincter Augmentation and Postoperative Dysphagia: Characterization, Clinical Risk Factors, and Management. *J Gastrointest Surg* 2020; **24**: 39-49 [PMID: [31388888](#) DOI: [10.1007/s11605-019-04331-9](#)]
  - 29 **Schwameis K**, Ayazi S, Zaidi AH, Hoppo T, Jobe BA. Development of pseudoachalasia following magnetic sphincter augmentation (MSA) with restoration of peristalsis after endoscopic dilation. *Clin J Gastroenterol* 2020; **13**: 697-702 [PMID: [32472375](#) DOI: [10.1007/s12328-020-01140-5](#)]
  - 30 **Ganz RA**, Gostout CJ, Grudem J, Swanson W, Berg T, DeMeester TR. Use of a magnetic sphincter for the treatment of GERD: a feasibility study. *Gastrointest Endosc* 2008; **67**: 287-294 [PMID: [18226691](#) DOI: [10.1016/j.gie.2007.07.027](#)]
  - 31 **Asti E**, Siboni S, Lazzari V, Bonitta G, Sironi A, Bonavina L. Removal of the Magnetic Sphincter Augmentation Device: Surgical Technique and Results of a Single-center Cohort Study. *Ann Surg* 2017; **265**: 941-945 [PMID: [27163959](#) DOI: [10.1097/SLA.0000000000001785](#)]
  - 32 **Harnsberger CR**, Broderick RC, Fuchs HF, Berducci M, Beck C, Gallo A, Jacobsen GR, Sandler BJ, Horgan S. Magnetic lower esophageal sphincter augmentation device removal. *Surg Endosc* 2015; **29**: 984-986 [PMID: [25119542](#) DOI: [10.1007/s00464-014-3757-6](#)]
  - 33 **Angelchik JP**, Cohen R. A new surgical procedure for the treatment of gastroesophageal reflux and hiatal hernia. *Surg Gynecol Obstet* 1979; **148**: 246-248 [PMID: [154176](#)]
  - 34 **Starling JR**, Reichelderfer MO, Pellett JR, Belzer FO. Treatment of symptomatic gastroesophageal reflux using the Angelchik prosthesis. *Ann Surg* 1982; **195**: 686-691 [PMID: [7082060](#) DOI: [10.1097/0000658-198206000-00002](#)]
  - 35 **Eyre-Brook IA**, Codling BW, Gear MW. Results of a prospective randomized trial of the Angelchik prosthesis and of a consecutive series of 119 patients. *Br J Surg* 1993; **80**: 602-604 [PMID: [8518898](#) DOI: [10.1002/bjbs.1800800517](#)]
  - 36 **Maddern GJ**, Myers JC, McIntosh N, Bridgewater FH, Jamieson GG. The effect of the Angelchik prosthesis on esophageal and gastric function. *Arch Surg* 1991; **126**: 1418-1422 [PMID: [1747057](#) DOI: [10.1001/archsurg.1991.01410350112018](#)]
  - 37 **Deakin M**, Mayer D, Temple JG. Surgery for gastro-oesophageal reflux: the Angelchik prosthesis compared to the floppy Nissen fundoplication. Two-year follow-up study and a five-year evaluation of the Angelchik prosthesis. *Ann R Coll Surg Engl* 1989; **71**: 249-252 [PMID: [2774454](#)]
  - 38 **Hill AD**, Walsh TN, Bolger CM, Byrne PJ, Hennessy TP. Randomized controlled trial comparing Nissen fundoplication and the Angelchik prosthesis. *Br J Surg* 1994; **81**: 72-74 [PMID: [8313128](#) DOI: [10.1002/bjbs.1800810124](#)]
  - 39 **Bonavina L**, DeMeester T, Mason R, Stein HJ, Feussner H, Evander A. Mechanical effect of the Angelchik prosthesis on the competency of the gastric cardia: pathophysiologic implications and surgical perspectives. *Dis Esophagus* 1997; **10**: 115-118 [PMID: [9179481](#) DOI: [10.1093/dote/10.2.115](#)]
  - 40 **Benjamin SB**, Knuff TK, Fink M, Woods E, Castell DO. The Angelchik antireflux prosthesis. Effects on the lower esophageal sphincter of primates. *Ann Surg* 1983; **197**: 63-67 [PMID: [6848055](#)]
  - 41 **Varshney S**, Kelly JJ, Branagan G, Somers SS, Kelly JM. Angelchik prosthesis revisited. *World J Surg* 2002; **26**: 129-133 [PMID: [11898046](#) DOI: [10.1007/s00268-001-0192-3](#)]
  - 42 **Stuart RC**, Dawson K, Keeling P, Byrne PJ, Hennessy TP. A prospective randomized trial of angelchik prosthesis versus Nissen fundoplication. *Br J Surg* 1989; **76**: 86-89 [PMID: [2645016](#) DOI: [10.1002/bjbs.1800760127](#)]
  - 43 **Albin J**, Noel T, Allan K, Khalil KG. Intrathoracic esophageal perforation with the Angelchik antireflux prosthesis: report of a new complication. *Gastrointest Radiol* 1985; **10**: 330-332 [PMID: [4054497](#) DOI: [10.1007/BF01893123](#)]
  - 44 **Massaioli N**, Bertero D, Buzio M, Mecozzi B, Albertino B, Mosca A. [Endogastric migration of an Angelchik prosthesis. A case report and review of the literature]. *Minerva Chir* 1990; **45**: 189-194 [PMID: [2192307](#)]
  - 45 **Pence MM**, Hubbard M, Singla MB, Young PE. Esophagogastric Fistula Caused by an Angelchik Antireflux Prosthesis. *ACG Case Rep J* 2015; **2**: 213-215 [PMID: [26203442](#) DOI: [10.14309/crj.2015.62](#)]
  - 46 **Kauten JR**, Mansour KA. Complications of the Angelchik prosthesis in the management of gastroesophageal reflux. *Am Surg* 1986; **52**: 208-213 [PMID: [3954273](#)]
  - 47 **Benjamin SB**, Kerr R, Cohen D, Motaparthy V, Castell DO. Complications of the Angelchik antireflux prosthesis. *Ann Intern Med* 1984; **100**: 570-5 [PMID: [6367581](#) DOI: [10.7326/0003-4819-100-4-570](#)]
  - 48 **Smith RS**, Chang FC, Hayes KA, deBakker J. Complications of the Angelchik antireflux prosthesis. A community experience. *Am J Surg* 1985; **150**: 735-738 [PMID: [4073367](#) DOI: [10.1016/0002-9610\(85\)90419-2](#)]
  - 49 **Stetler JL**, Gill S, Patel A, Davis SS Jr, Lin E. Surgical Technique for Laparoscopic Removal of a

- Magnetic Lower Esophageal Sphincter Augmentation Device. *J Laparoendosc Adv Surg Tech A* 2015; 1025-1028 [PMID: 26584252 DOI: 10.1089/lap.2015.0460]
- 50 **Bauer M**, Meining A, Kranzfelder M, Jell A, Schirren R, Wilhelm D, Friess H, Feussner H. Endoluminal perforation of a magnetic antireflux device. *Surg Endosc* 2015; **29**: 3806-3810 [PMID: 25877789 DOI: 10.1007/s00464-015-4145-6]
  - 51 **Parmar AD**, Tessler RA, Chang HY, Svahn JD. Two-Stage Explantation of a Magnetic Lower Esophageal Sphincter Augmentation Device Due to Esophageal Erosion. *J Laparoendosc Adv Surg Tech A* 2017; **27**: 829-833 [PMID: 28488920 DOI: 10.1089/lap.2017.0153]
  - 52 **Salvador R**, Costantini M, Capovilla G, Polese L, Merigliano S. Esophageal Penetration of the Magnetic Sphincter Augmentation Device: History Repeats Itself. *J Laparoendosc Adv Surg Tech A* 2017; **27**: 834-838 [PMID: 28586287 DOI: 10.1089/lap.2017.0182]
  - 53 **Yeung BPM**, Fullarton G. Endoscopic removal of an eroded magnetic sphincter augmentation device. *Endoscopy* 2017; **49**: 718-719 [PMID: 28558405 DOI: 10.1055/s-0043-109236]
  - 54 **Tatum JM**, Alicuben E, Bildzukewicz N, Samakar K, Houghton CC, Lipham JC. Removing the magnetic sphincter augmentation device: operative management and outcomes. *Surg Endosc* 2019; **33**: 2663-2669 [PMID: 30386987 DOI: 10.1007/s00464-018-6544-y]
  - 55 **Stadlhuber RJ**, Dubecz A, Meining A, Stein HJ. Adenocarcinoma of the Distal Esophagus in a Patient With a Magnetic Sphincter Augmentation Device: First of Many to Come? *Ann Thorac Surg* 2015; **99**: e147-e148 [PMID: 26046907 DOI: 10.1016/j.athoracsur.2015.03.063]
  - 56 **Alicuben ET**, Bell RCW, Jobe BA, Buckley FP 3rd, Daniel Smith C, Graybeal CJ, Lipham JC. Worldwide Experience with Erosion of the Magnetic Sphincter Augmentation Device. *J Gastrointest Surg* 2018; **22**: 1442-1447 [PMID: 29667094 DOI: 10.1007/s11605-018-3775-0]
  - 57 **Lipham JC**, Taiganides PA, Louie BE, Ganz RA, DeMeester TR. Safety analysis of first 1000 patients treated with magnetic sphincter augmentation for gastroesophageal reflux disease. *Dis Esophagus* 2015; **28**: 305-311 [PMID: 24612509 DOI: 10.1111/dote.12199]
  - 58 **Smith CD**, Ganz RA, Lipham JC, Bell RC, Rattner DW. Lower Esophageal Sphincter Augmentation for Gastroesophageal Reflux Disease: The Safety of a Modern Implant. *J Laparoendosc Adv Surg Tech A* 2017; **27**: 586-591 [PMID: 28430558 DOI: 10.1089/lap.2017.0025]
  - 59 **van Rijn S**, Rinsma NF, van Herwaarden-Lindeboom MY, Ringers J, Gooszen HG, van Rijn PJ, Veenendaal RA, Conchillo JM, Bouvy ND, Masclee AA. Effect of Vagus Nerve Integrity on Short and Long-Term Efficacy of Antireflux Surgery. *Am J Gastroenterol* 2016; **111**: 508-515 [PMID: 26977759 DOI: 10.1038/ajg.2016.42]
  - 60 **Bortolotti M**. The "magnetic collar": the ultimate solution for gastroesophageal reflux? *Scand J Gastroenterol* 2014; **49**: 511-512 [PMID: 24460023 DOI: 10.3109/00365521.2013.878383]
  - 61 **Bortolotti M**, Grandis A, Mazzero G. A novel endoesophageal magnetic device to prevent gastroesophageal reflux. *Surg Endosc* 2009; **23**: 885-889 [PMID: 19116748 DOI: 10.1007/s00464-008-0244-y]
  - 62 **Dobashi A**, Wu SW, Deters JL, Miller CA, Knipschildt MA, Cameron GP, Lu L, Rajan E, Gostout CJ. Endoscopic magnet placement into subadventitial tunnels for augmenting the lower esophageal sphincter using submucosal endoscopy: ex vivo and in vivo study in a porcine model (with video). *Gastrointest Endosc* 2019; **89**: 422-428 [PMID: 30261170 DOI: 10.1016/j.gie.2018.09.015]
  - 63 **Dobashi A**, Deters JL, Miller CA, Lavey CJ, Rajan E. Magnet-assist endoscopic augmentation of the lower esophageal sphincter for treatment of gastroesophageal reflux disease: cadaveric and survival studies in a porcine model (with video). *Surg Endosc* 2021; **35**: 4478-4484 [PMID: 33048232 DOI: 10.1007/s00464-020-07954-1]
  - 64 **Bortolotti M**, Ugolini G, Grandis A, Montroni I, Mazzero G. A novel magnetic device to prevent fecal incontinence (preliminary study). *Int J Colorectal Dis* 2008; **23**: 499-501 [PMID: 18231796 DOI: 10.1007/s00384-008-0437-9]



Published by **Baishideng Publishing Group Inc**  
7041 Koll Center Parkway, Suite 160, Pleasanton, CA 94566, USA

**Telephone:** +1-925-3991568

**E-mail:** [bpgoffice@wjgnet.com](mailto:bpgoffice@wjgnet.com)

**Help Desk:** <https://www.f6publishing.com/helpdesk>

<https://www.wjgnet.com>

