

# World Journal of *Clinical Cases*

*World J Clin Cases* 2021 November 16; 9(32): 9699-10051



## Contents

Thrice Monthly Volume 9 Number 32 November 16, 2021

## REVIEW

- 9699 Emerging role of long noncoding RNAs in recurrent hepatocellular carcinoma  
*Fang Y, Yang Y, Li N, Zhang XL, Huang HF*

## MINIREVIEWS

- 9711 Current treatment strategies for patients with only peritoneal cytology positive stage IV gastric cancer  
*Bausys A, Gricius Z, Aniukstyte L, Luksta M, Bickaite K, Bausys R, Strupas K*

## ORIGINAL ARTICLE

## Case Control Study

- 9722 Botulinum toxin associated with fissurectomy and anoplasty for hypertonic chronic anal fissure: A case-control study  
*D'Orazio B, Geraci G, Famà F, Terranova G, Di Vita G*
- 9731 Correlation between circulating endothelial cell level and acute respiratory distress syndrome in postoperative patients  
*Peng M, Yan QH, Gao Y, Zhang Z, Zhang Y, Wang YF, Wu HN*

## Retrospective Study

- 9741 Effects of early rehabilitation in improvement of paediatric burnt hands function  
*Zhou YQ, Zhou JY, Luo GX, Tan JL*
- 9752 Intracortical screw insertion plus limited open reduction in treating type 31A3 irreducible intertrochanteric fractures in the elderly  
*Huang XW, Hong GQ, Zuo Q, Chen Q*
- 9762 Treatment effects and periodontal status of chronic periodontitis after routine Er:YAG laser-assisted therapy  
*Gao YZ, Li Y, Chen SS, Feng B, Wang H, Wang Q*
- 9770 Risk factors for occult metastasis detected by inflammation-based prognostic scores and tumor markers in biliary tract cancer  
*Hashimoto Y, Ajiki T, Yanagimoto H, Tsugawa D, Shinozaki K, Toyama H, Kido M, Fukumoto T*
- 9783 Scapular bone grafting with allograft pin fixation for repair of bony Bankart lesions: A biomechanical study  
*Lu M, Li HP, Liu YJ, Shen XZ, Gao F, Hu B, Liu YF*
- 9792 High-resolution computed tomography findings independently predict epidermal growth factor receptor mutation status in ground-glass nodular lung adenocarcinoma  
*Zhu P, Xu XJ, Zhang MM, Fan SF*

- 9804** Colorectal cancer patients in a tertiary hospital in Indonesia: Prevalence of the younger population and associated factors

*Makmun D, Simadibrata M, Abdullah M, Syam AF, Shatri H, Fauzi A, Renaldi K, Maulahela H, Utari AP, Pribadi RR, Muzellina VN, Nursyirwan SA*

- 9815** Association between *Helicobacter pylori* infection and food-specific immunoglobulin G in Southwest China

*Liu Y, Shuai P, Liu YP, Li DY*

- 9825** Systemic immune inflammation index, ratio of lymphocytes to monocytes, lactate dehydrogenase and prognosis of diffuse large B-cell lymphoma patients

*Wu XB, Hou SL, Liu H*

### Clinical Trials Study

- 9835** Evaluating the efficacy of endoscopic sphincterotomy on biliary-type sphincter of Oddi dysfunction: A retrospective clinical trial

*Ren LK, Cai ZY, Ran X, Yang NH, Li XZ, Liu H, Wu CW, Zeng WY, Han M*

### Observational Study

- 9847** Management of pouch related symptoms in patients who underwent ileal pouch anal anastomosis surgery for adenomatous polyposis

*Gilad O, Rosner G, Brazowski E, Kariv R, Gluck N, Strul H*

- 9857** Presepsin as a biomarker for risk stratification for acute cholangitis in emergency department: A single-center study

*Zhang HY, Lu ZQ, Wang GX, Xie MR, Li CS*

### Prospective Study

- 9869** Efficacy of Yiqi Jianpi anti-cancer prescription combined with chemotherapy in patients with colorectal cancer after operation

*Li Z, Yin DF, Wang W, Zhang XW, Zhou LJ, Yang J*

### META-ANALYSIS

- 9878** Arthroplasty vs proximal femoral nails for unstable intertrochanteric femoral fractures in elderly patients: a systematic review and meta-analysis

*Chen WH, Guo WX, Gao SH, Wei QS, Li ZQ, He W*

### CASE REPORT

- 9889** Synchronous multiple primary malignancies of the esophagus, stomach, and jejunum: A case report

*Li Y, Ye LS, Hu B*

- 9896** Idiopathic acute superior mesenteric venous thrombosis after renal transplantation: A case report

*Zhang P, Li XJ, Guo RM, Hu KP, Xu SL, Liu B, Wang QL*

- 9903** Next-generation sequencing technology for diagnosis and efficacy evaluation of a patient with visceral leishmaniasis: A case report

*Lin ZN, Sun YC, Wang JP, Lai YL, Sheng LX*

- 9911** Cerebral air embolism complicating transbronchial lung biopsy: A case report  
*Herout V, Brat K, Richter S, Cundrle Jr I*
- 9917** Isolated synchronous Virchow lymph node metastasis of sigmoid cancer: A case report  
*Yang JQ, Shang L, Li LP, Jing HY, Dong KD, Jiao J, Ye CS, Ren HC, Xu QF, Huang P, Liu J*
- 9926** Clinical presentation and management of drug-induced gingival overgrowth: A case series  
*Fang L, Tan BC*
- 9935** Adult with mass burnt lime aspiration: A case report and literature review  
*Li XY, Hou HJ, Dai B, Tan W, Zhao HW*
- 9942** Massive hemothorax due to intercostal arterial bleeding after percutaneous catheter removal in a multiple-trauma patient: A case report  
*Park C, Lee J*
- 9948** Hemolymphangioma with multiple hemangiomas in liver of elderly woman with history of gynecological malignancy: A case report  
*Wang M, Liu HF, Zhang YZZ, Zou ZQ, Wu ZQ*
- 9954** Rare location and drainage pattern of right pulmonary veins and aberrant right upper lobe bronchial branch: A case report  
*Wang FQ, Zhang R, Zhang HL, Mo YH, Zheng Y, Qiu GH, Wang Y*
- 9960** Respiratory failure after scoliosis correction surgery in patients with Prader-Willi syndrome: Two case reports  
*Yoon JY, Park SH, Won YH*
- 9970** Computed tomography-guided chemical renal sympathetic nerve modulation in the treatment of resistant hypertension: A case report  
*Luo G, Zhu JJ, Yao M, Xie KY*
- 9977** Large focal nodular hyperplasia is unresponsive to arterial embolization: A case report  
*Ren H, Gao YJ, Ma XM, Zhou ST*
- 9982** Fine-needle aspiration cytology of an intrathyroidal nodule diagnosed as squamous cell carcinoma: A case report  
*Yu JY, Zhang Y, Wang Z*
- 9990** Extensive abdominal lymphangiomatosis involving the small bowel mesentery: A case report  
*Alhasan AS, Daqqaq TS*
- 9997** Gastrointestinal symptoms as the first sign of chronic granulomatous disease in a neonate: A case report  
*Meng EY, Wang ZM, Lei B, Shang LH*
- 10006** Screw penetration of the iliopsoas muscle causing late-onset pain after total hip arthroplasty: A case report  
*Park HS, Lee SH, Cho HM, Choi HB, Jo S*

- 10013** Uretero-lumbar artery fistula: A case report  
*Chen JJ, Wang J, Zheng QG, Sun ZH, Li JC, Xu ZL, Huang XJ*
- 10018** Rare mutation in MKRN3 in two twin sisters with central precocious puberty: Two case reports  
*Jiang LQ, Zhou YQ, Yuan K, Zhu JF, Fang YL, Wang CL*
- 10024** Primary mucosal-associated lymphoid tissue extranodal marginal zone lymphoma of the bladder from an imaging perspective: A case report  
*Jiang ZZ, Zheng YY, Hou CL, Liu XT*
- 10033** Focal intramural hematoma as a potential pitfall for iatrogenic aortic dissection during subclavian artery stenting: A case report  
*Zhang Y, Wang JW, Jin G, Liang B, Li X, Yang YT, Zhan QL*
- 10040** Ventricular tachycardia originating from the His bundle: A case report  
*Zhang LY, Dong SJ, Yu HJ, Chu YJ*
- 10046** Posthepatectomy jaundice induced by paroxysmal nocturnal hemoglobinuria: A case report  
*Liang HY, Xie XD, Jing GX, Wang M, Yu Y, Cui JF*

**ABOUT COVER**

Editorial Board Member of *World Journal of Clinical Cases*, Jalaj Garg, FACC, MD, Academic Research, Assistant Professor, Division of Cardiology, Medical College of Wisconsin, Milwaukee, WI 53226, United States.  
garg.jalaj@yahoo.com

**AIMS AND SCOPE**

The primary aim of *World Journal of Clinical Cases* (WJCC, *World J Clin Cases*) is to provide scholars and readers from various fields of clinical medicine with a platform to publish high-quality clinical research articles and communicate their research findings online.

WJCC mainly publishes articles reporting research results and findings obtained in the field of clinical medicine and covering a wide range of topics, including case control studies, retrospective cohort studies, retrospective studies, clinical trials studies, observational studies, prospective studies, randomized controlled trials, randomized clinical trials, systematic reviews, meta-analysis, and case reports.

**INDEXING/ABSTRACTING**

The WJCC is now indexed in Science Citation Index Expanded (also known as SciSearch®), Journal Citation Reports/Science Edition, Scopus, PubMed, and PubMed Central. The 2021 Edition of Journal Citation Reports® cites the 2020 impact factor (IF) for WJCC as 1.337; IF without journal self cites: 1.301; 5-year IF: 1.742; Journal Citation Indicator: 0.33; Ranking: 119 among 169 journals in medicine, general and internal; and Quartile category: Q3. The WJCC's CiteScore for 2020 is 0.8 and Scopus CiteScore rank 2020: General Medicine is 493/793.

**RESPONSIBLE EDITORS FOR THIS ISSUE**

Production Editor: Jia-Hui Li; Production Department Director: Yu-Jie Ma; Editorial Office Director: Jin-Lei Wang.

**NAME OF JOURNAL**

*World Journal of Clinical Cases*

**ISSN**

ISSN 2307-8960 (online)

**LAUNCH DATE**

April 16, 2013

**FREQUENCY**

Thrice Monthly

**EDITORS-IN-CHIEF**

Dennis A Bloomfield, Sandro Vento, Bao-Gan Peng

**EDITORIAL BOARD MEMBERS**

<https://www.wjgnet.com/2307-8960/editorialboard.htm>

**PUBLICATION DATE**

November 16, 2021

**COPYRIGHT**

© 2021 Baishideng Publishing Group Inc

**INSTRUCTIONS TO AUTHORS**

<https://www.wjgnet.com/bpg/gerinfo/204>

**GUIDELINES FOR ETHICS DOCUMENTS**

<https://www.wjgnet.com/bpg/GerInfo/287>

**GUIDELINES FOR NON-NATIVE SPEAKERS OF ENGLISH**

<https://www.wjgnet.com/bpg/gerinfo/240>

**PUBLICATION ETHICS**

<https://www.wjgnet.com/bpg/GerInfo/288>

**PUBLICATION MISCONDUCT**

<https://www.wjgnet.com/bpg/gerinfo/208>

**ARTICLE PROCESSING CHARGE**

<https://www.wjgnet.com/bpg/gerinfo/242>

**STEPS FOR SUBMITTING MANUSCRIPTS**

<https://www.wjgnet.com/bpg/GerInfo/239>

**ONLINE SUBMISSION**

<https://www.f6publishing.com>





Retrospective Study

# Scapular bone grafting with allograft pin fixation for repair of bony Bankart lesions: A biomechanical study

Ming Lu, Hai-Peng Li, Yu-Jie Liu, Xue-Zhen Shen, Feng Gao, Bo Hu, Yu-Feng Liu

**ORCID number:** Ming Lu 0000-0002-6595-9875; Hai-Peng Li 0000-0003-0620-6360; Yu-Jie Liu 0000-0001-5949-9545; Xue-Zhen Shen 0000-0002-1989-8565; Feng Gao 0000-0003-3017-4434; Bo Hu 0000-0003-4813-5476; Yu-Feng Liu 0000-0003-2430-225X.

**Author contributions:** Lu M and Liu YJ designed and performed the study; Lu M and Li HP analyzed the data; Lu M wrote the paper and revised the manuscript for final submission; Shen XZ, Gao F, Hu B, and Liu YF participated in the processing of cadaver shoulder joint specimens and biomechanical experiments.

**Supported by** PLA General Logistics Department, No. CWS14J067.

**Institutional review board statement:** The study was reviewed and approved by the Chinese PLA General Hospital Institutional Review Board.

**Informed consent statement:** All study participants, or their legal guardian, provided informed written consent prior to study enrollment.

**Conflict-of-interest statement:** We declare that we have no financial or personal relationships with

Ming Lu, Yu-Feng Liu, Medical School of Chinese PLA, Beijing 100853, China

Ming Lu, The Fourth Comprehensive Service and Support Center, The PLA Beijing Administration of Veterans Service Affairs Department, Beijing 100191, China

Hai-Peng Li, Yu-Jie Liu, Department of Orthopedics, The Fourth Medical Center, Chinese PLA General Hospital, Beijing 100853, China

Xue-Zhen Shen, Capital Medical University Beijing Luhe Hospital, Beijing 100000, China

Feng Gao, National Institute of Sports Medicine, Beijing 100000, China

Bo Hu, The Second Department of Orthopedics, Beijing Chaoyang Integrative Medicine Emergency Medical Center, Beijing 100022, China

**Corresponding author:** Yu-Jie Liu, MD, Professor, Department of Orthopedics, The Fourth Medical Center, Chinese PLA General Hospital, No. 51 Fucheng Road, Haidian District, Beijing 100853, China. [13701356381@163.com](mailto:13701356381@163.com)

## Abstract

### BACKGROUND

Severe bony Bankart lesions are a difficult challenge in clinical treatment and research. The current treatment methods consist mostly of Latarjet-Bristow surgery and its modified procedures. While good results have been achieved, there are also complications such as coracoid fracture, bone graft displacement, and vascular and nerve injury.

### AIM

To analyze the techniques and biomechanical properties of transversely fixing a bone block from the scapular spine using bone allograft pins with suture threads to repair bony Bankart lesions.

### METHODS

Fresh human shoulder joint specimens and a cadaver specimen model for scapular bone grafting with allograft pin fixation for repair of bony Bankart lesions were used. When the humeral rotation angles were 0°, 30°, 60° and 90°, and the axial loads were 30 N, 40 N, and 50 N, the humerus displacement was studied by biomechanical experiments.

other individuals or organizations that can inappropriately influence our work and that there is no professional or other personal interest of any nature in any product, service and/or company that could be construed as influencing the position presented in or the review of the manuscript.

**Data sharing statement:** Technical appendix, statistical code, and dataset available from the corresponding author at email address: [13701356381@163.com](mailto:13701356381@163.com). Participants gave informed consent for data sharing.

**Open-Access:** This article is an open-access article that was selected by an in-house editor and fully peer-reviewed by external reviewers. It is distributed in accordance with the Creative Commons Attribution NonCommercial (CC BY-NC 4.0) license, which permits others to distribute, remix, adapt, build upon this work non-commercially, and license their derivative works on different terms, provided the original work is properly cited and the use is non-commercial. See: <http://creativecommons.org/licenses/by-nc/4.0/>

**Specialty type:** Orthopedics

**Country/Territory of origin:** China

**Peer-review report's scientific quality classification**

Grade A (Excellent): 0  
Grade B (Very good): B  
Grade C (Good): 0  
Grade D (Fair): 0  
Grade E (Poor): 0

**Received:** June 6, 2021

**Peer-review started:** June 6, 2021

**First decision:** July 5, 2021

**Revised:** August 13, 2021

**Accepted:** August 27, 2021

**Article in press:** August 27, 2021

**Published online:** November 16, 2021

**P-Reviewer:** Kanematsu R

**S-Editor:** Wang JL

**L-Editor:** Wang TQ

**P-Editor:** Liu JH

## RESULTS

When the angle of external rotation of the humerus was 0°, 30°, 60°, and 90°, with axial loads of 30 N, 40 N, and 50 N, the data of the normal control group, allograft pin repair group, and titanium alloy hollow screw repair group were compared with each other by the *q*-test, which showed that there were no statistically differences among the three groups ( $P > 0.05$ ).

## CONCLUSION

The joints repaired with bone block from the scapular spine transversely fixed with allograft bony pins to repair bony Bankart lesions show good mechanical stability. The bone block has similar properties to normal glenohumeral joints in terms of biomechanical stability.

**Key Words:** Bankart lesion; Scapular spine; Allograft bone; Biomechanical

©The Author(s) 2021. Published by Baishideng Publishing Group Inc. All rights reserved.

**Core Tip:** Severe bony Bankart lesions are a difficult challenge in clinical treatment and research. The feasibility of using scapular spine graft bone allograft pins to repair Bankart lesions of the shoulder joint, and its biomechanical experimental results were preliminarily evaluated. This study found that the joints repaired with bone block from the scapular spine transversely fixed with allograft bony pins to repair bony Bankart lesions show good mechanical stability. This new method has no adverse effects on the bone donor area, avoiding the complications of coracoid extraction.

**Citation:** Lu M, Li HP, Liu YJ, Shen XZ, Gao F, Hu B, Liu YF. Scapular bone grafting with allograft pin fixation for repair of bony Bankart lesions: A biomechanical study. *World J Clin Cases* 2021; 9(32): 9783-9791

**URL:** <https://www.wjgnet.com/2307-8960/full/v9/i32/9783.htm>

**DOI:** <https://dx.doi.org/10.12998/wjcc.v9.i32.9783>

## INTRODUCTION

The shoulder joint is a typical multiaxial ball-and-socket joint. The humeral head is approximately spherical, and the glenoid is small and shallow[1]. This structure gives the shoulder joint greater flexibility. However, this structure also leads to a decrease in joint stability results[1]. Consequently, when the shoulder joint is dislocated, anteroinferior glenohumeral dislocation occurs[1]. Patients with primary traumatic anterior dislocation of the glenohumeral joint often develop redislocation[2,3]. Bony Bankart injury is traumatic avulsion of the glenoid labrum, or it indicates recurrent shoulder instability with a large bone defect due to anterior or anteroinferior shoulder dislocation. In clinical practice, 5.4% to 70% of shoulder instability cases result from traumatic factors[4-8]. The current treatments for bony Bankart injury, especially severe bony Bankart injury, mainly include open and arthroscopic Bristow-Latarjet surgeries[6]. Since the coracoid process serves as the donor area for bone grafting, some important structures such as the coracoacromial arch and pectoralis minor muscle can be damaged, resulting in shoulder joint instability and arthritis[9-12].

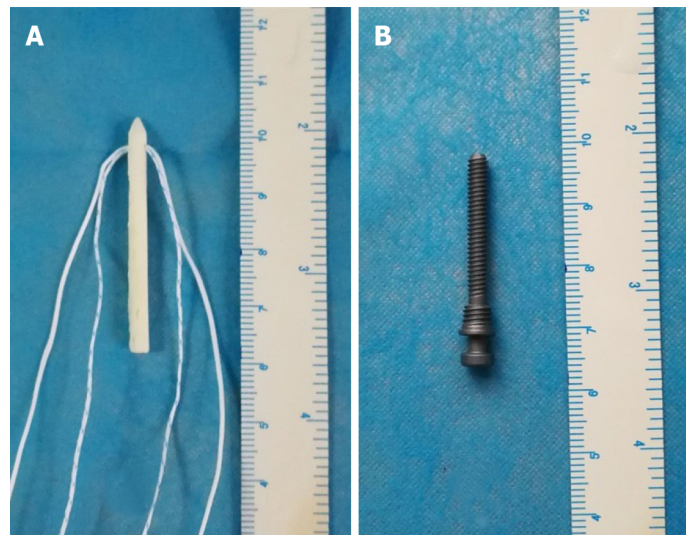
We proposed a new method of glenoid reconstruction using an autologous scapular bone graft from the scapular spine, which is trimmed and grafted into the glenoid defect following transfixation with bone allograft pins. In the present study, the feasibility and biomechanical properties of this surgical method were preliminarily evaluated using fresh human shoulder joint specimens.

## MATERIALS AND METHODS

### Specimen preparation and repair

There were 16 titanium alloy hollow screws (Figure 1A) and 16 allograft pins



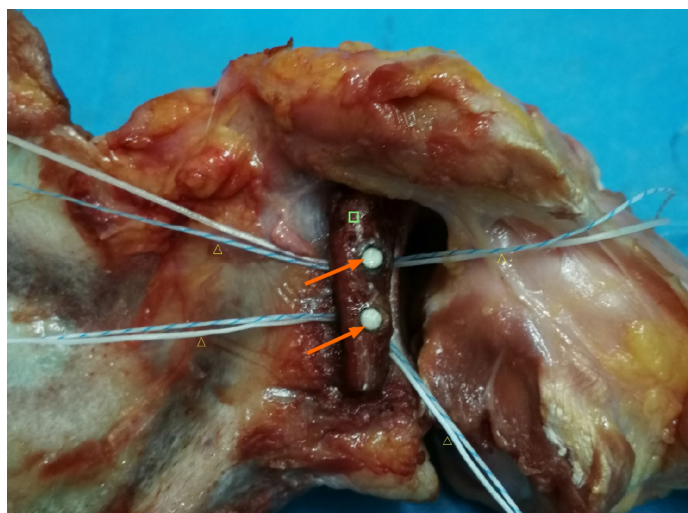


**Figure 1** Allograft pin with suture thread and titanium alloy hollow screw. A: Titanium alloy hollow screw; B: Allograft pin.


(Figure 1B) with suture threads. Twenty-four fresh human shoulder joint specimens were randomized into a titanium alloy hollow screw repair group (TS group), an allograft pin repair group (AP group), and a normal control groups (NC group), with eight shoulders in each group. The specimens were thawed at room temperature (24 °C) overnight, and the skin and subcutaneous tissue were removed. The muscle tissue around the articular capsule was partially removed, and the intact articular capsule and tendon were preserved. Then, a shoulder joint-bone-ligament muscle specimen was obtained. The humerus was severed at the upper middle part, and the periosteum was exposed. The glenoid cavity of the AP group and TS group was opened, and its transverse diameter was measured. A line 25% longer than the transverse diameter of the glenoid was drawn. The medial glenoid cavity and labrum were removed using a hand saw to create a model of severe Bankart injury in the porcine shoulder joint specimen. All the specimens were visually inspected to ensure that there were no fractures or joint capsule injuries. In the AP group, a bone knife was used to harvest a bone block from the scapular spine, as required, and the harvested bone block was trimmed, with two to three holes drilled. Bone allograft pins were hammered into the autologous bone graft, and the suture thread was inserted into the pinholes at the head. The pins were then hammered below the glenoid cavity (Figure 2), followed by suturing of the soft tissue with the bone graft. Finally, the articular capsule of the shoulder was sutured. In the TS group, a method similar to that in the AP group was used to fix the shoulder joint.

### Biomechanics testing

A Kirschner wire was inserted into the greater tubercle, coracoid process, and acromion of the shoulder joint specimen, and a marker was placed for motion capture on the Kirschner wire; when embedding the shoulder joint, we ensured that the scapula had an anterior tilt of approximately 20°. We fixed the embedded joints on the MTS Tytron 250 system. Sutures and thin steel wire ropes were used to connect three 1.02 kg custom weights to the supraspinatus tendon, infraspinatus tendon, and anterior and lower parts of the humerus. Custom weights of 1.53 kg and 0.51 kg were connected to the subscapularis tendon and round tendon, respectively, and the wire rope and weight were guided to the outside of the worktable along the muscle contraction direction. The weight drooped along the edge of the worktable through the pulley, and did not touch the ground to simulate the 10 N preload force on the supraspinatus and infraspinatus muscles, the 15 N preload force on the subscapularis, and the 5 N preload force on the teres minor muscle in the simulated physiological state. At the proximal end of the humerus, there was a 10 N tensile force of 45° forward and downward (using a wire rope to connect a 1.02 kg custom weight) to simulate the anterior and lower forces (Figure 3). After the humeral head was in contact with the scapular glenoid, when the humerus is externally rotated to 0°, 30°, 60°, and 90°, axial loads of 30 N, 40 N, and 50 N were applied to the glenoid, and the humerus was observed relative to displacement of the glenoid.



**Figure 2** Allograft pins repaired shoulder joint. Arrows: Allograft pins; Square: Scapular bone block; Triangles: Sutures.



**Figure 3** Biomechanics testing.

### Statistical analyses

Statistical analyses were performed using SPSS software (IBM Corp., Armonk, NY, United States), and the paired *q*-test was used.  $P < 0.05$  was considered statistically significant.

## RESULTS

When the external rotation of the humerus was at the same angle, with axial loads of 30 N, 40 N, and 50 N, the displacement of the humerus in each group increased; under the same load, when the angle of external rotation of the humerus increased, the displacement of humerus gradually decreased. Considering that the joint capsule was subjected to rotating torque at this time, the movement of the humerus was limited, so the displacement of the humerus decreased (Table 1).

When the angle of external rotation of the humerus is  $0^\circ$  and  $30^\circ$ , with axial loads of 30 N, 40 N, and 50 N, the data of the NC group, AP group, and TS group were compared with each other using the *q*-test, which showed that the differences in data among the NC group, TS group, and AP group were not statistically significant ( $P > 0.05$ ). The shoulder joints of the TS group and AP group had the same stability. The shoulder joints repaired with titanium alloy hollow screws and allograft pins had the same stability as the normal shoulder joints. When the humerus was externally rotated at  $60^\circ$  and  $90^\circ$ , and the axial loads were 40 N and 50 N, the same results were obtained ( $P > 0.05$ ), indicating that the shoulder joints in the TS group and AP group had the same stability. The shoulder joint repaired with the titanium alloy hollow screws and

Table 1 Displacement data of each group (mm, mean  $\pm$  SD)

ERA, load	NC	AP	TS
0°, 30 N	2.89 $\pm$ 0.13	2.64 $\pm$ 0.17	2.65 $\pm$ 0.36
0°, 40 N	3.36 $\pm$ 0.17	2.95 $\pm$ 0.20	3.19 $\pm$ 0.27
0°, 50 N	3.96 $\pm$ 0.30	3.41 $\pm$ 0.35	3.38 $\pm$ 0.18
30°, 30 N	2.51 $\pm$ 0.28	2.35 $\pm$ 0.19	2.37 $\pm$ 0.16
30°, 40 N	2.92 $\pm$ 0.11	2.54 $\pm$ 0.47	2.75 $\pm$ 0.221
30°, 50 N	3.22 $\pm$ 0.21	2.68 $\pm$ 0.23	2.82 $\pm$ 0.36
60°, 30 N	2.12 $\pm$ 0.13	1.96 $\pm$ 0.18	1.88 $\pm$ 0.33
60°, 40 N	2.23 $\pm$ 0.14	2.19 $\pm$ 0.31	2.13 $\pm$ 0.25
60°, 50 N	2.67 $\pm$ 0.39	2.51 $\pm$ 0.30	2.43 $\pm$ 0.31
90°, 30 N	1.08 $\pm$ 0.18	1.02 $\pm$ 0.23	1.03 $\pm$ 0.22
90°, 40 N	1.04 $\pm$ 0.38	1.08 $\pm$ 0.12	1.16 $\pm$ 0.29
90°, 50 N	1.12 $\pm$ 0.15	1.12 $\pm$ 0.15	1.27 $\pm$ 0.31

ERA: External rotation angle; NC: Normal control group; AP: Allograft pin repair group; TS: Titanium alloy hollow screw repair group.

allograft pins had the same stability as the normal shoulder joints (Table 2).

When the humerus was externally rotated to 60° and 90°, and the axial load was 30 N, the data of the AP group and NC group, TS group, and NC group were tested by the *q*-test, and the results indicated that, when the shoulder joints repaired with titanium alloy hollow screws and allograft pins were compared with the normal shoulder joint, they had the same degree of stability ( $P > 0.05$ ). In contrast, the difference in data between the TS group and the AP group was statistically significant ( $P < 0.05$ ). The joint capsules of the two groups were subjected to torsional force, and when the humerus was externally rotated at 60° and 90°, the axial load force was as small as 30 N, which limited the displacement of the humeral head. This resulted in a small forward and lower component force and limited displacement of the humeral head, leading in turn to a significant difference in the data between the AP group and TS group. As the axial load increased to 40 N and 50 N, there was no significant difference between the AP group and TS group (Table 2).

## DISCUSSION

The stability of the shoulder joint depends on multifactor synergy. Bankart lesions are the most common cause and an important pathological basis of recurrent anterior dislocation of the shoulder[9-12]. In 2014, Kim *et al*[13] proposed the classification of bony Bankart lesions according to bone fracture size as confirmed by three-dimensional computed tomography images: With mild lesion, the size of the bone block was  $< 12.5\%$  of the width of the glenoid cavity; with moderate lesion, the size of the bone block was  $12.5\%$  to  $25\%$  of the width of the glenoid cavity; and with severe lesion, the size of the bone block was  $> 25\%$  of the width of the glenoid cavity. The current clinical principles for treating these three types of injuries as follows: For mild lesion, arthroscopic repair of the glenoid labrum is recommended to reset the bone block to the greatest extent; for moderate lesion, bone reduction is recommended, and the bone block displacement is restricted to  $< 2$  mm; and for severe lesion, reconstruction with bone allograft, autograft, or Bristow-Latarjet surgery can be performed [14].

The current treatments for severe bony Bankart injury mainly include open or arthroscopic Bristow-Latarjet surgeries[6,14]. Since the coracoid process serves as the donor area for bone grafting, some important structures attached to the coracoid process such as the coracoacromial arch, biceps tendon, and pectoralis minor muscle will be damaged during bone harvesting, giving rise to shoulder joint dysfunction[15, 16]. Structural damage to the coracoacromial ligament is the greatest hidden peril of coracoid process transfer, whereas the coracoacromial ligament is the key structure for maintaining the stability of the shoulder joint[17]. The complication rate after coracoid

Table 2 The *q*-test results

ERA	AL	Groups	<i>P</i> value
0°	30 N	NC, AP	<i>P</i> > 0.05
0°	30 N	NC, TS	<i>P</i> > 0.05
0°	30 N	AP, TS	<i>P</i> > 0.05
0°	40 N	NC, AP	<i>P</i> > 0.05
0°	40 N	NC, TS	<i>P</i> > 0.05
0°	40 N	AP, TS	<i>P</i> > 0.05
0°	50 N	NC, AP	<i>P</i> > 0.05
0°	50 N	NC, TS	<i>P</i> > 0.05
0°	50 N	AP, TS	<i>P</i> > 0.05
30°	30 N	NC, AP	<i>P</i> > 0.05
30°	30 N	NC, TS	<i>P</i> > 0.05
30°	30 N	AP, TS	<i>P</i> > 0.05
30°	40 N	NC, AP	<i>P</i> > 0.05
30°	40 N	NC, TS	<i>P</i> > 0.05
30°	40 N	AP, TS	<i>P</i> > 0.05
30°	50 N	NC, AP	<i>P</i> > 0.05
30°	50 N	NC, TS	<i>P</i> > 0.05
30°	50 N	AP, TS	<i>P</i> > 0.05
60°	30 N	NC, AP	<i>P</i> > 0.05
60°	30 N	NC, TS	<i>P</i> > 0.05
60°	30 N	AP, TS	<i>P</i> < 0.05
60°	40 N	NC, AP	<i>P</i> > 0.05
60°	40 N	NC, TS	<i>P</i> > 0.05
60°	40 N	AP, TS	<i>P</i> > 0.05
60°	50 N	NC, AP	<i>P</i> > 0.05
60°	50 N	NC, TS	<i>P</i> > 0.05
60°	50 N	AP, TS	<i>P</i> > 0.05
90°	30 N	NC, AP	<i>P</i> > 0.05
90°	30 N	NC, TS	<i>P</i> > 0.05
90°	30 N	AP, TS	<i>P</i> < 0.05
90°	40 N	NC, AP	<i>P</i> > 0.05
90°	40 N	NC, TS	<i>P</i> > 0.05
90°	40 N	AP, TS	<i>P</i> > 0.05
90°	50 N	NC, AP	<i>P</i> > 0.05
90°	50 N	NC, TS	<i>P</i> > 0.05
90°	50 N	AP, TS	<i>P</i> > 0.05

ERA: External rotation angle; AL: Axial load; NC: Normal control group; AP: Allograft pin repair group; TS: Titanium alloy hollow screw repair group.

process transfer is up to 30%, accompanied by a recurrent dislocation rate of 2.9%, recurrent subluxation rate of 5.8%, revision rate of 7%, and average extorsion loss of 13.0°[18]. Griesse *et al*[19] reported some cases of coracoid and glenoid fractures. Other complications documented include bone block displacement, screw displacement,

fracture, infection, and neurovascular injury[19].

To avoid the rupture of normal shoulder joint structures by Latarjet or Bristow surgery, Auffarth *et al*[20] achieved good results by autologous iliac bone grafting. However, the results of the studies by Younger *et al*[21] and Summers *et al*[22] showed that the incidence of pain at the iliac donor site was 2.5% to 49%, and other complications, such as infection, hematoma, cutaneous nerve injury, scar formation, pseudoaneurysm, muscular herniation, arteriovenous fistula, and fracture of the anterosuperior iliac spine at the donor site, also occur frequently, disrupting the postoperative patient's quality of life[21,22]. Therefore, these complications should be considered by surgeons.

Autologous scapular grafts can eliminate the complications caused by coracoid process transfer and humeral bone removal and maintain the normal anatomical structure of the shoulder joint, which is beneficial to postoperative rehabilitation and recovery of shoulder mobility. As shown by anatomical studies in Chinese people, the width and height of the scapular spine are 7.26-19.58 and 11.48-23.86 mm, respectively, fully meeting the requirements for bone grafting of Bankart lesions[23,24].

Metal consumables for bone fixation have a higher elastic modulus than normal bone tissues. Implantation of metal consumables will produce stress shielding, affecting bone formation and even causing bone absorption, pin channel enlargement, fixation loosening, or even failure[25]. The elastic modulus of carbon fiber is close to that of normal bone tissue, but its biocompatibility is poor. Long-term use of carbon fibers can produce small debris and cause aseptic inflammation[26]. Absorbable biomaterials as consumables mostly consist of polylactic acid, and the degradation products will cause a local acidic environment, which is not conducive to bone formation and causes fixation loosening and failure[25,26]. In addition, the absorption time of absorbable biomaterials often mismatches the time of bone formation, and these materials are prone to becoming invalid prior to bone ingrowth, resulting in fixation failure[25,26].

Bone allograft pins have good histocompatibility, osteoconductivity, and osteoinductivity, making them conducive to the fusion of bone grafts with the glenoid cavity and bone ingrowth[27]. "Creeping substitution", which was initially described by Axhausen in 1908, is still in use today[10]. This theory reveals that the grafted bone block has osteogenic activity and serves as a scaffold to provide osteogenic environment for new bone formation on its surface[10]. Moreover, the grafted bone block gradually degrades and is completely replaced by new bone tissues[10]. Clinically used allogeneic bones include cancellous and cortical bones, both of which have a natural three-dimensional mesh structure enriched with various growth factors required for osteogenesis and characterized as having both bone conduction and osteoinductive advantages[10]. Overall, bone allograft pins with stitching threads have good biomechanical properties (with an elastic modulus close to normal bone tissues), producing little effect on imaging examinations, degrading completely, and not affecting secondary surgery. These pins have good osteogenic activity, and a stitching thread that not only tightly fixes the bone graft, but also stitches the bone graft with the surrounding soft tissues, further enhancing the fixation strength.

## CONCLUSION

In conclusion, autologous scapular grafting with bone allograft pin fixation is a feasible and effective surgery for repairing bony Bankart lesions, thus increasing shoulder joint stability.

## ARTICLE HIGHLIGHTS

### Research background

The pathological mechanism of anterior glenohumeral joint dislocation is mostly static stable structural damage. Bony Bankart lesions accounted for 5.4% to 70% of cases of traumatic instability of the glenohumeral joint and 90% of recurrent shoulder dislocations. Bony Bankart lesions lead to scapular glenoid defects, which are often repaired by the Latarjet-Bristow procedure. While good results have been achieved, there are also complications, such as coracoid fracture, bone graft displacement, and vascular and nerve injury.



### Research motivation

To avoid the complications caused by the removal of the grafted bone from the coracoid, this study used allograft bone from the scapular spine and the allograft pins to repair and reconstruct bony Bankart lesions of the shoulder joint. To avoid obtaining grafted bone from the coracoid, the complications and medical costs were decreased. *In vitro* biomechanics experiments were performed.

### Research objectives

This study aimed to analyze the technique and biomechanical properties of transversely fixing a bone block from the scapular spine using bone allograft pins with suture threads to repair bony Bankart lesions.

### Research methods

Twenty-four fresh human shoulder joint specimens were randomized into a titanium alloy hollow screw repair group, an allograft pin repair group, and a normal control group, with eight shoulders in each group. Model establishment and repair were performed as required, and biomechanical testing was performed using the MTS Tytron 250 system.

### Research results

When the angle of external rotation of the humerus was 0°, 30°, 60°, and 90°, with axials loads of 30 N, 40 N, and 50 N, the data of normal control group, allograft pin repair group, and titanium alloy hollow screw repair group, which revealed that there were no statistically significant differences among the three groups ( $P > 0.05$ ).

### Research conclusions

The joints repaired with bone block from the scapular spine transversely fixed with allograft bony pins to repair bony Bankart lesions show good mechanical stability.

### Research perspectives

This new method is conducive to treating injury post-surgery, is feasible, reduces medical costs, and is expected to be popularized and applied in the clinic.

## REFERENCES

- 1 Jin AM, Wang HQ. Clinical Anatomy of Orthopedics. Jinan: Shandong Science and Technology Press, 2010: 31-52
- 2 Rowe CR. Prognosis in dislocations of the shoulder. *J Bone Joint Surg Am* 1956; **38-A**: 957-977 [PMID: 13367074]
- 3 Simonet WT, Melton LJ 3rd, Cofield RH, Ilstrup DM. Incidence of anterior shoulder dislocation in Olmsted County, Minnesota. *Clin Orthop Relat Res* 1984; **186**: 186-191 [PMID: 6723141]
- 4 Bigliani LU, Newton PM, Steinmann SP, Connor PM, McIlveen SJ. Glenoid rim lesions associated with recurrent anterior dislocation of the shoulder. *Am J Sports Med* 1998; **26**: 41-45 [PMID: 9474399 DOI: 10.1177/03635465980260012301]
- 5 Sugaya H, Moriishi J, Dohi M, Kon Y, Tsuchiya A. Glenoid rim morphology in recurrent anterior glenohumeral instability. *J Bone Joint Surg Am* 2003; **85**: 878-884 [PMID: 12728039 DOI: 10.2106/00004623-200305000-00016]
- 6 Jiang CY, Zhu YM, Liu X, Li FL, Lu Y, Wu G. Do reduction and healing of the bony fragment really matter in arthroscopic bony Bankart reconstruction? *Am J Sports Med* 2013; **41**: 2617-2623 [PMID: 23964073 DOI: 10.1177/0363546513499304]
- 7 Porcellini G, Campi F, Paladini P. Arthroscopic approach to acute bony Bankart lesion. *Arthroscopy* 2002; **18**: 764-769 [PMID: 12209435 DOI: 10.1053/jars.2002.35266]
- 8 Sugaya H, Moriishi J, Kanisawa I, Tsuchiya A. Arthroscopic osseous Bankart repair for chronic recurrent traumatic anterior glenohumeral instability. Surgical technique. *J Bone Joint Surg Am* 2006; **88** Suppl 1 Pt 2: 159-169 [PMID: 16951089 DOI: 10.2106/JBJS.F.00319]
- 9 Ee GW, Mohamed S, Tan AH. Long term results of arthroscopic Bankart repair for traumatic anterior shoulder instability. *J Orthop Surg Res* 2011; **6**: 28 [PMID: 21672187 DOI: 10.1186/1749-799X-6-28]
- 10 Bevevino AJ, Kang DG, Lehman RA Jr, Van Blaricum GS, Wagner SC, Gwinn DE. Systematic review and meta-analysis of minimally invasive transforaminal lumbar interbody fusion rates performed without posterolateral fusion. *J Clin Neurosci* 2014; **21**: 1686-1690 [PMID: 24913928 DOI: 10.1016/j.jocn.2014.02.021]
- 11 Chen WX, Bao N, Zhao JN. [Advances on treatment of Bankart lesions]. *Yixue Yanjiusheng Xuebao* 2016; **29**: 309-313 [DOI: 10.16571/j.cnki.1008-8199.2016.03.019]



- 12 **Longo UG**, Loppini M, Rizzello G, Ciuffreda M, Maffulli N, Denaro V. Latarjet, Bristow, and Eden-Hybinette procedures for anterior shoulder dislocation: systematic review and quantitative synthesis of the literature. *Arthroscopy* 2014; **30**: 1184-1211 [PMID: [24907025](#) DOI: [10.1016/j.arthro.2014.04.005](#)]
- 13 **Kim YK**, Cho SH, Son WS, Moon SH. Arthroscopic repair of small and medium-sized bony Bankart lesions. *Am J Sports Med* 2014; **42**: 86-94 [PMID: [24272455](#) DOI: [10.1177/0363546513509062](#)]
- 14 **Huang CM**. [Repair of bony Bankart lesions]. *Zhonghua Jianzhouwaike Dianzi Zazhi* 2016; **4**: 56-60 [DOI: [10.3877/cma.j.issn.2095-5790.2016.01.011](#)]
- 15 **He S**. Applied anatomical study of the scapula and surgical treatment of scapular fracture. M.Sc. Thesis, Hebei Medical University. 2012 [DOI: [10.7666/d.y2106288](#)]
- 16 **Schaaf H**, Lendeckel S, Howaldt HP, Streckbein P. Donor site morbidity after bone harvesting from the anterior iliac crest. *Oral Surg Oral Med Oral Pathol Oral Radiol Endod* 2010; **109**: 52-58 [PMID: [20123379](#) DOI: [10.1016/j.tripleo.2009.08.023](#)]
- 17 **Zhao J**, Huangfu X, Yang X, Xie G, Xu C. Arthroscopic glenoid bone grafting with nonrigid fixation for anterior shoulder instability: 52 patients with 2- to 5-year follow-up. *Am J Sports Med* 2014; **42**: 831-839 [PMID: [24510068](#) DOI: [10.1177/0363546513519227](#)]
- 18 **Griesser MJ**, Harris JD, McCoy BW, Hussain WM, Jones MH, Bishop JY, Miniaci A. Complications and re-operations after Bristow-Latarjet shoulder stabilization: a systematic review. *J Shoulder Elbow Surg* 2013; **22**: 286-292 [PMID: [23352473](#) DOI: [10.1016/j.jse.2012.09.009](#)]
- 19 **Griesser MJ**, Harris JD, McCoy BW, Hussain WM, Jones MH, Bishop JY, Miniaci A. Glenoid fracture after Bristow-Latarjet shoulder stabilization: a case report and review of the literature. *J Shoulder Elbow Surg* 2013; **22**: e17-e20 [PMID: [23352058](#) DOI: [10.1016/j.jse.2012.11.003](#)]
- 20 **Auffarth A**, Schauer J, Matis N, Kofler B, Hitzl W, Resch H. The J-bone graft for anatomical glenoid reconstruction in recurrent posttraumatic anterior shoulder dislocation. *Am J Sports Med* 2008; **36**: 638-647 [PMID: [18006673](#) DOI: [10.1177/0363546507309672](#)]
- 21 **Younger EM**, Chapman MW. Morbidity at bone graft donor sites. *J Orthop Trauma* 1989; **3**: 192-195 [PMID: [2809818](#) DOI: [10.1097/00005131-198909000-00002](#)]
- 22 **Summers BN**, Eisenstein SM. Donor site pain from the ilium. A complication of lumbar spine fusion. *J Bone Joint Surg Br* 1989; **71**: 677-680 [PMID: [2768321](#) DOI: [10.1302/0301-620X.71B4.2768321](#)]
- 23 **Sun H**, Li Z, Wang JH, Liu ZP, Sun ZJ, Xu K, Wang YH. Anatomical study of the scapula. *Lin Chuang He Shi Yan Yixue Zazhi* 2015; **14**: 1858-1861 [DOI: [10.3969/j.issn.1671-4695.2015.22.008](#)]
- 24 **Li W**. Clinical Anatomy Study of scapula. M.D. Thesis, Southern Medical University. 2007 [DOI: [10.7666/d.y1145657](#)]
- 25 **Wang X**, Chen Y, Chen D, Yuan W, Chen X, Zhou X, Xiao J, Ni B, Jia L. Anterior decompression and interbody fusion with BAK/C for cervical disc degenerative disorders. *J Spinal Disord Tech* 2009; **22**: 240-245 [PMID: [19494742](#) DOI: [10.1097/BSD.0b013e31816d5f7e](#)]
- 26 **Lee JH**, Lee JH, Park JW, Lee HS. Fusion rates of a morselized local bone graft in polyetheretherketone cages in posterior lumbar interbody fusion by quantitative analysis using consecutive three-dimensional computed tomography scans. *Spine J* 2011; **11**: 647-653 [PMID: [21620776](#) DOI: [10.1016/j.spinee.2011.04.029](#)]
- 27 **Gazdag AR**, Lane JM, Glaser D, Forster RA. Alternatives to Autogenous Bone Graft: Efficacy and Indications. *J Am Acad Orthop Surg* 1995; **3**: 1-8 [PMID: [10790647](#) DOI: [10.5435/00124635-199501000-00001](#)]



Published by **Baishideng Publishing Group Inc**  
7041 Koll Center Parkway, Suite 160, Pleasanton, CA 94566, USA

**Telephone:** +1-925-3991568

**E-mail:** [bpgoffice@wjgnet.com](mailto:bpgoffice@wjgnet.com)

**Help Desk:** <https://www.f6publishing.com/helpdesk>

<https://www.wjgnet.com>

