

25,500 Results

Any time ▾

## Primary Intracranial Synovial Sarcoma

<https://www.ncbi.nlm.nih.gov/pmc/articles/PMC4876212>

May 09, 2016 · **Intracranial disease**, which is rare, has been reported as metastasis from **synovial sarcoma**. We report a case with no obvious primary extracranial pathology, suggesting **primary intracranial** disease; this has not been reported in the literature. Case Description. A 21-year-old male, with a prior right skull lesion resection for atypical spindle cell neoplasm, presented with headaches, ...

Cited by: 1

Author: Mohit Patel, Luyuan Li, Ha Son Nguyen, Nin...

Publish Year: 2016

## Primary Intracranial Synovial Sarcoma.

<https://www.ncbi.nlm.nih.gov/pubmed/27247811>

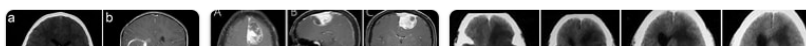
We report the first known case of **primary intracranial synovial sarcoma**. Moreover, we stress that **intracranial lesions** may have a tendency for **hemorrhage**, requiring urgent lifesaving decompression. PMID: PMC4876212

Cited by: 1

Author: Mohit Patel, Luyuan Li, Ha Son Nguyen, Nin...

Publish Year: 2016

## Images of Primary intracranial Synovial sarcoma with hemorrhage ...

<bing.com/images>

**Primary Intracranial Synovial Sarcoma.**<https://www.ncbi.nlm.nih.gov/pubmed/27247811>

We report the first known case of primary intracranial synovial sarcoma. Moreover, we stress that intracranial lesions may have a tendency for hemorrhage, requiring urgent lifesaving decompression. PMID: PMC4876212

Cited by: 1 Author: Mohit Patel, Luyuan Li, Ha Son Nguyen, Nin...  
Publish Year: 2016

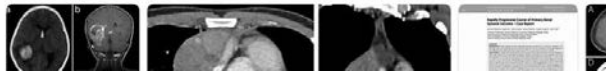## Search Tools


Turn off Hover Translation (关闭取词)

**Primary Intracranial Synovial Sarcoma**<https://www.ncbi.nlm.nih.gov/pmc/articles/PMC4876212>

May 09, 2016 · Intracranial disease, which is rare, has been reported as metastasis from synovial sarcoma. We report a case with no obvious primary extracranial pathology, suggesting primary intracranial disease; this has not been reported in the literature. Case Description. A 21-year-old male, with a prior right skull lesion resection for atypical spindle cell neoplasm, presented with headaches, ...

Cited by: 1 Author: Mohit Patel, Luyuan Li, Ha Son Nguyen, Nin...  
Publish Year: 2016

**Images of Primary intracranial Synovial sarcoma with hemorrhage ...**  
<bing.com/images>

**Primary intracranial synovial sarcoma with hemorrhage: A case report**

Wang YY *et al.* Primary intracranial SS a case report

Yang-Yang Wang, Man-Li Li, Zhi-Yong Zhang, Jiang-Wei Ding, Li-Fei Xiao, Wen-Chao Li, Lei Wang, Tao Sun

Received: June 3, 2021

Revised: July 16, 2021

Accepted:

Published online:

**Match Overview**

1	<b>Crossref</b> 91 words Qinbin Zhang, Bingqiang Xiao, Huanwei Huang, Yunsong Zhang, Xiaokang Zhang, Junting Zhang, Yonggang Weng "Intra	3%
2	<b>Internet</b> 71 words created on 22-Jul-2021 www.ngnet.com	1%
3	<b>Crossref</b> 29 words "Abstracts of Theses from the Nordic Countries", Asia Oncology, 2009	1%
4	<b>Internet</b> 15 words created on 14-Jul-2020 forsters.spendoo-publications.com	1%
5	<b>Internet</b> 12 words created on 24-Dec-2020 test.dovepress.com	1%

国内版

国际版

Primary intracranial synovial sarcoma with hemorrhage: A case rep



ALL

IMAGES

VIDEOS

22,600 Results

Any time ▾

### Primary Intracranial Synovial Sarcoma.

<https://www.ncbi.nlm.nih.gov/pubmed/27247811>

We report the first known case of primary intracranial synovial sarcoma. Moreover, we stress that intracranial lesions may have a tendency for hemorrhage, requiring urgent lifesaving decompression. PMID: PMC4876212

Cited by: 1

Author: Mohit Patel, Luyuan Li, Ha Son Nguyen, ...

Publish Year: 2016

### Primary Intracranial Synovial Sarcoma

<https://www.ncbi.nlm.nih.gov/pmc/articles/PMC4876212>

May 09, 2016 · Intracranial disease, which is rare, has been reported as metastasis from synovial sarcoma. We report a case with no obvious primary extracranial pathology, suggesting primary intracranial disease; this has not been reported in the literature. Case Description. A 21-year-old male, with a prior right skull lesion resection for atypical spindle cell neoplasm, presented with headaches, ...

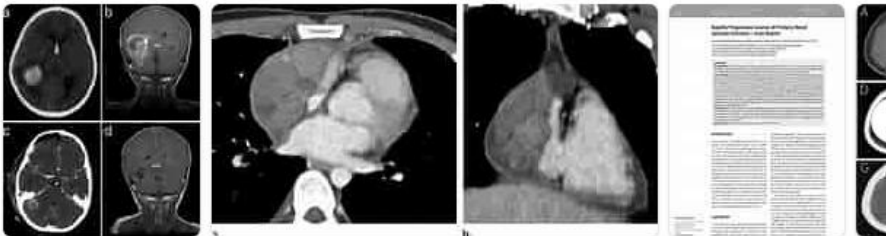
Cited by: 1

Author: Mohit Patel, Luyuan Li, Ha Son Nguyen, ...

Publish Year: 2016

### Images of Primary intracranial Synovial sarcoma with hemorr...

<bing.com/images>



See all images >

[\[PDF\] Primary Intracranial Fibrosarcoma Presenting with ...](#)