

# World Journal of *Clinical Cases*

*World J Clin Cases* 2021 November 16; 9(32): 9699-10051



## Contents

Thrice Monthly Volume 9 Number 32 November 16, 2021

## REVIEW

- 9699 Emerging role of long noncoding RNAs in recurrent hepatocellular carcinoma  
*Fang Y, Yang Y, Li N, Zhang XL, Huang HF*

## MINIREVIEWS

- 9711 Current treatment strategies for patients with only peritoneal cytology positive stage IV gastric cancer  
*Bausys A, Gricius Z, Aniukstyte L, Luksta M, Bickaite K, Bausys R, Strupas K*

## ORIGINAL ARTICLE

## Case Control Study

- 9722 Botulinum toxin associated with fissurectomy and anoplasty for hypertonic chronic anal fissure: A case-control study  
*D'Orazio B, Geraci G, Famà F, Terranova G, Di Vita G*
- 9731 Correlation between circulating endothelial cell level and acute respiratory distress syndrome in postoperative patients  
*Peng M, Yan QH, Gao Y, Zhang Z, Zhang Y, Wang YF, Wu HN*

## Retrospective Study

- 9741 Effects of early rehabilitation in improvement of paediatric burnt hands function  
*Zhou YQ, Zhou JY, Luo GX, Tan JL*
- 9752 Intracortical screw insertion plus limited open reduction in treating type 31A3 irreducible intertrochanteric fractures in the elderly  
*Huang XW, Hong GQ, Zuo Q, Chen Q*
- 9762 Treatment effects and periodontal status of chronic periodontitis after routine Er:YAG laser-assisted therapy  
*Gao YZ, Li Y, Chen SS, Feng B, Wang H, Wang Q*
- 9770 Risk factors for occult metastasis detected by inflammation-based prognostic scores and tumor markers in biliary tract cancer  
*Hashimoto Y, Ajiki T, Yanagimoto H, Tsugawa D, Shinozaki K, Toyama H, Kido M, Fukumoto T*
- 9783 Scapular bone grafting with allograft pin fixation for repair of bony Bankart lesions: A biomechanical study  
*Lu M, Li HP, Liu YJ, Shen XZ, Gao F, Hu B, Liu YF*
- 9792 High-resolution computed tomography findings independently predict epidermal growth factor receptor mutation status in ground-glass nodular lung adenocarcinoma  
*Zhu P, Xu XJ, Zhang MM, Fan SF*

- 9804** Colorectal cancer patients in a tertiary hospital in Indonesia: Prevalence of the younger population and associated factors

*Makmun D, Simadibrata M, Abdullah M, Syam AF, Shatri H, Fauzi A, Renaldi K, Maulahela H, Utari AP, Pribadi RR, Muzellina VN, Nursyirwan SA*

- 9815** Association between *Helicobacter pylori* infection and food-specific immunoglobulin G in Southwest China

*Liu Y, Shuai P, Liu YP, Li DY*

- 9825** Systemic immune inflammation index, ratio of lymphocytes to monocytes, lactate dehydrogenase and prognosis of diffuse large B-cell lymphoma patients

*Wu XB, Hou SL, Liu H*

### Clinical Trials Study

- 9835** Evaluating the efficacy of endoscopic sphincterotomy on biliary-type sphincter of Oddi dysfunction: A retrospective clinical trial

*Ren LK, Cai ZY, Ran X, Yang NH, Li XZ, Liu H, Wu CW, Zeng WY, Han M*

### Observational Study

- 9847** Management of pouch related symptoms in patients who underwent ileal pouch anal anastomosis surgery for adenomatous polyposis

*Gilad O, Rosner G, Brazowski E, Kariv R, Gluck N, Strul H*

- 9857** Presepsin as a biomarker for risk stratification for acute cholangitis in emergency department: A single-center study

*Zhang HY, Lu ZQ, Wang GX, Xie MR, Li CS*

### Prospective Study

- 9869** Efficacy of Yiqi Jianpi anti-cancer prescription combined with chemotherapy in patients with colorectal cancer after operation

*Li Z, Yin DF, Wang W, Zhang XW, Zhou LJ, Yang J*

### META-ANALYSIS

- 9878** Arthroplasty vs proximal femoral nails for unstable intertrochanteric femoral fractures in elderly patients: A systematic review and meta-analysis

*Chen WH, Guo WX, Gao SH, Wei QS, Li ZQ, He W*

### CASE REPORT

- 9889** Synchronous multiple primary malignancies of the esophagus, stomach, and jejunum: A case report

*Li Y, Ye LS, Hu B*

- 9896** Idiopathic acute superior mesenteric venous thrombosis after renal transplantation: A case report

*Zhang P, Li XJ, Guo RM, Hu KP, Xu SL, Liu B, Wang QL*

- 9903** Next-generation sequencing technology for diagnosis and efficacy evaluation of a patient with visceral leishmaniasis: A case report

*Lin ZN, Sun YC, Wang JP, Lai YL, Sheng LX*

- 9911** Cerebral air embolism complicating transbronchial lung biopsy: A case report  
*Herout V, Brat K, Richter S, Cundrle Jr I*
- 9917** Isolated synchronous Virchow lymph node metastasis of sigmoid cancer: A case report  
*Yang JQ, Shang L, Li LP, Jing HY, Dong KD, Jiao J, Ye CS, Ren HC, Xu QF, Huang P, Liu J*
- 9926** Clinical presentation and management of drug-induced gingival overgrowth: A case series  
*Fang L, Tan BC*
- 9935** Adult with mass burnt lime aspiration: A case report and literature review  
*Li XY, Hou HJ, Dai B, Tan W, Zhao HW*
- 9942** Massive hemothorax due to intercostal arterial bleeding after percutaneous catheter removal in a multiple-trauma patient: A case report  
*Park C, Lee J*
- 9948** Hemolymphangioma with multiple hemangiomas in liver of elderly woman with history of gynecological malignancy: A case report  
*Wang M, Liu HF, Zhang YZZ, Zou ZQ, Wu ZQ*
- 9954** Rare location and drainage pattern of right pulmonary veins and aberrant right upper lobe bronchial branch: A case report  
*Wang FQ, Zhang R, Zhang HL, Mo YH, Zheng Y, Qiu GH, Wang Y*
- 9960** Respiratory failure after scoliosis correction surgery in patients with Prader-Willi syndrome: Two case reports  
*Yoon JY, Park SH, Won YH*
- 9970** Computed tomography-guided chemical renal sympathetic nerve modulation in the treatment of resistant hypertension: A case report  
*Luo G, Zhu JJ, Yao M, Xie KY*
- 9977** Large focal nodular hyperplasia is unresponsive to arterial embolization: A case report  
*Ren H, Gao YJ, Ma XM, Zhou ST*
- 9982** Fine-needle aspiration cytology of an intrathyroidal nodule diagnosed as squamous cell carcinoma: A case report  
*Yu JY, Zhang Y, Wang Z*
- 9990** Extensive abdominal lymphangiomatosis involving the small bowel mesentery: A case report  
*Alhasan AS, Daqqaq TS*
- 9997** Gastrointestinal symptoms as the first sign of chronic granulomatous disease in a neonate: A case report  
*Meng EY, Wang ZM, Lei B, Shang LH*
- 10006** Screw penetration of the iliopsoas muscle causing late-onset pain after total hip arthroplasty: A case report  
*Park HS, Lee SH, Cho HM, Choi HB, Jo S*

- 10013** Uretero-lumbar artery fistula: A case report  
*Chen JJ, Wang J, Zheng QG, Sun ZH, Li JC, Xu ZL, Huang XJ*
- 10018** Rare mutation in *MKRN3* in two twin sisters with central precocious puberty: Two case reports  
*Jiang LQ, Zhou YQ, Yuan K, Zhu JF, Fang YL, Wang CL*
- 10024** Primary mucosal-associated lymphoid tissue extranodal marginal zone lymphoma of the bladder from an imaging perspective: A case report  
*Jiang ZZ, Zheng YY, Hou CL, Liu XT*
- 10033** Focal intramural hematoma as a potential pitfall for iatrogenic aortic dissection during subclavian artery stenting: A case report  
*Zhang Y, Wang JW, Jin G, Liang B, Li X, Yang YT, Zhan QL*
- 10040** Ventricular tachycardia originating from the His bundle: A case report  
*Zhang LY, Dong SJ, Yu HJ, Chu YJ*
- 10046** Posthepatectomy jaundice induced by paroxysmal nocturnal hemoglobinuria: A case report  
*Liang HY, Xie XD, Jing GX, Wang M, Yu Y, Cui JF*

**ABOUT COVER**

Editorial Board Member of *World Journal of Clinical Cases*, Jalaj Garg, FACC, MD, Academic Research, Assistant Professor, Division of Cardiology, Medical College of Wisconsin, Milwaukee, WI 53226, United States.  
garg.jalaj@yahoo.com

**AIMS AND SCOPE**

The primary aim of *World Journal of Clinical Cases* (WJCC, *World J Clin Cases*) is to provide scholars and readers from various fields of clinical medicine with a platform to publish high-quality clinical research articles and communicate their research findings online.

WJCC mainly publishes articles reporting research results and findings obtained in the field of clinical medicine and covering a wide range of topics, including case control studies, retrospective cohort studies, retrospective studies, clinical trials studies, observational studies, prospective studies, randomized controlled trials, randomized clinical trials, systematic reviews, meta-analysis, and case reports.

**INDEXING/ABSTRACTING**

The WJCC is now indexed in Science Citation Index Expanded (also known as SciSearch®), Journal Citation Reports/Science Edition, Scopus, PubMed, and PubMed Central. The 2021 Edition of Journal Citation Reports® cites the 2020 impact factor (IF) for WJCC as 1.337; IF without journal self cites: 1.301; 5-year IF: 1.742; Journal Citation Indicator: 0.33; Ranking: 119 among 169 journals in medicine, general and internal; and Quartile category: Q3. The WJCC's CiteScore for 2020 is 0.8 and Scopus CiteScore rank 2020: General Medicine is 493/793.

**RESPONSIBLE EDITORS FOR THIS ISSUE**

Production Editor: Jia-Hui Li; Production Department Director: Yu-Jie Ma; Editorial Office Director: Jin-Lei Wang.

**NAME OF JOURNAL**

*World Journal of Clinical Cases*

**ISSN**

ISSN 2307-8960 (online)

**LAUNCH DATE**

April 16, 2013

**FREQUENCY**

Thrice Monthly

**EDITORS-IN-CHIEF**

Dennis A Bloomfield, Sandro Vento, Bao-Gan Peng

**EDITORIAL BOARD MEMBERS**

<https://www.wjnet.com/2307-8960/editorialboard.htm>

**PUBLICATION DATE**

November 16, 2021

**COPYRIGHT**

© 2021 Baishideng Publishing Group Inc

**INSTRUCTIONS TO AUTHORS**

<https://www.wjnet.com/bpg/gerinfo/204>

**GUIDELINES FOR ETHICS DOCUMENTS**

<https://www.wjnet.com/bpg/GerInfo/287>

**GUIDELINES FOR NON-NATIVE SPEAKERS OF ENGLISH**

<https://www.wjnet.com/bpg/gerinfo/240>

**PUBLICATION ETHICS**

<https://www.wjnet.com/bpg/GerInfo/288>

**PUBLICATION MISCONDUCT**

<https://www.wjnet.com/bpg/gerinfo/208>

**ARTICLE PROCESSING CHARGE**

<https://www.wjnet.com/bpg/gerinfo/242>

**STEPS FOR SUBMITTING MANUSCRIPTS**

<https://www.wjnet.com/bpg/GerInfo/239>

**ONLINE SUBMISSION**

<https://www.f6publishing.com>



# Arthroplasty vs proximal femoral nails for unstable intertrochanteric femoral fractures in elderly patients: A systematic review and meta-analysis

Wen-Huan Chen, Wen-Xuan Guo, Shi-Hua Gao, Qiu-Shi Wei, Zi-Qi Li, Wei He

**ORCID number:** Wen-Huan Chen 0000-0002-7807-7361; Wen-Xuan Guo 0000-0002-2012-8306; Shi-Hua Gao 0000-0002-0567-5694; Qiu-Shi Wei 0000-0002-1432-2997; Zi-Qi Li 0000-0002-5305-5705; Wei He 0000-0001-8209-639X.

**Author contributions:** Chen WH contributed to study conception and design, drafting the submitted article; He W, Wei QS and Li ZQ revised the draft critically for important intellectual content; Guo WX and Gao SH contributed to acquisition, analysis, and interpretation the data; and all authors read and approved the final manuscript.

**Conflict-of-interest statement:** The authors declare that they have no competing interests.

**PRISMA 2009 Checklist statement:** The authors have read the PRISMA 2009 Checklist, and the manuscript was prepared and revised according to the PRISMA 2009 Checklist.

**Country/Territory of origin:** China

**Specialty type:** Medicine, research and experimental

**Provenance and peer review:** Unsolicited article; Externally peer

**Wen-Huan Chen**, The Third Clinical Medical School, Guangzhou University of Chinese Medicine, Guangzhou 510405, Guangdong Province, China

**Wen-Xuan Guo**, The First Clinical College, Zhejiang Chinese Medical University, Hangzhou 310000, Zhejiang Province, China

**Shi-Hua Gao**, The First Clinical Medical School, Guangzhou University of Chinese Medicine, Guangzhou 510405, Guangdong Province, China

**Qiu-Shi Wei, Zi-Qi Li, Wei He**, Department of Joint Surgery, The Third Affiliated Hospital of Guangzhou University of Chinese Medicine, Guangzhou 510405, Guangdong Province, China

**Corresponding author:** Wei He, MD, Professor, Department of Joint Surgery, The Third Affiliated Hospital of Guangzhou University of Chinese Medicine, No. 261 Longxi Road, Liwan District, Guangzhou 510405, Guangdong Province, China. [hw13802516062@126.com](mailto:hw13802516062@126.com)

## Abstract

### BACKGROUND

Proximal femoral nails (PFNs) are the most common method for the treatment of unstable intertrochanteric femoral fractures (IFFs), but postoperative bed rest is required. There is a large amount of blood loss during the operation. Osteoporosis in elderly patients may cause nonunion of fractures and other complications. Arthroplasty can give patients early weight bearing and reduce financial burden, but whether it can replace PFNs remains controversial.

### AIM

To compare the clinical outcomes of arthroplasty and PFNs in the treatment of unstable IFFs in elderly patients.

### METHODS

A search was conducted in the PubMed, Embase, and Cochrane Library databases and included relevant articles comparing arthroplasty and PFN. The search time was limited from January 1, 2005 to November 1, 2020. Two investigators independently screened studies, extracted data and evaluated the quality according to the inclusion and exclusion criteria. According to the research results, the fixed effect model or random effect model were selected for analysis. The following outcomes were analyzed: Harris Hip score, mortality, complica-

reviewed

**Peer-review report's scientific quality classification**

Grade A (Excellent): 0  
 Grade B (Very good): 0  
 Grade C (Good): C  
 Grade D (Fair): 0  
 Grade E (Poor): 0

**Open-Access:** This article is an open-access article that was selected by an in-house editor and fully peer-reviewed by external reviewers. It is distributed in accordance with the Creative Commons Attribution NonCommercial (CC BY-NC 4.0) license, which permits others to distribute, remix, adapt, build upon this work non-commercially, and license their derivative works on different terms, provided the original work is properly cited and the use is non-commercial. See: <http://creativecommons.org/licenses/by-nc/4.0/>

**Received:** June 18, 2021**Peer-review started:** June 18, 2021**First decision:** August 18, 2021**Revised:** August 27, 2021**Accepted:** September 19, 2021**Article in press:** September 19, 2021**Published online:** November 16, 2021**P-Reviewer:** Kakoulidis P**S-Editor:** Wang JJ**L-Editor:** Kerr C**P-Editor:** Guo X

ations, operation time, blood loss, hospital stay, weight-bearing time, fracture classification and type of anesthesia.

**RESULTS**

We analyzed four randomized controlled trials that met the requirements. A total of 298 patients were included in these studies. According to the AO/OTA classification, there are 20 A1 types, 136 A2 types, 42 A3 types and 100 unrecorded types. Primary outcome: The Harris Hip Score at the final follow-up of the PFN group was higher [mean difference (MD): 9.01, 95% confidence interval (CI): 16.57 to 1.45],  $P = 0.02$ . There was no significant difference between the two groups in the rate of overall mortality [risk ratio (RR): 1.44,  $P = 0.44$ ] or the number of complications (RR: 0.77,  $P = 0.05$ ). Secondary outcomes: blood loss of the arthroplasty group was higher (MD: 241.01, 95% CI: 43.06–438.96,  $P = 0.02$ ); the operation time of the PFN group was shorter (MD: 23.12, 95% CI: 10.46–35.77,  $P = 0.0003$ ); and the length of hospital stay of the arthroplasty group was shorter [MD: 0.97, 95% CI: 1.29 to 0.66],  $P < 0.00001$ . There was no difference between the two groups in the type of anesthesia (RR: 0.99). There were only two studies recording the weight-bearing time, and the time of full weight bearing in the arthroplasty group was significantly earlier.

**CONCLUSION**

Compared with PFN, arthroplasty can achieve weight bearing earlier and shorten hospital stay, but it cannot achieve a better clinical outcome. Arthroplasty cannot replace PFNs in the treatment of unstable IFFs in elderly individuals.

**Key Words:** Arthroplasty; Proximal femoral nail; Intertrochanteric femoral fracture; Elderly; Meta-analysis; Systematic review

©The Author(s) 2021. Published by Baishideng Publishing Group Inc. All rights reserved.

**Core Tip:** This review compared the clinical outcomes of arthroplasty and proximal femoral nails (PFNs) in the treatment of unstable intertrochanteric femoral fractures (IFFs) in elderly patients. Many people believe that arthroplasty can replace PFNs for unstable IFFs in elderly patients. However, there is no consensus. Some researchers have carried out reviews of the research, but the results were different. Therefore, we conducted this meta-analysis. We reviewed four randomized controlled trials about this topic and found that arthroplasty cannot achieve better results than PFNs in the clinic. Arthroplasty is not the first choice for the treatment of unstable IFFs in elderly patients.

**Citation:** Chen WH, Guo WX, Gao SH, Wei QS, Li ZQ, He W. Arthroplasty vs proximal femoral nails for unstable intertrochanteric femoral fractures in elderly patients: A systematic review and meta-analysis. *World J Clin Cases* 2021; 9(32): 9878-9888

**URL:** <https://www.wjgnet.com/2307-8960/full/v9/i32/9878.htm>

**DOI:** <https://dx.doi.org/10.12998/wjcc.v9.i32.9878>

**INTRODUCTION**

Intertrochanteric femoral fracture (IFF) is a common type of hip fracture and is extracapsular in nature. The incidence of IFFs accounts for 3.51% of systemic fractures, and IFFs are more common in elderly individuals[1]. AO/OTA classification is commonly used in clinical practice. Among the different types of IFFs, 31A1 and A2.1 are considered stable fractures, while the rest are unstable. With the increase in the human lifespan and the arrival of a globally aging society, the incidence of the disease is also increasing yearly. Thus, to achieve good stability and activity, surgeons are more willing to choose surgical treatment. Because strong internal fixation can promote the early recovery of limb function and reduce the occurrence of complications, surgical treatment has gradually become the preferred treatment[2]. The proximal femoral nail (PFN) is more consistent with the anatomical shape of the femur and provides better stability, so most clinicians choose PFNs to treat unstable IFFs[3-

5]. However, for elderly patients, osteoporosis often increases the failure rate of surgery[6] and leads to many complications and poor prognosis[7]. As a result, some people focus on artificial hip joint replacement, which can be used as a better treatment for some elderly patients with IFFs[8].

Arthroplasty can allow patients to achieve full weight bearing early, thus reducing the complications of long-term bed rest[9,10]. Studies have shown that bilateral hemiarthroplasty treatment of unstable IFFs can achieve good therapeutic effects[11]. However, there are also significant complications related to arthroplasty, such as bone marrow mud syndrome, a large amount of bleeding, prosthesis loosening, and wound infection[12].

Many scholars have conducted clinical studies to find evidence to prove that arthroplasty can replace PFNs in treating unstable IFFs in elderly patients, but there is no consensus[13-15]. Therefore, we conducted this meta-analysis and systematic review of RCTs to determine whether arthroplasty can achieve better results than PFNs in the treatment of unstable IFFs at an advanced age (> 60 years).

## MATERIALS AND METHODS

### Literature search

This article was performed following the Preferred Reporting Items for Systematic Reviews and Meta-Analyses (PRISMA) guidelines[16]. The primary search was conducted in PubMed, Embase and Cochrane Library databases by two investigators independently. They used the keywords and synonyms listed in Table 1 to aggregate all of the relevant published studies. Each investigator reviewed all titles, abstracts, and full texts of the potentially related studies.

### Study eligibility criteria

Studies were selected according to the inclusion and exclusion criteria. The inclusion criteria were all RCT studies on arthroplasty and PFNs in the treatment of elderly patients with IFFs. Through reading the literature, we found that there were few reports before 2005 on the clinical effects of PFN. Therefore, the research publication time was limited to between 2005 and 2020. The exclusion criteria were non-RCT studies, cadaver studies, biomechanical studies, conference abstracts, case reports, editorial reviews, patients aged  $\leq 60$  years, inconsistent publication time, and studies not written in English. The primary outcomes were the Harris Hip Score (HHS) at the final follow-up time, the rate of postoperative overall mortality and the number of complications. Secondary outcomes were blood loss, operation time, length of hospital stay, weight-bearing time and type of anesthesia.

### Statistical analysis

RevMan 5.4 software, provided by the Cochrane Collaboration Network, was used for statistical analysis. The relative risk (RR) was used as the effect analysis statistic for two categorical variables, and the mean difference (MD) was used for continuous variables. The heterogeneity of the included results was determined using the  $I^2$  test. If there was no statistical heterogeneity among the research results, the fixed effect model was used for meta-analysis; otherwise, the random effect model was used after excluding the influence of obvious clinical heterogeneity. Significant clinical heterogeneity was treated by subgroup analysis, sensitivity analysis, or descriptive analysis. The test level of meta-analysis was set as  $P = 0.05$ .

### Risk of bias assessment

The Cochrane Collaboration Risk of Bias Tool was used to evaluate the quality of the RCTs by two independent investigators.

## RESULTS

### Search and screening results

The literature was searched by two investigators and screened strictly by reading the title, abstract, or full text of the article according to the inclusion and exclusion criteria. A total of 1223 studies were obtained, and 502 were excluded by reading the titles and abstracts, and 20 relevant studies were identified for further evaluation. After screening the full texts, 16 studies were excluded. Ultimately, four RCTs were

Table 1 Search strategy

Database	Methodology	Results
PubMed	{[(hip fracture) or (intertrochanteric fracture)] or (femoral fracture)} and [(aged or elderly) or senile] and {[Arthroplasty, Replacement, Hip or Hemiarthroplasty or Prosthesis Implantation] or (total hip replacement)] or (hip replacement)} and (randomized). Filters: From 2005 to 2020	430
EMBASE	('femur intertrochanteric fracture'/exp or 'hip fracture'/exp or 'femoral fracture'/exp) and ('aged'/exp OR 'elderly'/exp) and ('hip replacement'/exp or 'hip hemiarthroplasty'/exp or 'total hip replacement'/exp or 'arthroplasty'/exp) and ('randomized') and [(2005-2020)/py]	239
Cochrane Library	[(hip fracture) or (intertrochanteric fracture) or (femoral fracture)] and (aged or elderly or senile) and (Arthroplasty or Hemiarthroplasty or Prosthesis Implantation or hip replacement). Custom year range: 2005 to 2020	554

identified for the meta-analysis[14,15,17,18] (Figure 1).

### Quality assessment

The results of bias risk assessment in RCTs are shown in Figure 2. None of the included RCTs reported blinding of the surgeons, participants, or assessors. The checklist is in the additional file.

### Demographic characteristics

The basic characteristics of the included studies are shown in Supplementary Tables 1 and 2. There were 298 patients, forming the arthroplasty group ( $n = 156$ ) and PFN group ( $n = 142$ ).

All the patients in the four studies were aged  $> 60$  years, and most of them were 75–85 years old. There was no significant difference in age between any of the studies. There was no significant difference between the arthroplasty and PFN groups in the sex ratio in three studies. However, the number of IFFs in women was greater than that in men in two studies, which may be related to osteoporosis and bone strength reduction caused by decreased estrogen levels[19,20].

Three studies reported the fracture types of the included patients. In the arthroplasty group, there were 10 patients with type A1 fractures, 73 with type A2 and 23 with types A3. In the PFN group, there were 10 patients with type A1, 63 with type A2 and with types A3 fractures. The number of stable fractures was small, and the corresponding data were not provided in the original literature, so they are not excluded in the analysis. The three studies did not list the incidence of outcomes for different classifications; therefore, subgroup analysis could not be conducted.

### Primary outcome

**HHS:** The HHS at the end of follow-up was compared between the arthroplasty and PFN groups. Three studies mentioned the HHS and included the mean and standard deviation (SD). The results of the fixed effect model showed that there was statistical heterogeneity among studies ( $P = 0.004$ ,  $I^2 = 82\%$ ), so we chose the random effect model for analysis. There was a significant difference in HHS between the arthroplasty and PFN groups [MD = 9.01, 95% confidence interval (CI): 16.57 to 1.45],  $P = 0.02$ . The score of the PFN group at the end of follow-up was higher than that of the arthroplasty group. All the studies included were followed up for  $> 12$  mo. Except for Jolly[18], the other three studies were followed up for  $> 24$  mo. Moreover, in terms of hip function, the arthroplasty group did not achieve better results (Figure 3).

**Mortality:** The rate of overall mortality was assessed by three studies. The results of the fixed effect model showed that there was heterogeneity among studies ( $P = 0.08$ ,  $I^2 = 61\%$ ), so we chose the random effect model for analysis. There was no significant difference between the two groups (RR: 1.44, 95% CI: 0.57–3.66,  $P = 0.44$ ) (Figure 4).

**Complications:** The four studies documented complications, including superficial infection, deep infection, implant failure, respiratory infection, and venous thromboembolism. There was no significant difference between the two groups (RR: 0.77, 95% CI: 0.60–1.00,  $P = 0.05$ ) (Figure 5).

### Secondary outcomes

**Blood loss:** Blood loss was compared between the arthroplasty and PFN groups. Two studies recorded the intraoperative bleeding volume. The results of the fixed effect model showed that there was statistical heterogeneity among studies ( $P < 0.00001$ ,  $I^2 = 99\%$ ), so we chose the random effect model for analysis. There was a significant

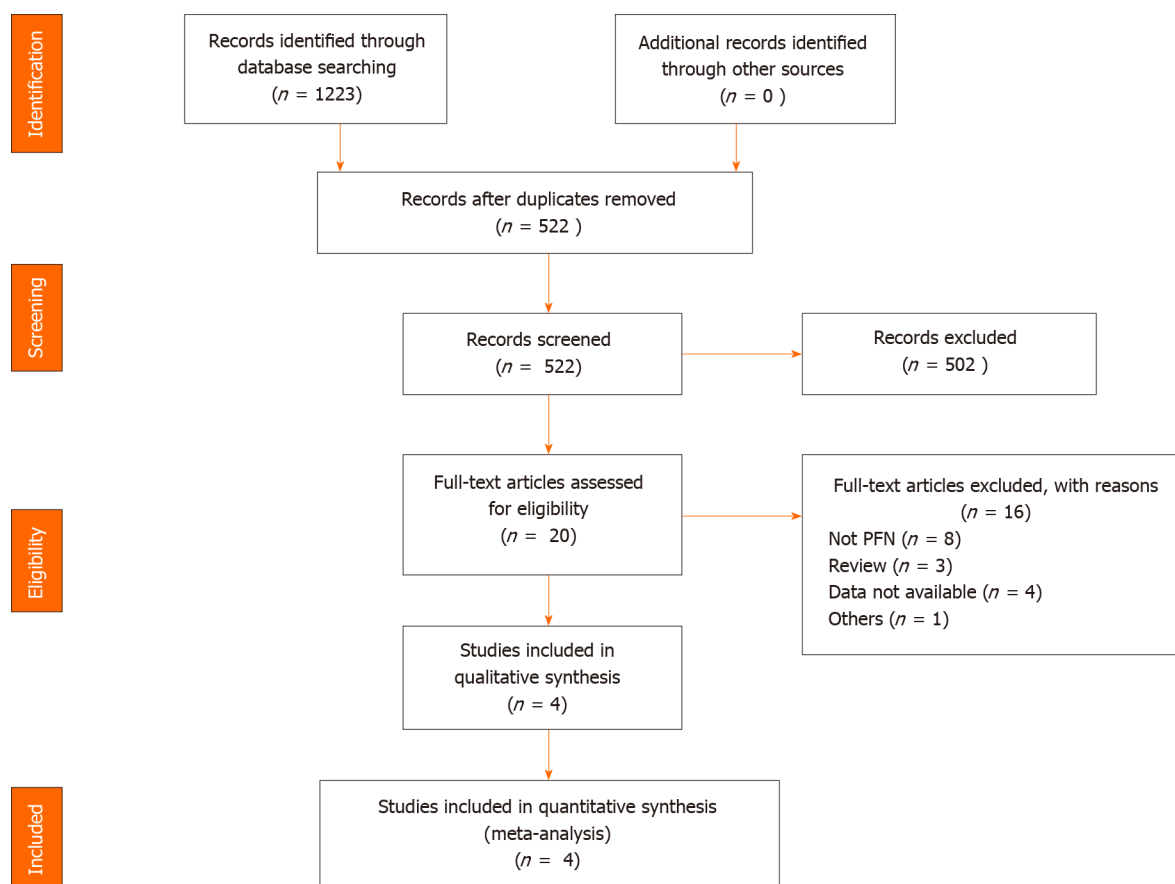


Figure 1 PRISMA flow chart depicting selection of articles. PFN: Proximal femoral nail.

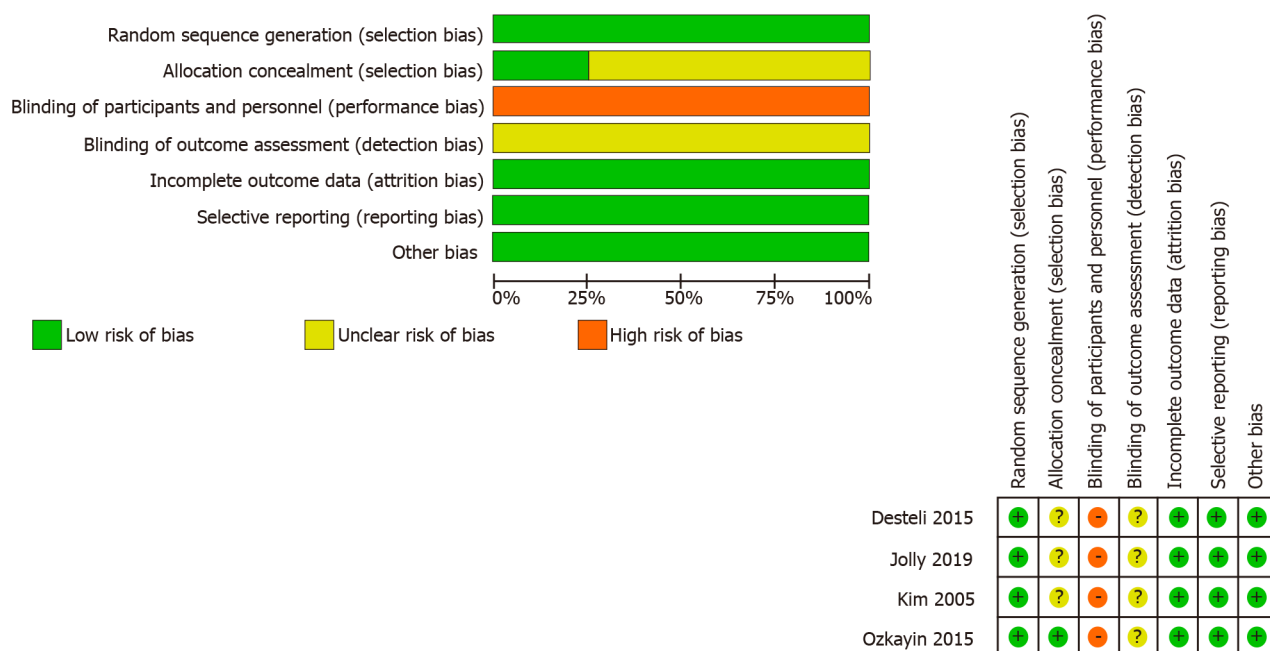
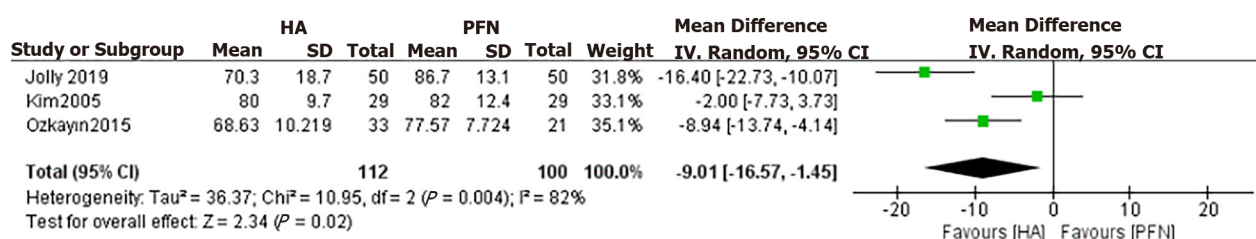


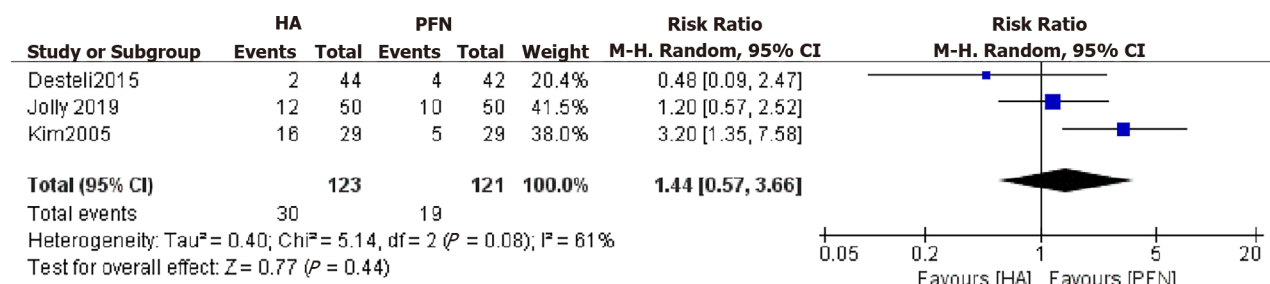
Figure 2 Risk of bias graph: Investigators judgment each risk of bias item presented across all studies.

difference between the two groups (MD: 241.01, 95% CI: 43.06–438.96,  $P = 0.02$ ). The blood loss of the arthroplasty group was higher than that of the PFN group (Figure 6).

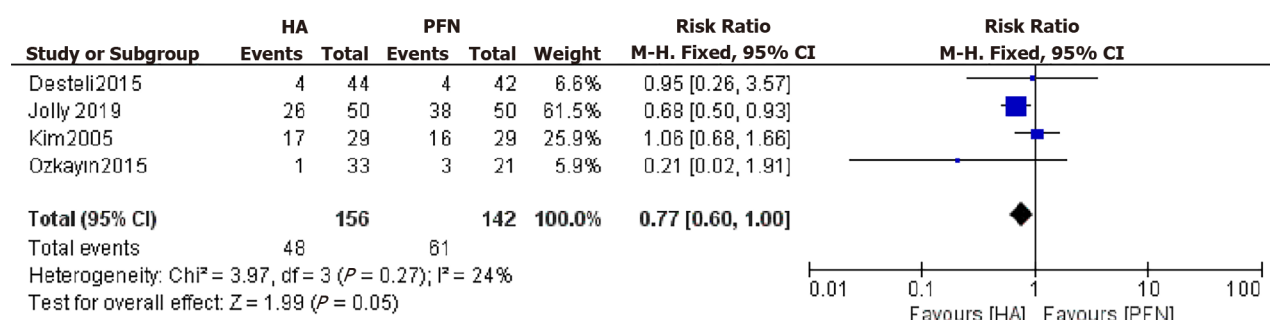
**Operation time:** The operation times for the arthroplasty and PFN groups were compared in the four studies. The results of the fixed effect model showed that there was statistical heterogeneity among all studies ( $P < 0.00001$ ,  $I^2 = 97\%$ ). After discussion,



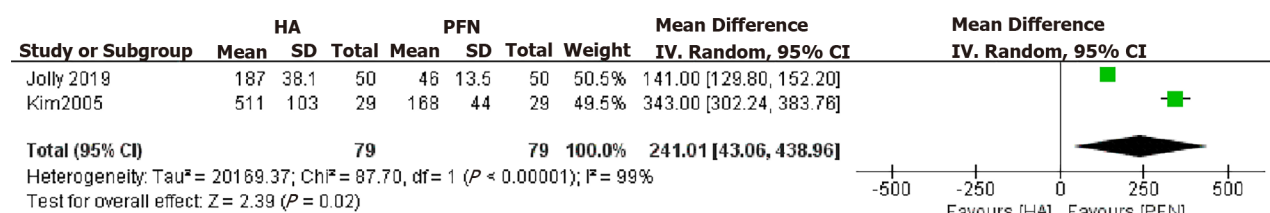
**Figure 3** Forest plot diagram of compared Harris Hip Score between arthroplasty and proximal femoral nail[14,17,18]. HA: arthroplasty; PFN: proximal femoral nail; CI: confidence interval.



**Figure 4** Forest plot diagram of mortality compared between arthroplasty and proximal femoral nail[14,15,18]. HA: arthroplasty; PFN: proximal femoral nail; CI: confidence interval.

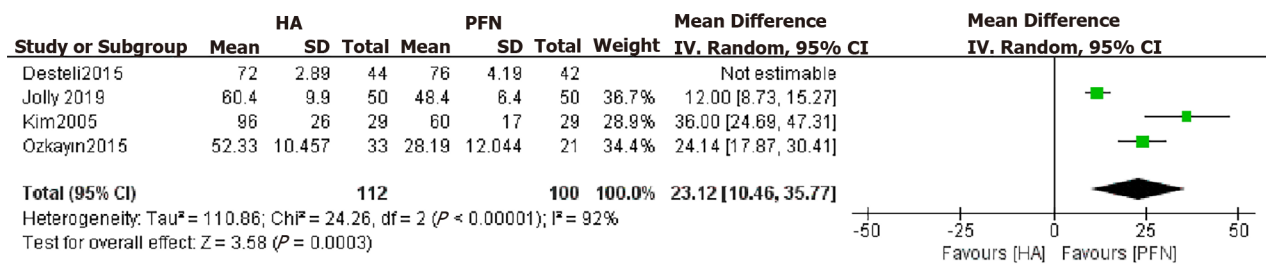


**Figure 5** Forest plot diagram of complications compared between arthroplasty and proximal femoral nail[14,15,18,17]. HA: arthroplasty; PFN: proximal femoral nail; CI: confidence interval.



**Figure 6** Forest plot diagram of blood loss compared between arthroplasty and proximal femoral nail[14,18]. HA: arthroplasty; PFN: proximal femoral nail; CI: confidence interval.

we excluded a study that had a greater impact on heterogeneity and used a random effect model for analysis. There was a significant difference in operation time between the arthroplasty and PFN groups (MD: 23.12, 95% CI: 10.46–35.77,  $P = 0.0003$ ). The operation time of the PFN group was significantly shorter than that of the arthroplasty group. A longer operation time and more intraoperative bleeding was found to easily lead to more potential complications and affect the patient's postoperative recovery (Figure 7).



**Figure 7** Forest plot diagram of operation time compared between arthroplasty and proximal femoral nail[14,15,18,17]. HA: arthroplasty; PFN: proximal femoral nail; CI: confidence interval.

**Hospital stay:** The lengths of hospital stay for the arthroplasty and PFN groups were compared. Two studies mentioned the days and included the mean and SD. The results of the fixed effect model showed that there was a significant difference in the length of hospital stay between the arthroplasty and PFN groups [MD: 0.97, 95% CI: 1.29 to 0.66),  $P < 0.00001$ ]. The length of stay in the arthroplasty group was significantly shorter than that in the PFN group (Figure 8).

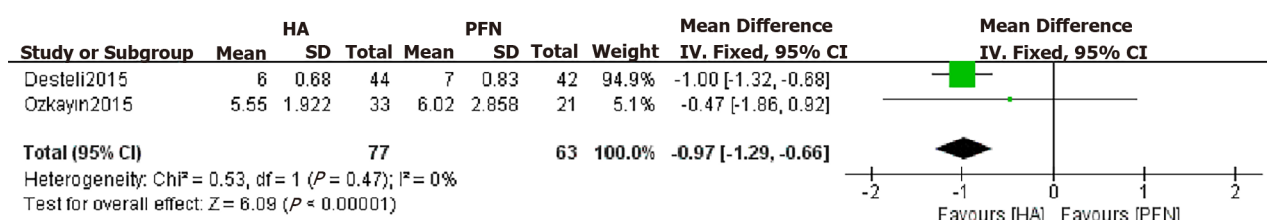
**Weight-bearing time:** Only two studies recorded the weight-bearing time. One recorded full weight-bearing time, and the other recorded walking with a walker. In addition, their units were different. Thus, we did not combine the results of the two papers. Jolly[18] documented that the mean time of full weight bearing in the PFN group was  $10.1 \pm 3.5$  wk, while the mean time in the arthroplasty group was  $3.2 \pm 4.7$  wk. Kim[14] documented that the time of walking with a walker in the PFN group was  $8.8 \pm 2.9$  d, while that in the arthroplasty group was  $7.8 \pm 1.6$  d. The weight-bearing time of the arthroplasty group was significantly shorter than that of the PFN group. The time of weight bearing reflects the time of postoperative bed rest. Shorter postoperative bed rest and hospital stay can reduce the complications caused by long-term bed rest, but a large amount of intraoperative blood loss and excessive operation time are not conducive to patients' self-repair.

**Type of anesthesia:** The type of anesthesia is a preoperative factor. Three studies recorded the type of anesthesia. The results showed that there was no significant difference between the arthroplasty and PFN groups, meaning that the anesthetic will not affect the therapeutic effect (RR: 0.99, 95% CI: 0.62–1.59,  $P = 0.98$ ) (Figure 9).

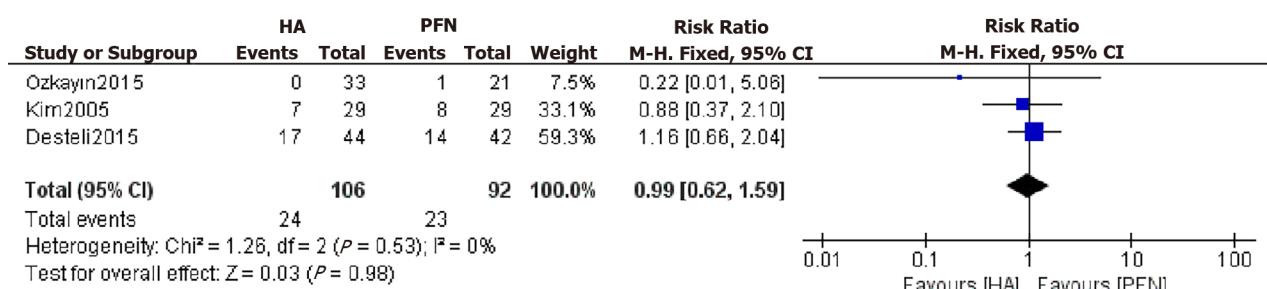
## DISCUSSION

The incidence rate of intertrochanteric fracture accounts for 50% of hip fractures[21]. Most intertrochanteric fractures are comminuted and unstable because of the lower bone strength in elderly people. It is difficult to achieve satisfactory results in conservative treatment, while surgical treatment can reduce complications and contribute to rehabilitation training. Therefore, we conducted a meta-analysis of RCTs and evaluated the clinical outcomes of elderly patients with unstable IFFs who underwent PFN or arthroplasty. In this meta-analysis, the type of anesthesia and fracture classification did not affect the clinical outcome. In the AO/OTA classification of IFFs, types A1 and A2.1 were considered stable fractures, while the rest were considered unstable fractures. In this study, the number of unstable fractures accounted for 60% of the included study reports. However, since the study reports did not list the incidence of adverse events in different classifications, no subgroup analysis was conducted. Compared with the PFN group, the arthroplasty group had earlier time to weight bearing, shorter hospital stay, more intraoperative bleeding, and longer operation time. There were no significant differences in postoperative complications or overall mortality between the two groups. The HHS at the final follow-up was significantly better in the PFN group than in the arthroplasty group.

The recovery of hip function is the most important concern of clinicians and patients. The HHS is the most common score in the clinical evaluation of hip function. The higher the score, the better the function. It comprehensively evaluates the affected limb from the four aspects of deformity, range of motion, pain and function to judge the degree of patients returning to normal activities of life. Among the four studies, only Desteli[15] used EQ-5D and mobility scores, while other studies used HHS. With



**Figure 8 Forest plot diagram of the length of hospital stay compared arthroplasty and proximal femoral nail[15,17].** HA: arthroplasty; PFN: proximal femoral nail; CI: confidence interval.



**Figure 9 Forest plot diagram of anesthesia compared between arthroplasty and proximal femoral nail[14,15,17].** HA: arthroplasty; PFN: proximal femoral nail; CI: confidence interval.

the exception of Jolly[18], which was followed up for 12 mo, all other studies were followed up for  $> 24$  mo, and the final HHS of all the studies was higher in the PFN group than in the arthroplasty group, indicating that with fracture healing, when the internal fixation was stable, the limb function provided by arthroplasty was not superior to PFNs. Arthroplasty does not provide significantly better hip function than PFNs. This is different from the report of Tu *et al*[21], who meta-analyzed the HHS of two RCTs and two retrospective comparative control trials, and showed that there was no significant difference between arthroplasty and PFNs. We think this may be due to the different types of studies included by us and them; additionally, retrospective studies may have patient selection bias.

Postoperative overall mortality is an important factor for the prognosis of hip fracture, and a point of concern to patients and their families. Most elderly patients have medical diseases of other systems, and they are more likely to die under the stimulation of trauma and surgery. Some studies record that arthroplasty of IFFs in elderly patients can reduce mortality by reducing bed time[9]. In contrast, some studies have reported that the postoperative mortality of the arthroplasty group is significantly higher than that of internal fixation[22,23]. In this study, a total of three articles reported overall mortality during the follow-up period, and the results showed that there was no significant difference between the arthroplasty and PFN groups, indicating that arthroplasty cannot reduce the incidence of postoperative mortality. It is important to note that although the difference was not significant, the number of deaths in the joint replacement group increased with the extension of follow-up time, which is consistent with other studies in the past 3 years[18,21,24].

There are many postoperative complications of unstable IFFs in elderly patients, including bedsores, respiratory infections, superficial wound infections, deep infections, deep vein thrombosis (DVT), periprosthetic fractures, nonunion of fractures, urinary tract infections, and dislocations of the prosthesis. Some of the postoperative complications were reported in the four studies included here. After meta-analysis, we found that there was no significant difference between arthroplasty and PFNs. This is consistent with the results of a previous study[8]. Arthroplasty may reduce the incidence of long-term bed rest complications such as DVT and bedsores by reducing the time spent in bed, but it cannot reduce the overall incidence of postoperative complications.

Operation time and blood loss are important indicators to evaluate the quality of the surgery and judge the prognosis. The operation time is usually proportional to the amount of intraoperative blood loss. The longer the operation time, the more blood loss there is, which increases cardiovascular and respiratory complications and risk of wound infection. In this study, the intraoperative blood loss and operation time of the

arthroplasty group were significantly greater than those of the PFN group, which is consistent with the results of another previous study[13]. Before 2005, arthroplasty was not widely used in the clinical treatment of IFFs. Many doctors are less proficient in arthroplasty, which results in longer operation time and more blood loss than traditional internal fixation methods. Notably, the average amount of bleeding reported by Kim was as high as 511 mL and close to three times that reported by Jolly [18] in 2019. We think that this is related to the technical level and proficiency of the surgeons. In particular, the surgical technique of calcar-replacement prosthesis is more advanced. When dealing with more comminuted unstable fractures, it is more difficult to fix. Sometimes it even needs to be fixed with steel wire and the amount of bleeding and operation time are also significantly increased. Authen[25] points out that doctors with less surgical experience have higher rates of adverse events than experienced doctors have. This may be the reason for the high heterogeneity of the outcomes in this study.

The weight-bearing time greatly affects the overall length of hospital stay. Salpakoski[26] noted that walking after internal fixation is more difficult than walking after joint replacement. Kim[14] and Jolly[18] also reported that the arthroplasty group had an earlier loading time. The two articles included in this study reported the times of full and half weight bearing. The arthroplasty group was capable of weight bearing significantly earlier than the PFN group was. Similarly, the length of hospital stay in the arthroplasty group was significantly shorter. These differences are related to many factors. Arthroplasty can allow patients to get out of bed early; promote the recovery of limb function; avoid complications such as bedsores caused by long-term bed rest [27,28]; significantly reduce the length of hospital stay and the economic burden of patients; help patients recover their mental health and return to normal life; and quickly improve their quality of life. This is why, in recent years, an increasing number of clinicians have considered arthroplasty to treat unstable IFFs in elderly patients. Moreover, osteoarthritis of the hip in elderly patients is a major factor for clinicians to consider when using arthroplasty in the treatment of IFFs.

The most important limitation of the study is that the number of RCTs was slightly lower, so the strength of the evidence was inadequate. Other limitations are the experience of surgeons and the blinding of inclusion studies, which may influence the heterogeneity. There was significant heterogeneity in several important parameters and the cause of this heterogeneity was often not identified and controlled for. It is likely that heterogeneity arose from the different patient populations and center experiences. Since the original literature does not provide relevant data, we cannot discuss the difference between different types of fractures. It is necessary for our further study to collect more high-quality RCTs for analysis.

## CONCLUSION

As a classic method for the treatment of unstable IFFs, PFNs have been widely recognized in clinical practice. Their clinical effect is definite, and the disadvantages of needing to lie in bed after surgery also exist all the time. Therefore, in recent years, some researchers have been trying to find evidence from clinical studies, aiming to use arthroplasty to replace PFNs in the treatment of unstable IFFs. However, while there are differences in the results reported in the literature, there is no conclusion thus far. The results of this study indicate that, compared with PFNs, although arthroplasty can shorten bed time and hospital stay, it cannot reduce postoperative complications and mortality of elderly patients with unstable IFFs; moreover, the operation time and blood loss are significantly increased. PFNs were associated with better limb function after stabilization of fracture healing with longer follow-up. Therefore, joint replacement is not a substitute for PFNs in the treatment of elderly patients with unstable IFFs.

## ACKNOWLEDGMENTS

We thank all authors for their helpful conversations about this manuscript.

## ARTICLE HIGHLIGHTS

**Research background**

Proximal femoral nails (PFNs) and arthroplasty are common methods for the treatment of intertrochanteric femoral fractures (IFFs), but there is no consensus on which treatment is better for elderly patients with unstable fractures.

**Research motivation**

At present, many retrospective studies have compared and analyzed the clinical efficacy of arthroplasty and PFNs in the treatment of unstable IFFs, but the results differed. To explore whether arthroplasty can really replace PFNs as the preferred treatment, we conducted this study.

**Research objectives**

To compare the clinical outcomes of arthroplasty and PFNs in the treatment of unstable IFFs in elderly patients and determine whether arthroplasty can replace traditional PFNs.

**Research methods**

Through meta-analysis and systematic review, we summarized the randomized controlled trials (RCTs) in the past 20 years. According to the inclusion and exclusion criteria, the results of four RCTs were finally included for analysis. According to the data given in the literature, the Harris Hip Score (HHS), mortality, complications, blood loss, operation time and hospital stay, weight-bearing walking time and anesthesia of the two methods were analyzed and compared.

**Research results**

The joint replacement group had earlier weight-bearing walking time and shorter hospital stay, but the HHS, bleeding volume and operation time in the PFN group were better. There were no significant differences in mortality, complications and anesthesia between the two groups.

**Research conclusions**

Based on available evidence, arthroplasty cannot replace PFNs in the treatment of unstable IFFs in elderly patients.

**Research perspectives**

More high-quality clinical studies are needed to judge whether joint replacement can replace PFNs as the first choice for the treatment of unstable IFFs in elderly patients.

## REFERENCES

- 1 Lu Y, Uppal HS. Hip Fractures: Relevant Anatomy, Classification, and Biomechanics of Fracture and Fixation. *Geriatr Orthop Surg Rehabil* 2019; **10**: 2151459319859139 [PMID: 31321116 DOI: 10.1177/2151459319859139]
- 2 Dehghan N, McKee MD. What's New in Orthopaedic Trauma. *J Bone Joint Surg Am* 2020; **102**: 1137-1141 [PMID: 32618920 DOI: 10.2106/BJJS.20.00425]
- 3 Ballal MS, Emms N, Thomas G. Proximal femoral nail failures in extracapsular fractures of the hip. *J Orthop Surg (Hong Kong)* 2008; **16**: 146-149 [PMID: 18725661 DOI: 10.1177/230949900801600203]
- 4 Ertürer RE, Sönmez MM, Sari S, Seçkin MF, Kara A, Öztürk I. Intramedullary osteosynthesis of instable intertrochanteric femur fractures with Profin® nail in elderly patients. *Acta Orthop Traumatol Turc* 2012; **46**: 107-112 [PMID: 22491435 DOI: 10.3944/AOTT.2012.2501]
- 5 Koval KJ. Intramedullary nailing of proximal femur fractures. *Am J Orthop (Belle Mead NJ)* 2007; **36**: 4-7 [PMID: 17547351]
- 6 Bhandari M, Devereaux PJ, Swionkowski MF, Tornetta P 3rd, Obrebsky W, Koval KJ, Nork S, Sprague S, Schemitsch EH, Guyatt GH. Internal fixation compared with arthroplasty for displaced fractures of the femoral neck. A meta-analysis. *J Bone Joint Surg Am* 2003; **85**: 1673-1681 [PMID: 12954824 DOI: 10.2106/00004623-200309000-00004]
- 7 Camurcu Y, Cobden A, Sofu H, Saklavci N, Kis M. What Are the Determinants of Mortality After Cemented Bipolar Hemiarthroplasty for Unstable Intertrochanteric Fractures in Elderly Patients? *J Arthroplasty* 2017; **32**: 3038-3043 [PMID: 28550964 DOI: 10.1016/j.arth.2017.04.042]
- 8 Kumar P, Rajnish RK, Sharma S, Dhillon MS. Proximal femoral nailing is superior to

- hemiarthroplasty in AO/OTA A2 and A3 intertrochanteric femur fractures in the elderly: a systematic literature review and meta-analysis. *Int Orthop* 2020; **44**: 623-633 [PMID: [31201487](#) DOI: [10.1007/s00264-019-04351-9](#)]
- 9 **Grimsrud C**, Monzon RJ, Richman J, Ries MD. Cemented hip arthroplasty with a novel cerclage cable technique for unstable intertrochanteric hip fractures. *J Arthroplasty* 2005; **20**: 337-343 [PMID: [15809952](#) DOI: [10.1016/j.arth.2004.04.017](#)]
  - 10 **Park MS**, Cho HM, Kim JH, Shin WJ. Cementless bipolar hemiarthroplasty using a rectangular cross-section stem for unstable intertrochanteric fractures. *Hip Int* 2013; **23**: 316-322 [PMID: [23760747](#) DOI: [10.5301/hipint.5000024](#)]
  - 11 **Feehan LM**, Tang CS, Oxland TR. Early controlled passive motion improves early fracture alignment and structural properties in a closed extra-articular metacarpal fracture in a rabbit model. *J Hand Surg Am* 2007; **32**: 200-208 [PMID: [17275595](#) DOI: [10.1016/j.jhsa.2006.11.004](#)]
  - 12 **Singh V**, Bhakta P, Zietak E, Hussain A. Bone cement implantation syndrome: a delayed postoperative presentation. *J Clin Anesth* 2016; **31**: 274-277 [PMID: [27185726](#) DOI: [10.1016/j.jclinane.2016.01.041](#)]
  - 13 **Nie B**, Wu D, Yang Z, Liu Q. Comparison of intramedullary fixation and arthroplasty for the treatment of intertrochanteric hip fractures in the elderly: A meta-analysis. *Medicine (Baltimore)* 2017; **96**: e7446 [PMID: [28682912](#) DOI: [10.1097/MD.0000000000007446](#)]
  - 14 **Kim SY**, Kim YG, Hwang JK. Cementless calcar-replacement hemiarthroplasty compared with intramedullary fixation of unstable intertrochanteric fractures. A prospective, randomized study. *J Bone Joint Surg Am* 2005; **87**: 2186-2192 [PMID: [16203881](#) DOI: [10.2106/JBJS.D.02768](#)]
  - 15 **Desteli EE**, İmren Y, Erdoğan M, Aydagün Ö. Quality of Life Following Treatment of Trochanteric Fractures with Proximal Femoral Nail versus Cementless Bipolar Hemiarthroplasty in Elderly. *Clin Invest Med* 2015; **38**: E63-E72 [PMID: [25864998](#) DOI: [10.25011/cim.v38i1.22577](#)]
  - 16 **Moher D**, Liberati A, Tetzlaff J, Altman DG; PRISMA Group. Preferred reporting items for systematic reviews and meta-analyses: the PRISMA statement. *BMJ* 2009; **339**: b2535 [PMID: [19622551](#) DOI: [10.1136/bmj.b2535](#)]
  - 17 **Özkayın N**, Okçu G, Aktuğlu K. Intertrochanteric femur fractures in the elderly treated with either proximal femur nailing or hemiarthroplasty: A prospective randomised clinical study. *Injury* 2015; **46** Suppl 2: S3-S8 [PMID: [26052057](#) DOI: [10.1016/j.injury.2015.05.024](#)]
  - 18 **Jolly A**, Bansal R, More AR, Pagadala MB. Comparison of complications and functional results of unstable intertrochanteric fractures of femur treated with proximal femur nails and cemented hemiarthroplasty. *J Clin Orthop Trauma* 2019; **10**: 296-301 [PMID: [30828197](#) DOI: [10.1016/j.jcot.2017.09.015](#)]
  - 19 **Semba RD**, Garrett E, Johnson BA, Guralnik JM, Fried LP. Vitamin D deficiency among older women with and without disability. *Am J Clin Nutr* 2000; **72**: 1529-1534 [PMID: [11101482](#) DOI: [10.1093/ajcn/72.6.1529](#)]
  - 20 **Moreira ML**, Neto LV, Madeira M, Lopes RF, Farias MLF. Vitamin D Deficiency and Its Influence on Bone Metabolism and Density in a Brazilian Population of Healthy Men. *J Clin Densitom* 2018; **21**: 91-97 [PMID: [28233710](#) DOI: [10.1016/j.jocd.2017.01.008](#)]
  - 21 **Tu DP**, Liu Z, Yu YK, Xu C, Shi XL. Internal Fixation versus Hemiarthroplasty in the Treatment of Unstable Intertrochanteric Fractures in the Elderly: A Systematic Review and Meta-Analysis. *Orthop Surg* 2020; **12**: 1053-1064 [PMID: [32691520](#) DOI: [10.1111/os.12736](#)]
  - 22 **Yang ZB**, Wu PH, Wong PK, Huang ZY, Fu M, Liao WM, He AS, Kang Y. Better Prognosis of Senile Patients with Intertrochanteric Femoral Fracture by Treatment with Open Reduction Internal Fixation than by Hip Arthroplasty. *J Invest Surg* 2018; **31**: 431-437 [PMID: [28722498](#) DOI: [10.1080/08941939.2017.1333177](#)]
  - 23 **Kesmezacar H**, Oğüt T, Bilgili MG, Gökay S, Tenekecioğlu Y. [Treatment of intertrochanteric femur fractures in elderly patients: internal fixation or hemiarthroplasty]. *Acta Orthop Traumatol Turc* 2005; **39**: 287-294 [PMID: [16269874](#)]
  - 24 **Ju JB**, Zhang PX, Jiang BG. Hip Replacement as Alternative to Intramedullary Nail in Elderly Patients with Unstable Intertrochanteric Fracture: A Systematic Review and Meta-Analysis. *Orthop Surg* 2019; **11**: 745-754 [PMID: [31663280](#) DOI: [10.1111/os.12532](#)]
  - 25 **Authen AL**, Dybvik E, Furnes O, Gjertsen JE. Surgeon's experience level and risk of reoperation after hip fracture surgery: an observational study on 30,945 patients in the Norwegian Hip Fracture Register 2011-2015. *Acta Orthop* 2018; **89**: 496-502 [PMID: [29860911](#) DOI: [10.1080/17453674.2018.1481588](#)]
  - 26 **Salpakoski A**, Kallinen M, Kiviranta I, Alen M, Portegijs E, Jämsen E, Ylinen J, Rantanen T, Sipilä S. Type of surgery is associated with pain and walking difficulties among older people with previous hip fracture. *Geriatr Gerontol Int* 2016; **16**: 754-761 [PMID: [26178923](#) DOI: [10.1111/ggi.12552](#)]
  - 27 **Kuru T**, Olçar HA. Effects of early mobilization and weight bearing on postoperative walking ability and pain in geriatric patients operated due to hip fracture: a retrospective analysis. *Turk J Med Sci* 2020; **50**: 117-125 [PMID: [31742370](#) DOI: [10.3906/sag-1906-57](#)]
  - 28 **Iosifidis M**, Iliopoulos E, Panagiotou A, Apostolidis K, Traios S, Giantsis G. Walking ability before and after a hip fracture in elderly predict greater long-term survivorship. *J Orthop Sci* 2016; **21**: 48-52 [PMID: [26755386](#) DOI: [10.1016/j.jos.2015.09.009](#)]



Published by **Baishideng Publishing Group Inc**  
7041 Koll Center Parkway, Suite 160, Pleasanton, CA 94566, USA

**Telephone:** +1-925-3991568

**E-mail:** [bpgoffice@wjgnet.com](mailto:bpgoffice@wjgnet.com)

**Help Desk:** <https://www.f6publishing.com/helpdesk>

<https://www.wjgnet.com>

