

World Journal of *Clinical Cases*

World J Clin Cases 2022 February 26; 10(6): 1754-2052



Contents

Thrice Monthly Volume 10 Number 6 February 26, 2022

OPINION REVIEW

- 1754** Gut-brain axis: Focus on gut metabolites short-chain fatty acids
Guo C, Huo YJ, Li Y, Han Y, Zhou D

MINIREVIEWS

- 1764** Association between direct-acting antiviral agents in hepatitis C virus treatment and hepatocellular carcinoma occurrence and recurrence: The endless debate
Kamal A, Elsheaita A, Abdelnabi M

ORIGINAL ARTICLE

Retrospective Cohort Study

- 1775** Effects of bilirubin on perioperative myocardial infarction and its long-term prognosis in patients undergoing percutaneous coronary intervention
Li Y, Li DB, Zhao LD, Lv QB, Wang Y, Ren YF, Zhang WB
- 1787** Disease exacerbation is common in inflammatory bowel disease patients treated with immune checkpoint inhibitors for malignancy
Rubin SJS, Balabanis T, Gubatan J, Habtezion A
- 1795** Multidrug-resistant organisms in intensive care units and logistic analysis of risk factors
Han Y, Zhang J, Zhang HZ, Zhang XY, Wang YM

Retrospective Study

- 1806** Change and impact of left ventricular global longitudinal strain during transcatheter aortic valve implantation
Zhang H, Xie JJ, Li RJ, Wang YL, Niu BR, Song L, Li J, Yang Y

Observational Study

- 1815** Early detection of noise-induced hearing loss
Meng ZL, Chen F, Zhao F, Gu HL, Zheng Y
- 1826** Empathetic nursing with mindful cognitive therapy for fatigue, depression, and negative emotions in leukemia patients undergoing long-term chemotherapy
Lu YY, Lu XM, Shao CY, Wang CC, Xu TT, Zhang BL

Prospective Study

- 1834** Superior pancreatic lymphadenectomy with portal vein priority *via* posterior common hepatic artery approach in laparoscopic radical gastrectomy
Zhang YJ, Xiang RC, Li J, Liu Y, Xie SM, An L, Li HL, Mai G

Randomized Controlled Trial

- 1843** Systematic nursing interventions in gastric cancer: A randomized controlled study
He F, He RX

META-ANALYSIS

- 1852** Impact of adding opioids to paravertebral blocks in breast cancer surgery patients: A systematic review and meta-analysis
Chen MH, Chen Z, Zhao D

CASE REPORT

- 1863** Multiple different remote epidural hematomas after craniotomy: A case report
He Q, Tao CY, Fu RH, You C
- 1869** Tuberculous pericarditis-a silent and challenging disease: A case report
Lucero OD, Bustos MM, Ariza Rodríguez DJ, Perez JC
- 1876** Transileocolic endovascular treatment by a hybrid approach for severe acute portal vein thrombosis with bowel necrosis: Two case reports
Shirai S, Ueda T, Sugihara F, Yasui D, Saito H, Furuki H, Kim S, Yoshida H, Yokobori S, Hayashi H, Kumita SI
- 1883** Efficacy of EGFR-TKI sequential therapy in patients with EGFR exon 19 insertion-positive non-small-cell lung cancer: A case report
Shan BB, Li Y, Zhao C, An XQ, Zhang QM
- 1889** Novel compound heterozygous variants in the TAF6 gene in a patient with Alazami-Yuan syndrome: A case report
Lin SZ, Feng JH, Sun LP, Ma HW, Wang WQ, Li JY
- 1896** Asymmetric limb weakness in Guillain-Barré syndrome: Three case reports
Hu M, Li X, Wong HY, Feng XG, Wang YZ, Zhang GR
- 1903** Modified treatment of knee osteoarthritis complicated with femoral varus deformity: A case report
Xu SM, Li W, Zhang DB, Bi HY, Gu GS
- 1909** Novel HNF1A gene mutation in maturity-onset diabetes of the young: A case report
Xu Q, Kan CX, Hou NN, Sun XD
- 1914** Cerebral corridor creator for resection of trigone ventricular tumors: Two case reports
Liu XW, Lu WR, Zhang TY, Hou XS, Fa ZQ, Zhang SZ
- 1922** Left abdominal wall proliferative myositis resection and patch repair: A case report
Xing RW, Nie HQ, Zhou XF, Zhang FF, Mou YH
- 1929** Concurrent ankylosing spondylitis and myelodysplastic syndrome: A case report
Xu GH, Lin J, Chen WQ

- 1937** Life-threatening subclavian artery bleeding following percutaneous coronary intervention with stent implantation: A case report and review of literature
Shi F, Zhang Y, Sun LX, Long S
- 1946** Cryptogenic organizing pneumonia associated with pregnancy: A case report
Lee YJ, Kim YS
- 1952** Eosinophilia complicated with venous thromboembolism: A case report
Su WQ, Fu YZ, Liu SY, Cao MJ, Xue YB, Suo FF, Liu WC
- 1961** Neck and mediastinal hematoma caused by a foreign body in the esophagus with diagnostic difficulties: A case report
Wang LP, Zhou ZY, Huang XP, Bai YJ, Shi HX, Sheng D
- 1966** Therapeutic endoscopy of a Dieulafoy lesion in a 10-year-old girl: A case report
Chen Y, Sun M, Teng X
- 1973** Cavernous hemangioma of an intrapancreatic accessory spleen mimicking a pancreatic tumor: A case report
Huang JY, Yang R, Li JW, Lu Q, Luo Y
- 1981** Surgery and antibiotics for the treatment of lupus nephritis with cerebral abscesses: A case report
Hu QD, Liao LS, Zhang Y, Zhang Q, Liu J
- 1991** Median arcuate ligamentum syndrome: Four case reports
Kim JE, Rhee PL
- 1998** Novel ABCB4 mutations in an infertile female with progressive familial intrahepatic cholestasis type 3: A case report
Liu TF, He JJ, Wang L, Zhang LY
- 2007** Primary duodenal dedifferentiated liposarcoma: A case report and literature review
Kim NI, Lee JS, Choi C, Nam JH, Choi YD, Kim HJ, Kim SS
- 2015** Implant site development using titanium plate and platelet-rich fibrin for congenitally missed maxillary lateral incisors: A case report
Zhang TS, Mudalal M, Ren SC, Zhou YM
- 2023** Successful embolization of an intrahepatic portosystemic shunt using balloon-occluded retrograde transvenous obliteration: A case report
Saito H, Murata S, Sugihara F, Ueda T, Yasui D, Miki I, Hayashi H, Kumita SI
- 2030** Bilateral pneumothorax and pneumomediastinum during colonoscopy in a patient with intestinal Behcet's disease: A case report
Mu T, Feng H
- 2036** Acute kidney injury due to intravenous detergent poisoning: A case report
Park S, Ryu HS, Lee JK, Park SS, Kwon SJ, Hwang WM, Yun SR, Park MH, Park Y

- 2045** Vaginal enterocele after cystectomy: A case report

Liu SH, Zhang YH, Niu HT, Tian DX, Qin F, Jiao W

ABOUT COVER

Editorial Board Member of *World Journal of Clinical Cases*, Navdeep Singh, MBBS, MS, Assistant Professor, Division of Transplantation, Department of Surgery, The Ohio State University, Columbus, OH 43210, United States.
navdeep.singh@osumc.edu

AIMS AND SCOPE

The primary aim of *World Journal of Clinical Cases* (WJCC, *World J Clin Cases*) is to provide scholars and readers from various fields of clinical medicine with a platform to publish high-quality clinical research articles and communicate their research findings online.

WJCC mainly publishes articles reporting research results and findings obtained in the field of clinical medicine and covering a wide range of topics, including case control studies, retrospective cohort studies, retrospective studies, clinical trials studies, observational studies, prospective studies, randomized controlled trials, randomized clinical trials, systematic reviews, meta-analysis, and case reports.

INDEXING/ABSTRACTING

The WJCC is now indexed in Science Citation Index Expanded (also known as SciSearch®), Journal Citation Reports/Science Edition, Scopus, PubMed, and PubMed Central. The 2021 Edition of Journal Citation Reports® cites the 2020 impact factor (IF) for WJCC as 1.337; IF without journal self cites: 1.301; 5-year IF: 1.742; Journal Citation Indicator: 0.33; Ranking: 119 among 169 journals in medicine, general and internal; and Quartile category: Q3. The WJCC's CiteScore for 2020 is 0.8 and Scopus CiteScore rank 2020: General Medicine is 493/793.

RESPONSIBLE EDITORS FOR THIS ISSUE

Production Editor: *Ying-Yi Yuan*, Production Department Director: *Xu Guo*, Editorial Office Director: *Jin-Lei Wang*.

NAME OF JOURNAL

World Journal of Clinical Cases

ISSN

ISSN 2307-8960 (online)

LAUNCH DATE

April 16, 2013

FREQUENCY

Thrice Monthly

EDITORS-IN-CHIEF

Bao-Gan Peng, Jerzy Tadeusz Chudek, George Kontogeorgos, Maurizio Serati, Ja Hyeon Ku

EDITORIAL BOARD MEMBERS

<https://www.wjgnet.com/2307-8960/editorialboard.htm>

PUBLICATION DATE

February 26, 2022

COPYRIGHT

© 2022 Baishideng Publishing Group Inc

INSTRUCTIONS TO AUTHORS

<https://www.wjgnet.com/bpg/gerinfo/204>

GUIDELINES FOR ETHICS DOCUMENTS

<https://www.wjgnet.com/bpg/GerInfo/287>

GUIDELINES FOR NON-NATIVE SPEAKERS OF ENGLISH

<https://www.wjgnet.com/bpg/gerinfo/240>

PUBLICATION ETHICS

<https://www.wjgnet.com/bpg/GerInfo/288>

PUBLICATION MISCONDUCT

<https://www.wjgnet.com/bpg/gerinfo/208>

ARTICLE PROCESSING CHARGE

<https://www.wjgnet.com/bpg/gerinfo/242>

STEPS FOR SUBMITTING MANUSCRIPTS

<https://www.wjgnet.com/bpg/GerInfo/239>

ONLINE SUBMISSION

<https://www.f6publishing.com>



Tuberculous pericarditis-a silent and challenging disease: A case report

Oscar David Lucero, Marlon Mauricio Bustos, Darwin Jhoan Ariza Rodríguez, Juan Camilo Perez

Specialty type: Medicine, research and experimental

Provenance and peer review: Unsolicited article; Externally peer reviewed.

Peer-review model: Single blind

Peer-review report's scientific quality classification

Grade A (Excellent): 0
Grade B (Very good): B, B
Grade C (Good): 0
Grade D (Fair): D
Grade E (Poor): 0

P-Reviewer: Basu S, Keikha M, Samadder S

Received: June 21, 2021

Peer-review started: June 21, 2021

First decision: July 26, 2021

Revised: September 7, 2021

Accepted: January 19, 2022

Article in press: January 19, 2022

Published online: February 26, 2022



Oscar David Lucero, Marlon Mauricio Bustos, Department of Internal Medicine, Hospital Universitario San Ignacio, Bogotá 110231, Colombia

Darwin Jhoan Ariza Rodríguez, Juan Camilo Perez, Internal Medicine Resident, Pontificia Universidad Javeriana, Bogotá 110231, Colombia

Corresponding author: Oscar David Lucero, MD, Doctor, Department of Internal Medicine, Hospital Universitario San Ignacio, Cra. 7 No. 40-62, Bogotá 110231, Colombia.
oscardavidlucero21@gmail.com

Abstract

BACKGROUND

Tuberculous pericarditis (TP) remains a challenge for endemic countries. In developing countries, one to two percent of patients with pulmonary tuberculosis develops TP.

CASE SUMMARY

A 49-year-old woman presented with dyspnea, chest pain and dry cough. On physical examination, veiled heart sounds were found. The electrocardiogram showed low-voltage complexes and the transthoracic echocardiography revealed a large and free-looking pericardial effusion. The patient was taken for an open pericardiotomy. The pericardial fluid revealed high levels of adenosine deaminase and Ziehl-Neelsen stain showed acid-fast bacilli. Polymerase chain reaction study for *Mycobacterium tuberculosis* in pericardial fluid was positive. The patient received tetra conjugate management with adequate clinical response after the first week of treatment and resolution of fever and chest pain.

CONCLUSION

In cases of TP, obtaining pericardial fluid and/or pericardial biopsy is the most efficient strategy to confirm the diagnosis. Early diagnosis of this entity will allow physicians to initiate timely treatment, avoid complications and improve the patient's clinical outcome, so we consider the description of this case pertinent and its review in the literature.

Key Words: Tuberculosis; Pericardial disease; Tuberculous pericarditis; Pericardial effusion; *Mycobacterium tuberculosis*; Case report

©The Author(s) 2022. Published by Baishideng Publishing Group Inc. All rights reserved.

Core Tip: Tuberculous pericarditis should be suspected in the evaluation of all cases of pericarditis that do not have a self-limited course. The present case identifies the usefulness of the study of Adenosine deaminase in the pericardial fluid and the performance of polymerase chain reaction for *Mycobacterium tuberculosis* in the biopsy, thanks to which the diagnosis could be confirmed. Management is based on the use of rifampin, isoniazid, ethambutol, and pyrazinamide.

Citation: Lucero OD, Bustos MM, Ariza Rodríguez DJ, Perez JC. Tuberculous pericarditis-a silent and challenging disease: A case report. *World J Clin Cases* 2022; 10(6): 1869-1875

URL: <https://www.wjgnet.com/2307-8960/full/v10/i6/1869.htm>

DOI: <https://dx.doi.org/10.12998/wjcc.v10.i6.1869>

INTRODUCTION

Tuberculosis (TB) is a transmissible disease and it is the main cause of morbimortality and one of the ten leading causes of death worldwide. It is also the leading cause of death from a single infectious agent [ahead of human immunodeficiency virus (HIV)/AIDS]. A quarter of the world's population is infected with *Mycobacterium tuberculosis* and thus is at risk of developing the disease[1]. In developing countries, coinfection with the HIV is associated with a higher mortality[2]. Although the lung is the target organ for TB, any other organ can be affected. Extrapulmonary TB accounts for 10%-20% of the clinical presentation suffered by immunocompetent patients[3]. Approximately 1% to 2% of patients with pulmonary TB have tuberculous pericarditis (TP) and this carries a high mortality rate (17% to 40% over 6 mo)[4].

Pericarditis can be caused by infectious agents (*e.g.*, viral and bacterial) or can be non-infectious in origin (*e.g.*, systemic inflammatory diseases, cancer, and post-cardiac injury syndromes). TB is a major cause of pericarditis in developing countries, but accounts for less than 5% of cases in developed countries, where viral causes are responsible for 80% to 90% of the cases[5]. TP accounts for approximately 4% of acute pericarditis, 7% of cardiac tamponade and 6% of constrictive pericarditis cases[6]. *Mycobacterium tuberculosis* usually affects the pericardium by retrograde lymphatic spread from the peritracheal, peribronchial, or mediastinal lymph nodes or by hematogenous spread of a primary TB infection and is rarely affected by contiguous spread of a tuberculous lesion in the lung or hematogenous spread of a distant focus[7].

CASE PRESENTATION

Chief complaints

A 49-year-old woman came to the emergency room for unquantified fever peaks and intermittent chest pain lasting 2 mo.

History of present illness

Unquantified fever peaks and intermittent chest pain lasting 2 mo which increased in intensity.

History of past illness

During the 2 wk prior to admission, the patient experienced dyspnea, cough and hyaline expectoration.

Personal and family history

The patient had a surgical history of liposuction and augmentation mammoplasty.

Physical examination

The patient was febrile with a temperature of 39.5 °C. Her heart rate 117 beats *per* minute, blood pressure 100/60 mmHg, respiratory rate of 24 breaths *per* minute and her oxygen saturation was 80%. The patient's neck veins were distended and heart sounds were muffled.

Laboratory examinations

Electrocardiogram was done (Figure 1) and showed sinus tachycardia and low-voltage complexes in the limb and precordial leads. There were no alterations in PQ interval or ST-segment. Deaminase level in the pericardial fluid of 36.50 U/L (reference range, 0 to 9 U/L). The cytology of the pericardial fluid was of lymphocytic predominance and examination of the pericardial fluid revealed acid-fast bacilli. Polymerase chain reaction (PCR) study of pericardial fluid was positive for *Mycobacterium tuberculosis*.

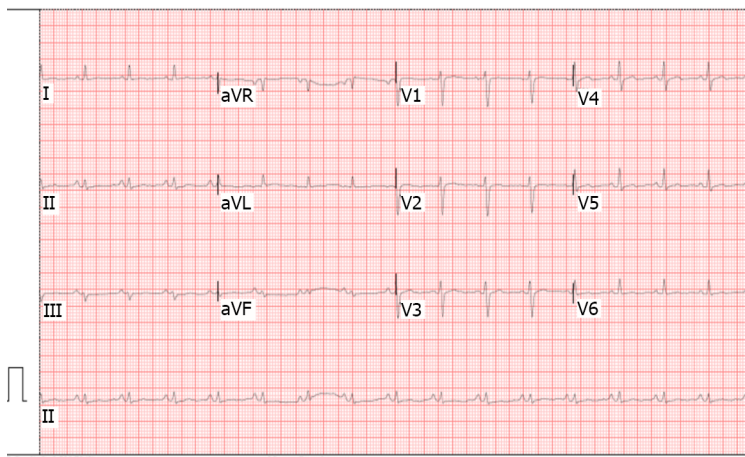


Figure 1 Low-voltage electrocardiogram (defined as QRS < 5 mm in limb shunts).

Imaging examinations

Chest x-ray was done (Figure 2) showing a generalized increase of the mediastinal cardiac silhouette, suggestive of pericardial effusion. There was an adequate pulmonary vascularization pattern. Pleuropulmonary lesions were not seen. Transthoracic echocardiography revealed a large and free-looking pericardial effusion, with an anterior interface of 17 mm and a posterior interface of 27 mm. The right cavities had a partial diastolic collapse, between 20%-30% (Figure 3). High-resolution chest tomography revealed a heart of normal size and there was evidence of pericardial effusion without alteration of the ventricular walls with a thickness of up to 25 mm (Figure 4).

MULTIDISCIPLINARY EXPERT CONSULTATION

TP was made. HIV was negative.

FINAL DIAGNOSIS

Tuberculous pericarditis.

TREATMENT

The patient received treatment each day with isoniazid 300 mg, rifampin 600 mg, pyrazinamide 1600 mg, and ethambutol 1100 mg for 2 mo. This was followed by rifampin and isoniazid for an additional 4 mo along with prednisolone for 6 wk.

OUTCOME AND FOLLOW-UP

In the days following pericardiocentesis and initiation of tetraconjugate management for TB, the patient progressed satisfactorily with improved hemodynamic parameters and fever resolution.

DISCUSSION

TP has a diverse clinical picture and should be considered in the evaluation of non-self-limiting pericarditis cases. Despite the fact that the prevalence of TB has been reduced in general, the cases of extrapulmonary TB remains stable; approximately 1050000 new cases were reported in the world in 2018[8]. In developing countries, one to two percent of pulmonary TB patients develop TP. However, it can also appear as an isolated extrapulmonary form[9]. There are few studies that evaluate the prevalence of TP in Colombia, and generally, it is considered that there is an underdiagnosis of the disease. 13626 new cases of TB were reported during 2020, of which 83% corresponded to pulmonary TB and 17% to extrapulmonary TB, while 1.6% of these corresponded to TP[9]. Furthermore, in Colombia, a

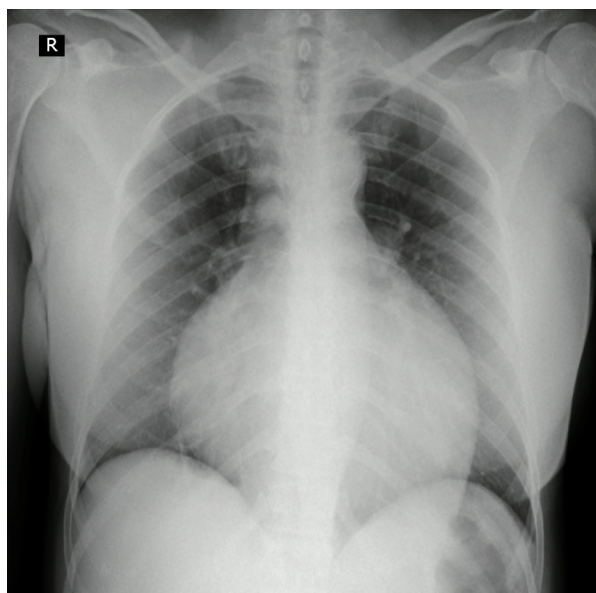


Figure 2 Chest X-ray. Global cardiomegaly with enlarging cardiothoracic ratio and "water bottle" configuration.

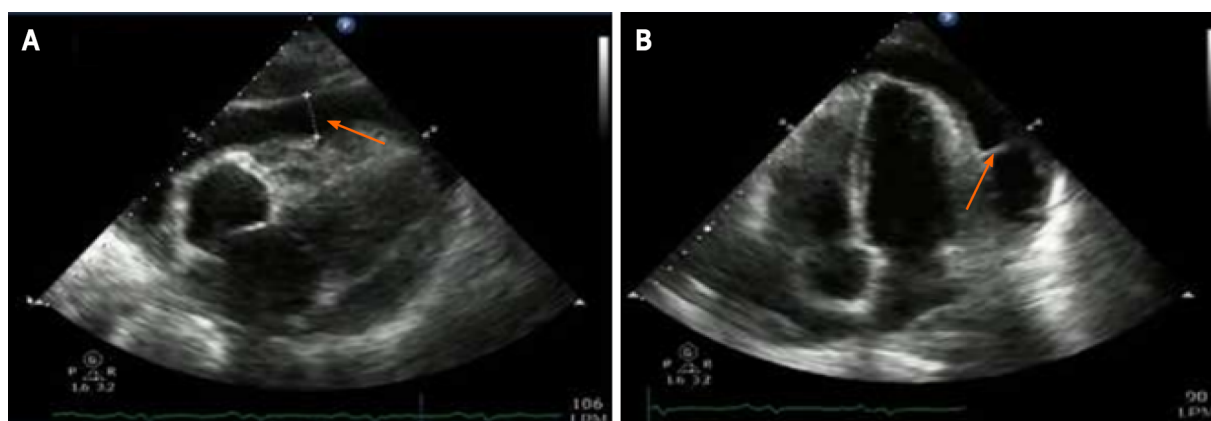


Figure 3 2D echocardiography. A: Echo-free space, or anechoic zone, between both layers of the pericardium of 27 mm (arrow) corresponding to pericardial effusion. The left ventricular ejection fraction was 60%, without segmental contractility disorders; B: Isoechoic image (arrow) at the level of the pericardial fluid that corresponds to a septum.

progressive increase in the extrapulmonary TB rate has been observed: 2.1 cases/100000 inhabitants in 1997; 3.7/100000 in 2006 and 4.4/100000 in 2018. Less than 1% of these cases correspond to TP, and generally, it occurs in patients coinfecting with HIV who constitute about 85% of cases[10].

TP usually develops insidiously and with nonspecific systemic symptoms such as fever, night sweats, fatigue and weight loss. Although chest pain, cough, and dyspnea are common, the severe acute-onset pericardial pain characteristic of idiopathic pericarditis is rare[10]. Large pericardial effusion should be suspected when micro voltage is observed on the electrocardiogram. This is seen in complexes < 5 mm in the limb leads and < 10 mm in the precordial leads[11]. Chest radiography generally shows a widening of the cardiac silhouette in more than 90% of cases, with a globular image described as "Bottle of water" configuration. Generally, these findings are observed in conjunction with active lung TB and pleural effusion in 30% and 60% of cases, respectively[12]. On the echocardiogram, TP usually comes accompanied by pericardial effusion with thickening of the visceral pericardium and it is possible to identify fibrin bands or fibrosis that heals the pericardium[13].

TP diagnosis is confirmed if one of the following criteria is present: Positive culture for the bacillus of Koch in pericardial fluid, positive direct examination for Koch bacillus, or value greater than 50 IU/L on the Adenosine deaminase (ADA) test[14]. Furthermore, the diagnosis can be confirmed if the pericardial biopsy shows the following findings: Positive culture for the Koch bacillus and granulomas with caseous necrosis, or presence of Langhans-type multinucleated giant cells, or presence of tubercle bacilli in the sample[15].

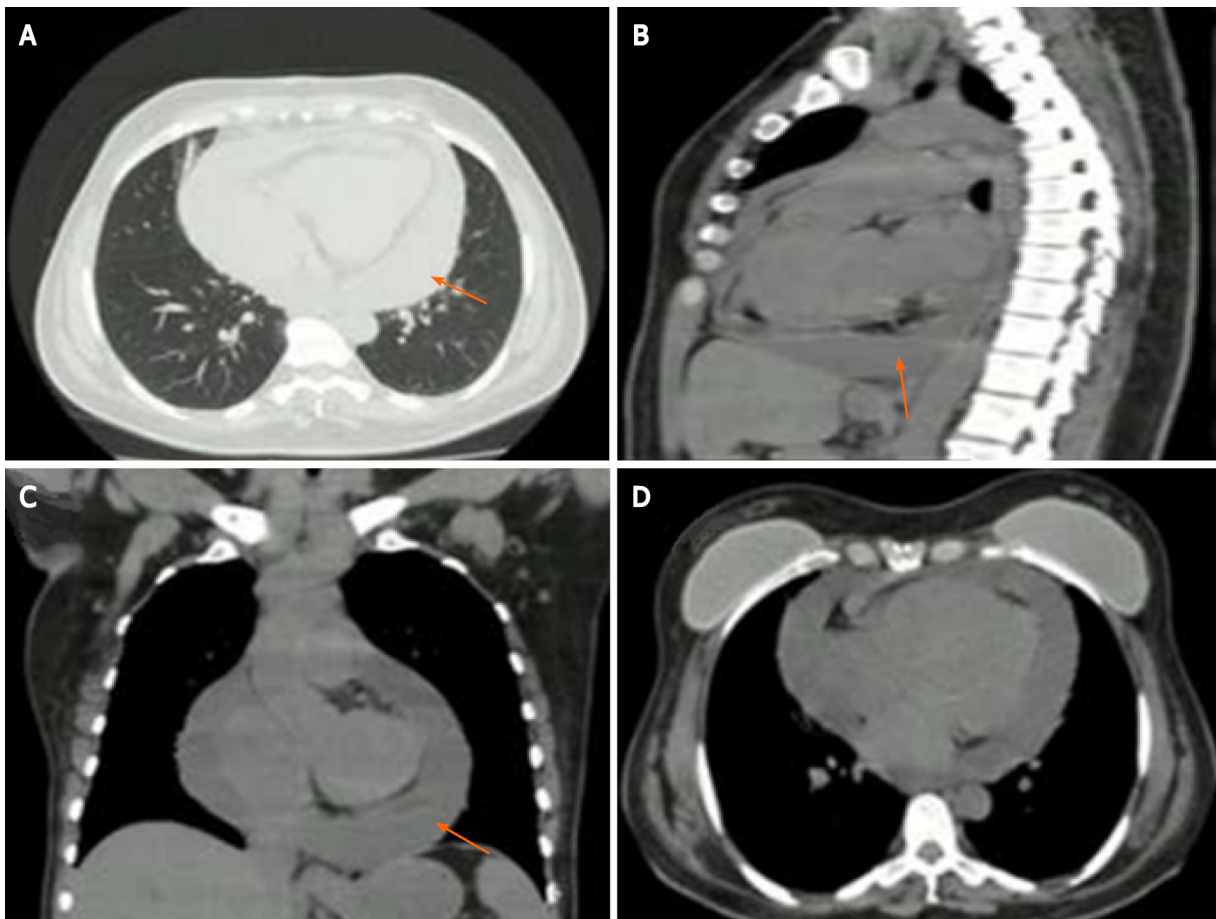


Figure 4 Chest computed tomography. A-C: Axial (A), sagittal (B), and coronal (C) computed tomography showing severe pericardial effusion thickness of up to 25 mm (arrows); D: No evidence of right ventricular free wall flattening. The breast implants had no signs of extracapsular rupture.

The diagnosis of TP remains difficult due to the absence of a simple, rapid and accessible diagnostic test despite its associated morbidity and mortality. A protein-rich lymphocytic exudate that is often grossly hemorrhagic is a typical finding in the pericardial fluid. However, the TP fluid is paucibacillary and the estimated diagnostic accuracy based on the smear is only 5% [16]. The sensitivity of pericardial fluid culture ranges from 53% to 75% [17]. However, results are obtained in an average of 3 wk. PCR test for *Mycobacterium tuberculosis* DNA or RNA in pericardial fluid is more accessible and faster, and it has a lower cost than pericardial tissue PCR, but it also has a lower sensitivity (15% *vs* 80% respectively), and can yield up to 20% false positives [18]. PCR has been very useful since it is capable of identifying different nucleic acid sequences in samples with low bacilli concentrations and in addition, it identifies resistance to rifampicin encoded in the *rpoB* gene, which can be useful in settings where there is a high prevalence of multidrug-resistant TB. Finally, in recent years, the performance of the immunoassay has been studied which quantifies the release of interferon gamma (IFN- γ) (QuantiFERON®, ELISpot) for the diagnosis of pulmonary TB, extrapulmonary TB and latent TB. The sensitivity of pericardial biopsy varies from 10% to 64% [19].

Pericardial ADA levels ≥ 35 U/L are diagnostic of TP with a sensitivity and specificity of 90% and 74%, respectively [20]. On the other hand, it has been shown that IFN- γ , which is produced by CD-4 + and CD-8 + T lymphocytes in the context of TP, could be a precise diagnostic biomarker [21].

Treatment of TP is based on the use of rifampicin, isoniazid, pyrazinamide, and ethambutol for 2 mo, followed by isoniazid and rifampicin (a total of 6 mo of treatment) [22]. The effectiveness of treatment with corticosteroids in TP remains controversial. Steroids have not yet been found to have overwhelming beneficial effects on reabsorption of pericardial effusion or in the progression to constrictive pericarditis [23].

CONCLUSION

TP occurs in 1%-2% of patients with pulmonary TB and carries a high mortality rate. The diagnosis of TP remains difficult due to the absence of a simple, rapid and accessible diagnostic test despite its associated morbidity and mortality. Treatment of TP consists of rifampicin, isoniazid, pyrazinamide,

and ethambutol for 2 mo, followed by isoniazid and rifampicin (total of 6 mo of therapy). Early diagnosis of this entity will allow physicians to initiate timely treatment, avoid complications and improve the patient's clinical outcome.

FOOTNOTES

Author contributions: Bustos MM participated in the conception of the work and review of the final version; Lucero OD contributed to the conception of the work and the preparation of the manuscript; Ariza Rodríguez DJ participated in the preparation of the manuscript and the bibliographic review; Perez JC participated in the design of the work and analysis; all authors have read and approved the final manuscript.

Informed consent statement: Written consent was provided by the patient.

Conflict-of-interest statement: The authors have no conflict of interest.

CARE Checklist (2016) statement: The authors have read the CARE Checklist (2016), and the manuscript was prepared and revised according to the CARE Checklist (2016).

Open-Access: This article is an open-access article that was selected by an in-house editor and fully peer-reviewed by external reviewers. It is distributed in accordance with the Creative Commons Attribution NonCommercial (CC BY-NC 4.0) license, which permits others to distribute, remix, adapt, build upon this work non-commercially, and license their derivative works on different terms, provided the original work is properly cited and the use is non-commercial. See: <http://creativecommons.org/licenses/by-nc/4.0/>

Country/Territory of origin: Colombia

ORCID number: Oscar David Lucero 0000-0002-4100-3529; Marlon Mauricio Bustos 0000-0002-1746-6398; Darwin Jhoan Ariza Rodríguez 0000-0003-2852-4669; Juan Camilo Perez 0000-0003-3332-248X.

S-Editor: Fan JR

L-Editor: Filipodia

P-Editor: Fan JR

REFERENCES

- 1 **World Health Organization.** Global tuberculosis report 2019. [cited 10 May 2021]. Available from: <https://www.aidshub.org/resource/global-tuberculosis-report-2019>
- 2 **Furin J,** Cox H, Pai M. Tuberculosis. *Lancet* 2019; **393**: 1642-1656 [PMID: 30904262 DOI: 10.1016/S0140-6736(19)30308-3]
- 3 **Natarajan A,** Beena PM, Devnikar AV, Mali S. A systemic review on tuberculosis. *Indian J Tuberc* 2020; **67**: 295-311 [PMID: 32825856 DOI: 10.1016/j.ijtb.2020.02.005]
- 4 **Isiguzo G,** Du Bruyn E, Howlett P, Ntsekhe M. Diagnosis and Management of Tuberculous Pericarditis: What Is New? *Curr Cardiol Rep* 2020; **22**: 2 [PMID: 31940097 DOI: 10.1007/s11886-020-1254-1]
- 5 **Munn-Mace G,** Parmar D. Treatment of tuberculosis in complex emergencies in developing countries: a scoping review. *Health Policy Plan* 2018; **33**: 247-257 [PMID: 29165621 DOI: 10.1093/heapol/czx157]
- 6 **Imazio M,** Gaita F, LeWinter M. Evaluation and Treatment of Pericarditis: A Systematic Review. *JAMA* 2015; **314**: 1498-1506 [PMID: 26461998 DOI: 10.1001/jama.2015.12763]
- 7 **López-López JP,** Posada-Martínez EL, Saldarriaga C, Wyss F, Ponte-Negretti CI, Alexander B, Miranda-Arboleda AF, Martínez-Sellés M, Baranchuk A; Neglected Tropical Diseases, Other Infectious Diseases Affecting the Heart (the NET-Heart Project). Tuberculosis and the Heart. *J Am Heart Assoc* 2021; **10**: e019435 [PMID: 33733808 DOI: 10.1161/JAHA.120.019435]
- 8 **Daniels B,** Kwan A, Pai M, Das J. Lessons on the quality of tuberculosis diagnosis from standardized patients in China, India, Kenya, and South Africa. *J Clin Tuberc Other Mycobact Dis* 2019; **16**: 100109 [PMID: 31720433 DOI: 10.1016/j.jctube.2019.100109]
- 9 **López MP.** Informe eventotuberculosis a periodo XI-2020. Bogotá: Instituto Nacional de Salud; 2020. [cited 10 May 2021]. Available from: https://www.ins.gov.co/buscaador-eventos/Lineamientos/PRO_Tuberculosis.pdf
- 10 **Amado SB,** Moreno S, Martínez S, Lasso JI, Lasserma AF. Tuberculosis extrapulmonar: un reto clínico vigente. *Univ Med* 2020; **61** [DOI: 10.11144/javeriana.umed61-4.reto]
- 11 **Jorquera-Román M,** Araya-Cancino J, Enríquez-Montenegro J, Obando-Valdés J, Reyes-Cornejo F, Gutiérrez OB, Monasterio-Angulo V, Jofre-Tobar N, Verdugo JB, Rojas FR. [Tuberculous pericarditis an infrequent extrapulmonary manifestation of TB]. *Rev Med Chil* 2021; **149**: 281-285 [PMID: 34479275 DOI: 10.4067/s0034-98872021000200281]
- 12 **Ren Y,** Qiu J, Li Z, Li C. P-wave terminal force in lead V1 is a predictive indicator for the diagnosis of tuberculous constrictive pericarditis. *Heart Lung* 2019; **48**: 155-158 [PMID: 30391075 DOI: 10.1016/j.hrtlng.2018.09.007]
- 13 **Howlett P,** Du Bruyn E, Morrison H, Godsent IC, Wilkinson KA, Ntsekhe M, Wilkinson RJ. The immunopathogenesis of tuberculous pericarditis. *Microbes Infect* 2020; **22**: 172-181 [PMID: 32092538 DOI: 10.1016/j.micinf.2020.02.001]

- 14 **Huang YS**, Zhang JX, Sun Y. Chronic massive pericardial effusion: a case report and literature review. *J Int Med Res* 2020; **48**: 300060520973091 [PMID: [33233991](#) DOI: [10.1177/0300060520973091](#)]
- 15 **Echeverri DI**, Matta L. Pericarditis tuberculosa. *Biomedica* 2014; **34** [DOI: [10.7705/biomedica.v34i4.2064](#)]
- 16 **Andrianto A**, Mertaniasih NM, Gandi P, Al-Farabi MJ, Azmi Y, Jonatan M, Silahooij SI. Diagnostic test accuracy of Xpert MTB/RIF for tuberculous pericarditis: a systematic review and meta-analysis. *F1000Res* 2020; **9**: 761 [PMID: [32802321](#) DOI: [10.12688/f1000research.22770.1](#)]
- 17 **GBD 2019 Tuberculosis Collaborators**. Global, regional, and national sex differences in the global burden of tuberculosis by HIV status, 1990-2019: results from the Global Burden of Disease Study 2019. *Lancet Infect Dis* 2021 [PMID: [34563275](#) DOI: [10.1016/S1473-3099\(21\)00449-7](#)]
- 18 **Naicker K**, Ntsekhe M. Tuberculous pericardial disease: a focused update on diagnosis, therapy and prevention of complications. *Cardiovasc Diagn Ther* 2020; **10**: 289-295 [PMID: [32420111](#) DOI: [10.21037/cdt.2019.09.20](#)]
- 19 **Kyriakakis CG**, Mayosi BM, de Vries E, Isaacs A, Doubell AF. An approach to the patient with suspected pericardial disease. *S Afr Med J* 2016; **106**: 151-155 [PMID: [27303770](#) DOI: [10.7196/samj.2016.v106i2.10328](#)]
- 20 **Hu X**, Xing B, Wang W, Yang P, Sun Y, Zheng X, Shang Y, Chen F, Liu N, Yang L, Zhao Y, Tan J, Zhang X, Wang Y, Zhang Z, Liu Y. Diagnostic values of Xpert MTB/RIF, T-SPOT.TB and adenosine deaminase for HIV-negative tuberculous pericarditis in a high burden setting: a prospective observational study. *Sci Rep* 2020; **10**: 16325 [PMID: [33004934](#) DOI: [10.1038/s41598-020-73220-y](#)]
- 21 **Lima NA**, Lino DODC, Coelho NM, Melgar T. Tuberculous constrictive pericarditis. *BMJ Case Rep* 2019; **12** [PMID: [31278202](#) DOI: [10.1136/bcr-2019-230420](#)]
- 22 **Uchi T**, Hakuno D, Fukae T, Takahashi M, Takiguchi S, Li HC, Nishizawa K, Nozaki H, Sueyoshi K. Armored Heart Because of Tuberculous Constrictive Pericarditis. *Circ Cardiovasc Imaging* 2019; **12**: e008726 [PMID: [30803258](#) DOI: [10.1161/CIRCIMAGING.118.008726](#)]
- 23 **Tzani A**, Doulamis IP, Tzoumas A, Avgerinos DV, Koudoumas D, Siasos G, Vavuranakis M, Klein A, Kampaktis PN. Meta-Analysis of Population Characteristics and Outcomes of Patients Undergoing Pericardiectomy for Constrictive Pericarditis. *Am J Cardiol* 2021; **146**: 120-127 [PMID: [33539860](#) DOI: [10.1016/j.amjcard.2021.01.033](#)]



Published by **Baishideng Publishing Group Inc**
7041 Koll Center Parkway, Suite 160, Pleasanton, CA 94566, USA

Telephone: +1-925-3991568

E-mail: bpgoffice@wjgnet.com

Help Desk: <https://www.f6publishing.com/helpdesk>

<https://www.wjgnet.com>

