

World Journal of *Clinical Cases*

World J Clin Cases 2021 December 26; 9(36): 11122-11508



Contents

Weekly Volume 9 Number 36 December 26, 2021

REVIEW

- 11122** Diet and microbiome in the beginning of the sequence of gut inflammation
Ceballos D, Hernández-Camba A, Ramos L

MINIREVIEWS

- 11148** Stem cell therapy: A promising treatment for COVID-19
Zheng ZX

ORIGINAL ARTICLE

Case Control Study

- 11156** Association between serum Sestrin2 level and diabetic peripheral neuropathy in type 2 diabetic patients
Mao EW, Cheng XB, Li WC, Kan CX, Huang N, Wang HS, Hou NN, Sun XD
- 11165** Plasma brain natriuretic peptide, platelet parameters, and cardiopulmonary function in chronic obstructive pulmonary disease
Guo HJ, Jiang F, Chen C, Shi JY, Zhao YW

Retrospective Cohort Study

- 11173** Analysis of the incidence and influencing factors of hyponatremia before ¹³¹I treatment of differentiated thyroid carcinoma
Cao JJ, Yun CH, Xiao J, Liu Y, Wei W, Zhang W

Retrospective Study

- 11183** Cognitive magnetic resonance imaging-ultrasound fusion transperineal targeted biopsy combined with randomized biopsy in detection of prostate cancer
Pang C, Wang M, Hou HM, Liu JY, Zhang ZP, Wang X, Zhang YQ, Li CM, Zhang W, Wang JY, Liu M
- 11193** Nomogram based on inflammation-related markers for predicting survival of patients undergoing hepatectomy for hepatocellular carcinoma
Pu T, Li ZH, Jiang D, Chen JM, Guo Q, Cai M, Chen ZX, Xie K, Zhao YJ, Liu FB
- 11208** Association of frailty with in-hospital outcomes in elderly patients with heart failure
Kang YP, Chen LY, Zhu JJ, Liu WX, Ma CS
- 11220** COVID-19 pandemic and exacerbation of ulcerative colitis
Suda T, Takahashi M, Katayama Y, Tamano M
- 11228** Surgical perspectives of symptomatic omphalomesenteric duct remnants: Differences between infancy and beyond
Kang A, Kim SH, Cho YH, Kim HY

- 11237** Clustering cases of *Chlamydia psittaci* pneumonia mimicking COVID-19 pneumonia

Zhao W, He L, Xie XZ, Liao X, Tong DJ, Wu SJ, Liu J

- 11248** Sodium nitroprusside injection immediately before balloon inflation during percutaneous coronary intervention

Yu Y, Yang BP

- 11255** Machine learning approach to predict acute kidney injury after liver surgery

Dong JF, Xue Q, Chen T, Zhao YY, Fu H, Guo WY, Ji JS

- 11265** Application effect for a care bundle in optimizing nursing of patients with severe craniocerebral injury

Gao Y, Liao LP, Chen P, Wang K, Huang C, Chen Y, Mou SY

Clinical Trials Study

- 11276** Influence of pontic design of anterior fixed dental prosthesis on speech: A clinical case study

Wan J, Cai H, Wang T, Chen JY

Observational Study

- 11285** Real-world data on the infliximab biosimilar CT-P13 (Remsima®) in inflammatory bowel disease

Huguet JM, Cortés X, Bosca-Watts MM, Aguas M, Maroto N, Martí L, Amorós C, Paredes JM

- 11300** Correlation of periodontal inflamed surface area with glycemic status in controlled and uncontrolled type 2 diabetes mellitus

Anil K, Vadakkekuttikal RJ, Radhakrishnan C, Parambath FC

- 11311** Audiological characteristics and exploratory treatment of a rare condition of acute-otitis-media-associated sudden sensorineural hearing loss

Cao X, Yi HJ

- 11320** Yield of testing for micronutrient deficiencies associated with pancreatic exocrine insufficiency in a clinical setting: An observational study

Jalal M, Campbell JA, Tesfaye S, Al-Mukhtar A, Hopper AD

Prospective Study

- 11330** Birthing ball on promoting cervical ripening and its influence on the labor process and the neonatal blood gas index

Shen HC, Wang H, Sun B, Jiang LZ, Meng Q

CASE REPORT

- 11338** Mucormycosis – resurgence of a deadly opportunist during COVID-19 pandemic: Four case reports

Upadhyay S, Bharara T, Khandait M, Chawdhry A, Sharma BB

- 11346** Ductal breast carcinoma metastasized to the rectum: A case report and review of the literature

Ban B, Zhang K, Li JN, Liu TJ, Shi J

- 11355** De Garengeot hernia with avascular necrosis of the appendix: A case report
Yao MQ, Yi BH, Yang Y, Weng XQ, Fan JX, Jiang YP
- 11362** Mature mediastinal bronchogenic cyst with left pericardial defect: A case report
Zhu X, Zhang L, Tang Z, Xing FB, Gao X, Chen WB
- 11369** Difficulties in diagnosing anorectal melanoma: A case report and review of the literature
Apostu RC, Stefanescu E, Scurtu RR, Kacso G, Drasovean R
- 11382** Solid pseudopapillary neoplasm of the pancreas in a young male with main pancreatic duct dilatation: A case report
Nakashima S, Sato Y, Imamura T, Hattori D, Tamura T, Koyama R, Sato J, Kobayashi Y, Hashimoto M
- 11392** Acute myocardial infarction in a young man with ankylosing spondylitis: A case report
Wan ZH, Wang J, Zhao Q
- 11400** Acute appendicitis complicated by mesenteric vein thrombosis: A case report
Yang F, Guo XC, Rao XL, Sun L, Xu L
- 11406** Inguinal endometriosis: Ten case reports and review of literature
Li SH, Sun HZ, Li WH, Wang SZ
- 11419** Dramatic response to immunotherapy in an epidermal growth factor receptor-mutant non-small cell lung cancer: A case report
Li D, Cheng C, Song WP, Ni PZ, Zhang WZ, Wu X
- 11425** Three-dimensional inlay-guided endodontics applied in variant root canals: A case report and review of literature
Yan YQ, Wang HL, Liu Y, Zheng TJ, Tang YP, Liu R
- 11437** Ectopic pregnancy implanted under the diaphragm: A rare case report
Wu QL, Wang XM, Tang D
- 11443** Ear ischemia induced by endovascular therapy for arteriovenous fistula of the sigmoid sinus: A case report
Li W, Zhang SS, Gao XR, Li YX, Ge HJ
- 11448** Giant schwannoma of thoracic vertebra: A case report
Zhou Y, Liu CZ, Zhang SY, Wang HY, Nath Varma S, Cao LQ, Hou TT, Li X, Yao BJ
- 11457** Severe digital ischemia coexists with thrombocytopenia in malignancy-associated antiphospholipid syndrome: A case report and review of literature
Chen JL, Yu X, Luo R, Liu M
- 11467** Rare spontaneous extensive annular intramural esophageal dissection with endoscopic treatment: A case report
Hu JW, Zhao Q, Hu CY, Wu J, Lv XY, Jin XH

- 11475** Mucinous cystic neoplasm of the liver: A case report
Yu TY, Zhang JS, Chen K, Yu AJ
- 11482** Retroperitoneal parasitic fetus: A case report
Xia B, Li DD, Wei HX, Zhang XX, Li RM, Chen J
- 11487** De novo mutation loci and clinical analysis in a child with sodium taurocholate cotransport polypeptide deficiency: A case report
Liu HY, Li M, Li Q
- 11495** Surgery for hepatocellular carcinoma with tumor thrombosis in inferior vena cava: A case report
Zhang ZY, Zhang EL, Zhang BX, Zhang W

LETTER TO THE EDITOR

- 11504** Advantages and issues of concern regarding approaches to peripheral nerve block for total hip arthroplasty
Crisci M, Cuomo A, Forte CA, Bimonte S, Esposito G, Tracey MC, Cascella M

ABOUT COVER

Editorial Board Member of *World Journal of Clinical Cases*, Moises Rodriguez-Gonzalez, MD, Adjunct Professor, Senior Researcher, Department of Pediatric Cardiology, Hospital Universitario Puerta del Mar, Cadiz 11009, Spain. doctormoisesrodriguez@gmail.com

AIMS AND SCOPE

The primary aim of *World Journal of Clinical Cases* (WJCC, *World J Clin Cases*) is to provide scholars and readers from various fields of clinical medicine with a platform to publish high-quality clinical research articles and communicate their research findings online.

WJCC mainly publishes articles reporting research results and findings obtained in the field of clinical medicine and covering a wide range of topics, including case control studies, retrospective cohort studies, retrospective studies, clinical trials studies, observational studies, prospective studies, randomized controlled trials, randomized clinical trials, systematic reviews, meta-analysis, and case reports.

INDEXING/ABSTRACTING

The WJCC is now indexed in Science Citation Index Expanded (also known as SciSearch®), Journal Citation Reports/Science Edition, Scopus, PubMed, and PubMed Central. The 2021 Edition of Journal Citation Reports® cites the 2020 impact factor (IF) for WJCC as 1.337; IF without journal self cites: 1.301; 5-year IF: 1.742; Journal Citation Indicator: 0.33; Ranking: 119 among 169 journals in medicine, general and internal; and Quartile category: Q3. The WJCC's CiteScore for 2020 is 0.8 and Scopus CiteScore rank 2020: General Medicine is 493/793.

RESPONSIBLE EDITORS FOR THIS ISSUE

Production Editor: Ji-Hong Lin; Production Department Director: Xu Guo; Editorial Office Director: Jin-Lei Wang.

NAME OF JOURNAL

World Journal of Clinical Cases

ISSN

ISSN 2307-8960 (online)

LAUNCH DATE

April 16, 2013

FREQUENCY

Weekly

EDITORS-IN-CHIEF

Bao-Gan Peng, Jerzy Tadeusz Chudek

EDITORIAL BOARD MEMBERS

<https://www.wjnet.com/2307-8960/editorialboard.htm>

PUBLICATION DATE

December 26, 2021

COPYRIGHT

© 2022 Baishideng Publishing Group Inc

INSTRUCTIONS TO AUTHORS

<https://www.wjnet.com/bpg/gerinfo/204>

GUIDELINES FOR ETHICS DOCUMENTS

<https://www.wjnet.com/bpg/GerInfo/287>

GUIDELINES FOR NON-NATIVE SPEAKERS OF ENGLISH

<https://www.wjnet.com/bpg/gerinfo/240>

PUBLICATION ETHICS

<https://www.wjnet.com/bpg/GerInfo/288>

PUBLICATION MISCONDUCT

<https://www.wjnet.com/bpg/gerinfo/208>

ARTICLE PROCESSING CHARGE

<https://www.wjnet.com/bpg/gerinfo/242>

STEPS FOR SUBMITTING MANUSCRIPTS

<https://www.wjnet.com/bpg/GerInfo/239>

ONLINE SUBMISSION

<https://www.f6publishing.com>

Observational Study

Audiological characteristics and exploratory treatment of a rare condition of acute-otitis-media-associated sudden sensorineural hearing loss

Xin Cao, Hai-Jin Yi

ORCID number: Xin Cao 0000-0001-8244-3697; Hai-Jin Yi 0000-0003-4661-7607.

Author contributions: Yi HJ designed and coordinated the study, interpreted the data; Cao X performed the experiments, acquired and analyzed data; all authors wrote the manuscript and approved the final version of the article.

Institutional review board

statement: This study was approved by the Human Research Ethics Committee of Beijing Tsinghua Changgung Hospital, No. 21192-6-01.

Informed consent statement:

Informed consent was obtained from all the subjects.

Conflict-of-interest statement: All authors have nothing to disclose.

Data sharing statement: No additional data are available.

STROBE statement: The authors have read the STROBE Statement – checklist of items, and the manuscript was prepared and revised according to the STROBE Statement – checklist of items.

Xin Cao, Hai-Jin Yi, Department of Otolaryngology, Head and Neck Surgery, Beijing Tsinghua Changgung Hospital, School of Clinical Medicine, Tsinghua University, Beijing 102218, China

Corresponding author: Hai-Jin Yi, MD, Chief Physician, Full Professor, Department of Otolaryngology, Head and Neck Surgery, Beijing Tsinghua Changgung Hospital, School of Clinical Medicine, Tsinghua University, No. 168 Litang Road, Changping District, Beijing 102218, China. caoxin19860201@163.com

Abstract

BACKGROUND

Acute otitis media (AOM) is a common disease that is more prevalent in children. Most studies concerning AOM-associated sudden sensorineural hearing loss are case reports and retrospective in nature, hence the etiology of AOM-associated sudden hearing loss has not been fully established.

AIM

To analyze audiological characteristics of AOM-associated sudden hearing loss and evaluate efficacy of combined tympanostomy tube placement (TTP) and intratympanic methylprednisolone.

METHODS

Eight adult patients who were diagnosed with AOM-associated sudden hearing loss and ineffectively treated by conventional medical therapy were enrolled in this study. Basic data were collected, and pure tone audiometry was performed to assess the audiological characteristics. Combination therapy with TTP and intratympanic methylprednisolone injection was given to the patients.

RESULTS

Mixed or sensorineural hearing loss was observed at high frequencies (2–4 kHz). All the cases in this study were cured after TTP and intratympanic methylprednisolone. After treatment, the average hearing threshold at affected frequencies was significantly lower than those in the pretreatment group ($P < 0.05$) and was similar to that in the healthy ears ($P > 0.05$).

CONCLUSION

AOM rarely induces sudden sensorineural hearing loss. Combination therapy

Country/Territory of origin: China**Specialty type:**

Otorhinolaryngology

Provenance and peer review:

Unsolicited article; Externally peer reviewed.

Peer-review model: Single blind**Peer-review report's scientific quality classification**

Grade A (Excellent): 0

Grade B (Very good): 0

Grade C (Good): C, C

Grade D (Fair): 0

Grade E (Poor): 0

Open-Access: This article is an open-access article that was selected by an in-house editor and fully peer-reviewed by external reviewers. It is distributed in accordance with the Creative Commons Attribution NonCommercial (CC BY-NC 4.0) license, which permits others to distribute, remix, adapt, build upon this work non-commercially, and license their derivative works on different terms, provided the original work is properly cited and the use is non-commercial. See: <http://creativecommons.org/licenses/by-nc/4.0/>

Received: June 28, 2021**Peer-review started:** June 28, 2021**First decision:** July 26, 2021**Revised:** July 27, 2021**Accepted:** November 5, 2021**Article in press:** November 5, 2021**Published online:** December 26, 2021**P-Reviewer:** Byeon H**S-Editor:** Wu YXJ**L-Editor:** Kerr C**P-Editor:** Wu YXJ

with TTP and intratympanic methylprednisolone injection may be effective after failure of conventional medical treatment.

Key Words: Acute otitis media; Sudden hearing loss; Hearing loss; Tympanostomy tube placement; Intratympanic methylprednisolone injection

©The Author(s) 2021. Published by Baishideng Publishing Group Inc. All rights reserved.

Core Tip: Acute otitis media (AOM)-associated sudden sensorineural hearing loss is a rare otological condition and the mechanism and treatment methods have not been defined. This study described the audiological features of the patients with AOM-associated sudden hearing loss and evaluated the clinical efficacy of tympanostomy tube placement and intratympanic methylprednisolone injection after failure of conventional medical therapy.

Citation: Cao X, Yi HJ. Audiological characteristics and exploratory treatment of a rare condition of acute-otitis-media-associated sudden sensorineural hearing loss. *World J Clin Cases* 2021; 9(36): 11311-11319

URL: <https://www.wjgnet.com/2307-8960/full/v9/i36/11311.htm>

DOI: <https://dx.doi.org/10.12998/wjcc.v9.i36.11311>

INTRODUCTION

Acute otitis media (AOM) is a common disease that is more prevalent in children, affecting > 80% of children before the age of 3 years[1]. Globally, there are > 709 million new cases reported every year[2,3]. AOM is mainly caused by acute viral infection of the upper respiratory tract, which alters eustachian tube function and exposes the middle ear to bacterial infiltration[4]. There may be a conductive hearing loss if the patient also has tympanic effusion, and the degree of hearing loss can vary from negligible to 60 dB[5-8]. In the clinic, antibiotics and early myringotomy are the only two treatment options currently available for AOM patients[9]. Sudden sensorineural hearing loss is a frightening symptom that affects about 5-27 per 100000 people annually, with around 66000 new cases per year in the United States[10]. Most of these cases received corticosteroids as initial therapy[11]. Furthermore, intratympanic steroid administration is suggested as salvage therapy when initial therapy fails[11,12]. However, AOM-associated sudden sensorineural hearing loss is a rare otological condition and the mechanism and treatment methods have not been defined.

Most studies concerning AOM-associated sudden sensorineural hearing loss are case reports and retrospective in nature[12-14], hence, the etiology of AOM-associated sudden hearing loss has not been fully established. One of the hypotheses is that effusion in the middle ear causes vibration limitation and hypoxia of two windows, which leads to bone conduction hearing loss[15]. Another hypothesis for the sudden deafness is that the toxins released by infection enter the inner ear through the round window membrane (RWM)[16]. Since absorbing the effusion in the middle ear does not completely restore sensorineural hearing loss, the latter hypothesis currently seems more acceptable. Even though AOM-associated sudden hearing loss is a rare otological disorder, if not treated on time, it might cause permanent hearing loss. Therefore, it is important that the disorder is diagnosed early and treated immediately. This study described the audiological features of patients with AOM-associated sudden hearing loss and evaluated the clinical efficacy of tympanostomy tube placement (TTP) and intratympanic methylprednisolone injection after failure of conventional medical therapy.

MATERIALS AND METHODS

Subjects

Patients with AOM-associated sudden hearing loss who visited the Department of Otolaryngology of Beijing Tsinghua Changgung Hospital between October 1, 2018 and June 1, 2020 were enrolled for this retrospective study. Written consent was signed by all the subjects, and this study was approved by the Human Research Ethics Committee of Beijing Tsinghua Changgung Hospital.

The patients were chosen based on following criteria: (1) Age 18–70 years; (2) AOM was diagnosed based on clinical symptoms, pneumatic otoscopy, pure-tone audiometry (PTA) and tympanometry; (3) Sudden hearing loss was diagnosed according to the Guidelines for Diagnosis and Management of Sudden Hearing Loss (2015), if PTA showed a decrease in hearing threshold ≥ 20 dB, for at least two consecutive frequencies from 0.25 to 4 kHz[17]; and (4) Conventional medical therapy was ineffective.

Exclusion criteria were as follows: (1) Current administration of oral or topical antibiotics for the affected ear; (2) Steroid treatment within 10 d before enrollment; (3) Previous perforation in the affected ear; (4) Allergic to cefuroxime axetil, cefdinir or moxifloxacin; and (5) Grommet (ventilation tube) in the affected ear.

Intervention

All patients underwent myringotomy under local anesthesia, a ventilation tube was placed, and intratympanic injection of methylprednisolone (approximate 0.4 mL, 40 mg/mL) was given once every 3–4 d. The surgical procedures were performed by an experienced physician. The injection was given at most four times and PTA was performed 2 d after the last treatment or when hearing improvement was reported by the subjects.

Audiometric evaluation

Pure-tone test: It was conducted by using audiometry (TDH-39P Telephonics headset; Clinical Audiometer AC40, Interacoustics Company, Assens, Denmark, and the B-71 bone vibrator) in a sound-insulated cabin. The frequency-specific threshold was determined as the lowest sound intensity that the patient could hear at the specific frequency. The air conduction thresholds at 0.25, 0.5, 1, 2 and 4 kHz were determined.

Measurement of bone conduction thresholds: A B-71 bone vibrator was placed on the mastoid protrusion of the temporal bone of the subjects. The BC threshold values were determined at 0.25, 0.5, 1, 2 and 4 kHz.

Air-bone gap: The air-bone gap (ABG) was calculated as the difference between the pure-tone bone conduction and air conduction thresholds.

Average hearing at affected frequencies: When the bone conduction threshold was ≥ 20 dB over two or more consecutive frequencies, these frequencies were determined as affected frequencies. An average hearing at the affected frequencies was determined as the average hearing threshold at the corresponding frequencies.

Evaluation of efficacy

An improvement of ≥ 15 dB of the average hearing threshold at the affected frequencies after treatment was identified as effective, whereas an improvement of < 15 dB was identified as ineffective. A cure was defined as restoring the average hearing threshold at the affected frequencies to the normal hearing levels or the contralateral hearing levels after treatment.

Statistical analysis

The data were evaluated by using SPSS version 26.0 (Chicago, IL, United States). The data were expressed as mean \pm SD. The changes in the hearing threshold values before and after treatment were analyzed by nonparametric test, and the difference was considered statistically significant if P was < 0.05 .

RESULTS

Demographics

Eight patients who met the inclusion criteria were included in the study (Table 1), with an average age of 51.1 ± 13.60 years. All of them were affected in one ear with different degrees of bone conduction hearing loss.

Audiological characteristics pretreatment

The bone conduction and air conduction threshold values of the affected ears and healthy ears at different frequencies are listed in Table 2. Table 2 shows that the hearing threshold values of the affected ears were significantly higher than those of the contralateral healthy ears over 0.5, 1, 2 and 4 kHz for bone conduction ($P < 0.05$) and at all frequencies for air conduction. The audiogram data clearly showed that conductive hearing loss was observed at low frequencies, and mixed or sensorineural hearing loss was seen at high frequencies (Figure 1). Bone conduction hearing was impaired at 2 kHz in all patients, *i.e.*, an incidence rate of 100%. The average hearing threshold of the affected frequencies was 37.19 ± 9.49 dB.

The frequency ranges of 0.25–1 kHz and 2–4 kHz were defined as low and high frequencies, respectively. The bone conduction threshold values at low frequencies were close to normal, and hearing loss was observed at high frequencies, with significant difference ($P < 0.05$) (Table 3). The average ABG was greater in the low frequency group, but the difference between the two groups was not statistically significant (Table 3).

Audiological characteristics and efficacy after treatment

The average interval from disease onset to the start of treatment was 8.63 ± 10.60 d (range, 3–30 d). All eight patients received TTP and intratympanic methylprednisolone injection (the average number of injections was 2), and were cured after treatment. The average hearing threshold value at the affected frequencies post-treatment was significantly lower than the pre-treatment value ($P < 0.05$), whereas it was not significantly different from that of the healthy ears ($P > 0.05$) (Table 4). The audiological changes observed after the treatment were shown in a post-treatment audiogram (Figure 2). The average ABG was significantly improved ($P < 0.05$) (Table 5). These results indicated that the combination of TTP and intratympanic methylprednisolone injection was a good salvage treatment regimen for patients suffering from AOM associated sudden hearing loss after failure of the conventional treatment.

DISCUSSION

The pathogenesis of sensorineural hearing loss in patients with AOM has been investigated, and the leading proposed theory is that an inflammation induces increased permeability of RWM, which allows the entry of endotoxins and ionic disequilibrium in the cochlea[17]. The bacterial (*e.g.*, *Streptococcus pneumoniae*) byproducts and inflammatory mediators associated with AOM have been proven to enhance the permeability of RWM and cause subsequent cochlear damage[16,18,19]. It was found that the resulting hearing loss predominantly affected the hearing threshold values at high frequencies, which supports the above-mentioned theory[20]. In this study, it was found that the audiological characteristics of the patients with AOM-associated sudden hearing loss were as follows: ABG at low frequencies and bone conduction hearing loss at high frequencies. These results were in accordance with a previous case report, in which a female patient who was diagnosed with AOM-associated bilateral sudden hearing loss presented with higher hearing threshold values for both bone and air conduction at 2 and 4 kHz frequencies[13]. Despite the similar results reported in several studies, the pathological explanation for the elevation in hearing thresholds at high frequencies following AOM with effusion has not been fully elucidated. It is noteworthy that the prognosis of low frequency hearing loss was demonstrated to be better than that of high frequency. Patients with low frequency hearing loss showed a significantly higher recovery rate (74.1%, 40/54) than those with high frequency hearing loss (45.6%, 26/57) ($P < 0.001$)[21]. High-frequency hearing loss has also been associated with various symptoms such as deterioration in music perception[22]. In addition, a longitudinal cohort study showed that patients who had chronic suppurative otitis media and hearing loss after recurrent AOM are more likely to suffer from dizziness in adulthood[23], indicating that AOM-associated high frequency

Table 1 Demographics of the enrolled patients ($n = 8$, mean \pm SD)

Case No.	Side of the affected ear		Gender		Age (yr)	Hearing loss		Tinnitus				Curve type		
	Left	Right	Male	Female		Yes	No	No	Light	Middle	Severe	A	B	C
1	√			√	37	√		√						√
2		√		√	38	√		√				√		
3	√		√		47	√		√						√
4	√			√	63	√		√						√
5	√			√	59	√		√						√
6		√	√		67	√				√				√
7	√			√	34	√				√				√
8	√			√	64	√		√						√
Total	6	2	2	6	51.1 ± 13.60	8	0	6	0	2	0	1	7	0

Table 2 Comparison of bone conduction and air conduction thresholds between the affected and contralateral healthy ears (dB HL, mean \pm SD)

Group	No.	0.25 kHz, BC	0.5 kHz, BC	1 kHz, BC	2 kHz, BC	4 kHz, BC
Affected ears	8	9.38 \pm 5.60	17.50 \pm 9.63	18.75 \pm 9.16	33.12 \pm 12.51	39.38 \pm 17.41
Healthy ears	8	8.13 \pm 5.30	13.13 \pm 5.30	11.25 \pm 6.40	17.50 \pm 8.86	22.50 \pm 11.34
Z		-0.220	-1.282	-1.973	-2.570	-2.161
P		0.826	0.200	0.048	0.010	0.031
Group	No.	0.25 kHz, AC	0.5 kHz, AC	1 kHz, AC	2 kHz, AC	4 kHz, AC
Affected ears	8	28.13 \pm 11.63	31.88 \pm 15.34	38.75 \pm 18.27	38.75 \pm 16.42	56.25 \pm 22.16
Healthy ears	8	8.13 \pm 5.30	13.13 \pm 5.30	11.25 \pm 6.40	17.50 \pm 8.86	22.50 \pm 11.34
Z		-2.965	-2.971	-3.242	-2.797	-2.905
P value		0.003	0.003	0.001	0.005	0.004

AC: Air conduction; BC: Bone conduction.

Table 3 Comparison of average bone conduction thresholds and air-bone gap at low and high frequency

Group	0.25-1 kHz	2-4 kHz	Z	P value
Average BC threshold	15.25 \pm 6.52	36.25 \pm 6.52	-2.897	0.004
Air-bone gap	16.25 \pm 11.64	11.56 \pm 6.80	-0.527	0.598

BC: Bone conduction.

hearing loss in childhood may influence the hearing and quality of life in the long term. Therefore, high-frequency audiometry should be considered for AOM patients to detect early changes in the auditory thresholds, and early intervention should be planned when plausible. To the best of our knowledge, this study is the largest case study that has investigated the audiological characteristics of patients with AOM-associated sudden deafness.

Currently, the front-line treatment choices for AOM, according to the guidelines and clinicians, are antibiotics and myringotomy, alone or in combination with ventilation tube placement. Song *et al*[9] suggested that early myringotomy (with or without placing ventilation tubes) and antibiotics significantly improved clinical outcomes of eight patients with AOM. As for the sudden sensorineural hearing loss, it was recommended by the American Academy of Otolaryngology guidelines that systemic

Table 4 Comparison of the average hearing threshold at affected frequencies pre- and post-treatment with healthy ears

Group	Mean hearing threshold at affected frequencies (dB HL)	Z	P value
Pre-treatment	37.19 ± 9.49	-2.804	0.005
Healthy ears	19.69 ± 7.95		
Post-treatment	21.66 ± 9.14	-0.370	0.712

Table 5 Comparison of the pre-treatment air-bone gap with post-treatment values

Group	Air-bone gap (dB HL)	Z	P value
Pre-treatment	14.38 ± 9.40	-3.165	0.002
Post-treatment	3.25 ± 2.71		

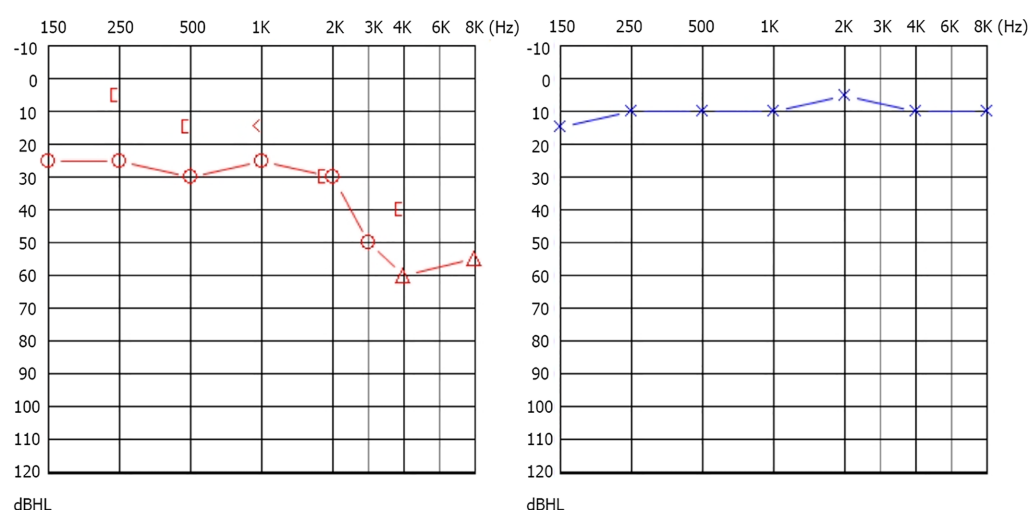


Figure 1 Audiogram. Audiogram pretreatment: conductive hearing loss was observed at low frequencies of 0.25–1 kHz, and sensorineural hearing loss was seen at high frequencies of 2–4 kHz; the hearing threshold of the left ear was normal. [: Bone conduction of right ear with sheltering; < : Bone conduction of left ear; O : Air conduction of right ear; Δ : Air conduction of right ear with sheltering; × : Air conduction of left ear; blue markers = left ear; red markers = right ear.

corticosteroids and/or hyperbaric oxygen therapy should be adopted as soon as the diagnosis was made, if needed an intratympanic steroid injection was recommended as a possible salvage therapy[11].

However, there is no standard treatment modality for patients with AOM-associated sudden deafness due to limited evidence and rarity of the disease. In the current study, antibiotics and intravenous methylprednisolone were administered in all eight patients; however, the treatment was ineffective. A combination treatment of TTP and intratympanic methylprednisolone injection was applied as a salvage and exploratory therapy. All the patients in this study showed improvement in BC threshold values at the affected frequencies and showed improvement in ABG. The results were in accordance with a previous study. Seven patients with sensorineural hearing loss associated with AOM were offered intratympanic steroids after oral antibiotics and oral prednisolone failed to improve hearing. Hearing improvement was achieved in 57% of patients (4/7) after intratympanic injections of methylprednisolone. A possible reason is that intratympanic methylprednisolone injection can provide a concentrated local steroid effect in nonresponders to antibiotics. The results clearly indicated that the combination therapy of TTP and intratympanic glucocorticoid injection was a good choice for treating patients with AOM-associated sudden deafness after failure of conventional medical treatment.

However, further well-designed studies are needed to verify the findings of the current study as there were some limitations to this study. Firstly, AOM-associated sudden hearing loss is a rare disease in adults, thus, the sample size of this study was too small. Secondly, a control group in which no further treatment was provided after failure of the first treatment was not accommodated in this study. Hence in the future,

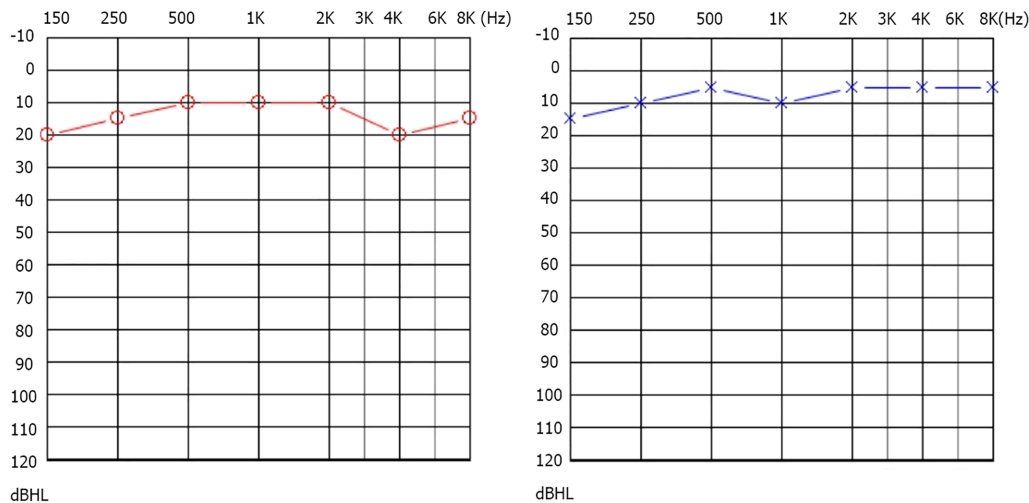


Figure 2 Audiogram. Audiogram after treatment: Conductive hearing loss at low frequencies of the same patient disappeared and sensorineural hearing loss observed at high frequencies of 2–4kHz was restored to the hearing level of the healthy ear; the hearing threshold of the left ear was normal. O: Air conduction of right ear = bone conduction of right ear; x: Air conduction of left ear = bone conduction of left ear; blue markers = left ear; red markers = right ear.

well-designed studies with a larger sample size are required to further corroborate findings of this study.

CONCLUSION

In summary, the current case study indicated that AOM may rarely induce sudden sensorineural hearing loss, and high frequencies (2–4 kHz) are often involved. Combination therapy with TTP and intratympanic methylprednisolone injection may be a good salvage treatment modality for patients with AOM-associated sudden hearing loss after failure of conventional treatment.

ARTICLE HIGHLIGHTS

Research background

Acute otitis media (AOM) is a common disease in children, affecting > 80% of children before the age of 3 years. AOM-associated sudden sensorineural hearing loss is a rare otological disorder, and the mechanism and treatment methods remain to be investigated.

Research motivation

If AOM-associated sudden hearing loss is not treated on time, it might cause permanent hearing loss. Therefore, early diagnosis and treatment of AOM-associated sudden hearing loss are important.

Research objectives

This study aimed to describe the audiological features of the patients with AOM-associated sudden hearing loss and evaluate the clinical efficacy of tympanostomy tube placement (TTP) and intratympanic methylprednisolone injection after failure of conventional medical therapy.

Research methods

Patients with AOM-associated sudden hearing loss who visited the Department of Otolaryngology of Beijing Tsinghua Changgung Hospital between October 1, 2018 and June 1, 2020 and were ineffectively treated by conventional medical therapy were enrolled in this study. Basic data were collected, and pure-tone audiometry was performed to assess the audiological characteristics. Combination therapy with TTP and intratympanic methylprednisolone injection was given to the patients.

Research results

Mixed or sensorineural hearing loss was observed at high frequencies (2–4 kHz). All the patients in this study were cured after TTP and intratympanic methylprednisolone. After treatment, the average hearing threshold at affected frequencies was significantly lower than those in the pretreatment group and was similar to those in the healthy ears.

Research conclusions

Our study indicated that AOM may rarely induce sudden sensorineural hearing loss, and high frequencies (2–4 kHz) are often involved. Combination therapy with TTP and intratympanic methylprednisolone injection may be a good salvage treatment modality for patients with AOM-associated sudden hearing loss after failure of conventional treatment.

Research perspectives

Our study may bring more chances for recovery of patients with AOM-associated sudden hearing loss after failure of conventional treatment. However, our findings remain to be verified by well-designed studies with a large sample size.

REFERENCES

- 1 **Leung AKC**, Wong AHC. Acute Otitis Media in Children. *Recent Pat Inflamm Allergy Drug Discov* 2017; **11**: 32-40 [PMID: 28707578 DOI: 10.2174/1874609810666170712145332]
- 2 **Cartel JL**, Sechan Y, Boutin JP, Celerier P, Plichart R, Roux JF. Ivermectin for treatment of bancroftian filariasis in French Polynesia: efficacy in man, effect on transmission by vector *Aedes polynesiensis*. *Trop Med Parasitol* 1990; **41**: 241-244 [PMID: 2255839 DOI: 10.1371/journal.pone.0036226]
- 3 **Vergison A**, Dagan R, Arguedas A, Bonhoeffer J, Cohen R, Dhooze I, Hoberman A, Liese J, Marchisio P, Palmu AA, Ray GT, Sanders EA, Simões EA, Uhari M, van Eldere J, Pelton SI. Otitis media and its consequences: beyond the earache. *Lancet Infect Dis* 2010; **10**: 195-203 [PMID: 20185098 DOI: 10.1016/S1473-3099(10)70012-8]
- 4 **Marom T**, Nokso-Koivisto J, Chonmaitree T. Viral-bacterial interactions in acute otitis media. *Curr Allergy Asthma Rep* 2012; **12**: 551-558 [PMID: 22968233 DOI: 10.1007/s11882-012-0303-2]
- 5 **Pagrani M**, Srivastava A, Mohan C. Adult onset acute otitis media - a preliminary report. *J Evolutive Med Dental Sciences-Jemds* 2014; **3**: 5094-5099 [DOI: 10.14260/jemds/2014/2559]
- 6 **Park JH**, Park SJ, Kim YH, Park MH. Sensorineural hearing loss: a complication of acute otitis media in adults. *Eur Arch Otorhinolaryngol* 2014; **271**: 1879-1884 [PMID: 23990061 DOI: 10.1007/s00405-013-2675-x]
- 7 **Kasemodel ALP**, Costa LEM, Monsanto RDC, Tomaz A, Penido NO. Sensorineural hearing loss in the acute phase of a single episode of acute otitis media. *Braz J Otorhinolaryngol* 2020; **86**: 767-773 [PMID: 31324458 DOI: 10.1016/j.bjorl.2019.06.001]
- 8 **Margolis RH**, Hunter LL. Audiologic evaluation of the otitis media patient. *Otolaryngol Clin North Am* 1991; **24**: 877-899 [PMID: 1870880]
- 9 **Song JE**, Sapthavee A, Cager GR, Saadia-Redleaf MI. Pseudo-sudden deafness. *Ann Otol Rhinol Laryngol* 2012; **121**: 96-99 [PMID: 22397217 DOI: 10.1177/000348941212100204]
- 10 **Chandrasekhar SS**, Tsai Do BS, Schwartz SR, Bontempo LJ, Faucett EA, Finestone SA, Hollingsworth DB, Kelley DM, Kmucha ST, Moonis G, Poling GL, Roberts JK, Stachler RJ, Zeitler DM, Corrigan MD, Nnacheta LC, Satterfield L. Clinical Practice Guideline: Sudden Hearing Loss (Update). *Otolaryngol Head Neck Surg* 2019; **161**: S1-S45 [PMID: 31369359 DOI: 10.1177/0194599819859885]
- 11 **Stachler RJ**, Chandrasekhar SS, Archer SM, Rosenfeld RM, Schwartz SR, Barrs DM, Brown SR, Fife TD, Ford P, Ganiats TG, Hollingsworth DB, Lewandowski CA, Montano JJ, Saunders JE, Tucci DL, Valente M, Warren BE, Yaremchuk KL, Robertson PJ; American Academy of Otolaryngology-Head and Neck Surgery. Clinical practice guideline: sudden hearing loss. *Otolaryngol Head Neck Surg* 2012; **146**: S1-S35 [PMID: 22383545 DOI: 10.1177/0194599812436449]
- 12 **Heywood RL**, Ifeacho SN, Narula AA. Effect of intratympanic steroid administration on sensorineural hearing loss associated with acute otitis media. *J Laryngol Otol* 2016; **130**: 532-535 [PMID: 27087111 DOI: 10.1017/S0022215116001110]
- 13 **Smith A**, Gutteridge I, Elliott D, Cronin M. Acute otitis media associated bilateral sudden hearing loss: case report and literature review. *J Laryngol Otol* 2017; **131**: S57-S61 [PMID: 28412992 DOI: 10.1017/S0022215117000779]
- 14 **Stenner M**, Jecker P, Gouveris H, Mann W. [Treatment of sensorineural hearing loss in acute viral otitis media with intratympanic dexamethasone and hyaluronic acid in comparison with intravenous therapy]. *Laryngorhinootologie* 2006; **85**: 32-37 [PMID: 16444653 DOI: 10.1055/s-2005-870274]
- 15 **Bhutta MF**, Lambie J, Hobson L, Williams D, Tyrer HE, Nicholson G, Brown SDM, Brown H, Piccinelli C, Devailly G, Ramsden J, Cheeseman MT. Transcript Analysis Reveals a Hypoxic

- Inflammatory Environment in Human Chronic Otitis Media With Effusion. *Front Genet* 2019; **10**: 1327 [PMID: 32153623 DOI: 10.3389/fgene.2019.01327]
- 16 **Schachern P**, Tsuprun V, Cureoglu S, Ferrieri P, Briles D, Paparella M, Juhn S. The round window membrane in otitis media: effect of pneumococcal proteins. *Arch Otolaryngol Head Neck Surg* 2008; **134**: 658-662 [PMID: 18559736 DOI: 10.1001/archotol.134.6.658]
 - 17 Editorial Board of Chinese Journal of Otorhinolaryngology Head and Neck Surgery; Society of Otorhinolaryngology Head and Neck Surgery CMA. [Guideline of diagnosis and treatment of sudden deafness (2015)]. *Zhonghua ErBiYanHouTouJing WaiKe ZaZhi* 2015; **50**: 443-447
 - 18 **Juhn SK**, Jung MK, Hoffman MD, Drew BR, Preciado DA, Sausen NJ, Jung TT, Kim BH, Park SY, Lin J, Ondrey FG, Mains DR, Huang T. The role of inflammatory mediators in the pathogenesis of otitis media and sequelae. *Clin Exp Otorhinolaryngol* 2008; **1**: 117-138 [PMID: 19434244 DOI: 10.3342/ceo.2008.1.3.117]
 - 19 **Joglekar S**, Morita N, Cureoglu S, Schachern PA, Deroee AF, Tsuprun V, Paparella MM, Juhn SK. Cochlear pathology in human temporal bones with otitis media. *Acta Otolaryngol* 2010; **130**: 472-476 [PMID: 19895333 DOI: 10.3109/00016480903311252]
 - 20 **Cordeiro FP**, da Costa Monsanto R, Kasemodel ALP, de Almeida Gondra L, de Oliveira Penido N. Extended high-frequency hearing loss following the first episode of otitis media. *Laryngoscope* 2018; **128**: 2879-2884 [PMID: 30194735 DOI: 10.1002/lary.27309]
 - 21 **Choo OS**, Yang SM, Park HY, Lee JB, Jang JH, Choi SJ, Choung YH. Differences in clinical characteristics and prognosis of sudden low- and high-frequency hearing loss. *Laryngoscope* 2017; **127**: 1878-1884 [PMID: 28719039 DOI: 10.1002/lary.26382]
 - 22 **Moreno-Gómez FN**, Véliz G, Rojas M, Martínez C, Olmedo R, Panussis F, Dagnino-Subiabre A, Delgado C, Delano PH. Music Training and Education Slow the Deterioration of Music Perception Produced by Presbycusis in the Elderly. *Front Aging Neurosci* 2017; **9**: 149 [PMID: 28579956 DOI: 10.3389/fnagi.2017.00149]
 - 23 **Aarhus L**, Tambs K, Hoffman HJ, Engdahl B. Childhood otitis media is associated with dizziness in adulthood: the HUNT cohort study. *Eur Arch Otorhinolaryngol* 2016; **273**: 2047-2054 [PMID: 26335289 DOI: 10.1007/s00405-015-3764-9]



Published by **Baishideng Publishing Group Inc**
7041 Koll Center Parkway, Suite 160, Pleasanton, CA 94566, USA

Telephone: +1-925-3991568

E-mail: bpgoffice@wjgnet.com

Help Desk: <https://www.f6publishing.com/helpdesk>

<https://www.wjgnet.com>

