


World Journal of *Clinical Cases*

World J Clin Cases 2022 March 6; 10(7): 2053-2361



FIELD OF VISION

- 2053 Personalized treatment - which interaction ingredients should be focused to capture the unconscious
Steinmair D, Löffler-Stastka H

MINIREVIEWS

- 2063 Patterns of liver profile disturbance in patients with COVID-19
Shousha HI, Ramadan A, Lithy R, El-Kassas M

ORIGINAL ARTICLE**Clinical and Translational Research**

- 2072 Prognostic and biological role of the N-Myc downstream-regulated gene family in hepatocellular carcinoma
Yin X, Yu H, He XK, Yan SX

Case Control Study

- 2087 Usefulness of the acromioclavicular joint cross-sectional area as a diagnostic image parameter of acromioclavicular osteoarthritis
Joo Y, Moon JY, Han JY, Bang YS, Kang KN, Lim YS, Choi YS, Kim YU
- 2095 Correlation between betatrophin/angiogenin-likeprotein3/lipoprotein lipase pathway and severity of coronary artery disease in Kazakh patients with coronary heart disease
Qin L, Rehemuding R, Ainiwaer A, Ma X

Retrospective Study

- 2106 Postoperative adverse cardiac events in acute myocardial infarction with high thrombus load and best time for stent implantation
Zhuo MF, Zhang KL, Shen XB, Lin WC, Hu B, Cai HP, Huang G
- 2115 Develop a nomogram to predict overall survival of patients with borderline ovarian tumors
Gong XQ, Zhang Y

Clinical Trials Study

- 2127 Diagnostic performance of Neutrophil CD64 index, procalcitonin, and C-reactive protein for early sepsis in hematological patients
Shang YX, Zheng Z, Wang M, Guo HX, Chen YJ, Wu Y, Li X, Li Q, Cui JY, Ren XX, Wang LR
- 2138 Previously unexplored etiology for femoral head necrosis: Metagenomics detects no pathogens in necrotic femoral head tissue
Liu C, Li W, Zhang C, Pang F, Wang DW

Observational Study

- 2147** Association of types of diabetes and insulin dependency on birth outcomes
Xaverius PK, Howard SW, Kiel D, Thurman JE, Wankum E, Carter C, Fang C, Carriere R
- 2159** Pathological pattern of endometrial abnormalities in postmenopausal women with bleeding or thickened endometrium
Xue H, Shen WJ, Zhang Y
- 2166** *In vitro* maturation of human oocytes maintaining good development potential for rescue intracytoplasmic sperm injection with fresh sperm
Dong YQ, Chen CQ, Huang YQ, Liu D, Zhang XQ, Liu FH
- 2174** Ultrasound-guided paravertebral nerve block anesthesia on the stress response and hemodynamics among lung cancer patients
Zhen SQ, Jin M, Chen YX, Li JH, Wang H, Chen HX

META-ANALYSIS

- 2184** Prognostic value of YKL-40 in colorectal carcinoma patients: A meta-analysis
Wang J, Qi S, Zhu YB, Ding L
- 2194** Prognostic value of neutrophil/lymphocyte, platelet/lymphocyte, lymphocyte/monocyte ratios and Glasgow prognostic score in osteosarcoma: A meta-analysis
Peng LP, Li J, Li XF

CASE REPORT

- 2206** Endovascular stent-graft treatment for aortoesophageal fistula induced by an esophageal fishbone: Two cases report
Gong H, Wei W, Huang Z, Hu Y, Liu XL, Hu Z
- 2216** Quetiapine-related acute lung injury: A case report
Huang YX, He GX, Zhang WJ, Li BW, Weng HX, Luo WC
- 2222** Primary hepatic neuroendocrine neoplasm diagnosed by somatostatin receptor scintigraphy: A case report
Akabane M, Kobayashi Y, Kinowaki K, Okubo S, Shindoh J, Hashimoto M
- 2229** Multidisciplinary non-surgical treatment of advanced periodontitis: A case report
Li LJ, Yan X, Yu Q, Yan FH, Tan BC
- 2247** Flip-over of blood vessel intima caused by vascular closure device: A case report
Sun LX, Yang XS, Zhang DW, Zhao B, Li LL, Zhang Q, Hao QZ
- 2253** Huge gastric plexiform fibromyxoma presenting as pyemia by rupture of tumor: A case report
Zhang R, Xia LG, Huang KB, Chen ND
- 2261** Intestinal intussusception caused by intestinal duplication and ectopic pancreas: A case report and review of literature
Wang TL, Gong XS, Wang J, Long CY

- 2268** Mixed neuroendocrine-nonneuroendocrine neoplasm of the ampulla: Four case reports
Wang Y, Zhang Z, Wang C, Xi SH, Wang XM
- 2275** Y-shaped shunt for the treatment of Dandy-Walker malformation combined with giant arachnoid cysts: A case report
Dong ZQ, Jia YF, Gao ZS, Li Q, Niu L, Yang Q, Pan YW, Li Q
- 2281** Posterior reversible encephalopathy syndrome in a patient with metastatic breast cancer: A case report
Song CH, Lee SJ, Jeon HR
- 2286** Multiple skin abscesses associated with bacteremia caused by *Burkholderia gladioli*: A case report
Wang YT, Li XW, Xu PY, Yang C, Xu JC
- 2294** Giant infected hepatic cyst causing exclusion pancreatitis: A case report
Kenzaka T, Sato Y, Nishisaki H
- 2301** Cutaneous leishmaniasis presenting with painless ulcer on the right forearm: A case report
Zhuang L, Su J, Tu P
- 2307** Gastrointestinal amyloidosis in a patient with smoldering multiple myeloma: A case report
Liu AL, Ding XL, Liu H, Zhao WJ, Jing X, Zhou X, Mao T, Tian ZB, Wu J
- 2315** Breast and dorsal spine relapse of granulocytic sarcoma after allogeneic stem cell transplantation for acute myelomonocytic leukemia: A case report
Li Y, Xie YD, He SJ, Hu JM, Li ZS, Qu SH
- 2322** Synchronous but separate neuroendocrine tumor and high-grade dysplasia/adenoma of the gall bladder: A case report
Hsiao TH, Wu CC, Tseng HH, Chen JH
- 2330** Novel mutations of the Alström syndrome 1 gene in an infant with dilated cardiomyopathy: A case report
Jiang P, Xiao L, Guo Y, Hu R, Zhang BY, He Y
- 2336** Acute esophageal obstruction after ingestion of psyllium seed husk powder: A case report
Shin S, Kim JH, Mun YH, Chung HS
- 2341** Spontaneous dissection of proximal left main coronary artery in a healthy adolescent presenting with syncope: A case report
Liu SF, Zhao YN, Jia CW, Ma TY, Cai SD, Gao F
- 2351** Relationship between treatment types and blood-brain barrier disruption in patients with acute ischemic stroke: Two case reports
Seo Y, Kim J, Chang MC, Huh H, Lee EH
- 2357** Ultrasound-guided rectus sheath block for anterior cutaneous nerve entrapment syndrome after laparoscopic surgery: A case report
Sawada R, Watanabe K, Tokumine J, Lefor AK, Ando T, Yoroze T

ABOUT COVER

Editorial Board Member of *World Journal of Clinical Cases*, Feng Yin, MD, PhD, Assistant Professor, Department of Pathology and Anatomic Sciences, University of Missouri, Columbia, MO 65212, United States.
fengyin@health.missouri.edu

AIMS AND SCOPE

The primary aim of *World Journal of Clinical Cases* (WJCC, *World J Clin Cases*) is to provide scholars and readers from various fields of clinical medicine with a platform to publish high-quality clinical research articles and communicate their research findings online.

WJCC mainly publishes articles reporting research results and findings obtained in the field of clinical medicine and covering a wide range of topics, including case control studies, retrospective cohort studies, retrospective studies, clinical trials studies, observational studies, prospective studies, randomized controlled trials, randomized clinical trials, systematic reviews, meta-analysis, and case reports.

INDEXING/ABSTRACTING

The WJCC is now indexed in Science Citation Index Expanded (also known as SciSearch®), Journal Citation Reports/Science Edition, Scopus, PubMed, and PubMed Central. The 2021 Edition of Journal Citation Reports® cites the 2020 impact factor (IF) for WJCC as 1.337; IF without journal self cites: 1.301; 5-year IF: 1.742; Journal Citation Indicator: 0.33; Ranking: 119 among 169 journals in medicine, general and internal; and Quartile category: Q3. The WJCC's CiteScore for 2020 is 0.8 and Scopus CiteScore rank 2020: General Medicine is 493/793.

RESPONSIBLE EDITORS FOR THIS ISSUE

Production Editor: Lin-YuTong Wang; Production Department Director: Xiang Li; Editorial Office Director: Jin-Lai Wang.

NAME OF JOURNAL

World Journal of Clinical Cases

ISSN

ISSN 2307-8960 (online)

LAUNCH DATE

April 16, 2013

FREQUENCY

Thrice Monthly

EDITORS-IN-CHIEF

Bao-Gan Peng, Jerzy Tadeusz Chudek, George Kontogeorgos, Maurizio Serati, Ja Hyeon Ku

EDITORIAL BOARD MEMBERS

<https://www.wjgnet.com/2307-8960/editorialboard.htm>

PUBLICATION DATE

March 6, 2022

COPYRIGHT

© 2022 Baishideng Publishing Group Inc

INSTRUCTIONS TO AUTHORS

<https://www.wjgnet.com/bpg/gerinfo/204>

GUIDELINES FOR ETHICS DOCUMENTS

<https://www.wjgnet.com/bpg/GerInfo/287>

GUIDELINES FOR NON-NATIVE SPEAKERS OF ENGLISH

<https://www.wjgnet.com/bpg/gerinfo/240>

PUBLICATION ETHICS

<https://www.wjgnet.com/bpg/GerInfo/288>

PUBLICATION MISCONDUCT

<https://www.wjgnet.com/bpg/gerinfo/208>

ARTICLE PROCESSING CHARGE

<https://www.wjgnet.com/bpg/gerinfo/242>

STEPS FOR SUBMITTING MANUSCRIPTS

<https://www.wjgnet.com/bpg/GerInfo/239>

ONLINE SUBMISSION

<https://www.f6publishing.com>

Multidisciplinary non-surgical treatment of advanced periodontitis: A case report

Ling-Jun Li, Xiang Yan, Qing Yu, Fu-Hua Yan, Bao-Chun Tan

Specialty type: Dentistry, oral surgery and medicine

Provenance and peer review: Unsolicited article; Externally peer reviewed.

Peer-review model: Single blind

Peer-review report's scientific quality classification

Grade A (Excellent): 0
Grade B (Very good): 0
Grade C (Good): C, C, C
Grade D (Fair): 0
Grade E (Poor): 0

P-Reviewer: Ghaffar KA, Heboyen A, Meqa K

Received: August 26, 2021

Peer-review started: August 26, 2021

First decision: October 22, 2021

Revised: November 29, 2021

Accepted: January 22, 2022

Article in press: January 22, 2022

Published online: March 6, 2022



Ling-Jun Li, Fu-Hua Yan, Bao-Chun Tan, Department of Periodontics, Nanjing Stomatological Hospital, Medical School of Nanjing University, Nanjing 210008, Jiangsu Province, China

Xiang Yan, Department of Orthodontics, Nanjing Stomatological Hospital, Medical School of Nanjing University, Nanjing 210008, Jiangsu Province, China

Qing Yu, Department of Prosthodontics, Nanjing Stomatological Hospital, Medical School of Nanjing University, Nanjing 210008, Jiangsu Province, China

Corresponding author: Bao-Chun Tan, MS, Doctor, Department of Periodontics, Nanjing Stomatological Hospital, Medical School of Nanjing University, No. 30 Zhongyang Road, Nanjing 210008, Jiangsu Province, China. tanbaochun2002@163.com

Abstract

BACKGROUND

Patients with severe periodontitis often require multidisciplinary treatment to achieve healthy periodontal tissue, normal occlusion, and optimal aesthetics. In the present study, we aimed to evaluate the efficacy of multidisciplinary non-surgical treatment in a patient with stage IV/ grade C periodontitis, malocclusion, and dentition defects.

CASE SUMMARY

A 47-year-old woman visited our periodontology department due to teeth mobility problems and difficulties chewing food. The patient had no history of drug allergies or systemic disease. Initial therapy involved scaling and root planning with a Gracey scaler and periodontal ultrasonic therapeutic apparatus using a periodontal endoscope (Perioscopy, Zest Dental Solutions, United States) to control the periodontal inflammation prior to treatment. Five months later, orthodontic treatment was then performed to treat occlusion and overall aesthetics. After completion, a Maryland bridge was used to restore Nos. 22, 31, and 41 teeth. Florida probing (Florida probe, United States) was performed every 2-3 mo to evaluate the periodontal condition throughout treatment. Overall, multidisciplinary non-surgical treatment resulted in satisfactory aesthetic results with healthy periodontal tissue and stable occlusion.

CONCLUSION

In some patients with stage IV/grade C periodontitis, systematic and sequential non-surgical treatment can provide excellent therapeutic results.

Key Words: Periodontitis; Periodontal endoscopy; Florida probing; Non-surgical treatment; Multidisciplinary treatment; Case report

©The Author(s) 2022. Published by Baishideng Publishing Group Inc. All rights reserved.

Core Tip: We present a case of severe periodontitis treated with standardized multidisciplinary therapy, with excellent therapeutic effects. This case report offers new insight into the treatment of patients with stage IV/ grade C periodontitis, highlighting the potential of a systematic and sequential non-surgical approach.

Citation: Li LJ, Yan X, Yu Q, Yan FH, Tan BC. Multidisciplinary non-surgical treatment of advanced periodontitis: A case report. *World J Clin Cases* 2022; 10(7): 2229-2246

URL: <https://www.wjgnet.com/2307-8960/full/v10/i7/2229.htm>

DOI: <https://dx.doi.org/10.12998/wjcc.v10.i7.2229>

INTRODUCTION

Periodontitis is a chronic inflammatory disease caused by plaque microorganisms that can lead to periodontal tissue inflammation and alveolar bone loss. If untreated, periodontitis increases the risk of loose teeth and subsequent tooth loss[1]. Global epidemiological studies have shown a high prevalence of periodontitis in various countries including China, America, and Britain[2,3]. In addition to initial treatment, periodontal surgery is often required to completely remove local inflammatory stimulation and restore the normal appearance of periodontal soft and hard tissue[4]. However, in patients with severe periodontitis, sequential periodontal treatment usually requires a range of periodontal surgery and high expenditure, which many patients cannot afford. Meanwhile, studies have also shown that subgingival scaling and root debridement with periodontal endoscopy can have a similarly positive therapeutic effect[5].

Occlusion disorder problems often occur in patients with severe periodontitis, while secondary occlusal trauma can aggravate the destruction of periodontal tissue; however, both can be treated orthodontically[6]. Sim *et al*[6] and Angelina *et al*[7] have both reported that orthodontic treatment will not exacerbate periodontal destruction if the periodontal inflammation and plaque are initially controlled. Moreover, postoperative stable occlusion was found to promote periodontal tissue recovery.

However, in patients with advanced periodontitis, choosing an appropriate prosthetic treatment plan can be difficult when considering restoration of the denture deficiency, minimization of damage to the abutment teeth, and increasing the stability of the periodontal tissue. A recent study showed that fixed prosthodontic treatment in compliant patients is highly successful after 20 years of supportive periodontal care[8]. Moreover, several studies have also demonstrated that prosthodontics need to be designed according to the periodontal conditions of the patient, with different fixed dental prostheses having an effect on the periodontium[9-12]. The Maryland bridge has also been suggested in such cases, providing restoration of missing teeth with long-term stability[13].

In this case report, we present a patient with stage IV/ grade C periodontitis who achieved a good treatment outcome following nonsurgical periodontal treatment, orthodontic treatment, and prosthodontic treatment with a Maryland bridge, bringing new insight into the treatment of advanced periodontal disease.

CASE PRESENTATION

Chief complaints

A 47 year old woman with no medical history presented to our hospital for teeth mobility problems.

History of present illness

While collecting detailed medical history, the patient complained of long-term problems with tooth loss and difficulties chewing. The patient had undergone no previous oral therapy, and sought treatment due to recent worsening of her chewing difficulties. The patient had mild halitosis and occasional bleeding during tooth brushing.

History of past illness

The patient had no significant medical history.

Personal and family history

The patient had no significant personal or family history.

Physical examination

In the clinical examination, we identified poor oral hygiene with a large amount of dental calculus and obvious plaque retention. The gingiva tissues appeared tender and edematous (Figure 1). No. 21 tooth was distinctly labially inclined, while Nos. 31 and 41 were extremely loose. Overall, 83% of her teeth (25 teeth) showed mobility \geq I°, and more than 50% presented a probing depth (PD) of > 4 mm with positive bleeding on probing (BOP). According to the “Classification of Periodontal and Peri-Implant Diseases and Conditions” in 2017[14] and the Angle classification[15], the patient was diagnosed with: (1) Periodontitis stage IV/ grade C; (2) angle class III skeletal malocclusion, with maxillary and mandibular prognathism; and (3) moderate crowded malocclusion. A therapeutic plan was subsequently proposed by a team of periodontists, orthodontists, and a prosthodontist. In view of her periodontal condition and dental calculus, supragingival ultrasonic scaling was carried out ahead of detailed examination in order to provide a baseline level 1 wk later.

Imaging examinations

Preoperative panoramic radiographs (Figure 1 baseline) revealed that the full mouth alveolar bone was absorbed to varying degrees into the middle 1/2 and apical 1/3 of the root, with Nos. 22 and 31 teeth absorbed into the apical region.

Patient consent and ethical approval

The patient approved the treatment plan and provided signed informed consent for inclusion in this case report. The report was reviewed and approved by the Ethics Committee of Nanjing Stomatological Hospital, Medical School of Nanjing University (Nanjing, China).

Methodology

Oral hygiene (plaque assessment): Oral hygiene and the amount of plaque near the gingival margin were examined by visual inspection and probing.

Florida probe: The Florida probe, a computerized system that transfers periodontal pressure-sensitive probing and charting systems into a graphical representation, was used throughout periodontal treatment. The system stores digital records of each periodontal treatment session, allowing the effectiveness of a course of treatment to be monitored.

Periodontal pocket depth: A periodontal probe was inserted into the periodontal pocket parallel to the long axis of the tooth. The periodontal pocket was then probed to determine the depth of central, mesial, and distal sites on the labial/buccal and lingual/palatal sides of the tooth, respectively.

Tooth mobility assessment: Forceps were placed around the incisal margins of the anterior teeth and then closed around the posterior teeth. The teeth were then moved in a buccal-lingual or mesial-distal direction with the forceps tip against the occlusal fossa and graded as follows: I°, mobility within 1 mm or only in a buccal-lingual direction; II°, mobility within a range of 1-2 mm or in buccal-lingual and mesial-distal directions; III°, mobility greater than 2 mm in buccal-lingual, mesial-distal, and vertical directions.

Bleeding on probing: A probe was inserted into the base of the periodontal pocket or the sulcus then removed, and the gingival margin was observed for bleeding.

X-ray evaluation: Periodontal hard tissues, notably the alveolar bone, was visualized using panoramic and apical radiographs.

FINAL DIAGNOSIS

Based on the clinical and imaging examinations, a final periodontal diagnosis of periodontitis (stage IV, grade C)/extensively severe chronic periodontitis and a final orthodontic diagnosis of Angle class I neutroclusion were made.

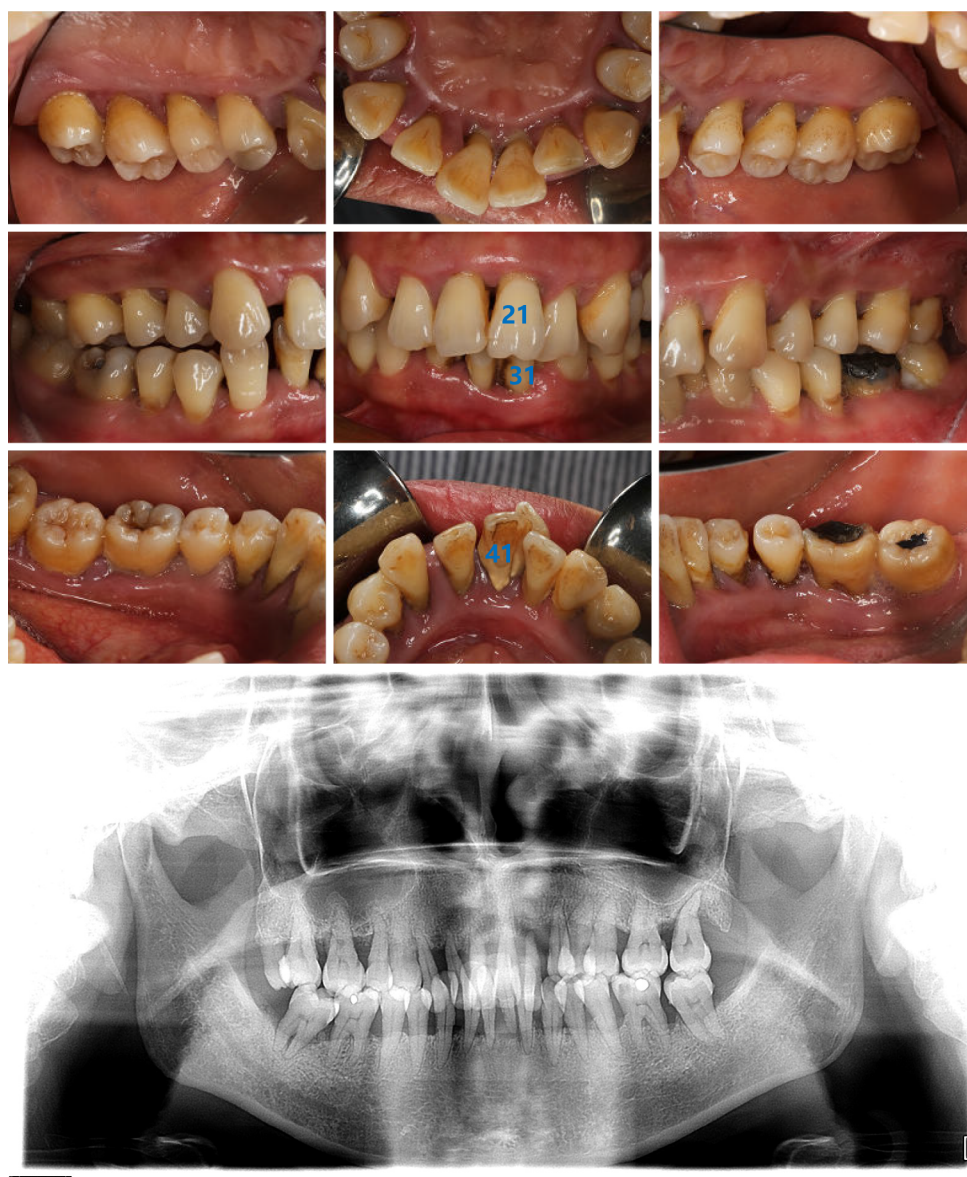


Figure 1 Intraoral images and radiographic image obtained at the first visit. Intraoral images show the poor level of oral hygiene, a large amount of dental calculus, and obvious plaque retention. No. 21 tooth was distinctly labially inclined and Nos. 31 and 41 were extremely loose. The radiographic image reveals that the full mouth alveolar bone was absorbed to varying degrees into the middle 1/2 and apical 1/3 of the root, with Nos. 22 and 31 absorbed to the apical region.

TREATMENT

Intraoral images obtained at the first visit showed a poor level of oral hygiene, a large amount of dental calculus, and obvious plaque retention (Figure 1). No. 21 tooth was distinctly labially inclined and Nos. 31 and 41 were extremely loose.

Therapeutic goal

The overall aim was to improve the periodontal condition and encourage efficient oral hygiene habits and plaque control. The aesthetic needs of the patient and problems with occlusion were also considered.

Therapeutic plan

At the beginning of treatment, the patient showed a desire to maintain her teeth and refused periodontal surgery. The therapeutic plan therefore consisted of: (1) Non-surgical initial periodontal therapy, with supra- and subgingival scaling, and root debridement using a periodontal endoscope; (2) orthodontic treatment aimed at improving occlusion and aesthetics; and (3) suitable prosthodontic treatment (*i.e.*, Maryland fixed bridge restoration). The patient's clinical index was continuously monitored and risk assessment was carried out throughout treatment, which lasted 38 mo. The treatment plan is shown in Figure 2.

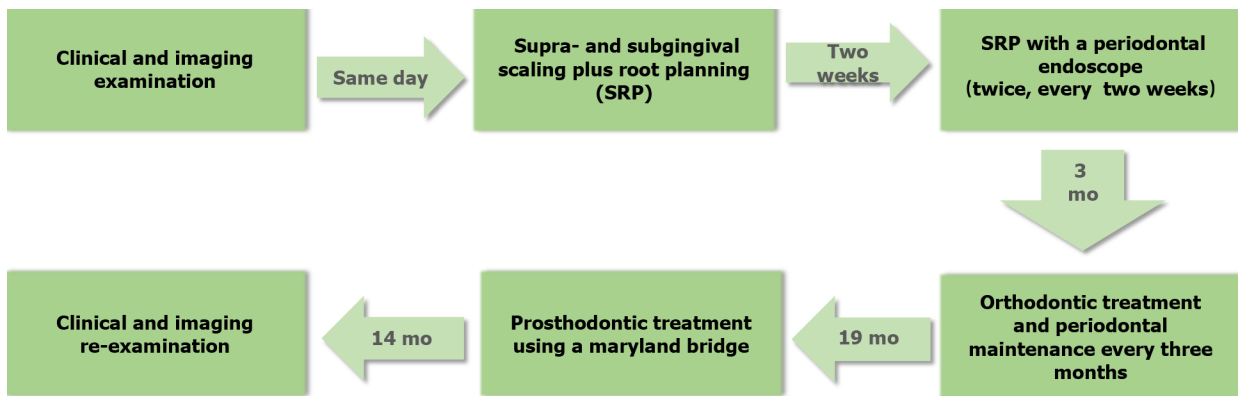


Figure 2 Timeline flow chart of the treatment plan.

Initial periodontal therapy

Initial periodontal therapy was based on mechanical removal of bacterial plaque *via* nonsurgical treatment, with standardized supra and subgingival scaling plus root planning (SRP). During the second visit, Nos. 22, 31, and 41 teeth were subsequently extracted. To achieve total calculus removal, SRP was carried out using a periodontal endoscope in sites with pockets ≥ 5 mm. Two weeks later, the patient underwent a session of professional plaque control, including reinforcement of oral hygiene processes *via* monthly checks and the use of plaque disclosing agents to facilitate daily examinations. Twelve weeks after completion of active therapy, the periodontal inflammation was deemed under control. Positive BOP sites were reduced by 86%-39%, and the plaque index showed that the plaque accumulation markedly decreased by 100%-17%, with a reduction in deep pockets ≥ 5 mm of 63%-2%. Orthodontic treatment was therefore initiated, with thorough examination and risk assessment using a Florida probe (Figure 3). A marked reduction in periodontal pockets was observed while probing; however, her risk assessment level remained high before orthodontic treatment, decreasing to moderate after 13-mo treatment (Figure 3A and B). The patient was recalled for periodontal maintenance every 3 mo throughout orthodontic therapy, at which point her periodontal parameters were examined and any changes in her condition were recorded. Positive therapeutic effects with a low risk assessment level and overall improvements in PD were ultimately achieved (Figure 4).

Orthodontic treatment

After systematic periodontal therapy, a stable periodontal condition was achieved despite some teeth remaining mobile. We therefore consulted orthodontics for a critical evaluation, which highlighted that no tooth movement to the labial-buccal side was required during orthodontics, and therefore, there was no increased risk of loosening. Instead, the plan was considered beneficial in terms of stabilization following improvements to the occlusal relationship.

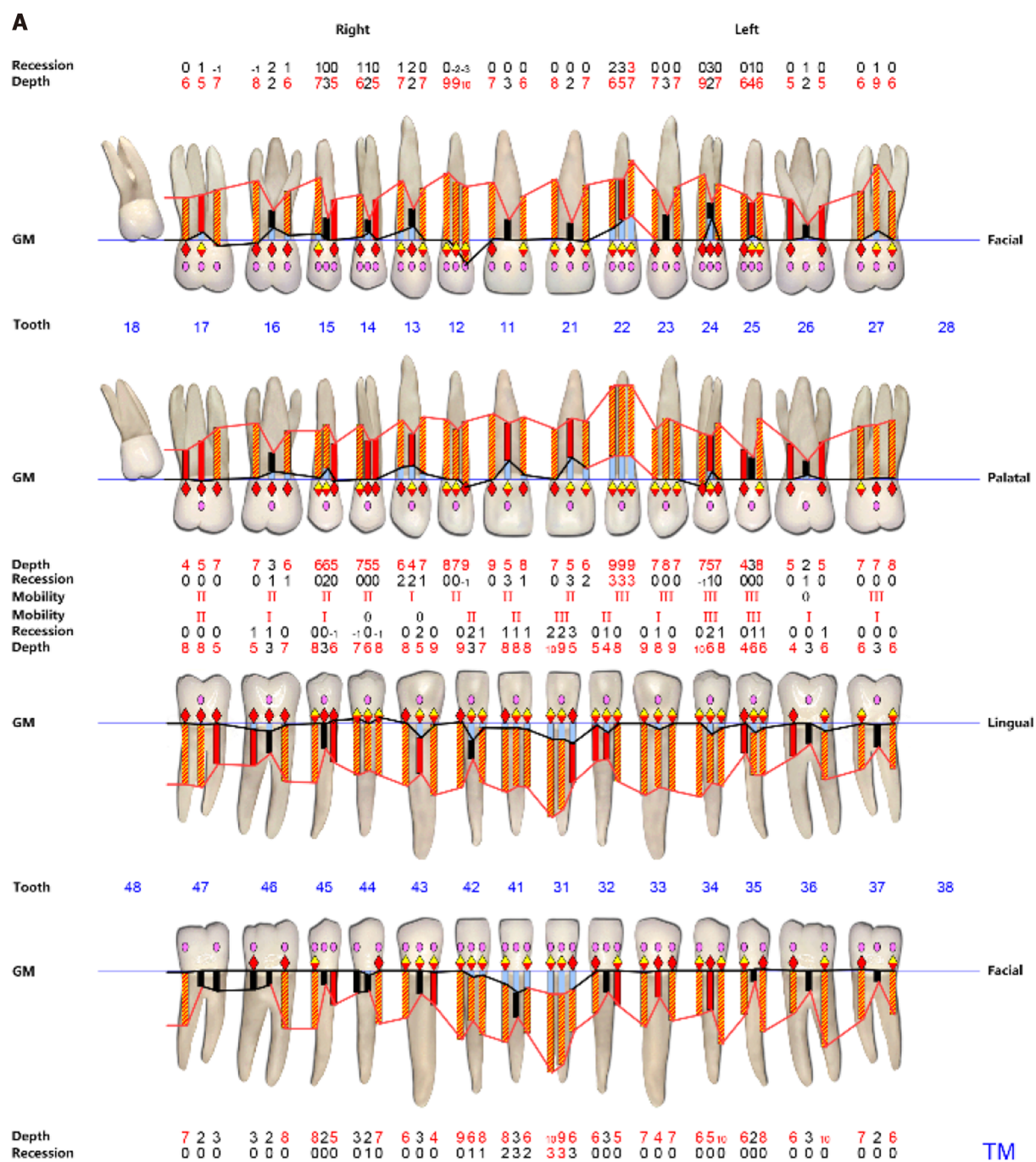
In order to correct the malocclusion and achieve a satisfactory occlusal relationship, orthodontic treatment was performed to initially align the teeth and then straighten the maxillary anterior teeth. Nickel titanium wires were used for alignment of the arches and interactive traction elastics were used for correction of the incisor position. The final duration of orthodontic treatment was 19 mo. The aesthetic profile was enhanced and the radiographic bone density increased in the molar region following periodontal and orthodontic treatment (Figure 5). Figure 6 shows intraoral and extraoral images obtained during treatment.

Prosthodontic treatment

After the completion of non-surgical periodontal and orthodontics treatment, the patient was referred to the department of prosthodontics for establishment of a prosthodontic treatment plan. Considering the compromised periodontal situation and tooth mobility problems, a Maryland bridge was selected on one side to provide full dentition, while on the other side, dental splints were used to fix the loose teeth (Figure 7). Eight months after treatment, the periodontal condition remained satisfactory and stable (Figure 8).

Supportive periodontal therapy

After completing prosthodontic treatment, the patient was called for follow-up visits every 3 mo, with intraoral images obtained after 8 mo. Periodontal examination with risk assessment was also performed using a Florida probe (Figure 8), revealing a stable periodontal condition and good plaque control. Another 6 mo later, radiographic data and additional intraoral images were obtained (Figure 9), revealing a continuous stable periodontal condition with no additional alveolar bone loss.



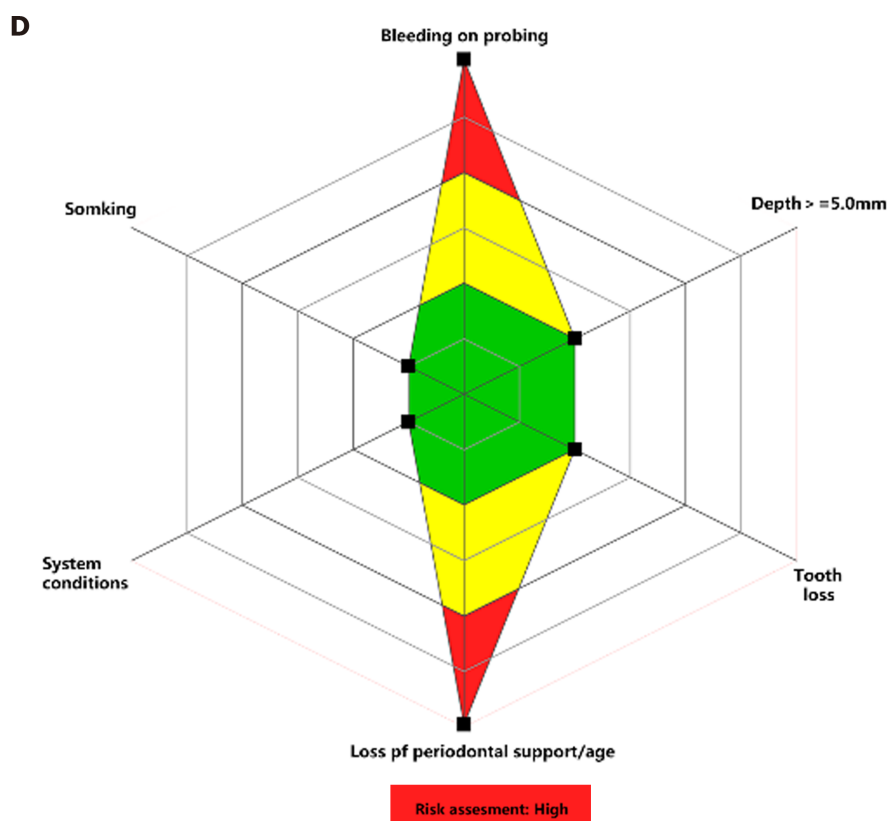


Figure 3 Periodontal charts and risk assessment. A and C: Periodontal charts obtained after supragingival scaling and 5 mo of initial nonsurgical periodontal treatment, respectively; B and D: Respective risk assessment levels obtained using a Florida probe at the same time points. Periodontal parameters remarkably improved, although the risk assessment level remained high before orthodontic therapy. GM: Gingival margin.

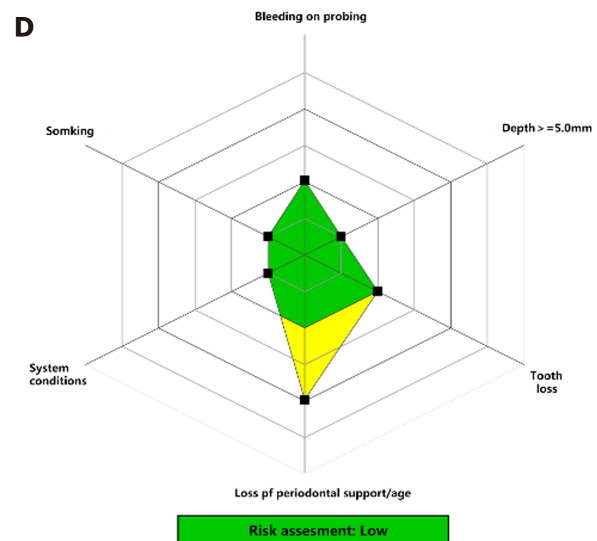
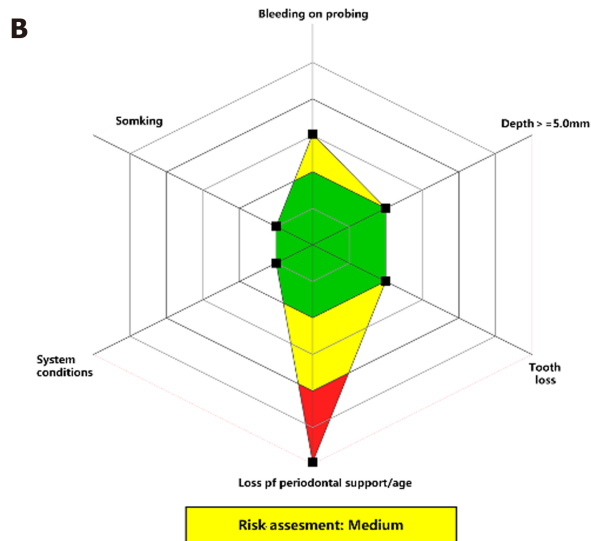
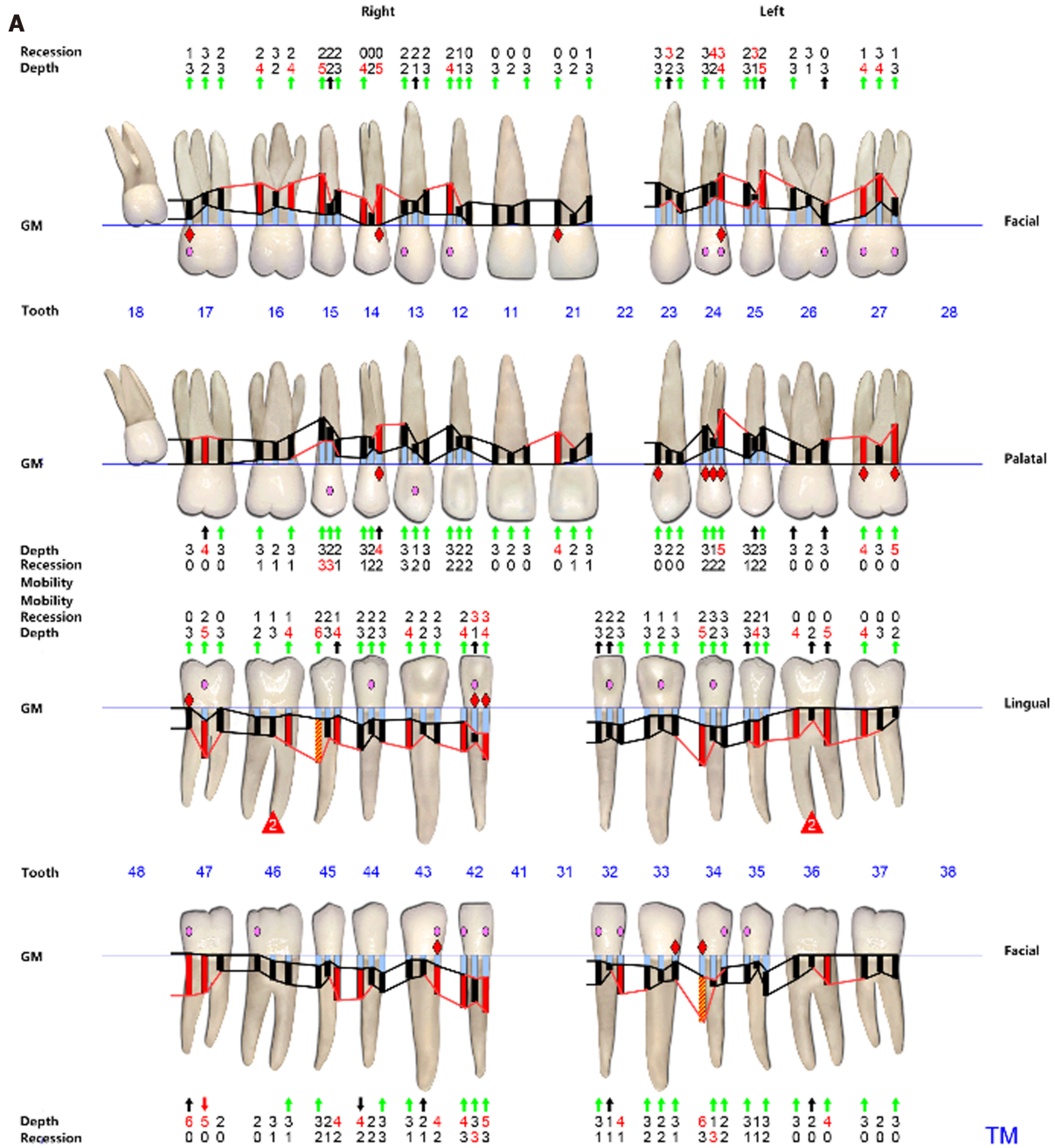
OUTCOME AND FOLLOW-UP

Supra- and subgingival scaling with root planing was initially performed using a periodontal endoscope, which took 5 mo. An obvious improvement in the patient's periodontal condition was revealed in terms of BOP and PD, and the high-risk assessment result decreased remarkably to low risk after 2-year treatment. Subsequently, based on the patient's desire for straightening teeth, consultation with the orthodontic doctor, and evaluation of the risk of orthodontic treatment, 19 mo of orthodontic treatment was commenced, providing excellent treatment effects. Obvious root absorption in the upper anterior teeth was observed in addition to an unusual root morphology.

DISCUSSION

Traditional periodontal treatment usually consists of four stages: Initial therapy, periodontal surgery, restorative therapy, and supportive periodontal therapy[16]. The aim of the second stage, periodontal surgery, is thorough debridement and restoration of the physiological morphology and function of the periodontal tissue. In this case study, we initially carried out supra- and subgingival scaling with root planing using a periodontal endoscope for 5 mo. Compared with general treatment, subgingival scaling and debridement with the aid of a periodontal endoscope are more thorough, offering a more efficient and minimally invasive approach for controlling periodontal inflammation. The main advantage of periodontal endoscopy is subgingival treatment with real-time image support[5], which directly displays the subgingival scaling process and therapeutic effect. This support is impractical with traditional treatment of, for example, deep periodontal pocket bottoms and multiple root bifurcations [17]. Periodontal endoscopic techniques can also reduce the risk of periodontal surgery and associated complications[18].

After completing initial treatment, re-evaluation is important, especially with severe periodontitis. In this case study, obvious improvement in the patient's periodontal condition was revealed, both in terms of BOP and PD, and the high-risk assessment result decreased remarkably to low risk after 2-year treatment. Moreover, the patient adopted a greatly improved oral hygiene routine. These re-assessment results are pivotal in determining the subsequent treatment plan. At present, the commonly accepted indicators representing the so-called "treatment endpoint" include: (1) No BOP; and (2) a PPD \leq 4 mm



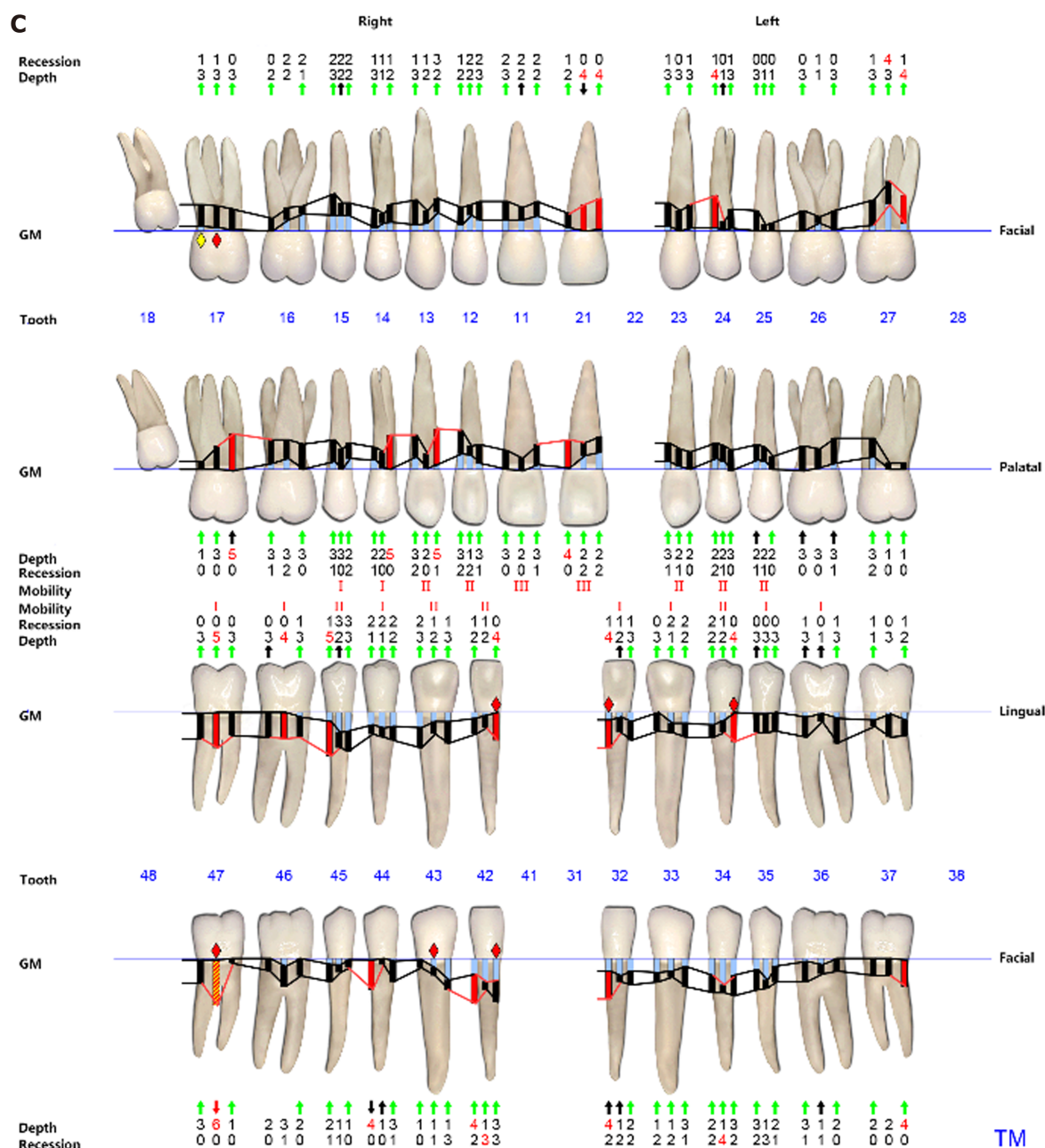


Figure 4 Periodontal charts and risk assessment. A and C: Periodontal charts obtained 1 mo after orthodontic treatment and at completion, respectively; B and D: Respective risk assessments levels obtained using a Florida probe at the same time points. Periodontal parameters continued to improve and the risk assessment level decreased from moderate to low after completion of orthodontic treatment. GM: Gingival margin.

[8]. A large number of long-term clinical studies have shown that patients with severe periodontitis who show good plaque control and receive only normative non-surgical periodontal treatment can achieve notable improvements in their periodontal condition[19]. For example, Barros *et al*[20] showed that non-surgical periodontal treatment alone could result in improvements in alveolar bone density.

In our case, 19 mo of orthodontic treatment provided excellent treatment effects. Orthodontic treatment can re-arrange the dentition, eliminate occlusal trauma, restore stability, and disperse the occlusal force, all of which are crucial in gaining healthy periodontal soft and hard tissue[6]. The precondition of orthodontic treatment is control of periodontal inflammation, which, if not achieved, can result in treatment failure or even accelerate periodontal destruction[21]. In patients with moderate to severe periodontal disease, periodontal-orthodontic treatment can not only correct malocclusion, but also significantly improve periodontal health[22]. Findings suggest that the performance of PD, plaque index, clinical attachment level, and the sulcus bleeding index of patients treated with combined orthodontic-periodontic treatment were much better than those treated with basic periodontics[23]. Notably, patients with periodontal disease must follow the principle of light force correction. Orthodontic forces are transmitted through periodontal fibers, which are the basis of tooth movement. The amount of orthodontic force depends on the periodontal ligament area of the teeth. If the alveolar

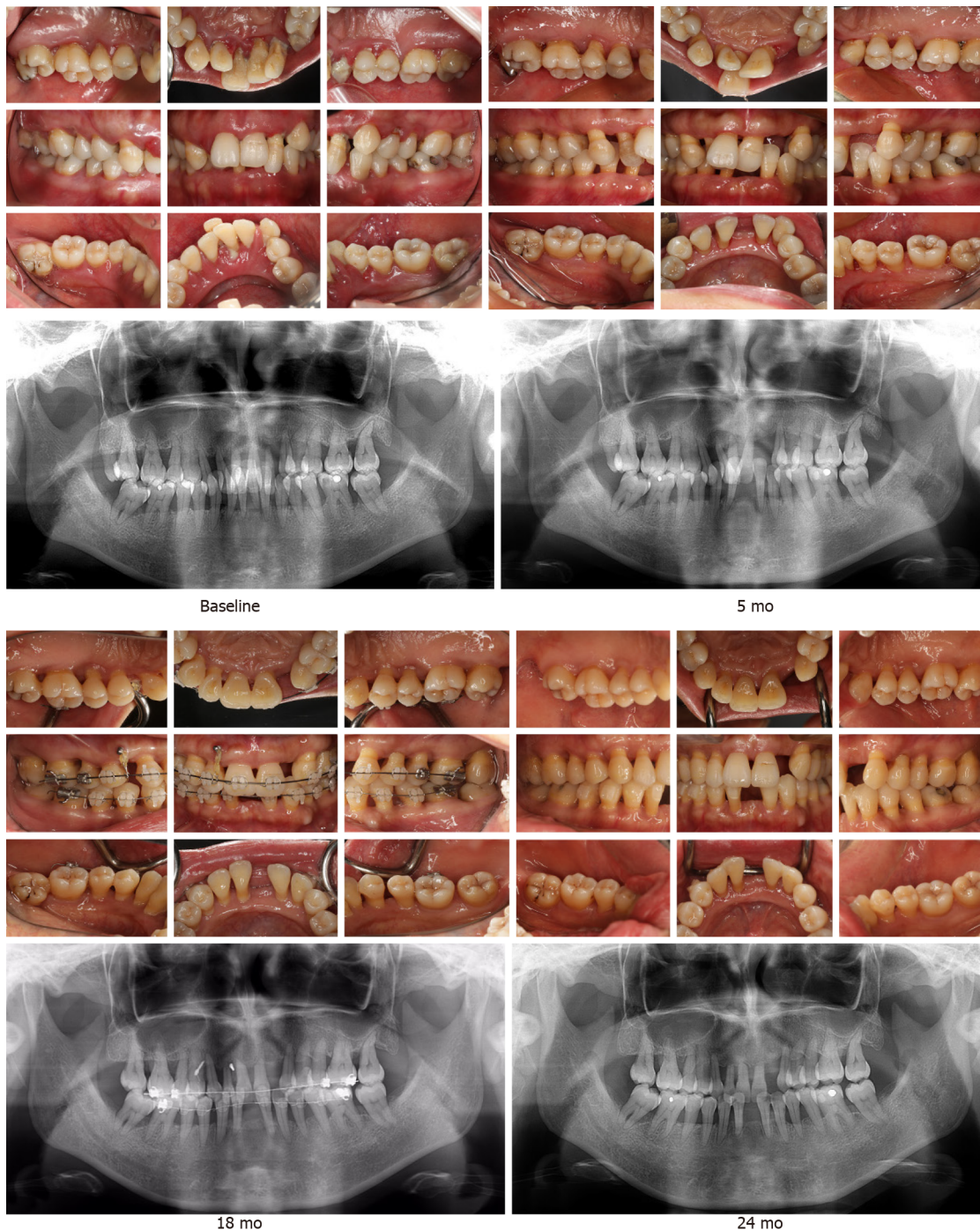


Figure 5 Intraoral and radiographic images obtained at baseline, and 5, 18, and 24 mo after treatment. The aesthetic profile was enhanced and the radiographic bone density increased in the molar region following periodontal and orthodontic treatment. Images show the excellent therapeutic outcome following multidisciplinary treatment.

bone height is reduced by 50%, the periodontal ligament area is reduced by 75%, leaving only 25%, and the orthodontic force should therefore be reduced to 25 rather than 50%. The orthodontic forces should therefore be determined according to the amount of residual alveolar bone[24]. In this case study, obvious root absorption in the upper anterior teeth was observed in addition to an unusual root morphology. It was previously reported that pointed and tapered apical morphologies are more likely to result in increased root absorption during orthodontic treatment[25,26].

It is often challenging to decide an appropriate prosthodontic treatment plan for patients with periodontitis resulting from a poor periodontal condition. However, with the development of oral prosthetics and manufacturing processes, even patients with severe periodontitis can undergo fixed denture restoration if the periodontal condition of the abutment teeth remains stable and meets the standard of clinical fixed denture abutment[8]. Fixed denture repair is more comfortable than removable dentures, and can improve periodontal tissue repair and the prognosis of loose teeth. Adhesive fixed dentures result in less teeth grinding and cutting, and do less harm to the abutment teeth. Corrente *et al*[27]

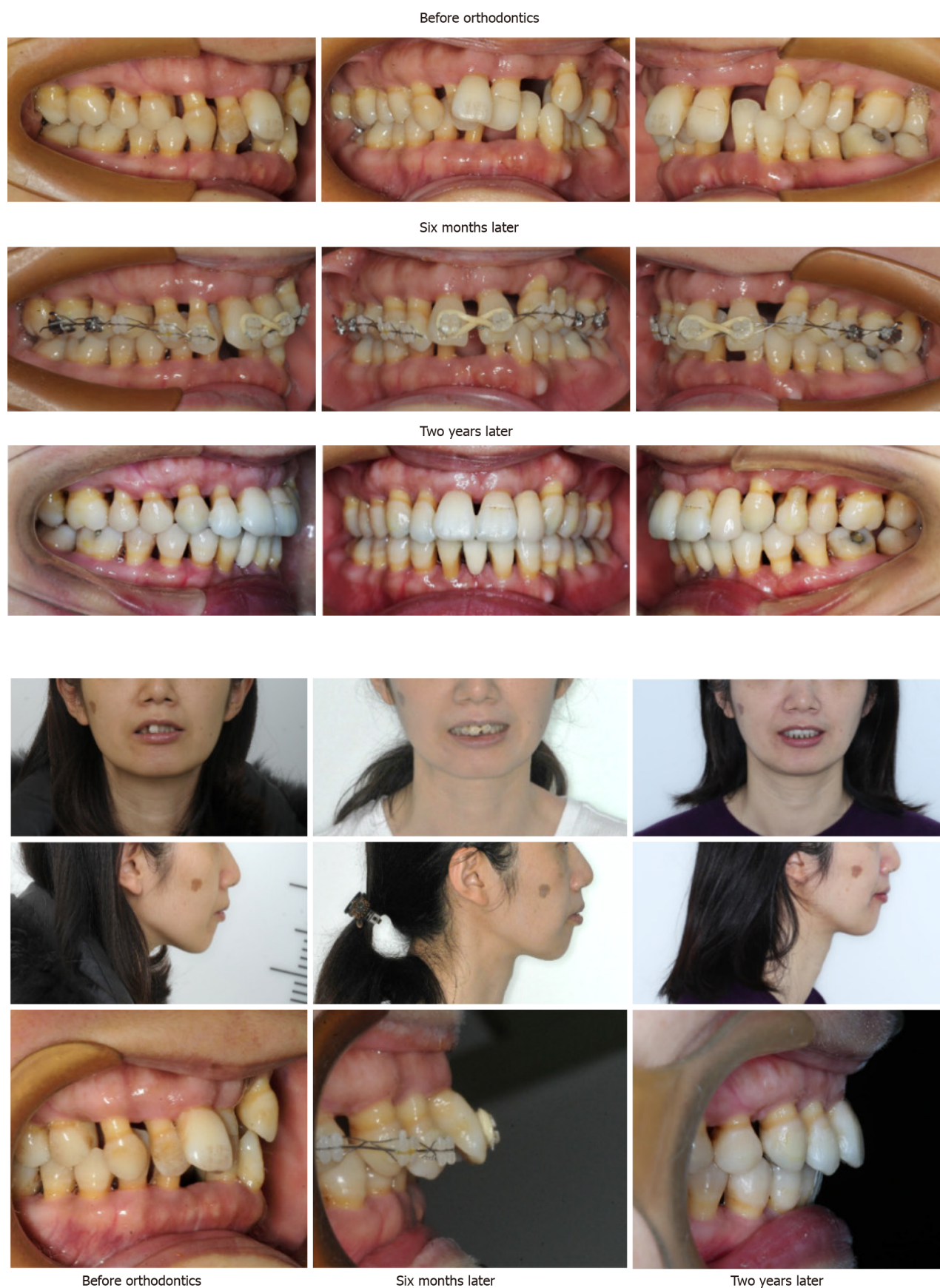


Figure 6 Intraoral and extraoral images obtained prior to, and 6 mo and 2 years following multidisciplinary treatment. Comparative views show the significant improvement in dentition, occlusion, and the aesthetic facial profile. Note the maintenance of a healthy periodontal condition.

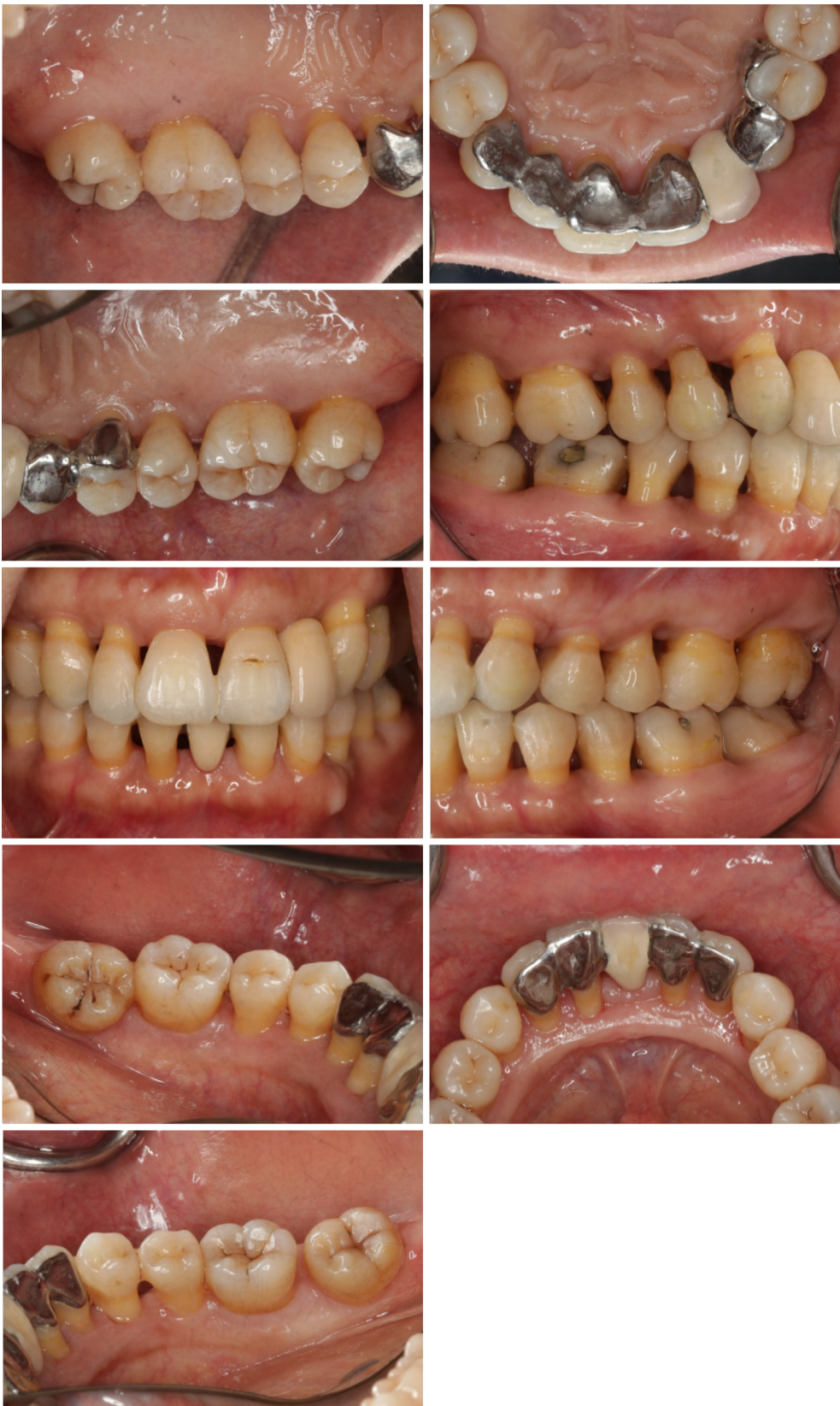

Figure 7 Intraoral images obtained after prosthodontic treatment. A Maryland bridge was used for Nos. 13-24 and 33-43 teeth to restore teeth 22, 31, and 41. Overall, stable occlusion and a satisfactory aesthetic appearance were obtained via the comprehensive multidisciplinary approach.

carried out a 10-year observational study of patients with periodontitis treated with bonded dentures, and revealed a cumulative denture survival rate of 76.2%. The Maryland bridge is widely used due to the minimal tooth preparation and subsequent reduction in pain. It is important to consider abutment teeth as much as possible during design since they act as periodontal splints, avoiding occlusal trauma and working as an entirety to restore the function and appearance of the missing teeth[28].

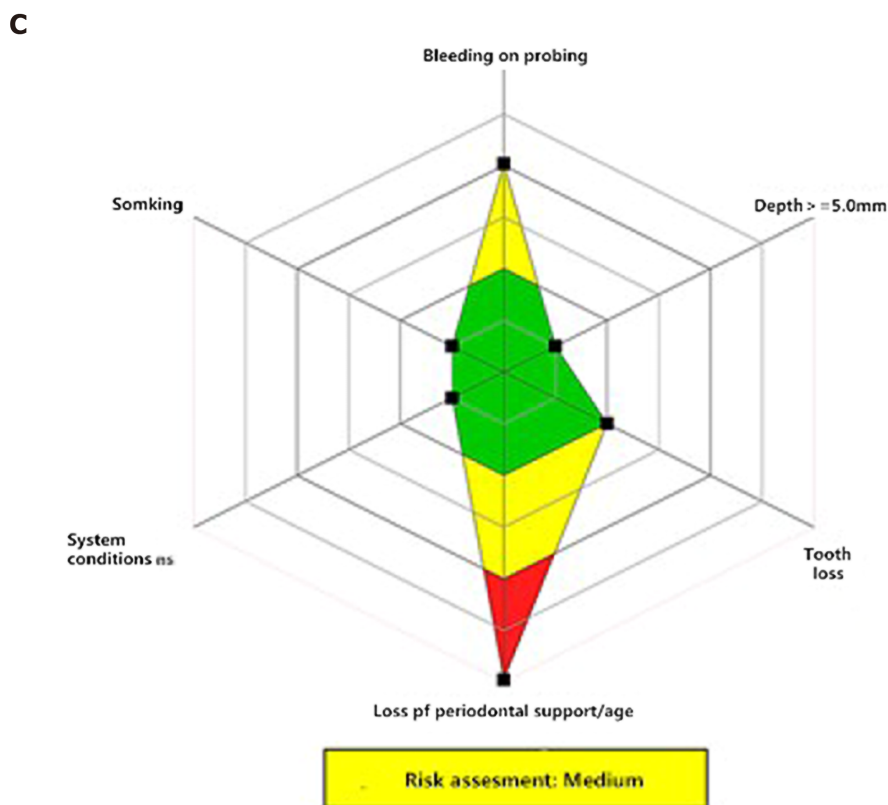
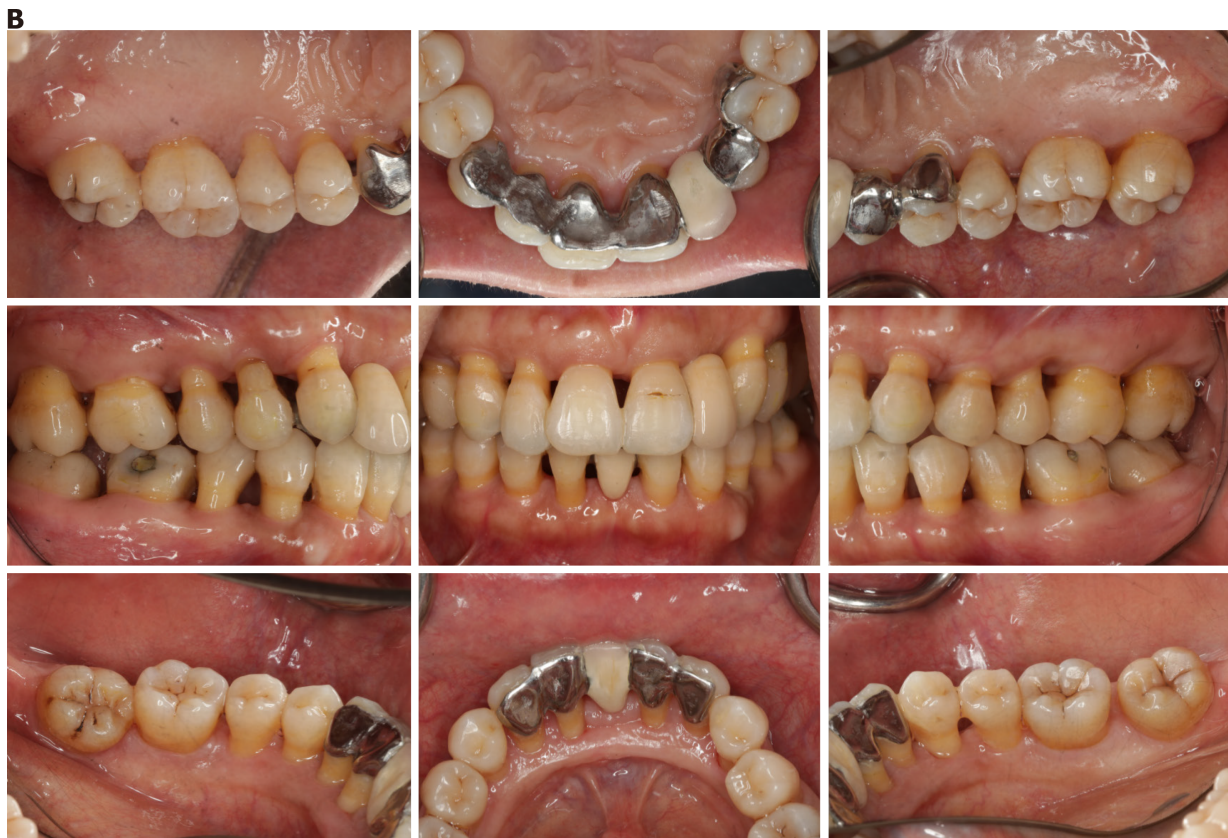

Figure 8 Periodontal condition analysis 8 mo after prosthodontic treatment (32 mo after starting treatment). The images show the stable periodontal condition obtained as a result of the comprehensive multidisciplinary approach. A: Periodontal charts obtained 8 mo after prosthodontic treatment; B: Intraoral images taken 8 mo after prosthodontic treatment; C: Risk assessment obtained 8 mo after prosthodontic treatment.

Overall, through multidisciplinary therapy lasting 38 mo and consisting of periodontal, orthodontic, and prosthodontic treatment, excellent therapeutic results were obtained in terms of aesthetics and occlusion. This case report highlights, therefore, that even in patients with severe periodontitis, by following serialized treatment and strict plaque control, non-surgical periodontal treatment can dramat-

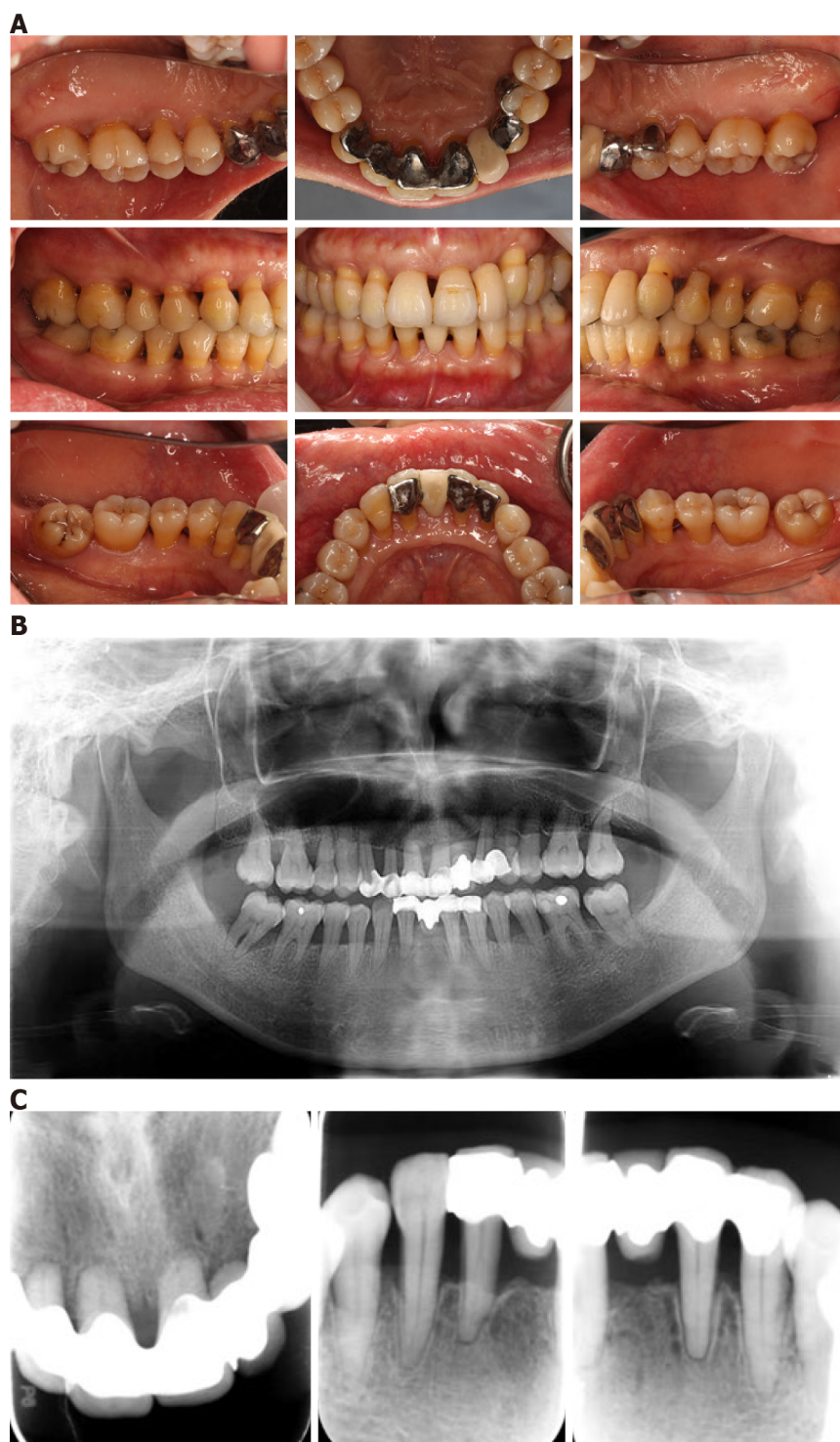


Figure 9 Periodontal condition analysis 14 mo after prosthodontic treatment (38 mo after starting treatment). The images show the stable periodontal condition obtained as a result of the comprehensive multidisciplinary approach. A: Intraoral images taken 14 mo after prosthodontic treatment; B: Panoramic radiograph taken 14 mo after prosthodontic treatment; C: Periapical films of the upper and lower anterior teeth 14 mo after prosthodontic treatment.

ically improve the overall periodontal condition and provide satisfactory therapeutic results.

CONCLUSION

In practice, to improve the treatment success of advanced periodontitis, a multidisciplinary approach involving orthodontics, prosthodontics, and endodontics is required. This case report offers new insight into the treatment of patients with advanced periodontitis, highlighting the potential of systematic and sequential non-surgical therapy.

FOOTNOTES

Author contributions: Tan BC was responsible for conceptualization and supervision; Li LJ was responsible for writing the original draft, reviewing, and editing; Yan X, Yu Q, and Yan FH contributed to investigation and data curation; all authors approved the final version to be submitted. Li LJ and Yan X contributed equally to this work.

Supported by the Nanjing Medical Science and Technology Development Program, No. YKK17139.

Informed consent statement: Informed written consent was obtained from the patient for publication of this report and any accompanying images.

Conflict-of-interest statement: The authors declare that they have no conflict of interest to disclose.

CARE Checklist (2016) statement: The authors have read the CARE Checklist (2016), and the manuscript was prepared and revised according to the CARE Checklist (2016).

Open-Access: This article is an open-access article that was selected by an in-house editor and fully peer-reviewed by external reviewers. It is distributed in accordance with the Creative Commons Attribution NonCommercial (CC BY-NC 4.0) license, which permits others to distribute, remix, adapt, build upon this work non-commercially, and license their derivative works on different terms, provided the original work is properly cited and the use is non-commercial. See: <https://creativecommons.org/licenses/by-nc/4.0/>

Country/Territory of origin: China

ORCID number: Ling-Jun Li 0000-0001-5625-0496; Xiang Yan 0000-0003-3687-9435; Qing Yu 0000-0002-5167-9370; Fu-Hua Yan 0000-0002-6963-3530; Bao-Chun Tan 0000-0002-8943-9356.

Corresponding Author's Membership in Professional Societies: Nanjing Stomatological Hospital, Medical School of Nanjing University.

S-Editor: Ma YJ

L-Editor: Wang TQ

P-Editor: Ma YJ

REFERENCES

- 1 **Borgnakke WS.** Does Treatment of Periodontal Disease Influence Systemic Disease? *Dent Clin North Am* 2015; **59**: 885-917 [PMID: 26427573 DOI: 10.1016/j.cden.2015.06.007]
- 2 **Martins MD, Jiao Y, Larsson L, Almeida LO, Garaicoa-Pazmino C, Le JM, Squarize CH, Inohara N, Giannobile WV, Castilho RM.** Epigenetic Modifications of Histones in Periodontal Disease. *J Dent Res* 2016; **95**: 215-222 [PMID: 26496800 DOI: 10.1177/0022034515611876]
- 3 **GBD 2016 Disease and Injury Incidence and Prevalence Collaborators.** Global, regional, and national incidence, prevalence, and years lived with disability for 328 diseases and injuries for 195 countries, 1990-2016: a systematic analysis for the Global Burden of Disease Study 2016. *Lancet* 2017; **390**: 1211-1259 [PMID: 28919117 DOI: 10.1016/S0140-6736(17)32154-2]
- 4 **Rios HF, Lin Z, Oh B, Park CH, Giannobile WV.** Cell- and gene-based therapeutic strategies for periodontal regenerative medicine. *J Periodontol* 2011; **82**: 1223-1237 [PMID: 21284553 DOI: 10.1902/jop.2011.100710]
- 5 **Kuang Y, Hu B, Chen J, Feng G, Song J.** Effects of periodontal endoscopy on the treatment of periodontitis: A systematic review and meta-analysis. *J Am Dent Assoc* 2017; **148**: 750-759 [PMID: 28637585 DOI: 10.1016/j.adaj.2017.05.011]
- 6 **Sim HY, Kim HS, Jung DU, Lee H, Lee JW, Han K, Yun KI.** Association between orthodontic treatment and periodontal diseases: Results from a national survey. *Angle Orthod* 2017; **87**: 651-657 [PMID: 28686092 DOI: 10.2319/030317-162.1]
- 7 **Gorbunkova A, Pagni G, Brizhak A, Farronato G, Rasperini G.** Impact of Orthodontic Treatment on Periodontal Tissues: A Narrative Review of Multidisciplinary Literature. *Int J Dent* 2016; **2016**: 4723589 [PMID: 26904120 DOI: 10.1155/2016/4723589]
- 8 **Di Febo G, Bedendo A, Romano F, Cairo F, Carnevale G.** Fixed prosthodontic treatment outcomes in the long-term management of patients with periodontal disease: a 20-year follow-up report. *Int J Prosthodont* 2015; **28**: 246-251 [PMID: 25965638 DOI: 10.11607/jip.3995]
- 9 **Vliegenthart JF.** Studies on glycoprotein-derived carbohydrates. *Biochem Soc Trans* 1994; **22**: 370-373 [PMID: 7958327 DOI: 10.3390/molecules26051331]
- 10 **Uccella R, Zibetti E, Gaiazzi M.** [Major histocompatibility complex antigens in a population of insulin-dependent diabetics living in the Province of Varese]. *Minerva Med* 1994; **85**: 71-76 [PMID: 8196846 DOI: 10.3390/ijms22115463]
- 11 **Heboyen A, Manrikyan M, Markaryan M, and Vardanyan I.** Changes in the Parameters of Gingival Crevicular Fluid in Masticatory Function Restoration by Various Prosthodontic Constructions. *Int J Pharm Res* 2020; **12**: 2088-2093 [DOI: 10.31838/ijpr/2020.12.02.280]
- 12 **Freeman S.** Occupational skin disease. *Curr Probl Dermatol* 1995; **22**: 80-85 [PMID: 7587339 DOI: 10.3390/molecules25204650]
- 13 **Kathariya R, Devanoorkar A, Golani R, Shetty N, Vallakatta V, Bhat MY.** To Splint or Not to Splint: The Current Status

- of Periodontal Splinting. *J Int Acad Periodontol* 2016; **18**: 45-56 [PMID: [27128157](#)]
- 14 **Papapanou PN**, Sanz M, Buduneli N, Dietrich T, Feres M, Fine DH, Flemmig TF, Garcia R, Giannobile WV, Graziani F, Greenwell H, Herrera D, Kao RT, Kebschull M, Kinane DF, Kirkwood KL, Kocher T, Kornman KS, Kumar PS, Loos BG, Machtei E, Meng H, Mombelli A, Needleman I, Offenbacher S, Seymour GJ, Teles R, Tonetti MS. Periodontitis: Consensus report of workgroup 2 of the 2017 World Workshop on the Classification of Periodontal and Peri-Implant Diseases and Conditions. *J Periodontol* 2018; **89** Suppl 1: S173-S182 [PMID: [29926951](#) DOI: [10.1002/JPER.17-0721](#)]
- 15 **Du SQ**, Rinchuse DJ, Zullo TG. Reliability of three methods of occlusion classification. *Am J Orthod Dentofacial Orthop* 1998; **113**: 463-470 [PMID: [9563363](#) DOI: [10.1016/S0889-5406\(98\)80019-X](#)]
- 16 **Bartold PM**, Gronthos S, Ivanovski S, Fisher A, Huttmacher DW. Tissue engineered periodontal products. *J Periodontol Res* 2016; **51**: 1-15 [PMID: [25900048](#) DOI: [10.1111/jre.12275](#)]
- 17 **Ganesh PR**, Karthikeyan R, and Malathi K. Perio-Scopy: A New Paradigm in Periodontal Therapy. *International Journal of Dental and Medical Research* 2015; **1**: 168-171
- 18 **Sanz I**, Alonso B, Carasol M, Herrera D, Sanz M. Nonsurgical treatment of periodontitis. *J Evid Based Dent Pract* 2012; **12**: 76-86 [PMID: [23040340](#) DOI: [10.1016/S1532-3382\(12\)70019-2](#)]
- 19 **Aimetti M**. Nonsurgical periodontal treatment. *Int J Esthet Dent* 2014; **9**: 251-267 [PMID: [24765632](#)]
- 20 **de Barros FC**, Braga FF, Fischer RG, Figueredo CM. Effects of nonsurgical periodontal treatment on the alveolar bone density. *Braz Dent J* 2014; **25**: 90-95 [PMID: [25140711](#) DOI: [10.1590/0103-6440201302308](#)]
- 21 **Kloehn JS**, Pfeifer JS. The effect of orthodontic treatment on the periodontium. *Angle Orthod* 1974; **44**: 127-134 [PMID: [4524468](#) DOI: [10.1043/0003-3219\(1974\)044<0127:TEOOTO>2.0.CO;2](#)]
- 22 **Re S**, Corrente G, Abundo R, Cardaropoli D. Orthodontic treatment in periodontally compromised patients: 12-year report. *Int J Periodontics Restorative Dent* 2000; **20**: 31-39 [PMID: [11203546](#)]
- 23 **Maeda S**, Maeda Y, Ono Y, Nakamura K, Sasaki T. Interdisciplinary treatment of a patient with severe pathologic tooth migration caused by localized aggressive periodontitis. *Am J Orthod Dentofacial Orthop* 2005; **127**: 374-384 [PMID: [15775955](#) DOI: [10.1016/j.ajodo.2004.01.019](#)]
- 24 **Christensen L**, Luther F. Adults seeking orthodontic treatment: expectations, periodontal and TMD issues. *Br Dent J* 2015; **218**: 111-117 [PMID: [25686427](#) DOI: [10.1038/sj.bdj.2015.46](#)]
- 25 **Dindaroğlu F**, Doğan S. Root Resorption in Orthodontics. *Turk J Orthod* 2016; **29**: 103-108 [PMID: [30112483](#) DOI: [10.5152/TurkJOrthod.2016.16021](#)]
- 26 **Krishnan V**. Root Resorption with Orthodontic Mechanics: Pertinent Areas Revisited. *Aust Dent J* 2017; **62** Suppl 1: 71-77 [PMID: [28297086](#) DOI: [10.1111/adj.12483](#)]
- 27 **Corrente G**, Vergnano L, Re S, Cardaropoli D, Abundo R. Resin-bonded fixed partial dentures and splints in periodontally compromised patients: a 10-year follow-up. *Int J Periodontics Restorative Dent* 2000; **20**: 628-636 [PMID: [11203600](#)]
- 28 **Prathyusha P**, Jyoti S, Kaul RB, Sethi N. Maryland Bridge: An Interim Prosthesis for Tooth Replacement in Adolescents. *Int J Clin Pediatr Dent* 2011; **4**: 135-138 [PMID: [27672253](#) DOI: [10.5005/jp-journals-10005-1097](#)]



Published by **Baishideng Publishing Group Inc**
7041 Koll Center Parkway, Suite 160, Pleasanton, CA 94566, USA

Telephone: +1-925-3991568

E-mail: bpgoffice@wjgnet.com

Help Desk: <https://www.f6publishing.com/helpdesk>

<https://www.wjgnet.com>

