

World Journal of *Clinical Cases*

World J Clin Cases 2021 December 26; 9(36): 11122-11508



Contents

Thrice Monthly Volume 9 Number 36 December 26, 2021

REVIEW

- 11122** Diet and microbiome in the beginning of the sequence of gut inflammation
Ceballos D, Hernández-Camba A, Ramos L

MINIREVIEWS

- 11148** Stem cell therapy: A promising treatment for COVID-19
Zheng ZX

ORIGINAL ARTICLE

Case Control Study

- 11156** Association between serum Sestrin2 level and diabetic peripheral neuropathy in type 2 diabetic patients
Mao EW, Cheng XB, Li WC, Kan CX, Huang N, Wang HS, Hou NN, Sun XD
- 11165** Plasma brain natriuretic peptide, platelet parameters, and cardiopulmonary function in chronic obstructive pulmonary disease
Guo HJ, Jiang F, Chen C, Shi JY, Zhao YW

Retrospective Cohort Study

- 11173** Analysis of the incidence and influencing factors of hyponatremia before ¹³¹I treatment of differentiated thyroid carcinoma
Cao JJ, Yun CH, Xiao J, Liu Y, Wei W, Zhang W

Retrospective Study

- 11183** Cognitive magnetic resonance imaging-ultrasound fusion transperineal targeted biopsy combined with randomized biopsy in detection of prostate cancer
Pang C, Wang M, Hou HM, Liu JY, Zhang ZP, Wang X, Zhang YQ, Li CM, Zhang W, Wang JY, Liu M
- 11193** Nomogram based on inflammation-related markers for predicting survival of patients undergoing hepatectomy for hepatocellular carcinoma
Pu T, Li ZH, Jiang D, Chen JM, Guo Q, Cai M, Chen ZX, Xie K, Zhao YJ, Liu FB
- 11208** Association of frailty with in-hospital outcomes in elderly patients with heart failure
Kang YP, Chen LY, Zhu JJ, Liu WX, Ma CS
- 11220** COVID-19 pandemic and exacerbation of ulcerative colitis
Suda T, Takahashi M, Katayama Y, Tamano M
- 11228** Surgical perspectives of symptomatic omphalomesenteric duct remnants: Differences between infancy and beyond
Kang A, Kim SH, Cho YH, Kim HY

- 11237** Clustering cases of *Chlamydia psittaci* pneumonia mimicking COVID-19 pneumonia
Zhao W, He L, Xie XZ, Liao X, Tong DJ, Wu SJ, Liu J
- 11248** Sodium nitroprusside injection immediately before balloon inflation during percutaneous coronary intervention
Yu Y, Yang BP
- 11255** Machine learning approach to predict acute kidney injury after liver surgery
Dong JF, Xue Q, Chen T, Zhao YY, Fu H, Guo WY, Ji JS
- 11265** Application effect for a care bundle in optimizing nursing of patients with severe craniocerebral injury
Gao Y, Liao LP, Chen P, Wang K, Huang C, Chen Y, Mou SY

Clinical Trials Study

- 11276** Influence of pontic design of anterior fixed dental prosthesis on speech: A clinical case study
Wan J, Cai H, Wang T, Chen JY

Observational Study

- 11285** Real-world data on the infliximab biosimilar CT-P13 (Remsima®) in inflammatory bowel disease
Huguet JM, Cortés X, Bosca-Watts MM, Aguas M, Maroto N, Martí L, Amorós C, Paredes JM
- 11300** Correlation of periodontal inflamed surface area with glycemic status in controlled and uncontrolled type 2 diabetes mellitus
Anil K, Vadakkekuttikal RJ, Radhakrishnan C, Parambath FC
- 11311** Audiological characteristics and exploratory treatment of a rare condition of acute-otitis-media-associated sudden sensorineural hearing loss
Cao X, Yi HJ
- 11320** Yield of testing for micronutrient deficiencies associated with pancreatic exocrine insufficiency in a clinical setting: An observational study
Jalal M, Campbell JA, Tesfaye S, Al-Mukhtar A, Hopper AD

Prospective Study

- 11330** Birthing ball on promoting cervical ripening and its influence on the labor process and the neonatal blood gas index
Shen HC, Wang H, Sun B, Jiang LZ, Meng Q

CASE REPORT

- 11338** Mucormycosis – resurgence of a deadly opportunist during COVID-19 pandemic: Four case reports
Upadhyay S, Bharara T, Khandait M, Chawdhry A, Sharma BB
- 11346** Ductal breast carcinoma metastasized to the rectum: A case report and review of the literature
Ban B, Zhang K, Li JN, Liu TJ, Shi J

- 11355** De Garengeot hernia with avascular necrosis of the appendix: A case report
Yao MQ, Yi BH, Yang Y, Weng XQ, Fan JX, Jiang YP
- 11362** Mature mediastinal bronchogenic cyst with left pericardial defect: A case report
Zhu X, Zhang L, Tang Z, Xing FB, Gao X, Chen WB
- 11369** Difficulties in diagnosing anorectal melanoma: A case report and review of the literature
Apostu RC, Stefanescu E, Scurtu RR, Kacso G, Drasovean R
- 11382** Solid pseudopapillary neoplasm of the pancreas in a young male with main pancreatic duct dilatation: A case report
Nakashima S, Sato Y, Imamura T, Hattori D, Tamura T, Koyama R, Sato J, Kobayashi Y, Hashimoto M
- 11392** Acute myocardial infarction in a young man with ankylosing spondylitis: A case report
Wan ZH, Wang J, Zhao Q
- 11400** Acute appendicitis complicated by mesenteric vein thrombosis: A case report
Yang F, Guo XC, Rao XL, Sun L, Xu L
- 11406** Inguinal endometriosis: Ten case reports and review of literature
Li SH, Sun HZ, Li WH, Wang SZ
- 11419** Dramatic response to immunotherapy in an epidermal growth factor receptor-mutant non-small cell lung cancer: A case report
Li D, Cheng C, Song WP, Ni PZ, Zhang WZ, Wu X
- 11425** Three-dimensional inlay-guided endodontics applied in variant root canals: A case report and review of literature
Yan YQ, Wang HL, Liu Y, Zheng TJ, Tang YP, Liu R
- 11437** Ectopic pregnancy implanted under the diaphragm: A rare case report
Wu QL, Wang XM, Tang D
- 11443** Ear ischemia induced by endovascular therapy for arteriovenous fistula of the sigmoid sinus: A case report
Li W, Zhang SS, Gao XR, Li YX, Ge HJ
- 11448** Giant schwannoma of thoracic vertebra: A case report
Zhou Y, Liu CZ, Zhang SY, Wang HY, Varma SN, Cao LQ, Hou TT, Li X, Yao BJ
- 11457** Severe digital ischemia coexists with thrombocytopenia in malignancy-associated antiphospholipid syndrome: A case report and review of literature
Chen JL, Yu X, Luo R, Liu M
- 11467** Rare spontaneous extensive annular intramural esophageal dissection with endoscopic treatment: A case report
Hu JW, Zhao Q, Hu CY, Wu J, Lv XY, Jin XH

- 11475** Mucinous cystic neoplasm of the liver: A case report
Yu TY, Zhang JS, Chen K, Yu AJ
- 11482** Retroperitoneal parasitic fetus: A case report
Xia B, Li DD, Wei HX, Zhang XX, Li RM, Chen J
- 11487** De novo mutation loci and clinical analysis in a child with sodium taurocholate cotransport polypeptide deficiency: A case report
Liu HY, Li M, Li Q
- 11495** Surgery for hepatocellular carcinoma with tumor thrombosis in inferior vena cava: A case report
Zhang ZY, Zhang EL, Zhang BX, Zhang W

LETTER TO THE EDITOR

- 11504** Advantages and issues of concern regarding approaches to peripheral nerve block for total hip arthroplasty
Crisci M, Cuomo A, Forte CA, Bimonte S, Esposito G, Tracey MC, Cascella M

ABOUT COVER

Editorial Board Member of *World Journal of Clinical Cases*, Moises Rodriguez-Gonzalez, MD, Adjunct Professor, Senior Researcher, Department of Pediatric Cardiology, Hospital Universitario Puerta del Mar, Cadiz 11009, Spain. doctormoisesrodriguez@gmail.com

AIMS AND SCOPE

The primary aim of *World Journal of Clinical Cases* (WJCC, *World J Clin Cases*) is to provide scholars and readers from various fields of clinical medicine with a platform to publish high-quality clinical research articles and communicate their research findings online.

WJCC mainly publishes articles reporting research results and findings obtained in the field of clinical medicine and covering a wide range of topics, including case control studies, retrospective cohort studies, retrospective studies, clinical trials studies, observational studies, prospective studies, randomized controlled trials, randomized clinical trials, systematic reviews, meta-analysis, and case reports.

INDEXING/ABSTRACTING

The WJCC is now indexed in Science Citation Index Expanded (also known as SciSearch®), Journal Citation Reports/Science Edition, Scopus, PubMed, and PubMed Central. The 2021 Edition of Journal Citation Reports® cites the 2020 impact factor (IF) for WJCC as 1.337; IF without journal self cites: 1.301; 5-year IF: 1.742; Journal Citation Indicator: 0.33; Ranking: 119 among 169 journals in medicine, general and internal; and Quartile category: Q3. The WJCC's CiteScore for 2020 is 0.8 and Scopus CiteScore rank 2020: General Medicine is 493/793.

RESPONSIBLE EDITORS FOR THIS ISSUE

Production Editor: Ji-Hong Lin; Production Department Director: Xu Guo; Editorial Office Director: Jin-Lei Wang.

NAME OF JOURNAL

World Journal of Clinical Cases

ISSN

ISSN 2307-8960 (online)

LAUNCH DATE

April 16, 2013

FREQUENCY

Thrice Monthly

EDITORS-IN-CHIEF

Bao-Gan Peng

EDITORIAL BOARD MEMBERS

<https://www.wjnet.com/2307-8960/editorialboard.htm>

PUBLICATION DATE

December 26, 2021

COPYRIGHT

© 2021 Baishideng Publishing Group Inc

INSTRUCTIONS TO AUTHORS

<https://www.wjnet.com/bpg/gerinfo/204>

GUIDELINES FOR ETHICS DOCUMENTS

<https://www.wjnet.com/bpg/GerInfo/287>

GUIDELINES FOR NON-NATIVE SPEAKERS OF ENGLISH

<https://www.wjnet.com/bpg/gerinfo/240>

PUBLICATION ETHICS

<https://www.wjnet.com/bpg/GerInfo/288>

PUBLICATION MISCONDUCT

<https://www.wjnet.com/bpg/gerinfo/208>

ARTICLE PROCESSING CHARGE

<https://www.wjnet.com/bpg/gerinfo/242>

STEPS FOR SUBMITTING MANUSCRIPTS

<https://www.wjnet.com/bpg/GerInfo/239>

ONLINE SUBMISSION

<https://www.f6publishing.com>

Ear ischemia induced by endovascular therapy for arteriovenous fistula of the sigmoid sinus: A case report

Wei Li, Sui-Sui Zhang, Xiao-Ran Gao, You-Xiang Li, Hui-Jian Ge

ORCID number: Wei Li 0000-0001-5092-9334; Sui-Sui Zhang 0000-0003-4803-2602; Xiao-Ran Gao 0000-0003-3951-0086; You-Xiang Li 0000-0003-8982-814X; Hui-Jian Ge 0000-0001-8197-3709.

Author contributions: Li W and Ge HJ contributed equally to this work; Li W, Li YX, and Ge HJ designed the research study; Li W, Zhang SS, and Gao XR performed the research; Li W and Ge HJ contributed new reagents and analytic tools; Li W, Li YX, and Ge HJ analyzed the data and wrote the manuscript; all authors have read and approve the final manuscript.

Informed consent statement:

Informed written consent was obtained from the patient for publication of this case report and accompanying images.

Conflict-of-interest statement: The authors declare that they have no conflict of interest.

CARE Checklist (2016) statement:

The authors have read the CARE Checklist (2016), and the manuscript was prepared and revised according to the CARE Checklist (2016).

Country/Territory of origin: China

Specialty type: Neurosciences

Provenance and peer review:

Wei Li, You-Xiang Li, Hui-Jian Ge, Beijing Neurosurgical Institute, Capital Medical University, Beijing 100070, China

Wei Li, Sui-Sui Zhang, Xiao-Ran Gao, Department of Neurosurgery, The Second Affiliated Hospital of Xingtai Medical College, Xingtai 054000, Hebei Province, China

Corresponding author: Hui-Jian Ge, MD, Doctor, Beijing Neurosurgical Institute, Capital Medical University, No. 119 Nansihuan West Road, Fengtai District, Beijing 100070, China. yushengge@sina.com

Abstract

BACKGROUND

Arteriovenous fistula of the sigmoid sinus is an abnormal connection of arteries with the sigmoid sinus. Endovascular treatments of such lesions are considered safe and with low rates of complications.

CASE SUMMARY

A 62-year-old female patient underwent endovascular treatment of an arteriovenous fistula of the right sigmoid sinus on February 7, 2017, but her tinnitus was not cured. She was admitted to the Beijing Tiantan Hospital, Capital Medical University, on March 20, 2017, and her pre-operative diagnosis, by digital subtraction cerebral angiography, was arteriovenous fistula of the sigmoid sinus. She underwent endovascular embolization of the distal occipital artery and posterior auricular artery using Onyx-18. The arteriovenous fistula of the sigmoid sinus was cured, and her tinnitus disappeared, but ischemia of the upper 2/3 of the right auricle occurred without hearing loss. The patient received treatment to improve microcirculation, in addition to fluid supplementation, analgesia, and hyperbaric oxygen, and the swelling due to ischemia in the right auricle did not progress further. The patient reported no tinnitus, and the right auricle had returned to normal 3 years later.

CONCLUSION

Ischemic complications of vital organs should be considered when performing embolization procedures for arteriovenous fistulas of cerebral sinuses. Compensation of the organs should be evaluated before the operation, and the related treatment regimens should be planned.

Key Words: Arteriovenous fistula; Sigmoid sinus; Posterior auricular artery; Endovascular

Unsolicited article; Externally peer reviewed.

Peer-review model: Single blind

Peer-review report's scientific quality classification

Grade A (Excellent): 0
Grade B (Very good): 0
Grade C (Good): C
Grade D (Fair): 0
Grade E (Poor): 0

Open-Access: This article is an open-access article that was selected by an in-house editor and fully peer-reviewed by external reviewers. It is distributed in accordance with the Creative Commons Attribution NonCommercial (CC BY-NC 4.0) license, which permits others to distribute, remix, adapt, build upon this work non-commercially, and license their derivative works on different terms, provided the original work is properly cited and the use is non-commercial. See: <http://creativecommons.org/licenses/by-nc/4.0/>

Received: July 22, 2021

Peer-review started: July 22, 2021

First decision: September 1, 2021

Revised: September 9, 2021

Accepted: November 14, 2021

Article in press: November 14, 2021

Published online: December 26, 2021

P-Reviewer: Ferreira GSA

S-Editor: Yan JP

L-Editor: A

P-Editor: Yan JP



treatment; Tinnitus; Case report

©The Author(s) 2021. Published by Baishideng Publishing Group Inc. All rights reserved.

Core Tip: A 62-year-old female patient underwent endovascular treatment of an arteriovenous fistula of the right sigmoid sinus, but her tinnitus was not cured. She was admitted to the Beijing Tiantan Hospital, Capital Medical University, on March 20, 2017. She underwent endovascular embolization of the distal occipital artery and posterior auricular artery using Onyx-18. The arteriovenous fistula of the sigmoid sinus was cured, and her symptoms of tinnitus disappeared, but ischemia of the upper 2/3 auricle of the right auricle occurred without hearing loss. Ischemic complications of vital organs should be considered when performing embolization procedures for arteriovenous fistulas of cerebral sinuses.

Citation: Li W, Zhang SS, Gao XR, Li YX, Ge HJ. Ear ischemia induced by endovascular therapy for arteriovenous fistula of the sigmoid sinus: A case report. *World J Clin Cases* 2021; 9(36): 11443-11447

URL: <https://www.wjgnet.com/2307-8960/full/v9/i36/11443.htm>

DOI: <https://dx.doi.org/10.12998/wjcc.v9.i36.11443>

INTRODUCTION

Dural arteriovenous fistulas (DAVFs) refer to the abnormal connections of the internal carotid artery, external carotid artery (ECA), or vertebral artery branches with sinuses of the dura mater, leading to hemodynamic changes in the sinuses and a higher risk of intracerebral hemorrhage[1-4]. Endovascular therapy is an important method for the treatment for DAVFs. There are many vascular anastomoses in vital organs in the head and facial areas, such as eyes, ears, and nose, and endovascular therapy rarely induces ischemic changes in these organs[5-7]. Here we report a patient with auricle ischemia induced by the embolization of an arteriovenous fistula of the sigmoid sinus through the middle meningeal, occipital, and posterior auricular arteries.

CASE PRESENTATION

Chief complaints

A 62-year-old female patient was admitted to the Neurointerventional Department of Beijing Tiantan Hospital, Capital Medical University, on March 20, 2017, due to 41 d of tinnitus symptoms after a partial embolization of an arteriovenous fistula of the sigmoid sinus through the middle meningeal artery (MMA), without any sign of tinnitus improvement.

History of present illness

The patient reported pulsatile tinnitus in the right ear in June 2016, but without hearing loss.

History of past illness

The patient had no history of head trauma, intracranial infection, nasal sinus infection, or cerebral surgery. As her symptoms did not worsen from June 2016 to February 2017, the patient did not receive specific treatments.

Personal and family history

She did not report any personal and family history. The patient was admitted to the Zhuhai People's Hospital on February 7, 2017, due to pulsatile tinnitus in the right ear.

Physical examination

The patient reported pulsatile tinnitus in the right ear without any other abnormal physical examination.

Laboratory examinations

Her laboratory examinations were normal.

Imaging examinations

Digital subtraction cerebral angiography (Siemens, Erlangen, Germany) was performed, showing blood flow in the right MMA, right occipital artery (OA), and right posterior auricular artery (PAA) to the right sigmoid sinus, which was classified as Cognard Type-I (Figure 1A). Partial embolization of the arteriovenous fistula of the sigmoid sinus was performed through the MMA at the hospital, but her tinnitus symptoms did not improve after the operation.

Following admission to Beijing Tiantan Hospital, the pre-operative diagnosis, by digital subtraction cerebral angiography, was arteriovenous fistula of the sigmoid sinus. No other treatments were performed before the operation. On March 23, 2017, the patient underwent embolization of the arteriovenous fistula of the sigmoid sinus under general anesthesia. A Marathon micro-catheter (EV3, Plymouth, MN, United States) was inserted into the distal OA to a site close to the fistula, 0.25 mL of dimethyl sulfoxide (DMSO) was injected, and then 0.25 mL of Onyx-18 was injected (Figure 1B). Angiography showed no blood flow from the OA to the sigmoid sinus, but blood flow from the PPA to the sigmoid sinus. A Marathon micro-catheter (EV3, Plymouth, MN, United States) was inserted into the distal PAA to a site close to the fistula, 0.25 mL of DMSO (EV3, Plymouth, MN, United States) was injected, and then 0.25 mL of Onyx-18 was injected (Figure 1C). Angiography showed that the arteriovenous fistula had disappeared after these procedures (Figure 1D). When the patient woke up from anesthesia, her tinnitus symptoms had disappeared. However, she reported pain in the right auricle about 40 min later. Cyanosis and swelling of the upper 2/3 of the right auricle were observed 2 h later, and skin swelling at the occipital area posterior to the ear was also noted (Figure 1E). Hearing in the right ear did not decrease. The patient received treatment to improve microcirculation, in addition to fluid supplementation, analgesia, and hyperbaric oxygen. Swelling of the ischemic right auricle did not progress further. A re-examination using digital subtraction cerebral angiography 3 mo later showed no recurrence of the arteriovenous fistula (Figure 1F), and the cyanosis and swelling in the right auricle had improved. Telephone follow-up 3 years later revealed that the patient had no tinnitus symptoms, and the right auricle had returned to normal.

FINAL DIAGNOSIS

The final diagnosis of the presented case was arteriovenous fistula of the sigmoid sinus.

TREATMENT

The patient underwent endovascular embolization of the distal OA and PAA using Onyx-18 and received treatment to improve microcirculation, in addition to fluid supplementation, analgesia, and hyperbaric oxygen.

OUTCOME AND FOLLOW-UP

The patient reported no tinnitus symptoms, and the right auricle had returned to normal 3 years later.

DISCUSSION

In the case reported here, tinnitus due to DAVF was effectively managed by embolizing the arteries feeding the DAVF. However, the initial treatment at a local hospital was insufficient as since only one artery was occluded. Embolization of the two other arteries finally resolved the tinnitus, but the patient developed auricle ischemia that required 15 d of management before resolution.

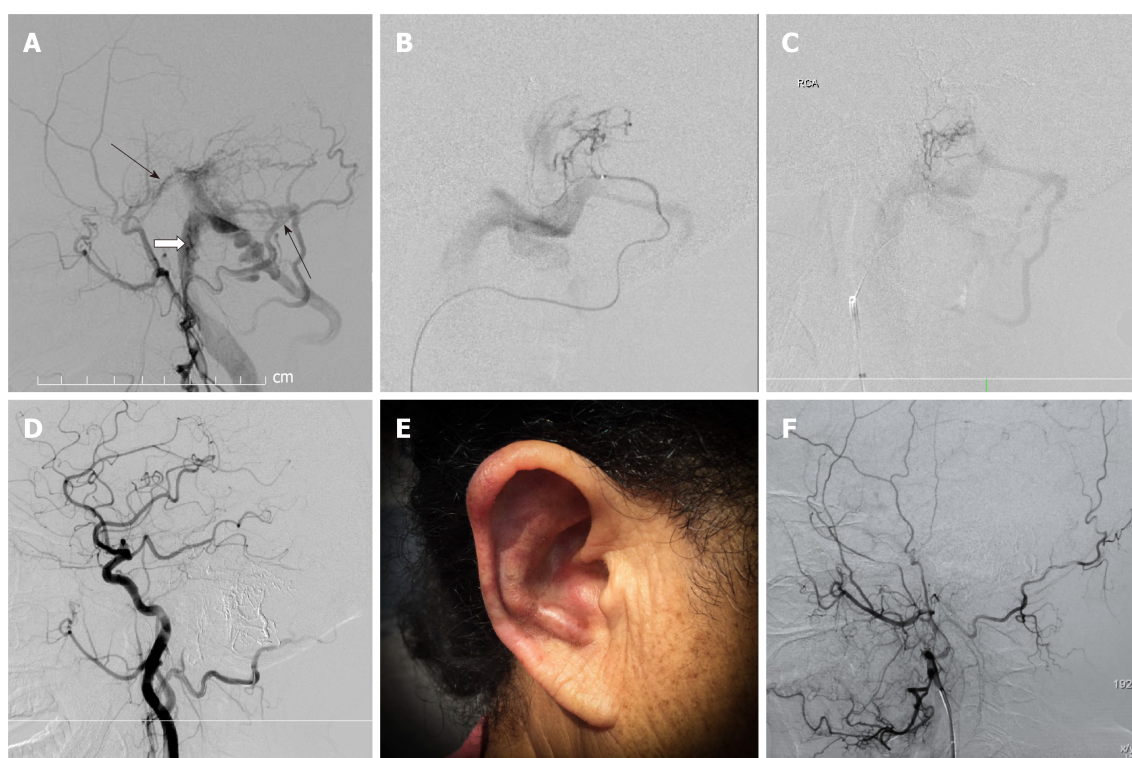


Figure 1 The diagnosis, surgical procedures and postoperative recovery of the patient. A: Angiography of the right external carotid artery showed the arteriovenous fistula of the sigmoid sinus. The blood supply was from the right occipital artery (short black arrow), right middle meningeal artery (long black arrow), and right posterior auricular artery (white arrow); B: Trans-occipital artery distal microangiography showed the blood flow from the occipital artery branches to the sigmoid sinus; C: Trans-posterior auricular artery microangiography showed blood flow from the posterior auricular artery branches to the sigmoid sinus; D: Angiography after the injection of Onyx-18 through the posterior auricular artery and occipital artery did not show the sigmoid sinus, and the arteriovenous fistula was cured; E: Cyanosis and swelling of the middle and upper 2/3 of the right auricle were found 2 d after operation; F: Angiography of the right external carotid artery at 3 mo after operation showed the arteriovenous fistula disappeared.

DAVF is a condition caused by the abnormal connection of arteries and veins of the dura mater, mainly at the transverse sinus, sigmoid sinus, and cavernous sinus[8]. The blood supply of a DAVF is mainly from the MMA and meningeal branches of the OA. In addition, the posterior meningeal artery (PMA) and meningo-hypophyseal trunk of the internal carotid artery can also participate in the blood supply in rare cases[9-11]. The PAA, a small branch of the ECA is the major blood supply to the auricle[12]. The PAA originates from an ECA branch above the OA, travels to the space between the parotid gland and zygomatic process, and then through the groove between the mastoid process and auricular cartilage[13]. Participation of the PAA in a DAVF is relatively rare but is reported to cause tinnitus[14,15], as in the present case. Although embolization therapy was performed for the MMA and OA, the disease was not cured. Therefore, no other options but the embolization of the PAA was available for this patient.

The arteriovenous fistula disappeared after embolization of the PAA. However, the PAA is responsible for the ear's blood supply, and the blood flow in the auricle is from the PAA and the auricle branch of the superficial temporal artery (STA). The STA is a thick artery but has only limited, fine branches for the auricle's blood supply and mainly provides blood to the upper and lower part and 1/2 of the internal side of the middle part of the anterior auricle. On the other hand, the PAA is finer than the STA and has more and thicker auricle branches that mainly distribute blood to the posterior auricle, the auricle's external margin, and 1/2 of the middle-external part of the anterior auricle. Hence, the PAA is the major blood supply of the posterior auricle, auricular lobule, and 1/2 of the middle-external part of the anterior auricle. There is generally one perforating branch which originates from the lower branch of the PAA that travels through the cartilage of the posterior margin of the external auditory canal to the anterior auricle, and 1-2 marginal branches cross the external margin of the auricle to the anterior auricle, which then comprehensively anastomose with the middle and lower branches of the STA[8]. As there are limited anastomoses at the middle and upper parts of the auricle, over-embolization of the PAA could lead to auricle ischemia symptoms, which has not been previously reported to date. The

symptoms in this patient disappeared after treatments. Nevertheless, evaluating the compensations and performing corresponding preventive plans are needed during the embolization of arteries providing blood flow to vital organs in order to prevent serious complications.

CONCLUSION

We reported a case of DAVF of the sigmoid sinus treated with Onyx-18 embolization of the MMA, OA, and PPA; however, the patient developed auricle ischemia after treatment. When treating DAVF, complications, including occlusion of normal blood vessels, nerve injuries, and intracranial bleeding, should be managed properly. Regarding the blood supply of vital facial organs, especially when the organ's collateral circulation is insufficient, the possible ischemic complications after embolization need to be evaluated thoroughly.

REFERENCES

- 1 **Nishijima M**, Kuwayama N, Endo S, Takaku A. Clinico-pathological study in patients with transverse-sigmoid sinus dural arteriovenous malformations. *J Clin Neurosci* 1998; **5** Suppl: 42-44 [PMID: 18639099 DOI: 10.1016/s0967-5868(98)90010-8]
- 2 **Men S**, Idiman F, Gulcu A. Reversible cytotoxic edema associated with dural arteriovenous fistula: a case report. *Eur J Radiol* 2004; **52**: 1-5 [DOI: 10.1016/j.ejrex.2004.07.002]
- 3 **Caragine LP**, Halbach VV, Dowd CF, Ng PP, Higashida RT. Parallel venous channel as the recipient pouch in transverse/sigmoid sinus dural fistulae. *Neurosurgery* 2003; **53**: 1261-6; discussion 1266 [PMID: 14633292 DOI: 10.1227/01.neu.0000093494.54083.29]
- 4 **Irie F**, Fujimoto S, Uda K, Toyoda K, Hagiwara N, Inoue T, Okada Y. Primary intraventricular hemorrhage from dural arteriovenous fistula. *J Neurol Sci* 2003; **215**: 115-118 [PMID: 14568138 DOI: 10.1016/s0022-510x(03)00176-x]
- 5 **Ertl L**, Brückmann H, Kunz M, Crispin A, Fesl G. Endovascular therapy of low- and intermediate-grade intracranial lateral dural arteriovenous fistulas: a detailed analysis of primary success rates, complication rates, and long-term follow-up of different technical approaches. *J Neurosurg* 2017; **126**: 360-367 [PMID: 27128596 DOI: 10.3171/2016.2.JNS152081]
- 6 **Maus V**, Drescher F, Goertz L, Weber A, Weber W, Fischer S. Endovascular Treatment of Intracranial Dural Arteriovenous Fistulas: A German Single-Center Experience. *Cerebrovasc Dis Extra* 2020; **10**: 84-93 [PMID: 32846415 DOI: 10.1159/000509455]
- 7 **Mohr JP**, Keida-Scharler J, Pile-Spellman J. Diagnosis and treatment of arteriovenous malformations. *Curr Neurol Neurosci Rep* 2013; **13**: 324 [PMID: 23307509 DOI: 10.1007/s11910-012-0324-1]
- 8 **Xu K**, Yang X, Li C, Yu J. Current status of endovascular treatment for dural arteriovenous fistula of the transverse-sigmoid sinus: A literature review. *Int J Med Sci* 2018; **15**: 1600-1610 [PMID: 30588182 DOI: 10.7150/ijms.27683]
- 9 **Guo Y**, Chen H, Chen X, Yu J. Clinical importance of the occipital artery in vascular lesions: A review of the literature. *Neuroradiol J* 2019; **32**: 366-375 [PMID: 31188082 DOI: 10.1177/1971400919857245]
- 10 **Wang G**, Yu J, Hou K, Guo Y. Clinical importance of the posterior meningeal artery: a review of the literature. *Neuroradiol J* 2019; **32**: 158-165 [PMID: 30924401 DOI: 10.1177/1971400919840843]
- 11 **Yu J**, Guo Y, Xu B, Xu K. Clinical importance of the middle meningeal artery: A review of the literature. *Int J Med Sci* 2016; **13**: 790-799 [PMID: 27766029 DOI: 10.7150/ijms.16489]
- 12 **Imanishi N**, Nakajima H, Aiso S. Arterial anatomy of the ear. *Okajimas Folia Anat Jpn* 1997; **73**: 313-323 [PMID: 9128063 DOI: 10.2535/ofaj1936.73.6_313]
- 13 **Standring S**. Gray's Anatomy E-Book: The Anatomical Basis of Clinical Practice. London: Elsevier Health Sciences, 2015: 1519
- 14 **Kim S**, Byun J, Park M, Lee S. Pulsatile tinnitus with a dural arterio-venous fistula diagnosed by computed tomography-angiography. *Korean J Audiol* 2013; **17**: 133-137 [PMID: 24653921 DOI: 10.7874/kja.2013.17.3.133]
- 15 **Oh SJ**, Chon YI, Kong SK, Goh EK. Multiple Dural Arteriovenous Fistulas Presenting as Pulsatile Tinnitus Treated with External Manual Compression. *J Audiol Otol* 2017; **21**: 156-159 [PMID: 28942629 DOI: 10.7874/jao.2017.00115]



Published by **Baishideng Publishing Group Inc**
7041 Koll Center Parkway, Suite 160, Pleasanton, CA 94566, USA

Telephone: +1-925-3991568

E-mail: bpgoffice@wjgnet.com

Help Desk: <https://www.f6publishing.com/helpdesk>

<https://www.wjgnet.com>

