

World Journal of *Clinical Cases*

World J Clin Cases 2022 June 6; 10(16): 5124-5517



Contents

Thrice Monthly Volume 10 Number 16 June 6, 2022

OPINION REVIEW

- 5124 Malignant insulinoma: Can we predict the long-term outcomes?
Cigrovski Berkovic M, Ulamec M, Marinovic S, Balen I, Mrzljak A

MINIREVIEWS

- 5133 Practical points that gastrointestinal fellows should know in management of COVID-19
Sahin T, Simsek C, Balaban HY
- 5146 Nanotechnology in diagnosis and therapy of gastrointestinal cancer
Liang M, Li LD, Li L, Li S
- 5156 Advances in the clinical application of oxycodone in the perioperative period
Chen HY, Wang ZN, Zhang WY, Zhu T

ORIGINAL ARTICLE

Clinical and Translational Research

- 5165 Circulating miR-627-5p and miR-199a-5p are promising diagnostic biomarkers of colorectal neoplasia
Zhao DY, Zhou L, Yin TF, Zhou YC, Zhou GYJ, Wang QQ, Yao SK

Retrospective Cohort Study

- 5185 Management and outcome of bronchial trauma due to blunt *versus* penetrating injuries
Gao JM, Li H, Du DY, Yang J, Kong LW, Wang JB, He P, Wei GB

Retrospective Study

- 5196 Ovarian teratoma related anti-N-methyl-D-aspartate receptor encephalitis: A case series and review of the literature
Li SJ, Yu MH, Cheng J, Bai WX, Di W
- 5208 Endoscopic surgery for intraventricular hemorrhage: A comparative study and single center surgical experience
Wang FB, Yuan XW, Li JX, Zhang M, Xiang ZH
- 5217 Protective effects of female reproductive factors on gastric signet-ring cell carcinoma
Li Y, Zhong YX, Xu Q, Tian YT
- 5230 Risk factors of mortality and severe disability in the patients with cerebrovascular diseases treated with perioperative mechanical ventilation
Zhang JZ, Chen H, Wang X, Xu K

- 5241** Awareness of initiative practice for health in the Chinese population: A questionnaire survey based on a network platform

Zhang YQ, Zhou MY, Jiang MY, Zhang XY, Wang X, Wang BG

- 5253** Effectiveness and safety of chemotherapy for patients with malignant gastrointestinal obstruction: A Japanese population-based cohort study

Fujisawa G, Niikura R, Kawahara T, Honda T, Hasatani K, Yoshida N, Nishida T, Sumiyoshi T, Kiyotoki S, Ikeya T, Arai M, Hayakawa Y, Kawai T, Fujishiro M

Observational Study

- 5266** Long-term outcomes of high-risk percutaneous coronary interventions under extracorporeal membrane oxygenation support: An observational study

Huang YX, Xu ZM, Zhao L, Cao Y, Chen Y, Qiu YG, Liu YM, Zhang PY, He JC, Li TC

- 5275** Health care worker occupational experiences during the COVID-19 outbreak: A cross-sectional study

Li XF, Zhou XL, Zhao SX, Li YM, Pan SQ

Prospective Study

- 5287** Enhanced recovery after surgery strategy to shorten perioperative fasting in children undergoing non-gastrointestinal surgery: A prospective study

Ying Y, Xu HZ, Han ML

- 5297** Orthodontic treatment combined with 3D printing guide plate implant restoration for edentulism and its influence on mastication and phonic function

Yan LB, Zhou YC, Wang Y, Li LX

Randomized Controlled Trial

- 5306** Effectiveness of psychosocial intervention for internalizing behavior problems among children of parents with alcohol dependence: Randomized controlled trial

Omkarappa DB, Rentala S, Nattala P

CASE REPORT

- 5317** Crouzon syndrome in a fraternal twin: A case report and review of the literature

Li XJ, Su JM, Ye XW

- 5324** Laparoscopic duodenojejunostomy for malignant stenosis as a part of multimodal therapy: A case report

Murakami T, Matsui Y

- 5331** Chordoma of petrosal mastoid region: A case report

Hua JJ, Ying ML, Chen ZW, Huang C, Zheng CS, Wang YJ

- 5337** Pneumatosis intestinalis after systemic chemotherapy for colorectal cancer: A case report

Liu H, Hsieh CT, Sun JM

- 5343** Mammary-type myofibroblastoma with infarction and atypical mitosis-a potential diagnostic pitfall: A case report

Zeng YF, Dai YZ, Chen M

- 5352** Comprehensive treatment for primary right renal diffuse large B-cell lymphoma with a renal vein tumor thrombus: A case report
He J, Mu Y, Che BW, Liu M, Zhang WJ, Xu SH, Tang KF
- 5359** Ectopic peritoneal paragonimiasis mimicking tuberculous peritonitis: A care report
Choi JW, Lee CM, Kim SJ, Hah SI, Kwak JY, Cho HC, Ha CY, Jung WT, Lee OJ
- 5365** Neonatal hemorrhage stroke and severe coagulopathy in a late preterm infant after receiving umbilical cord milking: A case report
Lu Y, Zhang ZQ
- 5373** Heel pain caused by os subcalcis: A case report
Saijilafu, Li SY, Yu X, Li ZQ, Yang G, Lv JH, Chen GX, Xu RJ
- 5380** Pulmonary lymphomatoid granulomatosis in a 4-year-old girl: A case report
Yao JW, Qiu L, Liang P, Liu HM, Chen LN
- 5387** Idiopathic membranous nephropathy in children: A case report
Cui KH, Zhang H, Tao YH
- 5394** Successful treatment of aortic dissection with pulmonary embolism: A case report
Chen XG, Shi SY, Ye YY, Wang H, Yao WF, Hu L
- 5400** Renal papillary necrosis with urinary tract obstruction: A case report
Pan HH, Luo YJ, Zhu QG, Ye LF
- 5406** Glomangiomas - immunohistochemical study: A case report
Wu RC, Gao YH, Sun WW, Zhang XY, Zhang SP
- 5414** Successful living donor liver transplantation with a graft-to-recipient weight ratio of 0.41 without portal flow modulation: A case report
Kim SH
- 5420** Treatment of gastric hepatoid adenocarcinoma with pembrolizumab and bevacizumab combination chemotherapy: A case report
Liu M, Luo C, Xie ZZ, Li X
- 5428** Ipsilateral synchronous papillary and clear renal cell carcinoma: A case report and review of literature
Yin J, Zheng M
- 5435** Laparoscopic radical resection for situs inversus totalis with colonic splenic flexure carcinoma: A case report
Zheng ZL, Zhang SR, Sun H, Tang MC, Shang JK
- 5441** PIGN mutation multiple congenital anomalies-hypotonia-seizures syndrome 1: A case report
Hou F, Shan S, Jin H

- 5446** Pediatric acute myeloid leukemia patients with i(17)(q10) mimicking acute promyelocytic leukemia: Two case reports
Yan HX, Zhang WH, Wen JQ, Liu YH, Zhang BJ, Ji AD
- 5456** Fatal left atrial air embolism as a complication of percutaneous transthoracic lung biopsy: A case report
Li YW, Chen C, Xu Y, Weng QP, Qian SX
- 5463** Diagnostic value of bone marrow cell morphology in visceral leishmaniasis-associated hemophagocytic syndrome: Two case reports
Shi SL, Zhao H, Zhou BJ, Ma MB, Li XJ, Xu J, Jiang HC
- 5470** Rare case of hepatocellular carcinoma metastasis to urinary bladder: A case report
Kim Y, Kim YS, Yoo JJ, Kim SG, Chin S, Moon A
- 5479** Osteotomy combined with the trephine technique for invisible implant fracture: A case report
Chen LW, Wang M, Xia HB, Chen D
- 5487** Clinical diagnosis, treatment, and medical identification of specific pulmonary infection in naval pilots: Four case reports
Zeng J, Zhao GL, Yi JC, Liu DD, Jiang YQ, Lu X, Liu YB, Xue F, Dong J
- 5495** Congenital tuberculosis with tuberculous meningitis and situs inversus totalis: A case report
Lin H, Teng S, Wang Z, Liu QY
- 5502** Mixed large and small cell neuroendocrine carcinoma of the stomach: A case report and review of literature
Li ZF, Lu HZ, Chen YT, Bai XF, Wang TB, Fei H, Zhao DB

LETTER TO THE EDITOR

- 5510** Pleural involvement in cryptococcal infection
Georgakopoulou VE, Damaskos C, Sklapani P, Trakas N, Gkoufa A
- 5515** Electroconvulsive therapy plays an irreplaceable role in treatment of major depressive disorder
Ma ML, He LP

ABOUT COVER

Editorial Board Member of *World Journal of Clinical Cases*, Shivanshu Misra, MBBS, MCh, MS, Assistant Professor, Surgeon, Department of Minimal Access and Bariatric Surgery, Shivani Hospital and IVF, Kanpur 208005, Uttar Pradesh, India. shivanshu_medico@rediffmail.com

AIMS AND SCOPE

The primary aim of *World Journal of Clinical Cases* (WJCC, *World J Clin Cases*) is to provide scholars and readers from various fields of clinical medicine with a platform to publish high-quality clinical research articles and communicate their research findings online.

WJCC mainly publishes articles reporting research results and findings obtained in the field of clinical medicine and covering a wide range of topics, including case control studies, retrospective cohort studies, retrospective studies, clinical trials studies, observational studies, prospective studies, randomized controlled trials, randomized clinical trials, systematic reviews, meta-analysis, and case reports.

INDEXING/ABSTRACTING

The WJCC is now indexed in Science Citation Index Expanded (also known as SciSearch®), Journal Citation Reports/Science Edition, Scopus, PubMed, and PubMed Central. The 2021 Edition of Journal Citation Reports® cites the 2020 impact factor (IF) for WJCC as 1.337; IF without journal self cites: 1.301; 5-year IF: 1.742; Journal Citation Indicator: 0.33; Ranking: 119 among 169 journals in medicine, general and internal; and Quartile category: Q3. The WJCC's CiteScore for 2020 is 0.8 and Scopus CiteScore rank 2020: General Medicine is 493/793.

RESPONSIBLE EDITORS FOR THIS ISSUE

Production Editor: Xu Guo; Production Department Director: Xiang Li; Editorial Office Director: Jin-Lei Wang.

NAME OF JOURNAL

World Journal of Clinical Cases

ISSN

ISSN 2307-8960 (online)

LAUNCH DATE

April 16, 2013

FREQUENCY

Thrice Monthly

EDITORS-IN-CHIEF

Bao-Gan Peng, Jerzy Tadeusz Chudek, George Kontogeorgos, Maurizio Serati, Ja Hyeon Ku

EDITORIAL BOARD MEMBERS

<https://www.wjgnet.com/2307-8960/editorialboard.htm>

PUBLICATION DATE

June 6, 2022

COPYRIGHT

© 2022 Baishideng Publishing Group Inc

INSTRUCTIONS TO AUTHORS

<https://www.wjgnet.com/bpg/gerinfo/204>

GUIDELINES FOR ETHICS DOCUMENTS

<https://www.wjgnet.com/bpg/GerInfo/287>

GUIDELINES FOR NON-NATIVE SPEAKERS OF ENGLISH

<https://www.wjgnet.com/bpg/gerinfo/240>

PUBLICATION ETHICS

<https://www.wjgnet.com/bpg/GerInfo/288>

PUBLICATION MISCONDUCT

<https://www.wjgnet.com/bpg/gerinfo/208>

ARTICLE PROCESSING CHARGE

<https://www.wjgnet.com/bpg/gerinfo/242>

STEPS FOR SUBMITTING MANUSCRIPTS

<https://www.wjgnet.com/bpg/GerInfo/239>

ONLINE SUBMISSION

<https://www.f6publishing.com>



Retrospective Study

Endoscopic surgery for intraventricular hemorrhage: A comparative study and single center surgical experience

Feng-Bo Wang, Xiao-Wa Yuan, Jin-Xiao Li, Ming Zhang, Zhao-Hui Xiang

Specialty type: Surgery

Provenance and peer review:

Unsolicited article; Externally peer reviewed.

Peer-review model: Single blind

Peer-review report's scientific quality classification

Grade A (Excellent): 0
Grade B (Very good): B, B
Grade C (Good): 0
Grade D (Fair): 0
Grade E (Poor): 0

P-Reviewer: Anandan H, India;
Chiu KW, Taiwan

Received: August 8, 2021

Peer-review started: August 8, 2021

First decision: January 10, 2022

Revised: January 19, 2022

Accepted: April 2, 2022

Article in press: April 2, 2022

Published online: June 6, 2022



Feng-Bo Wang, Xiao-Wa Yuan, Jin-Xiao Li, Ming Zhang, Zhao-Hui Xiang, Department of Neurosurgery, Xinyi People's Hospital, Xinyi 221400, Jiangsu Province, China

Corresponding author: Zhao-Hui Xiang, BSc, Neurosurgeon, Department of Neurosurgery, Xinyi People's Hospital, No. 16 Renmin Road, Xinyi 221400, Jiangsu Province, China.
xiangzhaohui40752@163.com

Abstract

BACKGROUND

Intraventricular hemorrhage is a neurosurgical emergency, and a dangerous condition associated with high morbidity and mortality. Previously, hematoma evacuation is generally executed by external intracranial drainage (EVD) or surgical evacuation. Nowadays, endoscopic evacuation is emerging as a good alternative because it brings relatively less invasion and injury. However, successful endoscopic evacuation requires skilled manipulation of endoscopic devices and the evidence supporting its efficacy differs in different reports.

AIM

To improve the technique usage and provide more evidence of endoscopic evacuation efficacy, we summarize our surgical experience and compared the outcomes of the endoscopic evacuation with EVD using real-world data.

METHODS

We retrospectively studied 96 consecutive patients with intraventricular hemorrhage who underwent either endoscopic surgery ($n = 43$) or non-endoscopic surgery ($n = 53$) for hemorrhage evacuation between November 2013 and September 2019 in our center. Patients' conditions prior to and after the operation were evaluated and analyzed to assess the efficacy of the operation. The consciousness status improvement and perioperative in-hospital parameters in the two types of operation groups were assessed and compared.

RESULTS

Patients in the endoscopic and non-endoscopic groups presented with a similar state of consciousness, with a comparable Glasgow Coma Scale (GCS) index. The average operation time of the endoscopic group was longer than that of the non-endoscopic group (median 2.42 h vs 1.08 h, $P < 0.001$). Although the endoscopic group was older and had a baseline Graeb score that indicated more severe hemorrhage than the non-endoscopic group (Graeb median: Endoscopic group =

9 *vs* non-endoscopic group = 8, $P = 0.023$), the clearance rate of hematoma was as high as 60.5%. Both the endoscopic and non-endoscopic groups showed an improved GCS index after surgery. However, this improvement was more marked in patients in the endoscopic group (median improvement of GCS index: Endoscope group = 4 *vs* non-endoscopic group = 1, $P < 0.001$). Additionally, the endoscopic group had a lower Graeb score than the non-endoscopic group after the operation. The intensive care unit stay of the endoscopic group was significantly shorter than that of the non-endoscopic group (median: endoscopic group = 6 d *vs* non-endoscope group = 7 d, $P = 0.017$).

CONCLUSION

Endoscopic evacuation of intraventricular hemorrhage was generally an effective and efficient way for hemorrhage evacuation, and contributed remarkably to the improvement of consciousness in patients with intraventricular hemorrhage.

Key Words: Ventriculoscope; Intraventricular hemorrhage; Minimal invasion; Ventricular irrigation fluid; Endoscopic evacuation; Efficacy

©The Author(s) 2022. Published by Baishideng Publishing Group Inc. All rights reserved.

Core Tip: Endoscopic evacuation is a minimally invasive technique used to treat intraventricular hemorrhage. However, skilled manipulation is required when applying the technique, the evidence supporting its efficacy differs in different reports. Here, we present our experience in patients with intraventricular hemorrhage who underwent endoscopic intraventricular hematoma evacuation, and compared the efficacy of the technique with traditional external ventricular drainage using real-world data. The results indicate that endoscope evacuation was effective and efficient for treating intraventricular hemorrhage, and led to a higher rate of hemorrhage evacuation and a more remarkable recovery in consciousness than patients who underwent non-endoscopic surgery.

Citation: Wang FB, Yuan XW, Li JX, Zhang M, Xiang ZH. Endoscopic surgery for intraventricular hemorrhage: A comparative study and single center surgical experience. *World J Clin Cases* 2022; 10(16): 5208-5216

URL: <https://www.wjgnet.com/2307-8960/full/v10/i16/5208.htm>

DOI: <https://dx.doi.org/10.12998/wjcc.v10.i16.5208>

INTRODUCTION

Intraventricular hemorrhage (IVH) is a neurosurgical emergency, and a dangerous condition associated with high morbidity and mortality[1]. IVH in adults generally results from aneurysm rupture, trauma, vascular malformation and tumor (primary causes), or entrance of intracranial hemorrhage into the ventricle system (secondary cause)[2]. In such cases, it is essential to evacuate the hematoma and normalize intracranial pressure. Hematoma evacuation is generally executed by external intracranial drainage or surgical evacuation, but endoscopic evacuation is emerging as a good alternative[3].

Endoscopic evacuation is a minimally invasive technique for IVH treatment, and has been reported to efficiently improve surgery outcomes[4]. However, successful endoscopic evacuation requires skilled manipulation of endoscopic devices. Here, we present in detail our experience in 43 patients with IVH who underwent endoscopic intraventricular hematoma evacuation and catheter drainage of residual hematoma. Surgery outcomes were generally satisfactory, and we believe that our experience of IVH surgery may constructively improve the clinical practice of endoscopic evacuation.

MATERIALS AND METHODS

Study population

We retrospectively enrolled patients diagnosed with IVH and underwent endoscopic surgery or external ventricular drainage (EVD) surgery between November 2013 and September 2019 in Xinyi People's hospital (Jiangsu province). The inclusion criteria were as follows: (1) 15–80 years of age; (2) with clinical signs of moderate to severe IVH; (3) Head computed tomography (CT) images showed the existence of hemorrhage breaking into the third and fourth ventricles or primary IVH; and (4) A Glasgow Coma Scale (GCS) score < 10. Patients over 80 years old, with any anticoagulation/anti-

aggregation-related bleeding, a serious disease in other major organs or systems, or who rejected the surgery treatment were excluded. Generally, the treatment choice was made based on integrating surgeons' experience, CT appearance, and the patient's clinical conditions and financial situation. Finally, a total of 96 patients were studied; of these, 43 received endoscopic surgery and 53 underwent EVD surgery. The conscious states of all patients were assessed using the GCS[5] upon admission. The Graeb score was used to assess the severity of hemorrhage[6]. The Graeb score components are as follows: Each lateral ventricle, 1 = trace of blood, 2 = less than 50% filled, 3 = more than 50% filled, 4 = completely filled and expanded (each lateral ventricle was assessed individually); third and fourth ventricles, 0 = no blood, 1 = blood present and size normal, 2 = filled with blood and expanded. The total score was 12.

Ventriculoscopic system

A KARL STORZ high-resolution ventriculoscopic system was used. The 6° 28164 LA LOTTA ventriculoscope was 6.1 mm in outside diameter and 18 cm in length, with a 2.9 mm working channel and two 1.6 mm irrigation/suction channels (Figure 1A). The working sheath was 6.8 mm for the outside diameter and 13.3 cm long. A holding arm was used to hold and stabilize the ventriculoscope.

Surgical technique

All procedures were performed while patients were under general anesthesia in the supine position. The procedures began from the side with the least hemorrhage. At 3 cm posterior to the hairline and 2.5 cm lateral to the midline, a 3 cm scalp incision parallel to the midline was made. A 1.2 cm burr hole was made at the midpoint of the incision. After hemostasis, a cross-shape incision of the dura mater was made. Then, a drainage catheter (O.D. 4 mm) was inserted perpendicularly to the surface of the brain into the lateral ventricle. Generally, bloody cerebrospinal fluid flowed out when the catheter reached a depth of 5 cm-6 cm inside the brain. Then, the catheter was removed, and the working sheath (with an obturator) was placed carefully through the trajectory of the catheter. After reaching the lateral ventricle, the sheath was advanced 0.5 cm deeper. Then, the obturator was removed and the ventriculoscope was placed into the lateral ventricle frontal horn through the working sheath.

Normal saline (23 °C-25 °C) was continuously infused through one of the irrigation/suction channels and drained from the other one to irrigate the lateral ventricle. Visible hematomas were aspirated through the irrigation/suction channel or the working channel, and removal of hematomas in the third ventricle was conducted if necessary. When blood clots could not be removed by aspiration, or an important ventricular structure was suspected to be beneath the clots, forceps were advanced through the working channel to pull out the clot (Figure 1B). A bipolar coagulation electrode was used to stop active hemorrhages. Finally, the ventriculoscope and the working sheath were slowly removed while avoiding injuring brain tissue along the trajectory. A ventricular drainage catheter was inserted before closing the scalp incision. The same procedure was repeated on the other side. A head CT scan was conducted immediately after the surgery (Figure 1C). If there was residual hematoma in the fourth ventricle, ventricular irrigation was performed by pumping 40000 IU urokinase and 100 mL normal saline through the drainage catheter at 4.3 mL/h. Patients were followed up to monitor the occurrence of complications, including hydrocephalus.

Statistical analysis

Continuous variables with normally distributed data are presented as the mean \pm SD, and were compared using *t*-tests. Non-normally distributed data are presented as the median and interquartile range (IQR), and were compared using the nonparametric Kruskal-Wallis test. Categorical variables are expressed as absolute numbers with percentages, and were compared using Chi-square tests. A two-tailed *P* < 0.05 was considered as statistically significant. All statistical analyses were performed using SPSS 22.0 (IBM SPSS Statistics, IBM, Chicago, IL, United States) and GraphPad Prism (version 7.0; GraphPad Software, Inc, San Diego, CA, United States).

RESULTS

Baseline characteristic of patients

Twenty (46.51%) and twenty-two (41.51%) men were included in the endoscopic and EVD groups, respectively, and the two groups did not show a significant difference in sex distribution. Patients in the endoscopic group were significantly older than those in the EVD group [endoscopic group: (median, IQR) 60.40 \pm 9.55 years; EVD group: 55.34 \pm 12.17 years]. The preoperative GCS score was comparable between the two groups (Table 1). The total ventricular hemorrhage and hematoma into the third and fourth ventricles (blood volume \geq 30 mL) were regularly recorded by head CT scans (Figure 1C). Among all patients, 12 had a pre-operative history of hypertension and 2 had a history of moyamoya disease. Compared with the non-endoscopic group, the baseline Graeb score was higher in the endoscopic group, which indicated more severe hemorrhage.

Table 1 The baseline and perioperative characteristics of the study population

Metrics	Endoscopic group	Non-endoscopic group	P value
Baseline			
Age, yr	60.40 ± 9.55	55.34 ± 12.71	0.033
Sex (male), n %	20 (46.51%)	22 (41.51%)	0.623
Pre-operative GCS score	6.00 (6.00-7.00)	7.00 (6.00-8.00)	0.216
Graeb score	9.00 (7.00-10.00)	8.00 (6.00-9.00)	0.023
Perioperative			
Operation time, hours	2.42 (2.17-2.88)	1.08 (0.82-3.33)	< 0.001
Hematoma clearance rate, %	60.50% (53.20%-70.40%)	10.20% (6.60%-18.90%)	< 0.001
GCS score improvement	4.00 (2.00-4.50)	1.00 (-1.00-2.00)	< 0.001
Drainage, d	5.00 (5.00-6.00)	5.00 (5.00-6.00)	0.288
ICU stay, d	6.00 (3.00-9.00)	7.00 (5.00-10.00)	0.017
Hospitalization time, d	26.00 (18.50-33.00)	26.00 (19.00-40.00)	0.292

Normally distributed variables are presented as the mean ± SD and were compared using *t*-tests. Non-normally distributed variables are presented as the median and interquartile range and were compared using nonparametric Kruskal-Wallis tests. The Graeb score was used to assess the severity of hemorrhage. ^a*P* < 0.05. GCS: Glasgow coma scale.

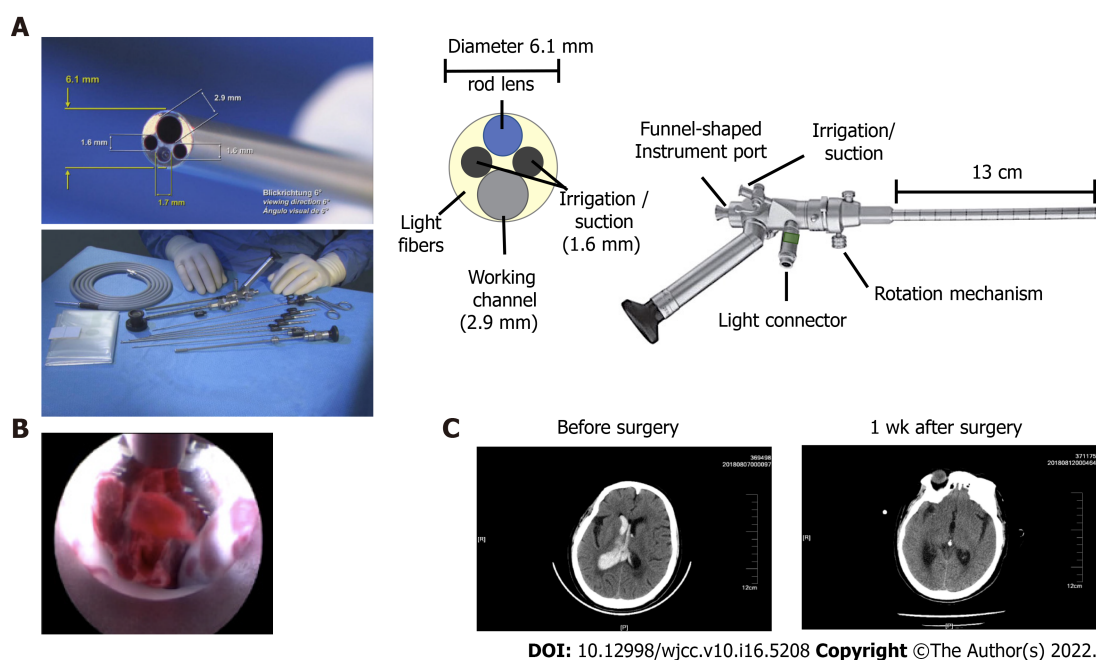
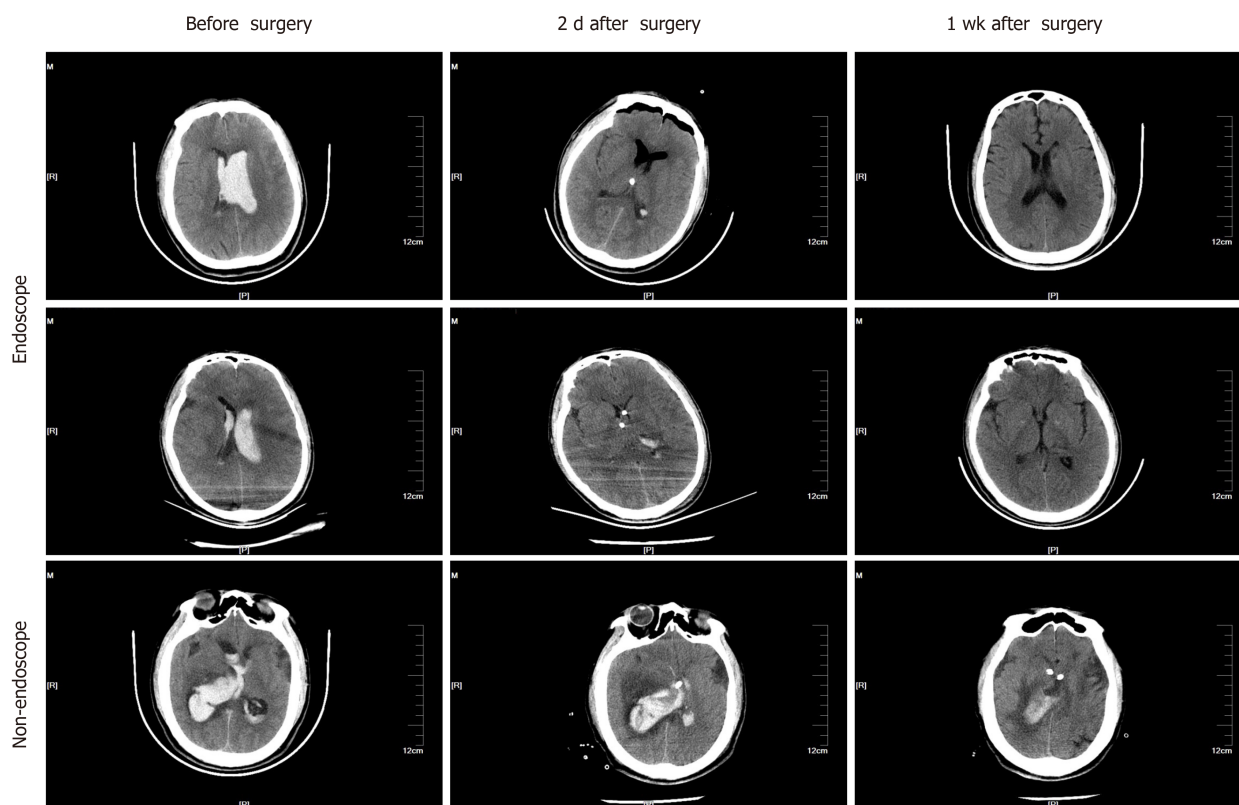


Figure 1 The structure and procedure of endoscopic surgery for intraventricular hemorrhage. A: The structure of the KARL STORZ high resolution ventriculoscope system (provided by KARL STORZ Co. Ltd.); B: A representative image showing how to pull out the clot by advancing through the working channel using forceps; C: Representative images of head computed tomography in the endoscopic group before and after surgery.

Outcomes of endoscope surgery for IVH

The median operation time was 2.42 h and 1.08 h for the endoscopic and EVD groups, respectively (Table 1). During the endoscopic operation, conversion to craniotomy was necessary in 10 cases (23.3%) (including 5 patients with moyamoya disease, 2 with aneurysm ruptures at the basilar artery junction, and 3 with hypertensive intracerebral hemorrhage in the basal ganglia) as a result of intraoperative massive hemorrhage. Eight (18.6%) patients with hypertensive intracerebral hemorrhage had a history of hematoma evacuation by craniotomy before endoscopic evacuation, and their hematoma volumes were over 30 mL. The ventricular hemorrhage and hematoma in the endoscopic group were evaluated by head CT scans before and after surgery (Figure 2). The average clearance rate of the hematoma was



DOI: 10.12998/wjcc.v10.i16.5208 Copyright ©The Author(s) 2022.

Figure 2 Representative head computed tomography images in the endoscopic and non-endoscopic groups. The upper and middle panels show images from patients in the endoscopic group. The lower panel shows images from the non-endoscopic group. Three time points are shown, including before surgery, two days after surgery, and one week after surgery.

60.5% in the endoscopic group, and only 10.2% in the EVD group (Table 1).

In the short term, 28 (65%) patients in the endoscopic group showed marked improvement in conscious states, with a mean GCS score increase of more than 3. Five patients (11.7%) had postoperative communicating hydrocephalus and were cured by ventriculoperitoneal shunt. No other complications, such as intracranial infection, were observed in any patients. In the long term, consciousness was restored in most patients, as revealed by increased GCS scores after surgery (Figure 3A and Table 1).

Comparison of clinical outcomes between endoscope and EVD surgery groups

The total ventricular hemorrhage and hematoma in the non-endoscopic group were visualized using head CT scans before and after surgery (Figure 2, lower panel). Drainage tube indwelling time (Figure 3C and Table 1) was comparable between the endoscopic and non-endoscopic groups. Despite a longer operation time, older age, and more serious hemorrhage, the endoscopic surgery dramatically improved the clearance rate of hematoma (Figure 3D). The endoscopic group had a longer operation time than the non-endoscopic group (Figure 3E). Although both groups exhibited an increased GCS after surgery (Figure 3A and 3F), the endoscopic group had a higher GCS index than the non-endoscopic group after surgery (Figure 3G and Table 1), which indicates that endoscopic surgery for IVH contributed to the recovery of consciousness. In addition, the endoscopic group showed a lower Graeb score than the non-endoscope group after surgery (Figure 3H), which suggests that endoscopic surgery leads to more successful hemorrhage evacuation. Finally, although there was no significant difference in hospitalization time between the two groups, the intensive care unit stay of the endoscopic group was shorter than that of the EVD group (Table 1).

DISCUSSION

In this paper, we present our experience of treating patients with IVH using endoscopic surgery, and compared their perioperative metrics with patients who received traditional EVD surgeries. We found that endoscopic evacuation was effective and efficient for treating IVH. Furthermore, endoscopic surgery led to a higher rate of hemorrhage evacuation and more marked consciousness recovery compared with the non-endoscopic surgery group. Herein, we will combine clinical evidence, our

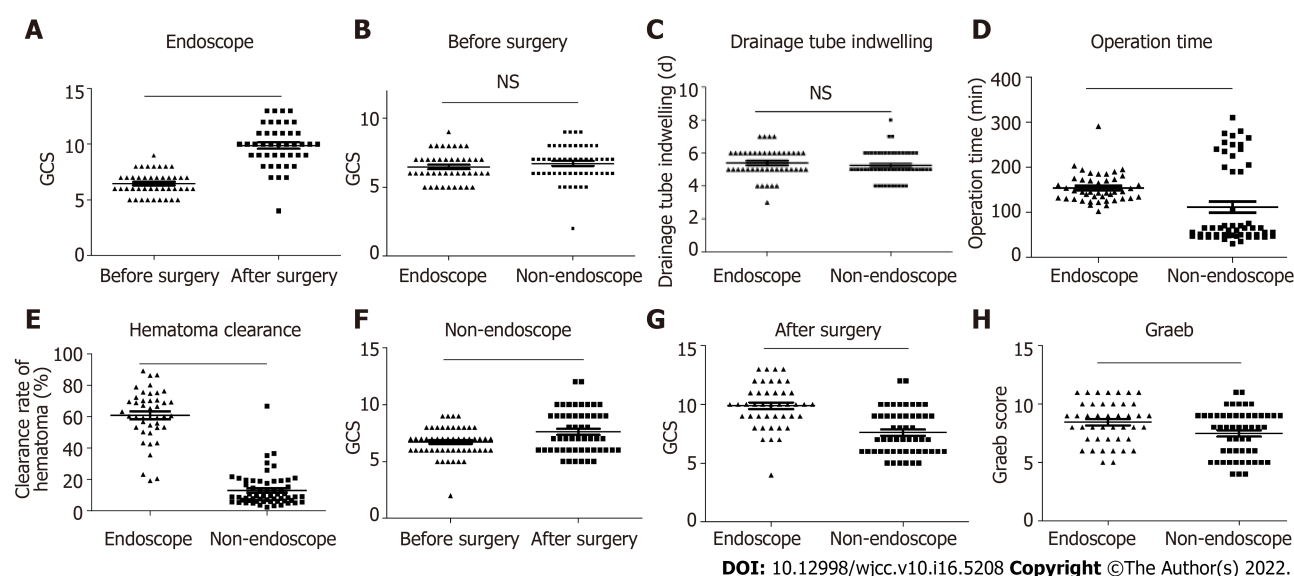


Figure 3 The endoscopic surgery group showed better clinical outcomes than the non-endoscopic group. A: The change of the Glasgow Coma Scale (GCS) score in the endoscopic group after surgery. $n = 43$. A two-tailed paired t -test was performed; B: The comparison in the GCS score between the endoscopic group and non-endoscopic group before surgery. Endoscopic group, $n = 43$; Non-endoscopic group, $n = 53$. The Kruskal-Wallis test was performed; C: The comparison of the drainage tube indwelling time between the endoscopic group and non-endoscopic group before surgery. Endoscopic group, $n = 43$; Non-endoscopic group, $n = 53$. The Kruskal-Wallis test was performed; D: The operation time in the endoscopic and non-endoscopic groups. Endoscopic group, $n = 43$; Non-endoscopic group, $n = 53$. The Kruskal-Wallis test was performed; E: The clearance rate of hematoma in the endoscopic and non-endoscopic groups. Endoscopic group, $n = 43$; Non-endoscopic group, $n = 53$. The Kruskal-Wallis test was performed; F: The change of the GCS score in the non-endoscopic group after surgery. $n = 53$. A two-tailed paired t -test was performed; G: The comparison of the GCS score between the endoscopic group and non-endoscopic group after surgery. Endoscopic group, $n = 43$; Non-endoscopic group, $n = 53$. The Kruskal-Wallis test was performed; H: The comparison of the Graeb score between the endoscopic group and non-endoscopic group after surgery. Endoscopic group, $n = 43$; Non-endoscopic group, $n = 53$. The Kruskal-Wallis test was performed. ^a $P < 0.05$, ^b $P < 0.01$, ^c $P < 0.001$; $P < 0.05$ was considered as statistically significant. Two-tailed unpaired t -tests were performed.

clinical experience, and previous publications to discuss the key factors for hemorrhage evacuation using the endoscopic approach.

IVH can induce a cascade of lethal symptoms. Cerebrospinal fluid circulation obstruction by hemorrhage clots in the third and fourth ventricles leads to drastic elevation of intracranial pressure and loss of consciousness. Blood clots and breakdown products compress and squeeze the hypothalamus and brain stem, resulting in multiple organ dysfunction. Immediate clearance of intraventricular blood is the key to an improved prognosis[7]. Currently, many methods are available for the evacuation of IVH, such as catheter drainage with or without fibrinolytic therapy, neurosurgical evacuation, and minimally invasive endoscopic surgery. A recent meta-analysis[8] has reported that endoscopic evacuation is more favorable than catheter drainage. However, other researchers claim that the latter is more favorable[4,9]. Moreover, with the help of more accurate instruments and neuronavigation methods, endoscopic hematoma evacuation can be conducted under the guidance of visualization of ventricles. Previous reports have shown that patients with IVH treated by endoscopic management tend to have more favorable outcomes, a shorter recovery time[3,7,10], and a lower incidence of infection [11]. Generally, subdural effusion, intraventricular hemorrhage and infection are the main complications in endoscopic procedure, which is similar with conventional indwelling ventricular drainage tube operation. However, as with the application of endoscopic methods in other fields, the techniques and experiences of surgeons have great impacts on the efficacy and outcome of ventricular endoscopic surgery. Subdural effusion always occurs during the operation of intraventricular lesions, which cases needed drilling and drainage. When the thick intraventricular endoscope entering ventricle from the cortex, it is equivalent to ventriculostomy. Cerebrospinal fluid flow from the ventricle to the subdural canal caused by the endoscope, resulting in subdural effusion, and few patients could heal themselves. It is worth noting that the rate of communicating hydrocephalus was relatively low (11.7%) in our study. Blood residue in the ventricles after intracranial hemorrhage evacuation is a risk factor for communicating hydrocephalus[12], which suggested that the evacuation was effective. Intraventricular endoscopic surgery is an operation with high aseptic requirements, which need the instruments be strictly disinfected, and the aseptic operation should be strictly carried out during the operation. It is best to use antibiotics before the operation. In our series, no patients showed signs of intracranial infection. Effective prevention of infection may have been done because the drainage was completed within 3 d in our series. Therefore, our operation method greatly prevents the occurrence of complications, and has operability and safety.

We have summarized several features of our experience in surgical techniques. First, the frontal horn of the lateral ventricle is a safer trajectory towards lesions in the lateral ventricle in intracranial procedures[13], which was effective and less traumatic in our patients. Meanwhile, careful positional adjustments of the ventriculoscope could help to improve the efficacy and safety of hematoma evacuation. Second, clearing the visual field increased the accuracy of hematoma removal. The vision of the endoscope was often blurred by bloody cerebrospinal fluid as the endoscope entered the lateral ventricle. The incidence of injury may significantly increase without clear vision, and blind manipulation under blurred or “red-out” endoscopic vision is not recommended[14]. Thus, we used normal saline to displace the bloody cerebrospinal fluid before aspiration. Intraoperative hemorrhage can also obscure the endoscope vision, so continuous rinsing and avoiding blind operation are particularly important issues to highlight. In addition, the endoscope can be interfered with by hemorrhages from small vessels on the puncture trajectory and damaged choroid plexus and ventricular walls, which can usually be attenuated or prevented by rinsing, which is consistent with previous reports[15,16]. After regaining a clear vision, the hemorrhagic spots can be identified and cauterized with a bipolar coagulation electrode to stop bleeding.

We considered navigation to be necessary at the beginning of the surgery since the loss of cerebrospinal fluid during an evacuation may cause a position shift of the brain. Moreover, given that rinsing ensures a better visibility in the ventricle, the endoscopy can be more precisely navigated to avoid damaging the brain. Therefore, performing endoscopy in the center of the hematoma is not necessary.

The irrigation fluid used was normal saline (23 °C -25 °C) at 5 cm -10 cm H₂O, which is not consistent with other authors who have claimed that artificial cerebrospinal fluid is the better choice for irrigation [17-19]. The use of low-temperature saline should indeed be avoided in infants[20]. However, there is no evidence to suggest that normal saline is more harmful than irrigation fluid in adults, and, considering accessibility, we used normal saline in our series. No irrigation-related intraoperative or postoperative side effects were observed.

Three patients had an intraoperative massive hemorrhage, which is a challenge in neurological procedures[21]. A conversion to craniotomy was conducted to manage intraoperative hemorrhage in these cases. All three patients exhibited large volumes of red bloody fluid and intracranial hypertension (elevated blood pressure and pulse pressure), compared with the previously mentioned minor hemorrhage. Massive hemorrhage cannot be stopped by irrigation. Based on our experience, we suggest that a large hematoma volume and significant brain position shift after hematoma evacuation are likely to be signs of an intraoperative massive hemorrhage, in which case craniotomy should be considered.

This study has some limitations, such as the small sample size and the retrospective nature of the study. Future prospective studies with a larger series are required to further confirm the efficacy and safety of endoscopic evacuation.

CONCLUSION

Our study showed that endoscopic evacuation of IVH was generally effective and efficient. The included patients showed significant improvement in consciousness, long-term recovery, and the Graeb index. In addition, this research demonstrates our preliminary experience in practicing endoscopic evacuation.

ARTICLE HIGHLIGHTS

Research background

Intraventricular hemorrhage (IVH) is a neurosurgical emergency, and a dangerous condition associated with high morbidity and mortality. In traditional treatment, hematoma evacuation is generally executed by external intracranial drainage (EVD) or surgical evacuation, but endoscopic evacuation is emerging as a good alternative approach, which brings relatively less invasion and injury. Accordingly, we need more successful endoscopic evacuation skilled experience to support endoscopic evacuation development.

Research motivation

With the development of endoscopic evacuation approach in Intraventricular hemorrhage therapy, we need more successful endoscopic evacuation skilled manipulation of endoscopic devices and the evidence supporting its efficacy differs. Thus, in this research, we retrospectively studied 96 consecutive patients with intraventricular hemorrhage who underwent either endoscopic surgery or non-endoscopic surgery for hemorrhage evacuation in different reports, which could provide guidance for endoscopic evacuation treatment in IVH.

Research objectives

In this research, we try to improve the technique usage and provide more evidence of endoscopic evacuation efficacy. Besides, we summarize our surgical experience and compared the outcomes of the endoscopic evacuation with EVD using real-world data.

Research methods

We retrospectively studied 96 consecutive patients with intraventricular hemorrhage who underwent either endoscopic surgery ($n = 43$) or non-endoscopic surgery ($n = 53$) for hemorrhage evacuation between November 2013 and September 2019 in our center. Patients' conditions prior to and after the operation were evaluated and analyzed to assess the efficacy of the operation. The consciousness status improvement and perioperative in-hospital parameters in the two types of operation groups were assessed and compared.

Research results

Patients in the endoscopic and non-endoscopic groups presented with a similar state of consciousness, with a comparable Glasgow Coma Scale (GCS) index. It was found that the average operation time was longer in the endoscopic group; the endoscopic group had a baseline Graeb score that indicated more severe hemorrhage than the non-endoscopic group, and the clearance rate of hematoma was as high as 60.5%. In the endoscopic group, the improved GCS index was more marked. Besides, the intensive care unit stay of the endoscopic group was significantly shorter than that of the non-endoscopic group.

Research conclusions

Endoscopic evacuation of intraventricular hemorrhage was generally an effective and efficient way for hemorrhage evacuation, and contributed remarkably to the improvement of consciousness in patients with intraventricular hemorrhage, which could be a potential surgical methods to be developed.

Research perspectives

In our retrospective analysis, our study showed that endoscopic evacuation of IVH was generally effective and efficient. The included patients showed significant improvement in consciousness, long-term recovery, and the Graeb index. This research provides us more preliminary experience in practicing endoscopic evacuation.

FOOTNOTES

Author contributions: Wang FB and Xiang ZH conceived of the presented idea. Wang FB, Yuan XW wrote the manuscript with support from Li JX and Zhang M; all authors discussed the results and contributed to the final manuscript.

Institutional review board statement: The study was reviewed and approved by the Institutional Review Board at MedImmune and Gubra.

Informed consent statement: All study participants or their legal guardian provided informed written consent about personal and medical data collection prior to study enrolment.

Conflict-of-interest statement: The authors declare that they have no conflicts of interest.

Data sharing statement: No additional data are available.

Open-Access: This article is an open-access article that was selected by an in-house editor and fully peer-reviewed by external reviewers. It is distributed in accordance with the Creative Commons Attribution NonCommercial (CC BY-NC 4.0) license, which permits others to distribute, remix, adapt, build upon this work non-commercially, and license their derivative works on different terms, provided the original work is properly cited and the use is non-commercial. See: <https://creativecommons.org/licenses/by-nc/4.0/>

Country/Territory of origin: China

ORCID number: Feng-Bo Wang 0000-0002-4843-5092; Xiao-Wa Yuan 0000-0002-1111-5968; Jin-Xiao Li 0000-0002-2297-3677; Ming Zhang 0000-0003-2675-4225; Zhao-Hui Xiang 0000-0001-7593-5212.

S-Editor: Xing YX

L-Editor: A

P-Editor: Xing YX

REFERENCES

- 1 **Garton T**, Hua Y, Xiang J, Xi G, Keep RF. Challenges for intraventricular hemorrhage research and emerging therapeutic targets. *Expert Opin Ther Targets* 2017; **21**: 1111-1122 [PMID: [29067856](#) DOI: [10.1080/14728222.2017.1397628](#)]
- 2 **Zhang S**, Jia B, Li H, You C, Hanley DF, Jiang Y. Primary intraventricular hemorrhage in adults: etiological causes and prognostic factors in Chinese population. *J Neurol* 2017; **264**: 382-390 [PMID: [28000008](#) DOI: [10.1007/s00415-016-8367-x](#)]
- 3 **Ma L**, Hou Y, Zhu R, Chen X. Endoscopic Evacuation of Basal Ganglia Hematoma: Surgical Technique, Outcome, and Learning Curve. *World Neurosurg* 2017; **101**: 57-68 [PMID: [28147238](#) DOI: [10.1016/j.wneu.2017.01.072](#)]
- 4 **Song P**, Duan FL, Cai Q, Wu JL, Chen XB, Wang Y, Huang CG, Li JQ, He ZQ, Huang QC, Liu M, Zhang YG, Luo M. Endoscopic Surgery vs External Ventricular Drainage Surgery for Severe Intraventricular Hemorrhage. *Curr Med Sci* 2018; **38**: 880-887 [PMID: [30341524](#) DOI: [10.1007/s11596-018-1957-3](#)]
- 5 **Green SM**, Haukoos JS, Schriger DL. How to Measure the Glasgow Coma Scale. *Ann Emerg Med* 2017; **70**: 158-160 [PMID: [28169051](#) DOI: [10.1016/j.annemergmed.2016.12.016](#)]
- 6 **Romero JM**, Rosand J. Hemorrhagic cerebrovascular disease. *Handb Clin Neurol* 2016; **135**: 351-364 [PMID: [27432674](#) DOI: [10.1016/B978-0-444-53485-9.00018-0](#)]
- 7 **Ceja Espinosa A**, Franco Jimenez JA, Reyes Vazquez P, Gutierrez Aceves GA, Ponce Ayala A. Endoscopic Third Ventriculostomy for Obstructive Hydrocephalus Secondary to Delayed Intracerebellar Hematoma. *Cureus* 2021; **13**: e17302 [PMID: [34552836](#) DOI: [10.7759/cureus.17302](#)]
- 8 **Kellner CP**, Song R, Ali M, Nistal DA, Samarage M, Dangayach NS, Liang J, McNeill I, Zhang X, Bederson JB, Mocco J. Time to Evacuation and Functional Outcome After Minimally Invasive Endoscopic Intracerebral Hemorrhage Evacuation. *Stroke* 2021; **52**: e536-e539 [PMID: [34424739](#) DOI: [10.1161/STROKEAHA.121.034392](#)]
- 9 **Xiao T**, Wan J, Qu H, Jiang W, Zhou X. Endoscopic Surgery vs Minimal Puncture Drainage Surgery for Treatment of Supratentorial Intracerebral Hemorrhage. *Turk Neurosurg* 2020; **30**: 565-572 [PMID: [32530475](#) DOI: [10.5137/1019-5149.JTN.27977-19.2](#)]
- 10 **Oertel J**, Linsler S, Csokonay A, Schroeder HWS, Senger S. Management of severe intraoperative hemorrhage during intraventricular neuroendoscopic procedures: the dry field technique. *J Neurosurg* 2018; **131**: 931-935 [PMID: [30239311](#) DOI: [10.3171/2018.4.JNS.172537](#)]
- 11 **Wellons JC 3rd**, Shannon CN, Holubkov R, Riva-Cambrin J, Kulkarni AV, Limbrick DD Jr, Whitehead W, Browd S, Rozzelle C, Simon TD, Tamber MS, Oakes WJ, Drake J, Luerssen TG, Kestle J; Hydrocephalus Clinical Research Network. Shunting outcomes in posthemorrhagic hydrocephalus: results of a Hydrocephalus Clinical Research Network prospective cohort study. *J Neurosurg Pediatr* 2017; **20**: 19-29 [PMID: [28452657](#) DOI: [10.3171/2017.1.PEDS16496](#)]
- 12 **Yang WS**, Shen YQ, Zhang XD, Zhao LB, Wei X, Xiong X, Xie XF, Li R, Deng L, Li XH, Lv XN, Lv FJ, Li Q, Xie P. Hydrocephalus Growth: Definition, Prevalence, Association with Poor Outcome in Acute Intracerebral Hemorrhage. *Neurocrit Care* 2021; **35**: 62-71 [PMID: [33174150](#) DOI: [10.1007/s12028-020-01140-w](#)]
- 13 **Avinash KS**, Thakar S, Ghosal N, Hegde AS. Anaplastic hemangiopericytoma in the frontal horn of the lateral ventricle. *J Clin Neurosci* 2016; **26**: 147-149 [PMID: [26732285](#) DOI: [10.1016/j.jocn.2015.08.031](#)]
- 14 **Motegi H**, Kobayashi H, Terasaka S, Yamaguchi S, Ishi Y, Ito Y, Houkin K. Application of endoscopic ultrasonography to intraventricular lesions. *Acta Neurochir (Wien)* 2016; **158**: 87-92 [PMID: [26542528](#) DOI: [10.1007/s00701-015-2617-z](#)]
- 15 **Oesterling AE**, Hansen BE. Severe Intraoperative Hemorrhage during Craniectomy in a Patient with Polyostotic Fibrous Dysplasia. *Anesthesiology* 2020; **133**: 1261-1262 [PMID: [32898214](#) DOI: [10.1097/ALN.0000000000003556](#)]
- 16 **Tan LA**, Lopes DK, Munoz LF, Shah Y, Bhabad S, Jhaveri M, Moftakhar R. Minimally invasive evacuation of intraventricular hemorrhage with the Apollo vibration/suction device. *J Clin Neurosci* 2016; **27**: 53-58 [PMID: [26778051](#) DOI: [10.1016/j.jocn.2015.08.037](#)]
- 17 **Yamamoto T**, Takeuchi K, Nagata Y, Mizuno A, Wakabayashi T. Novel Endoscopic Technique for Inserting a Sheath into a Slit Ventricle: The Water-Slide Technique. *World Neurosurg* 2021; **145**: 1-4 [PMID: [32891843](#) DOI: [10.1016/j.wneu.2020.08.206](#)]
- 18 **Kuwabara M**, Sadatomo T, Yuki K, Migita K, Imada Y, Shimizu K, Hara T, Oba H, Kurisu K. The Effect of Irrigation Solutions on Recurrence of Chronic Subdural Hematoma: A Consecutive Cohort Study of 234 Patients. *Neurol Med Chir (Tokyo)* 2017; **57**: 210-216 [PMID: [28367840](#) DOI: [10.2176/nmc.0a.2016-0228](#)]
- 19 **Guan F**, Peng WC, Huang H, Ren ZY, Wang ZY, Fu JD, Li YB, Cui FQ, Dai B, Zhu GT, Xiao ZY, Mao BB, Hu ZQ. Application of neuroendoscopic surgical techniques in the assessment and treatment of cerebral ventricular infection. *Neural Regen Res* 2019; **14**: 2095-2103 [PMID: [31397347](#) DOI: [10.4103/1673-5374.262591](#)]
- 20 **Demerdash A**, Rocque BG, Johnston J, Rozzelle CJ, Yalcin B, Oskouian R, Delashaw J, Tubbs RS. Endoscopic third ventriculostomy: A historical review. *Br J Neurosurg* 2017; **31**: 28-32 [PMID: [27774823](#) DOI: [10.1080/02688697.2016.1245848](#)]
- 21 **Li C**, Zong X, Wang X, Gui S, Zhang Y. Intraoperative Hemorrhage in Ventriculoscopic Surgery: Experience of a Single Chinese Neurosurgery Center. *World Neurosurg* 2016; **88**: 548-551 [PMID: [26514635](#) DOI: [10.1016/j.wneu.2015.10.041](#)]



Published by **Baishideng Publishing Group Inc**
7041 Koll Center Parkway, Suite 160, Pleasanton, CA 94566, USA

Telephone: +1-925-3991568

E-mail: bpgoffice@wjgnet.com

Help Desk: <https://www.f6publishing.com/helpdesk>

<https://www.wjgnet.com>

