

World Journal of *Clinical Cases*

World J Clin Cases 2022 February 6; 10(4): 1140-1456



Contents

Thrice Monthly Volume 10 Number 4 February 6, 2022

REVIEW

- 1140 COVID-19: Gastrointestinal manifestations, liver injury and recommendations
Ozkurt Z, Çınar Tanrıverdi E

ORIGINAL ARTICLE

Retrospective Study

- 1164 Continuous intravenous infusion of recombinant human endostatin using infusion pump plus chemotherapy in non-small cell lung cancer
Qin ZQ, Yang SF, Chen Y, Hong CJ, Zhao TW, Yuan GR, Yang L, Gao L, Wang X, Lu LQ
- 1172 Sequential sagittal alignment changes in the cervical spine after occipitocervical fusion
Zhu C, Wang LN, Chen TY, Mao LL, Yang X, Feng GJ, Liu LM, Song YM
- 1182 Importance of the creation of a short musculofascial tunnel in peritoneal dialysis catheter placement
Lee CY, Tsai MK, Chen YT, Zhan YJ, Wang ML, Chen CC
- 1190 Clinical effect of methimazole combined with selenium in the treatment of toxic diffuse goiter in children
Zhang XH, Yuan GP, Chen TL
- 1198 Clinical study on the minimally invasive percutaneous nephrolithotomy treatment of upper urinary calculi
Xu XJ, Zhang J, Li M, Hou JQ

Observational Study

- 1206 Comparison of diagnostic validity of two autism rating scales for suspected autism in a large Chinese sample
Chu JH, Bian F, Yan RY, Li YL, Cui YH, Li Y
- 1217 Doctor-led intensive diet education on health-related quality of life in patients with chronic renal failure and hyperphosphatemia
Feng XD, Xie X, He R, Li F, Tang GZ

SYSTEMATIC REVIEWS

- 1226 What are the self-management experiences of the elderly with diabetes? A systematic review of qualitative research
Li TJ, Zhou J, Ma JJ, Luo HY, Ye XM

META-ANALYSIS

- 1242 Comparison of the clinical performance of i-gel and Ambu laryngeal masks in anaesthetised paediatric patients: A meta-analysis
Bao D, Yu Y, Xiong W, Wang YX, Liang Y, Li L, Liu B, Jin X

CASE REPORT

- 1255** Autogenous iliotibial band enhancement combined with tendon lengthening plasty to treat patella baja: A case report
Tang DZ, Liu Q, Pan JK, Chen YM, Zhu WH
- 1263** Sintilimab-induced autoimmune diabetes: A case report and review of the literature
Yang J, Wang Y, Tong XM
- 1278** Unicentric Castleman disease was misdiagnosed as pancreatic mass: A case report
Zhai HY, Zhu XY, Zhou GM, Zhu L, Guo DD, Zhang H
- 1286** Iguratimod in treatment of primary Sjögren's syndrome concomitant with autoimmune hemolytic anemia: A case report
Zhang J, Wang X, Tian JJ, Zhu R, Duo RX, Huang YC, Shen HL
- 1291** Primary central nervous system lymphoma presenting as a single choroidal lesion mimicking metastasis: A case report
Jang HR, Lim KH, Lee K
- 1296** Surgical treatment of acute cholecystitis in patients with confirmed COVID-19: Ten case reports and review of literature
Bozada-Gutiérrez K, Trejo-Avila M, Chávez-Hernández F, Parraguirre-Martínez S, Valenzuela-Salazar C, Herrera-Esquivel J, Moreno-Portillo M
- 1311** Hydrogen inhalation promotes recovery of a patient in persistent vegetative state from intracerebral hemorrhage: A case report and literature review
Huang Y, Xiao FM, Tang WJ, Qiao J, Wei HF, Xie YY, Wei YZ
- 1320** Ultrasound-guided needle release plus corticosteroid injection of superficial radial nerve: A case report
Zeng Z, Chen CX
- 1326** Inverted Y ureteral duplication with an ectopic ureter and multiple urinary calculi: A case report
Ye WX, Ren LG, Chen L
- 1333** Multiple miscarriages in a female patient with two-chambered heart and situs inversus totalis: A case report
Duan HZ, Liu JJ, Zhang XJ, Zhang J, Yu AY
- 1341** Chidamide combined with traditional chemotherapy for primary cutaneous aggressive epidermotropic CD8+ cytotoxic T-cell lymphoma: A case report
He ZD, Yang HY, Zhou SS, Wang M, Mo QL, Huang FX, Peng ZG
- 1349** Fatal rhabdomyolysis and disseminated intravascular coagulation after total knee arthroplasty under spinal anesthesia: A case report
Yun DH, Suk EH, Ju W, Seo EH, Kang H
- 1357** Left atrial appendage occlusion in a mirror-image dextrocardia: A case report and review of literature
Tian B, Ma C, Su JW, Luo J, Sun HX, Su J, Ning ZP

- 1366** Imaging presentation of biliary adenofibroma: A case report
Li SP, Wang P, Deng KX
- 1373** Multiple gouty tophi in the head and neck with normal serum uric acid: A case report and review of literatures
Song Y, Kang ZW, Liu Y
- 1381** Toxic epidermal necrolysis induced by ritodrine in pregnancy: A case report
Liu WY, Zhang JR, Xu XM, Ye TY
- 1388** Direct antiglobulin test-negative autoimmune hemolytic anemia in a patient with β -thalassemia minor during pregnancy: A case report
Zhou Y, Ding YL, Zhang LJ, Peng M, Huang J
- 1394** External penetrating laryngeal trauma caused by a metal fragment: A Case Report
Qiu ZH, Zeng J, Zuo Q, Liu ZQ
- 1401** Antegrade in situ laser fenestration of aortic stent graft during endovascular aortic repair: A case report
Wang ZW, Qiao ZT, Li MX, Bai HL, Liu YF, Bai T
- 1410** Hoffa's fracture in an adolescent treated with an innovative surgical procedure: A case report
Jiang ZX, Wang P, Ye SX, Xie XP, Wang CX, Wang Y
- 1417** Hemizygous deletion in the OTC gene results in ornithine transcarbamylase deficiency: A case report
Wang LP, Luo HZ, Song M, Yang ZZ, Yang F, Cao YT, Chen J
- 1423** Langerhans cell histiocytosis presenting as an isolated brain tumour: A case report
Liang HX, Yang YL, Zhang Q, Xie Z, Liu ET, Wang SX
- 1432** Inflammatory myofibroblastic tumor after breast prosthesis: A case report and literature review
Zhou P, Chen YH, Lu JH, Jin CC, Xu XH, Gong XH
- 1441** Eustachian tube involvement in a patient with relapsing polychondritis detected by magnetic resonance imaging: A case report
Yunaiyama D, Aoki A, Kobayashi H, Someya M, Okubo M, Saito K
- 1447** Endoscopic clipping for the secondary prophylaxis of bleeding gastric varices in a patient with cirrhosis: A case report
Yang GC, Mo YX, Zhang WH, Zhou LB, Huang XM, Cao LM

LETTER TO THE EDITOR

- 1454** Rituximab as a treatment for human immunodeficiency virus-associated nemaline myopathy: What does the literature have to tell us?
Gonçalves Júnior J, Shinjo SK

ABOUT COVER

Editorial Board Member of *World Journal of Clinical Cases*, Nicoleta-Monica Popa-Fotea, MD, PhD, Assistant Professor, Department of Cardio-thoracic, University of Medicine and Pharmacy, Bucharest 050474, Romania. nicoleta.popa-fotea@drd.umfcd.ro

AIMS AND SCOPE

The primary aim of *World Journal of Clinical Cases* (WJCC, *World J Clin Cases*) is to provide scholars and readers from various fields of clinical medicine with a platform to publish high-quality clinical research articles and communicate their research findings online.

WJCC mainly publishes articles reporting research results and findings obtained in the field of clinical medicine and covering a wide range of topics, including case control studies, retrospective cohort studies, retrospective studies, clinical trials studies, observational studies, prospective studies, randomized controlled trials, randomized clinical trials, systematic reviews, meta-analysis, and case reports.

INDEXING/ABSTRACTING

The WJCC is now indexed in Science Citation Index Expanded (also known as SciSearch®), Journal Citation Reports/Science Edition, Scopus, PubMed, and PubMed Central. The 2021 Edition of Journal Citation Reports® cites the 2020 impact factor (IF) for WJCC as 1.337; IF without journal self cites: 1.301; 5-year IF: 1.742; Journal Citation Indicator: 0.33; Ranking: 119 among 169 journals in medicine, general and internal; and Quartile category: Q3. The WJCC's CiteScore for 2020 is 0.8 and Scopus CiteScore rank 2020: General Medicine is 493/793.

RESPONSIBLE EDITORS FOR THIS ISSUE

Production Editor: Hua-Ge Yin; Production Department Director: Xu Guo; Editorial Office Director: Jin-Lei Wang.

NAME OF JOURNAL

World Journal of Clinical Cases

ISSN

ISSN 2307-8960 (online)

LAUNCH DATE

April 16, 2013

FREQUENCY

Thrice Monthly

EDITORS-IN-CHIEF

Bao-Gan Peng, Jerzy Tadeusz Chudek, George Kontogeorgos, Maurizio Serati, Ja Hyeon Ku

EDITORIAL BOARD MEMBERS

<https://www.wjgnet.com/2307-8960/editorialboard.htm>

PUBLICATION DATE

February 6, 2022

COPYRIGHT

© 2022 Baishideng Publishing Group Inc

INSTRUCTIONS TO AUTHORS

<https://www.wjgnet.com/bpg/gerinfo/204>

GUIDELINES FOR ETHICS DOCUMENTS

<https://www.wjgnet.com/bpg/GerInfo/287>

GUIDELINES FOR NON-NATIVE SPEAKERS OF ENGLISH

<https://www.wjgnet.com/bpg/gerinfo/240>

PUBLICATION ETHICS

<https://www.wjgnet.com/bpg/GerInfo/288>

PUBLICATION MISCONDUCT

<https://www.wjgnet.com/bpg/gerinfo/208>

ARTICLE PROCESSING CHARGE

<https://www.wjgnet.com/bpg/gerinfo/242>

STEPS FOR SUBMITTING MANUSCRIPTS

<https://www.wjgnet.com/bpg/GerInfo/239>

ONLINE SUBMISSION

<https://www.f6publishing.com>



Ultrasound-guided needle release plus corticosteroid injection of superficial radial nerve: A case report

Zeng Zeng, Cong-Xian Chen

ORCID number: Zeng Zeng 0000-0002-8944-2950; Cong-Xian Chen 0000-0001-7305-3662.

Author contributions: Zeng Z and Chen CX were responsible for substantial contributions to conception and design; Chen CX was responsible for the acquisition of data; Zeng Z was responsible for drafting the article; Zeng Z and Chen CX were responsible for the final approval of the version to be published.

Informed consent statement: All study participants, or their legal guardian, provided informed written consent prior to study enrollment.

Conflict-of-interest statement: The authors declare that they have no conflict of interest.

CARE Checklist (2016) statement: The authors have read the CARE Checklist (2016), and the manuscript was prepared and revised according to the CARE Checklist (2016).

Country/Territory of origin: China

Specialty type: Radiology, nuclear medicine and medical imaging

Provenance and peer review: Unsolicited manuscript; Externally peer reviewed.

Zeng Zeng, Cong-Xian Chen, Department of Ultrasound, Zhejiang Provincial People's Hospital, Hangzhou 310000, Zhejiang Province, China

Corresponding author: Cong-Xian Chen, MM, Doctor, Department of Ultrasound, Zhejiang Provincial People's Hospital, No. 158 Shangtang Road, Hangzhou 310000, Zhejiang Province, China. kema320@qq.com

Abstract

BACKGROUND

The radial nerve (RN) splits into two main branches at the elbow: The superficial branch of RN (SBRN) and the deep branch of RN. The SBRN can be easily damaged in acute trauma due to its superficial feature.

CASE SUMMARY

A 55-year-old male patient injured his right wrist 10 mo ago. Debridement, suturing and bandaging were performed in the emergency room. Six months after the scar had healed, he felt numbness and tingling in the dorsal surface of the thumb of the right hand. So the surgery of resection and SBRN anastomosis were performed. The pathological findings showed it as traumatic neuroma. Four months after surgery, the patient felt numbness and tingling in the right dorsal surface of the thumb again. The tenderness was marked in the operated area. Ultrasound indicated that the SBRN was adhered to the surrounding tissue. The patient refused further surgical treatment and underwent ultrasound-guided needle release plus corticosteroid injection of the SBRN. Four weeks later, the tenderness in the surgical area was reduced by 70%, the numbness in the dorsal surface of the thumb of the right hand was reduced by 40% and the nerve swelling evaluated by ultrasound was reduced. Four months passed, he did not feel any numbness or tingling sensation of his right wrist. This is the first report of ultrasound-guided needle release plus corticosteroid injection of the SBRN.

CONCLUSION

Ultrasound can evaluate the condition of the RN, and the relationship with surrounding tissues. Ultrasound-guided needle release plus corticosteroid injection is an effective and safe treatment for SBRN adhesion.

Key Words: Ultrasound-guided; Needle release; Superficial radial nerve; Traumatic neuroma; Corticosteroid injection; Case report

Peer-review model: Single blind**Peer-review report's scientific quality classification**

Grade A (Excellent): 0
 Grade B (Very good): B
 Grade C (Good): 0
 Grade D (Fair): 0
 Grade E (Poor): 0

Open-Access: This article is an open-access article that was selected by an in-house editor and fully peer-reviewed by external reviewers. It is distributed in accordance with the Creative Commons Attribution NonCommercial (CC BY-NC 4.0) license, which permits others to distribute, remix, adapt, build upon this work non-commercially, and license their derivative works on different terms, provided the original work is properly cited and the use is non-commercial. See: <https://creativecommons.org/licenses/by-nc/4.0/>

Received: August 4, 2021**Peer-review started:** August 4, 2021**First decision:** November 6, 2021**Revised:** November 7, 2021**Accepted:** December 23, 2021**Article in press:** December 23, 2021**Published online:** February 6, 2022**P-Reviewer:** Watanabe A**S-Editor:** Liu JH**L-Editor:** A**P-Editor:** Liu JH

©The Author(s) 2022. Published by Baishideng Publishing Group Inc. All rights reserved.

Core Tip: A patient felt numbness and tingling in the right dorsal surface of the thumb four months after traumatic neuroma resection and the superficial branch anastomosis. Ultrasound revealed that the superficial branch was adhered to the surrounding tissue. Four weeks after ultrasound-guided needle release plus corticosteroid injection of the superficial branch, the tenderness and numbness both reduced thus indicating ultrasound-guided needle release plus corticosteroid injection is an effective and safe treatment for superficial branch adhesion.

Citation: Zeng Z, Chen CX. Ultrasound-guided needle release plus corticosteroid injection of superficial radial nerve: A case report. *World J Clin Cases* 2022; 10(4): 1320-1325

URL: <https://www.wjgnet.com/2307-8960/full/v10/i4/1320.htm>

DOI: <https://dx.doi.org/10.12998/wjcc.v10.i4.1320>

INTRODUCTION

The radial nerve (RN) is the largest branch of the brachial plexus posterior cord. It splits into two main branches at the elbow: The superficial branch of RN (SBRN) and the deep branch of RN[1,2]. The RN supplies the skin of the dorsal forearm, the dorsal-radial region of the hand and the muscle of the extensor compartment[1,2].

Ultrasound (US) is currently used as an imaging modality to observe nerves, especially superficial nerves[3]. The RN has a twisted course in the upper limb and is superficial enough to be accurately found using an ultrasonic high frequency probe[1,2]. Herein, we report a patient who had numbness and tingling in the dorsal surface of the thumb after traumatic neuroma resection plus SBRN anastomosis. Treatment consisted of US-guided needle release plus corticosteroid injection of the SBRN. Tenderness and numbness were reduced 4 wk after treatment.

CASE PRESENTATION

Chief complaints

A 55-year-old male patient presented to the department of ultrasound with numbness and tingling in the dorsal surface of the right thumb.

History of present illness

The patient injured his right wrist 10 mo previously. Debridement, suturing and bandaging were performed in the emergency room. Six months after the scar had healed, he felt numbness and tingling in the dorsal surface of the right thumb and was diagnosed with traumatic neuroma. Traumatic neuroma resection and SBRN anastomosis were performed. Four months after this treatment, he felt numbness and tingling in the right dorsal surface of the thumb, with obvious tenderness in the operated area.

History of past illness

No data were available.

Personal and family history

No data were available.

Physical examination

Tinel's sign was found to be positive on percussion of the right wrist.

Laboratory examinations

No data were available.

Imaging examinations

US revealed that the SBRN was adhered to the surrounding tissue.

FINAL DIAGNOSIS

US indicated that the SBRN had adhered to the surrounding tissue after traumatic neuroma resection and SBRN anastomosis (Figure 1).

TREATMENT

All treatment procedures were performed with the probe covered with surgical gloves. We used an acoustic coupling agent on the probe inside the surgical gloves (Figure 2). The patient's skin was disinfected 3 times with complex iodine. A sterile surgical towel was then placed. A 4 mL aliquot of a mixed solution which contained 2 mL 0.9% sodium chloride and 2 mL 2% lidocaine (in a ratio of 1:1) was injected. Then local anesthesia layer by layer was performed *via* the SBRN surface.

The adhesion between the SBRN and the subcutaneous soft tissue was separated under US guidance. Due to the needle angle, we performed needle release to the middle incision (transverse incision level) as it was difficult to go further. Needle release was then performed from the incision distal area to the proximal area, above the level of the transverse incision. Separation of posterior and bilateral adhesions of the SBRN was carried out on both the short and long axis (transverse incision level). During needle release, the process was considered satisfactory when there was no resistance between the syringe and the tissues around the RN. Finally, a mixture of 1 mL corticosteroid (betamethasone) and 2 mL 2% lidocaine was injected into the area of severe adhesion on the short axis (Figure 3).

OUTCOME AND FOLLOW-UP

Four weeks later after ultrasound-guided needle release plus corticosteroid injection of superficial radial nerve, the tenderness in the surgical area was reduced by 70%, the numbness in the dorsal surface of the right thumb was reduced by 40% and the nerve swelling evaluated by US was reduced. Four months passed, he did not feel any numbness or tingling sensation of his right wrist.

DISCUSSION

Because of cost-effectiveness and non-invasive characteristics, US has gained popularity in diagnosing peripheral nerve diseases[4]. US can not only detect the nerve but can also reveal the location and the relationship to other structures[5]. In most studies, nerves in US images are always described as hypoechoic fascicles with surrounding hyperechoic tissue, appearing as a typical honeycomb structure[6]. The nerve is usually observed on US axial view from the proximal to distal area and is tracked along an extended length. Color Doppler is used to observe vessels which can serve as anatomical landmarks near the nerve. In US images, a muscle innervated by a nerve which is smaller and hyperechoic compared to the contralateral side indicates atrophy and thus may indicate an abnormal nerve.

The RNs are normal when they had a stippled honeycomb appearance with hypoechoic areas corresponding to the nerve fascicles and surrounding hyperechoic rims corresponding to endoneurium, perineurium, and epineurium on the short axis of US images[7]. The RN can be damaged during acute trauma by direct laceration or contusion, by traction in high-impact trauma with bone separation or by osseous fragments[2]. Humeral shaft fractures are the most common injuries to the RN[8,9]. The RN can also be compressed or stretched in patients who have undergone surgery. The SBRN can easily be affected by penetrating trauma especially the point which pierces the fascia due to its superficial characteristics. The symptoms include pain, dysesthesia and drop wrist. Conservative treatments include rest, nonsteroidal anti-inflammatory drugs (NSAIDs) and physical therapy. If symptoms persist 12 wk after conservative treatment, then surgery is strongly recommended[10].

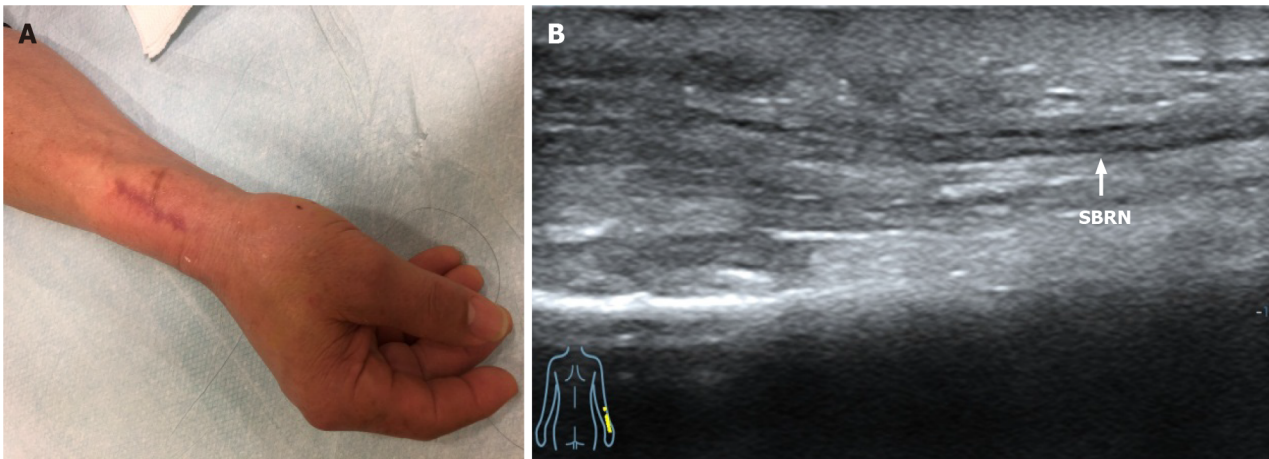


Figure 1 Three months after resection of traumatic neuroma. A: Appearance; B: Ultrasound image shows the long-axis view of the superficial branch of radial nerve adhered to the surrounding tissues (white line). SBRN: Superficial branch of radial nerve.

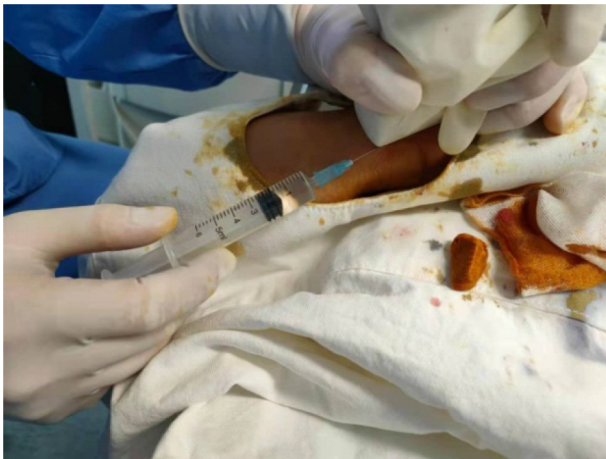

Figure 2 Sonographer held the probe covered with surgical gloves with one hand and did needle release of the superficial branch of radial nerve continuously under continuous guidance of ultrasound.

In this case, we found that after traumatic neuroma resection and nerve anastomosis, the patient felt numbness in the dorsal surface of the right thumb and obvious tenderness in the surgical area. US revealed that the SBRN was adhered to the surrounding tissues. NSAIDs administered for 3 mo were ineffective. The patient refused further surgical treatment. Thus, we used US-guided needle release plus corticosteroid injection to relieve the adhesion between the SBRN and the subcutaneous soft tissue for the first time. Under US guidance, we observed the needle in real-time thus improving accuracy and safety. A short-axis view of the nerve and an in-plane view of the needle were performed in order to view the outline of the SBRN and the approach of the needle. We also rotated between short-axis and long-axis views of the SBRN. The process of acupuncture release was continued until there was no resistance between the syringe and the tissues around the RN. A mixture of 1 mL corticosteroid (betamethasone) and 2 mL 2% lidocaine was then injected around the SBRN in the area of severe adhesion. The injection of corticosteroids can reduce pain and swelling.

There are several lessons to be learned from this study. First, due to skin scar formation and subcutaneous soft tissue adhesion, local infiltration anesthesia is difficult to inject subcutaneously; therefore, preoperative local infiltration anesthesia combined with skin surface anesthesia can be used, thus making the patient feel less pain and more comfortable. Secondly, the puncture was carried out in the plane so that the needle tip could be observed during the whole process in order to avoid injury to the nerve. Thirdly, the SBRN is very superficial, thus probe compression can lead to deformation making it difficult to identify the nerve. Therefore, at puncture initiation, it should be noted that the insertion site should be superficial and should not allow

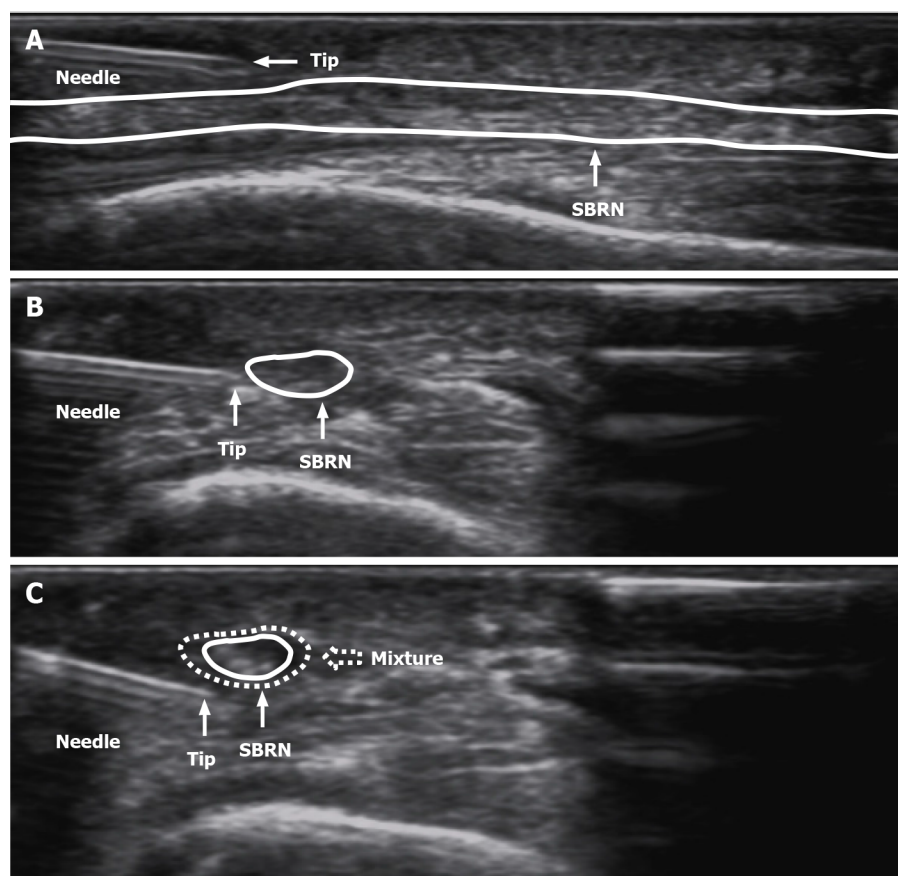


Figure 3 Procedures of ultrasound-guided needle release plus corticosteroid injection of superficial radial nerve. A: The superficial adhesion of superficial branch of radial nerve (SBRN) was separated by needle release; B: The deep adhesion of SBRN was separated by needle release; C: Injected the mixture (1 mL betamethasone and 2 mL 2% lidocaine) (white dotted arrow) around the SBRN. SBRN: Superficial branch of radial nerve.

pressure from the probe. Last, ultrasound-guided needle release has significant effect in many kinds of neural adhesion. We also tried other adhesive treatments for nerves, such as ultrasound-guided needle release of sciatic nerves and deep branches of the sciatic nerve. They all worked well.

CONCLUSION

Ultrasound is an effective method for evaluating the condition of the RN, as it can assess the RN and main terminal branches, observe any abnormalities and the relationship with surrounding tissues. Ultrasound-guided needle release plus corticosteroid injection is an effective and safe treatment for SBRN adhesion.

REFERENCES

- 1 Agarwal A, Chandra A, Jaipal U, Saini N. A panorama of radial nerve pathologies- an imaging diagnosis: a step ahead. *Insights Imaging* 2018; **9**: 1021-1034 [PMID: 30397879 DOI: 10.1007/s13244-018-0662-x]
- 2 Bodner G, Buchberger W, Schocke M, Bale R, Harpf C, Gassner E, Jäschke W. Radial nerve palsy associated with humeral shaft fracture: evaluation with US--initial experience. *Radiology* 2001; **219**: 811-816 [PMID: 11376275 DOI: 10.1148/radiology.219.3.r01jn09811]
- 3 Bianchi S. Ultrasound of the peripheral nerves. *Joint Bone Spine* 2008; **75**: 643-649 [PMID: 18823807 DOI: 10.1016/j.jbspin.2008.07.002]
- 4 Lawande AD, Warriar SS, Joshi MS. Role of ultrasound in evaluation of peripheral nerves. *Indian J Radiol Imaging* 2014; **24**: 254-258 [PMID: 25114388 DOI: 10.4103/0971-3026.137037]
- 5 Foxall GL, Skinner D, Hardman JG, Bedford NM. Ultrasound anatomy of the radial nerve in the distal upper arm. *Reg Anesth Pain Med* 2007; **32**: 217-220 [PMID: 17543816 DOI: 10.1016/j.rapm.2007.02.006]

- 6 **Jacobson JA**, Wilson TJ, Yang LJ. Sonography of Common Peripheral Nerve Disorders With Clinical Correlation. *J Ultrasound Med* 2016; **35**: 683-693 [PMID: [26931790](#) DOI: [10.7863/ultra.15.05061](#)]
- 7 **Esparza M**, Wild JR, Minnock C, Mohty KM, Truchan LM, Taljanovic MS. Ultrasound Evaluation of Radial Nerve Palsy Associated with Humeral Shaft Fractures to Guide Operative Versus Non-Operative Treatment. *Acta Med Acad* 2019; **48**: 183-192 [PMID: [31718219](#) DOI: [10.5644/ama2006-124.257](#)]
- 8 **Pollock FH**, Drake D, Bovill EG, Day L, Trafton PG. Treatment of radial neuropathy associated with fractures of the humerus. *J Bone Joint Surg Am* 1981; **63**: 239-243 [PMID: [7462281](#)]
- 9 **Bumbasirević M**, Lesić A, Bumbasirević V, Cobeljić G, Milosević I, Atkinson HD. The management of humeral shaft fractures with associated radial nerve palsy: a review of 117 cases. *Arch Orthop Trauma Surg* 2010; **130**: 519-522 [PMID: [19669771](#) DOI: [10.1007/s00402-009-0951-4](#)]
- 10 **Knutsen EJ**, Calfee RP. Uncommon upper extremity compression neuropathies. *Hand Clin* 2013; **29**: 443-453 [PMID: [23895725](#) DOI: [10.1016/j.hcl.2013.04.014](#)]



Published by **Baishideng Publishing Group Inc**
7041 Koll Center Parkway, Suite 160, Pleasanton, CA 94566, USA

Telephone: +1-925-3991568

E-mail: bpgoffice@wjgnet.com

Help Desk: <https://www.f6publishing.com/helpdesk>

<https://www.wjgnet.com>

