

World Journal of *Gastrointestinal Pharmacology and Therapeutics*

World J Gastrointest Pharmacol Ther 2022 March 5; 13(2): 11-29





ORIGINAL ARTICLE

Basic Study

- 11 Melatonin restores zinc levels, activates the Keap1/Nrf2 pathway, and modulates endoplasmic reticular stress and HSP in rats with chronic hepatotoxicity

Bona S, Fernandes SA, Moreira ACJ, Rodrigues G, Schemitt EG, Di Naso FC, Marroni CA, Marroni NP

CASE REPORT

- 23 Hypereosinophilic syndrome presenting as eosinophilic gastroenteritis disorder and splinter hemorrhages: A case report

Bhasi A, Patnaik I, Panda PK, Singh A

Contents

World Journal of Gastrointestinal Pharmacology and Therapeutics

Bimonthly Volume 13 Number 2 March 5, 2022

ABOUT COVER

Editorial Board Member of *World Journal of Gastrointestinal Pharmacology and Therapeutics*, Rahul Kumar, FRCP, MBBS, MD, Associate Professor, Department of Gastroenterology and Hepatology, Duke-NUS academic Medical Centre, Changi General Hospital, Singapore 529889, Singapore. rahul.kumar@singhealth.com.sg

AIMS AND SCOPE

The primary aim of the *World Journal of Gastrointestinal Pharmacology and Therapeutics* (WJGPT, *World J Gastrointest Pharmacol Ther*) is to provide scholars and readers from various fields of gastrointestinal pharmacology and therapeutics with a platform to publish high-quality basic and clinical research articles and communicate their research findings online.

WJGPT mainly publishes articles reporting research results obtained in the field of gastrointestinal pharmacology and therapeutics and covering a wide range of topics including acid-related disorders, functional gastrointestinal disorders, fundamentals of gastrointestinal pharmacology, etc.

INDEXING/ABSTRACTING

The WJGPT is now abstracted and indexed in PubMed, PubMed Central, Reference Citation Analysis, China National Knowledge Infrastructure, China Science and Technology Journal Database, and Superstar Journals Database.

RESPONSIBLE EDITORS FOR THIS ISSUE

Production Editor: Hua-Ge Yu; **Production Department Director:** Xiang Li; **Editorial Office Director:** Jin-Li Wang.

NAME OF JOURNAL

World Journal of Gastrointestinal Pharmacology and Therapeutics

ISSN

ISSN 2150-5349 (online)

LAUNCH DATE

May 6, 2010

FREQUENCY

Bimonthly

EDITORS-IN-CHIEF

Emanuele Sinagra

EDITORIAL BOARD MEMBERS

<https://www.wjgnet.com/2150-5349/editorialboard.htm>

PUBLICATION DATE

March 5, 2022

COPYRIGHT

© 2022 Baishideng Publishing Group Inc

INSTRUCTIONS TO AUTHORS

<https://www.wjgnet.com/bpg/gerinfo/204>

GUIDELINES FOR ETHICS DOCUMENTS

<https://www.wjgnet.com/bpg/gerinfo/287>

GUIDELINES FOR NON-NATIVE SPEAKERS OF ENGLISH

<https://www.wjgnet.com/bpg/gerinfo/240>

PUBLICATION ETHICS

<https://www.wjgnet.com/bpg/gerinfo/288>

PUBLICATION MISCONDUCT

<https://www.wjgnet.com/bpg/gerinfo/208>

ARTICLE PROCESSING CHARGE

<https://www.wjgnet.com/bpg/gerinfo/242>

STEPS FOR SUBMITTING MANUSCRIPTS

<https://www.wjgnet.com/bpg/gerinfo/239>

ONLINE SUBMISSION

<https://www.f6publishing.com>

© 2022 Baishideng Publishing Group Inc. All rights reserved. 7041 Koll Center Parkway, Suite 160, Pleasanton, CA 94566, USA

E-mail: bpgoffice@wjgnet.com <https://www.wjgnet.com>



Hypereosinophilic syndrome presenting as eosinophilic gastroenteritis disorder and splinter hemorrhages: A case report

Ankith Bhasi, Itish Patnaik, Prasan Kumar Panda, Ashok Singh

Specialty type: Allergy

Provenance and peer review:

Unsolicited article; Externally peer reviewed.

Peer-review model: Single blind

Peer-review report's scientific quality classification

Grade A (Excellent): 0

Grade B (Very good): 0

Grade C (Good): C, C

Grade D (Fair): 0

Grade E (Poor): 0

P-Reviewer: Ferrarese A

Received: August 2, 2021

Peer-review started: August 2, 2021

First decision: October 15, 2021

Revised: October 31, 2021

Accepted: January 22, 2022

Article in press: January 22, 2022

Published online: March 5, 2022



Ankith Bhasi, Prasan Kumar Panda, Department of Internal Medicine, All India Institute of Medical Sciences, Rishikesh 249203, Uttarakhand, India

Itish Patnaik, Department of Gastroenterology, All India Institute of Medical Sciences, Rishikesh 249203, India

Ashok Singh, Department of Pathology, All India Institute of Medical Sciences, Rishikesh 249203, India

Corresponding author: Prasan Kumar Panda, MBBS, MD, Associate Professor, Department of Internal Medicine, All India Institute of Medical Sciences, Rishikesh 249203, Uttarakhand, India. motherprasanna@rediffmail.com

Abstract

BACKGROUND

Eosinophilia and related organ damage are extensively studied hot topics among rare disorders. Any addition to the cohort of available case reports of the same will be adding knowledge for better management of this less known entity.

CASE SUMMARY

In this article, we describe a 27-year-old Indo-Aryan man who presented with abdominal pain, abdominal distension, and loose stools for variable days. He had splinter hemorrhages in the majority of fingernails. He was diagnosed with predominant eosinophilic gastrointestinal involvement with bowel obstruction and ascites, and was managed with intravenous immunoglobulin. He was subsequently treated with oral low dose steroid therapy and responded completely.

CONCLUSION

Our experience is evidence that prompt management of this hypereosinophilic lethal gastrointestinal (all three layers) infiltrative disease provides a cure and avoids complications. Splinter nail hemorrhages may be seen in the same disease.

Key Words: Ascites; Diarrhea; Eosinophilia; Intravenous immunoglobulin; Leucoproliferative disorder; Case report

©The Author(s) 2022. Published by Baishideng Publishing Group Inc. All rights reserved.

Core Tip: This case reveals the wide spectrum of atypical manifestations of hyper-eosinophilic syndrome. Clinicians must be vigilant in order to diagnose primary instead of secondary eosinophilia as the former can cause diffuse organ infiltration and widespread tissue damage. Eosinophilic gastrointestinal disorder can present with involvement of all three layers of the gastrointestinal tract. Hypereosinophilic syndrome can also present with splinter hemorrhages. Prompt management of this lethal infiltrative disease provides a cure and avoids organ complications.

Citation: Bhasi A, Patnaik I, Panda PK, Singh A. Hypereosinophilic syndrome presenting as eosinophilic gastroenteritis disorder and splinter hemorrhages: A case report. *World J Gastrointest Pharmacol Ther* 2022; 13(2): 23-29

URL: <https://www.wjgnet.com/2150-5349/full/v13/i2/23.htm>

DOI: <https://dx.doi.org/10.4292/wjgpt.v13.i2.23>

INTRODUCTION

Hypereosinophilic syndrome (HES) is an idiopathic, less defined, less known, primary leuco-proliferative disorder associated with peripheral blood eosinophilia and organ damage. The term HES was first used by Anderson[1] in 1968 in a case series, and since then, there have been considerable improvements in the understanding and hence changes in the definition and criteria for the diagnosis of this syndrome. The old definition (1975, Chusid *et al*[2]) included persistent blood eosinophilia $\geq 1.5 \times 10^9/L$ lasting for > 6 mo, associated with eosinophil-mediated organ damage. However, the new definition (2010, Simon *et al*[3]) includes more than peripheral blood eosinophilia or duration of symptoms, and the evidence of eosinophil-mediated organ damage is enough for diagnosis of HES.

Presentations may vary, and can be organ-specific, may present as a myeloproliferative disorder, or may be asymptomatic. Treatment guidelines are not yet defined. Patients mostly present with organ damage in organ-specific eosinophilia syndrome and thus require an immediate intensive phase treatment to avoid organ failure and then a continuous phase of immunomodulator or steroids to avoid recurrences.

Eosinophilic gastroenteritis is a term reserved for an entity, where there is eosinophilic inflammation of more than one histologically distinct anatomic location in the gut[4]. Clinical presentation depends on the anatomical site and histological layer of the gut. The presentation can be as mild and chronic as dyspepsia, nausea, diarrhea, or as a differential for protein-losing enteropathy with mucosal layer involvement to as severe as crampy abdominal pain and intestinal obstruction with muscular layer involvement. The least common serosal type presents with eosinophilic ascites and abundant peripheral eosinophilia or rarely in severe cases as perforation[5].

Here we report a case of HES who presented with abdominal pain, distension, diarrhea, and splinter hemorrhages.

CASE PRESENTATION

Chief complaints

A 27-year-old Indo-Aryan man, resident of North-India, an electrician by profession, without addictions or co-morbidities presented with abdominal pain of 20 d, abdominal distension of 10 d, and loose stools of 3 d.

History of present illness

Abdominal pain was a continuous dull ache around the umbilicus. The pain became intermittent associated with the non-passage of flatus and feeling of fullness in the abdomen that was relieved with passage of flatus after some time. In the previous 10 d he had abdominal distension, which started around the left flank, and progressed to involve the whole abdomen. He had no vomiting, fever, jaundice, significant weight loss, urinary problems, chest problems, or lower limb swelling. Reports from outside our hospital showed eosinophilia (absolute count, $11400/\mu L$).

History of past illness

He had no allergic tendency, pruritus ani, any recent intake of drugs, or B symptoms.

Personal and family history

No history of atopy in his family and no history suggestive of the same.

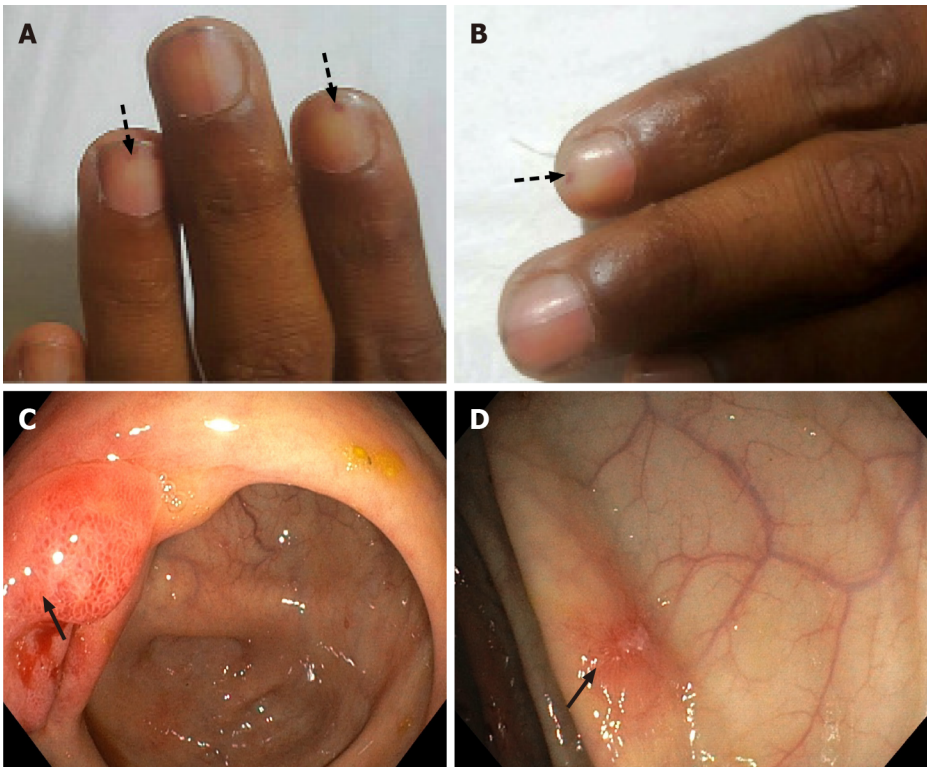


Figure 1 Cutaneous manifestations and endoscopic findings in the patient with eosinophilic gastrointestinal disorder. A and B: Sections show splinter hemorrhages (arrows) in different nails; C and D: Show terminal ileum and colonic mucosal erythematous erosions (arrows).

Physical examination

On examination, he was of average built (body mass index, 22 kg/m²) with stable vitals. His local examination revealed splinter hemorrhages in digital nails (Figure 1A and B); however, fundoscopy did not show any Roth spots. Abdominal examination showed a distended abdomen with shifting dullness and sluggish bowel sounds without organomegaly or any stigmata of chronic liver disease. His systemic examination was non-contributory.

Laboratory examinations

His initial hemogram showed a leucocyte count of 33000/ μ L (absolute eosinophil count, 25000/ μ L) and normal hemoglobin and platelet count. Peripheral smear confirmed eosinophilic leukocytosis without any blasts or hemiparasites. Midnight diethyl carbamazine provocation test was negative (diethyl carbamazine single dose 300 mg at midnight to increase yield). His kidney and liver functions were essentially normal. Total IgE was 830 kUA/L (normal range, < 64 kUA/L). The ascitic fluid study revealed low SAAG ascites (ascitic albumin: 2.9 g/dL and SAAG: 0.7 g/dL) with raised leukocyte count (6000 cells/mm³) and numerous eosinophils (95% polymorphs and 5% monomorphs) and reactive mesothelial cells. Multiple stool microscopy samples were obtained, however no evidence of parasites was observed.

Imaging examinations

Ultrasonography of the abdomen showed ascites with multiple echogenic foci (septated) and few subcentimetric mesenteric lymph nodes. ECG and chest X-ray were normal. A contrast-enhanced computed tomography (CT) of the abdomen was performed to rule out any occult abdominal pathology, which revealed diffuse bowel wall thickening and submucosal edema. Both upper gastrointestinal (GI) endoscopy and colonoscopy were performed and showed erythematous mucosa (Figure 1C and D). The biopsy from multiple sites (antrum, duodenum, ileum, cecum, rectum) revealed eosinophilic infiltration in the lamina propria with dense infiltration of muscularis mucosa at the terminal ileum (Figure 2). His esophageal biopsies were essentially normal.

FINAL DIAGNOSIS

At initial evaluation, differentials were parasitic infiltrations with secondary eosinophilia *vs* hyper-eosinophilic gastroenteritis *vs* hyper IgE syndrome. However, after all the investigations, the patient

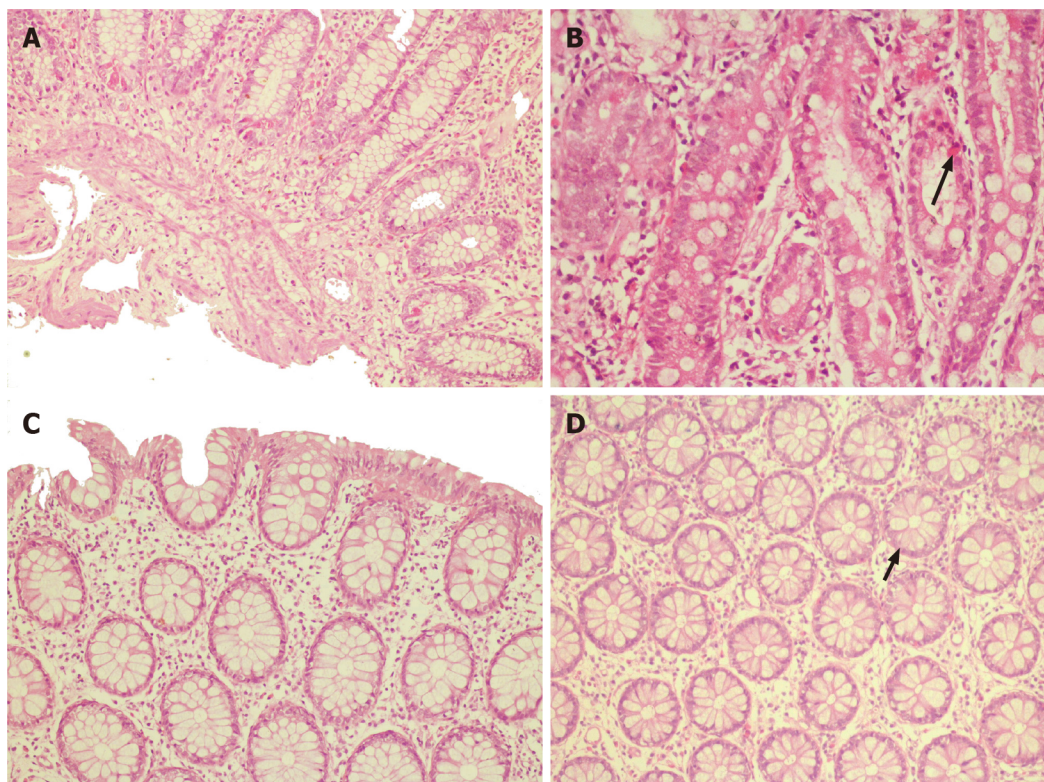


Figure 2 Histopathology images. A: Terminal ileal/ileocecal biopsy section shows mucosal lining with marked eosinophil rich infiltrates in the lamina propria. The eosinophils infiltrate the muscularis mucosae; B: Higher magnification (400×) of the duodenum section shows the infiltration of crypt epithelium by eosinophils (arrow); C: Section from the ascending colon lamina propria shows a mild increase in eosinophils; however, no cryptitis or crypt abscess is seen; D: Higher magnification (400×) of the rectum shows crypt lining epithelium infiltrated by eosinophils (arrow).

was confirmed to have hypereosinophilic syndrome presenting as eosinophilic gastroenteritis disorder (EGD) with atypical splinter hemorrhages.

TREATMENT

He was started on intravenous immunoglobulin (IVIG) at a total dose of 2 gm/kg divided over 5 d, after which he showed significant symptom improvement. He was started on a six food elimination diet (cow's milk, soy, wheat, egg, peanut, seafood/shellfish). His abdominal girth had reduced from 96 cm to 81 cm at discharge. His eosinophilic count also reduced to 1200/ μ L.

He was discharged on oral prednisolone 30 mg/d and planned to taper off.

OUTCOME AND FOLLOW-UP

In his last follow-up after 2-mo, there was no evidence of ascites or splinter hemorrhages. He has resumed work with normal eosinophil counts on low-dose steroid (prednisolone 10 mg/d) and plans to stop the steroid after 6-mo with a wait and watch policy.

DISCUSSION

This particular case revealed two major findings concerning HES. One is EGD and the other is splinter hemorrhages. EGD is proposed to have a centrifugal eosinophilic infiltrate starting from the mucosa to serosa evidenced by the fact that the disease with serosal and muscular types always has mucosal involvement[6]. This case had symptoms suggestive of the involvement of all the three layers of the GI tract: Diarrhea and hypoalbuminemia suggestive of mucosal involvement, intestinal obstruction, and related symptoms suggestive of muscular involvement, and exudative ascites suggestive of serosal involvement. Such extensive symptomatology, whether reported in a single case or not is to our knowledge unknown. The classification or therapeutic guideline for HES is still limited as most review

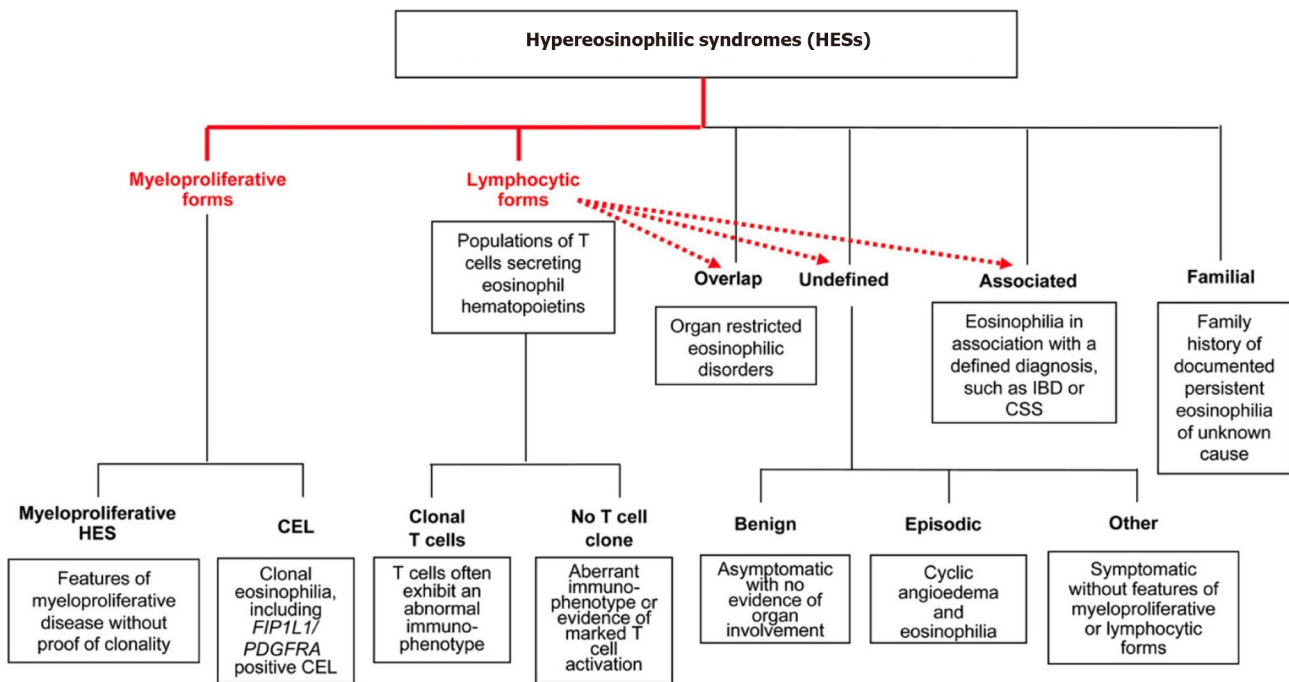


Figure 3 The classification of hypereosinophilic syndrome as per Simon *et al*[3]. CSS: Cyberchondria severity scale; IBD: Inflammatory bowel disease; HES: Hypereosinophilic syndrome; CEL: Carboxyl ester lipase. Citation: Simon HU, Rothenberg ME, Bochner BS, Weller PF, Wardlaw AJ, Wechsler ME, Rosenwasser LJ, Roufosse F, Gleich GJ, Klion AD. Refining the definition of hypereosinophilic syndrome. *J Allergy Clin Immunol* 2010; 126: 45-49.

articles are based on case reports and case series. To date, no randomized studies have been carried out in the adult population regarding management. Simon *et al*[3] classified HES into multiple independent categories based on clinical manifestations and pathogenesis (Figure 3). Lymphoproliferative HES is associated with increased production of eosinophil hematopoietin (mainly IL-5) by activated T-lymphocytes[7]. Another feature associated with the same is increased levels of serum IgE, dermatologic manifestations, and gastrointestinal symptoms. Hence our case could be a type of this variety. Other types such as undefined and organ-specific variants are also associated with a similar pathogenesis, lymphocyte-mediated increased eosinophil hematopoietin production, and related eosinophilic infiltration and organ damage[8]. These variants are responsive to immunosuppressive therapy, both to steroids and steroid-sparing immunomodulatory agents.

Eosinophilic gastroenteritis was first reported in 1937; however, the pathogenesis and management are unknown. There are two main reasons for this apparent contradiction. Firstly, it presents just like any other GI disorder with heterogeneous and nonspecific symptoms and is thus under-diagnosed. Secondly, it is a less prevalent disease[4]. The pathogenesis of EGD is complex and multifactorial. A trigger factor such as a food allergen, helminth, or bacterial infection is often involved, leading to and IL-5 mediated eosinophilic recruitment to the GI tract. The eosinophil-mast cell axis is a known factor involved in functional GI disorder[4]. Activated mast cells secrete histamine and serotonin, which results in visceral sensitivity and motility disorder. The same axis is proposed to function in EGD. EGD can be associated with or without peripheral eosinophilia and diagnosis thus remains tricky. In the presence of ascites, a diagnostic tap showing exudative ascites with eosinophilia is suggestive of the disease[9]. Endoscopy guided biopsy is a useful test; however, patchy involvement of the GI tract means that diagnosis can be missed in 25% of cases[10]. In such cases, CT imaging is useful to identify thickened bowel areas where a surgical biopsy can be attempted[11]. Small bowel MRI, as well as CT scanning, are nonspecific in diagnosing eosinophilic gastroenteritis and use of imaging is to guide biopsies. Presently, no studies comparing the diagnostic accuracy of these procedures are available. Capsule endoscopy[12] may be used to detect eosinophilic gastroenteritis as it may provide clues for lesions in the small bowel which may be difficult to diagnose with conventional endoscopy; however, studies pertaining to the same are not available.

Subungual splinter hemorrhages are vertical hemorrhages occurring in the capillary loops of the nail. Their association with an eosinophilic syndrome was provided in a case report of eosinophilic endomyocarditis[13]. Their association with HES or EGD has not been reported to date. The pathogenesis is questionable as cutaneous manifestations of HES are related to dermal microthrombosis. Usual cutaneous manifestations are angioedema, erythematous pruritic papules and nodules, generalized erythroderma, and blistering skin lesions in the form of vesiculobullous lesions[14]. In infective endocarditis, splinter hemorrhages are thought to be due to the embolic phenomenon and subsequent hemorrhagic changes[15]. Thus, hemorrhagic changes on microthrombosis can be the reason for splinter hemorrhages in HES but further research and clarification are needed.

EGD is still a novel disease requiring extensive research for further knowledge expansion. Until then treatment is based primarily on clinician experience. Treatment strategies involve immunosuppression with corticosteroids, leukotriene receptor antagonists, mast cell stabilizers, antihistamines, or treatment with immunomodulators such as 6-mercaptopurine and azathioprine. Novel therapies include biologicals like Reslizumab (IL5 antagonist), Infliximab (TNF alpha inhibitor), Omalizumab (a monoclonal antibody against IgE), or IVIG[4]. Our patient presented with alarming symptoms of bowel obstruction and exudative ascites, hence we preferred to start him on IVIG therapy, to which he responded, potentially avoiding surgical intervention, and then started him on oral prednisolone therapy. Hence, we suggest the use of IVIG therapy in patients with alarming symptoms for rapid response. However, this was a single case report and hence requires blinded, prospective and randomized studies to determine the efficacy of IVIG for HES.

CONCLUSION

Our experience provides evidence that prompt management of this infiltrative disease offers a cure and avoids organ complications. Clinicians must be vigilant in order to diagnose primary instead of secondary eosinophilia as the former can cause diffuse organ infiltration and widespread tissue damage. EGD can present with the involvement of all three layers of the GI tract. HES can also present with splinter hemorrhages.

FOOTNOTES

Author contributions: Bhasi A collected all data; Bhasi A, Panda PK and Singh A wrote the manuscript; Bhasi A, Patnaik I and Singh A contributed to the analysis; Bhasi A, Patnaik I, Panda PK, and Singh A contributed to approval; Patnaik I collected endoscopy data, reviewed the manuscript; Panda PK collected data, critically reviewed; Singh A collected pathology data.

Informed consent statement: The patient gave informed consent to share his clinical images and details including laboratory reports.

Conflict-of-interest statement: The authors declare that they have no conflict of interest.

CARE Checklist (2016) statement: The authors have read the CARE Checklist (2016), and the manuscript was prepared and revised according to the CARE Checklist (2016).

Open-Access: This article is an open-access article that was selected by an in-house editor and fully peer-reviewed by external reviewers. It is distributed in accordance with the Creative Commons Attribution NonCommercial (CC BY-NC 4.0) license, which permits others to distribute, remix, adapt, build upon this work non-commercially, and license their derivative works on different terms, provided the original work is properly cited and the use is non-commercial. See: <http://creativecommons.org/licenses/by-nc/4.0/>

Country/Territory of origin: India

ORCID number: Ankith Bhasi 0000-0002-2366-397X; Itish Patnaik 0000-0003-2726-3516; Prasan Kumar Panda 0000-0002-3008-7245; Ashok Singh 0000-0001-8778-7958.

S-Editor: Liu JH

L-Editor: Webster JR

P-Editor: Liu JH

REFERENCES

- 1 Anderson RE. The hypereosinophilic syndromes. *Aun Intern Med* 1968; **68**: 1220
- 2 Chusid MJ, Dale DC, West BC, Wolff SM. The hypereosinophilic syndrome: analysis of fourteen cases with review of the literature. *Medicine (Baltimore)* 1975; **54**: 1-27 [PMID: 1090795]
- 3 Simon HU, Rothenberg ME, Bochner BS, Weller PF, Wardlaw AJ, Wechsler ME, Rosenwasser LJ, Roufosse F, Gleich GJ, Klion AD. Refining the definition of hypereosinophilic syndrome. *J Allergy Clin Immunol* 2010; **126**: 45-49 [PMID: 20639008 DOI: 10.1016/j.jaci.2010.03.042]
- 4 Sunkara T, Rawla P, Yarlagadda KS, Gaduputi V. Eosinophilic gastroenteritis: diagnosis and clinical perspectives. *Clin Exp Gastroenterol* 2019; **12**: 239-253 [PMID: 31239747 DOI: 10.2147/CEG.S173130]
- 5 Chen MJ, Chu CH, Lin SC, Shih SC, Wang TE. Eosinophilic gastroenteritis: clinical experience with 15 patients. *World J Gastroenterol* 2003; **9**: 2813-2816 [PMID: 14669340 DOI: 10.3748/wjg.v9.i12.2813]

- 6 **Chang JY**, Choung RS, Lee RM, Locke GR 3rd, Schleck CD, Zinsmeister AR, Smyrk TC, Talley NJ. A shift in the clinical spectrum of eosinophilic gastroenteritis toward the mucosal disease type. *Clin Gastroenterol Hepatol* 2010; **8**: 669-75; quiz e88 [PMID: [20451664](#) DOI: [10.1016/j.cgh.2010.04.022](#)]
- 7 **Roufosse F**, Cogan E, Goldman M. Lymphocytic variant hypereosinophilic syndromes. *Immunol Allergy Clin North Am* 2007; **27**: 389-413 [PMID: [17868856](#) DOI: [10.1016/j.jiac.2007.07.002](#)]
- 8 **Simon D**, Simon HU. Eosinophilic disorders. *J Allergy Clin Immunol* 2007; **119**: 1291-300; quiz 1301 [PMID: [17399779](#) DOI: [10.1016/j.jaci.2007.02.010](#)]
- 9 **Harmon WA**, Helman CA. Eosinophilic gastroenteritis and ascites. *J Clin Gastroenterol* 1981; **3**: 371-373 [PMID: [7338618](#) DOI: [10.1097/00004836-198112000-00013](#)]
- 10 **Talley NJ**, Shorter RG, Phillips SF, Zinsmeister AR. Eosinophilic gastroenteritis: a clinicopathological study of patients with disease of the mucosa, muscle layer, and subserosal tissues. *Gut* 1990; **31**: 54-58 [PMID: [2318432](#) DOI: [10.1136/gut.31.1.54](#)]
- 11 **Wiesner W**, Kocher T, Heim M, Bongartz G. CT findings in eosinophilic enterocolitis with predominantly serosal and muscular bowel wall infiltration. *JBR-BTR* 2002; **85**: 4-6 [PMID: [11936478](#)]
- 12 **Herrera Quiñones G**, Scharrer SI, Jiménez Rodríguez AR, García Compean D, Borjas Almaguer OD, Martínez Segura JA, Jáquez Quintana JO, González González JA, Maldonado Garza HJ. Diagnosis of Eosinophilic Enteritis With Video Capsule Endoscopy and Double Balloon Enteroscopy With Favorable Response to Corticosteroids. *ACG Case Rep J* 2019; **6**: e00127 [PMID: [31620526](#) DOI: [10.14309/crj.0000000000000127](#)]
- 13 **Usui S**, Dainichi T, Kitoh A, Miyachi Y, Kabashima K. Janeway Lesions and Splinter Hemorrhages in a Patient With Eosinophilic Endomyocarditis. *JAMA Dermatol* 2015; **151**: 907-908 [PMID: [25924060](#) DOI: [10.1001/jamadermatol.2015.0388](#)]
- 14 **Weller PF**, Bubley GJ. The idiopathic hypereosinophilic syndrome. *Blood* 1994; **83**: 2759-2779 [PMID: [8180373](#)]
- 15 **Kilpatrick ZM**, Greenberg PA, Sanford JP. Splinter hemorrhages--their clinical significance. *Arch Intern Med* 1965; **115**: 730-735 [PMID: [14299446](#) DOI: [10.1001/archinte.1960.03860180102019](#)]



Published by **Baishideng Publishing Group Inc**
7041 Koll Center Parkway, Suite 160, Pleasanton, CA 94566, USA

Telephone: +1-925-3991568

E-mail: bpgoffice@wjgnet.com

Help Desk: <https://www.f6publishing.com/helpdesk>

<https://www.wjgnet.com>

