

# World Journal of *Clinical Cases*

*World J Clin Cases* 2022 February 6; 10(4): 1140-1456



## Contents

Thrice Monthly Volume 10 Number 4 February 6, 2022

### REVIEW

- 1140** COVID-19: Gastrointestinal manifestations, liver injury and recommendations  
*Ozkurt Z, Çınar Tanrıverdi E*

### ORIGINAL ARTICLE

#### Retrospective Study

- 1164** Continuous intravenous infusion of recombinant human endostatin using infusion pump plus chemotherapy in non-small cell lung cancer  
*Qin ZQ, Yang SF, Chen Y, Hong CJ, Zhao TW, Yuan GR, Yang L, Gao L, Wang X, Lu LQ*
- 1172** Sequential sagittal alignment changes in the cervical spine after occipitocervical fusion  
*Zhu C, Wang LN, Chen TY, Mao LL, Yang X, Feng GJ, Liu LM, Song YM*
- 1182** Importance of the creation of a short musculofascial tunnel in peritoneal dialysis catheter placement  
*Lee CY, Tsai MK, Chen YT, Zhan YJ, Wang ML, Chen CC*
- 1190** Clinical effect of methimazole combined with selenium in the treatment of toxic diffuse goiter in children  
*Zhang XH, Yuan GP, Chen TL*
- 1198** Clinical study on the minimally invasive percutaneous nephrolithotomy treatment of upper urinary calculi  
*Xu XJ, Zhang J, Li M, Hou JQ*

#### Observational Study

- 1206** Comparison of diagnostic validity of two autism rating scales for suspected autism in a large Chinese sample  
*Chu JH, Bian F, Yan RY, Li YL, Cui YH, Li Y*
- 1217** Doctor-led intensive diet education on health-related quality of life in patients with chronic renal failure and hyperphosphatemia  
*Feng XD, Xie X, He R, Li F, Tang GZ*

### SYSTEMATIC REVIEWS

- 1226** What are the self-management experiences of the elderly with diabetes? A systematic review of qualitative research  
*Li TJ, Zhou J, Ma JJ, Luo HY, Ye XM*

### META-ANALYSIS

- 1242** Comparison of the clinical performance of i-gel and Ambu laryngeal masks in anaesthetised paediatric patients: A meta-analysis  
*Bao D, Yu Y, Xiong W, Wang YX, Liang Y, Li L, Liu B, Jin X*

## CASE REPORT

- 1255** Autogenous iliotibial band enhancement combined with tendon lengthening plasty to treat patella baja: A case report  
*Tang DZ, Liu Q, Pan JK, Chen YM, Zhu WH*
- 1263** Sintilimab-induced autoimmune diabetes: A case report and review of the literature  
*Yang J, Wang Y, Tong XM*
- 1278** Unicentric Castleman disease was misdiagnosed as pancreatic mass: A case report  
*Zhai HY, Zhu XY, Zhou GM, Zhu L, Guo DD, Zhang H*
- 1286** Iguratimod in treatment of primary Sjögren's syndrome concomitant with autoimmune hemolytic anemia: A case report  
*Zhang J, Wang X, Tian JJ, Zhu R, Duo RX, Huang YC, Shen HL*
- 1291** Primary central nervous system lymphoma presenting as a single choroidal lesion mimicking metastasis: A case report  
*Jang HR, Lim KH, Lee K*
- 1296** Surgical treatment of acute cholecystitis in patients with confirmed COVID-19: Ten case reports and review of literature  
*Bozada-Gutiérrez K, Trejo-Avila M, Chávez-Hernández F, Parraguirre-Martínez S, Valenzuela-Salazar C, Herrera-Esquivel J, Moreno-Portillo M*
- 1311** Hydrogen inhalation promotes recovery of a patient in persistent vegetative state from intracerebral hemorrhage: A case report and literature review  
*Huang Y, Xiao FM, Tang WJ, Qiao J, Wei HF, Xie YY, Wei YZ*
- 1320** Ultrasound-guided needle release plus corticosteroid injection of superficial radial nerve: A case report  
*Zeng Z, Chen CX*
- 1326** Inverted Y ureteral duplication with an ectopic ureter and multiple urinary calculi: A case report  
*Ye WX, Ren LG, Chen L*
- 1333** Multiple miscarriages in a female patient with two-chambered heart and situs inversus totalis: A case report  
*Duan HZ, Liu JJ, Zhang XJ, Zhang J, Yu AY*
- 1341** Chidamide combined with traditional chemotherapy for primary cutaneous aggressive epidermotropic CD8+ cytotoxic T-cell lymphoma: A case report  
*He ZD, Yang HY, Zhou SS, Wang M, Mo QL, Huang FX, Peng ZG*
- 1349** Fatal rhabdomyolysis and disseminated intravascular coagulation after total knee arthroplasty under spinal anesthesia: A case report  
*Yun DH, Suk EH, Ju W, Seo EH, Kang H*
- 1357** Left atrial appendage occlusion in a mirror-image dextrocardia: A case report and review of literature  
*Tian B, Ma C, Su JW, Luo J, Sun HX, Su J, Ning ZP*

- 1366** Imaging presentation of biliary adenofibroma: A case report  
*Li SP, Wang P, Deng KX*
- 1373** Multiple gouty tophi in the head and neck with normal serum uric acid: A case report and review of literatures  
*Song Y, Kang ZW, Liu Y*
- 1381** Toxic epidermal necrolysis induced by ritodrine in pregnancy: A case report  
*Liu WY, Zhang JR, Xu XM, Ye TY*
- 1388** Direct antiglobulin test-negative autoimmune hemolytic anemia in a patient with  $\beta$ -thalassemia minor during pregnancy: A case report  
*Zhou Y, Ding YL, Zhang LJ, Peng M, Huang J*
- 1394** External penetrating laryngeal trauma caused by a metal fragment: A Case Report  
*Qiu ZH, Zeng J, Zuo Q, Liu ZQ*
- 1401** Antegrade in situ laser fenestration of aortic stent graft during endovascular aortic repair: A case report  
*Wang ZW, Qiao ZT, Li MX, Bai HL, Liu YF, Bai T*
- 1410** Hoffa's fracture in an adolescent treated with an innovative surgical procedure: A case report  
*Jiang ZX, Wang P, Ye SX, Xie XP, Wang CX, Wang Y*
- 1417** Hemizygous deletion in the OTC gene results in ornithine transcarbamylase deficiency: A case report  
*Wang LP, Luo HZ, Song M, Yang ZZ, Yang F, Cao YT, Chen J*
- 1423** Langerhans cell histiocytosis presenting as an isolated brain tumour: A case report  
*Liang HX, Yang YL, Zhang Q, Xie Z, Liu ET, Wang SX*
- 1432** Inflammatory myofibroblastic tumor after breast prosthesis: A case report and literature review  
*Zhou P, Chen YH, Lu JH, Jin CC, Xu XH, Gong XH*
- 1441** Eustachian tube involvement in a patient with relapsing polychondritis detected by magnetic resonance imaging: A case report  
*Yunaiyama D, Aoki A, Kobayashi H, Someya M, Okubo M, Saito K*
- 1447** Endoscopic clipping for the secondary prophylaxis of bleeding gastric varices in a patient with cirrhosis: A case report  
*Yang GC, Mo YX, Zhang WH, Zhou LB, Huang XM, Cao LM*

**LETTER TO THE EDITOR**

- 1454** Rituximab as a treatment for human immunodeficiency virus-associated nemaline myopathy: What does the literature have to tell us?  
*Gonçalves Júnior J, Shinjo SK*



**ABOUT COVER**

Editorial Board Member of *World Journal of Clinical Cases*, Nicoleta-Monica Popa-Fotea, MD, PhD, Assistant Professor, Department of Cardio-thoracic, University of Medicine and Pharmacy, Bucharest 050474, Romania. nicoleta.popa-fotea@drd.umfcd.ro

**AIMS AND SCOPE**

The primary aim of *World Journal of Clinical Cases* (WJCC, *World J Clin Cases*) is to provide scholars and readers from various fields of clinical medicine with a platform to publish high-quality clinical research articles and communicate their research findings online.

WJCC mainly publishes articles reporting research results and findings obtained in the field of clinical medicine and covering a wide range of topics, including case control studies, retrospective cohort studies, retrospective studies, clinical trials studies, observational studies, prospective studies, randomized controlled trials, randomized clinical trials, systematic reviews, meta-analysis, and case reports.

**INDEXING/ABSTRACTING**

The WJCC is now indexed in Science Citation Index Expanded (also known as SciSearch®), Journal Citation Reports/Science Edition, Scopus, PubMed, and PubMed Central. The 2021 Edition of Journal Citation Reports® cites the 2020 impact factor (IF) for WJCC as 1.337; IF without journal self cites: 1.301; 5-year IF: 1.742; Journal Citation Indicator: 0.33; Ranking: 119 among 169 journals in medicine, general and internal; and Quartile category: Q3. The WJCC's CiteScore for 2020 is 0.8 and Scopus CiteScore rank 2020: General Medicine is 493/793.

**RESPONSIBLE EDITORS FOR THIS ISSUE**

Production Editor: Hua-Ge Yin; Production Department Director: Xu Guo; Editorial Office Director: Jin-Lei Wang.

**NAME OF JOURNAL**

*World Journal of Clinical Cases*

**ISSN**

ISSN 2307-8960 (online)

**LAUNCH DATE**

April 16, 2013

**FREQUENCY**

Thrice Monthly

**EDITORS-IN-CHIEF**

Bao-Gan Peng, Jerzy Tadeusz Chudek, George Kontogeorgos, Maurizio Serati, Ja Hyeon Ku

**EDITORIAL BOARD MEMBERS**

<https://www.wjgnet.com/2307-8960/editorialboard.htm>

**PUBLICATION DATE**

February 6, 2022

**COPYRIGHT**

© 2022 Baishideng Publishing Group Inc

**INSTRUCTIONS TO AUTHORS**

<https://www.wjgnet.com/bpg/gerinfo/204>

**GUIDELINES FOR ETHICS DOCUMENTS**

<https://www.wjgnet.com/bpg/GerInfo/287>

**GUIDELINES FOR NON-NATIVE SPEAKERS OF ENGLISH**

<https://www.wjgnet.com/bpg/gerinfo/240>

**PUBLICATION ETHICS**

<https://www.wjgnet.com/bpg/GerInfo/288>

**PUBLICATION MISCONDUCT**

<https://www.wjgnet.com/bpg/gerinfo/208>

**ARTICLE PROCESSING CHARGE**

<https://www.wjgnet.com/bpg/gerinfo/242>

**STEPS FOR SUBMITTING MANUSCRIPTS**

<https://www.wjgnet.com/bpg/GerInfo/239>

**ONLINE SUBMISSION**

<https://www.f6publishing.com>



## Left atrial appendage occlusion in a mirror-image dextrocardia: A case report and review of literature

Bei Tian, Chuang Ma, Jin-Wen Su, Jun Luo, Hong-Xia Sun, Jie Su, Zhong-Ping Ning

**ORCID number:** Bei Tian 0000-0002-2797-6084; Chuang Ma 0000-0001-9747-4189; Jin-Wen Su 0000-0001-5461-572X; Jun Luo 0000-0002-1274-5910; Hong-Xia Sun 0000-0002-2855-3577; Jie Su 0000-0003-2978-2942; Zhong-Ping Ning 0000-0002-1490-2385.

**Author contributions:** Ning ZP supervised the team efforts; Tian B, Sun HX, and Luo J served as the surgical nurses; Tian B and Su J performed the data review and provided guidance on preparation of the case report; Tian B performed the video production; Tian B, Ma C, and Su J performed the data collection and writing of the manuscript.

**Informed consent statement:** Informed written consent was obtained from the patient for publication of this report and any accompanying images.

**Conflict-of-interest statement:** The authors declare that they have no conflict of interest.

**CARE Checklist (2016) statement:** The authors have read the CARE Checklist (2016), and the manuscript was prepared and revised according to the CARE Checklist (2016).

**Supported by** Pudong New Area Science and Technology

**Bei Tian, Jin-Wen Su, Jun Luo, Hong-Xia Sun, Zhong-Ping Ning,** Zhoupu Hospital Shanghai University of Medicine & Health Sciences, Shanghai University of Traditional Chinese Medicine, Shanghai 200437, China

**Chuang Ma,** Longhua Hospital Shanghai University of Traditional Chinese Medicine, Shanghai University of Traditional Chinese Medicine, Shanghai 200437, China

**Jie Su,** Shache County People's Hospital, Kashgar 200437, Xinjiang Uygur Autonomous Region, China

**Corresponding author:** Zhong-Ping Ning, MD, Chief Physician, Zhoupu Hospital Shanghai University of Medicine & Health Sciences, Shanghai University of Traditional Chinese Medicine, No. 650 South Wanping Road, Shanghai 200437, China.  
[ningzhongping88@163.com](mailto:ningzhongping88@163.com)

### Abstract

#### BACKGROUND

In mirror-image dextrocardia, the anterior-posterior position of the cardiac chambers and great vessels is maintained, but the left-right orientation of the abdominal organs is reversed. The abnormal anatomy of the heart poses surgical challenges and problems in dealing with surgical risk and monitoring complications. There are few reports on closure of the left atrial appendage (LAA) in dextrocardia and no reports on the application of enhanced recovery after surgery (ERAS) following LAA occlusion (LAAO) procedures.

#### CASE SUMMARY

The objective for this case was to ensure perioperative safety and accelerate postoperative recovery from LAAO in a patient with mirror-image dextrocardia. ERAS was guided by the theory and practice of nursing care. Atrial fibrillation was diagnosed in a 77-year-old male patient, in whom LAAO was performed. The 2019 guidelines for perioperative care after cardiac surgery recommend that the clinical nursing procedures for patients with LAAO should be optimized to reduce the incidence of perioperative complications and ensure patient safety. Music therapy can be used throughout perioperative treatment and nursing to improve the anxiety symptoms of patients.

#### CONCLUSION

The procedure was uneventful and proceeded without complications. Anxiety symptoms were improved.

Development Fund Livelihood Scientific Research Project: Medical and Health, No. PKJ2020-Y106; Shanghai Pudong New District Medical Discipline Construction Project C Cardiovascular Internal Medicine Clinical Plateau Discipline, No. PWYgy2018-03; Shanghai Key Medical Specialty Construction Project, No. ZK2019B25; and Scientific Research Project of Shanghai Municipal Health and Family Planning Commission (Youth Project), No. 20184Y0230.

**Country/Territory of origin:** China

**Specialty type:** Cardiac and cardiovascular systems

**Provenance and peer review:** Unsolicited article; Externally peer reviewed.

**Peer-review model:** Single blind

#### Peer-review report's scientific quality classification

Grade A (Excellent): 0  
Grade B (Very good): 0  
Grade C (Good): 0  
Grade D (Fair): 0  
Grade E (Poor): 0

**Open-Access:** This article is an open-access article that was selected by an in-house editor and fully peer-reviewed by external reviewers. It is distributed in accordance with the Creative Commons Attribution NonCommercial (CC BY-NC 4.0) license, which permits others to distribute, remix, adapt, build upon this work non-commercially, and license their derivative works on different terms, provided the original work is properly cited and the use is non-commercial. See: <http://creativecommons.org/licenses/by-nc/4.0/>

**Received:** August 11, 2021

**Peer-review started:** August 11, 2021

**First decision:** September 2, 2021

**Revised:** September 22, 2021

**Accepted:** December 23, 2021

**Article in press:** December 23, 2021

**Published online:** February 6, 2022

**Key Words:** Atrial fibrillation; Dextrocardia; Left atrial appendage occlusion; Music therapy; Enhanced recovery after surgery; Case report

©The Author(s) 2022. Published by Baishideng Publishing Group Inc. All rights reserved.

**Core Tip:** Mirror dextrocardia has typical clinical characteristics. Because of the high prevalence and mortality of atrial fibrillation of patients with mirror dextrocardia, left atrial appendage occlusion has an important role in treatment, which continues to be confirmed. Left atrial appendage occlusion is an ideal choice for patients with atrial fibrillation. Moreover, music therapy can be used throughout perioperative treatment and nursing to improve the anxiety symptoms of patients.

**Citation:** Tian B, Ma C, Su JW, Luo J, Sun HX, Su J, Ning ZP. Left atrial appendage occlusion in a mirror-image dextrocardia: A case report and review of literature. *World J Clin Cases* 2022; 10(4): 1357-1365

**URL:** <https://www.wjgnet.com/2307-8960/full/v10/i4/1357.htm>

**DOI:** <https://dx.doi.org/10.12998/wjcc.v10.i4.1357>

## INTRODUCTION

Enhanced recovery after surgery (ERAS) is a multimode, interdisciplinary care model designed to improve perioperative care, including medical care before, during, and after surgery and during rehabilitation. Increasing evidence supports the use of ERAS in surgical patients. ERAS is effective in reducing gastrointestinal infections and hospital stay associated with general colon and rectum surgery. The ERAS Society has been the source of international plans for colorectal, hepatobiliary, urinary, gastric, gynecological, and cardiac surgery groups, and provided evidence-based guidelines for the perioperative treatment and nursing of patients[1-3].

In cardiac surgery, the ERAS model shows that early extubation is safe and feasible, and can significantly shorten electrocardiogram (ECG) monitoring and coronary care unit (CCU) stays. However, the application of ERAS models in cardiac surgery is still at an early stage, and reports in interventional cardiology are limited. Studies have shown that ERAS regimens are feasible and safe in minimally invasive cardiac surgery, and have the potential to significantly improve patient prognosis[4,5].

The ERAS model has characteristics specific to different clinical fields, but the basic concept is common to all fields. The 2019 guidelines for accelerating postoperative rehabilitation of heart surgery include correcting malnutrition before surgery, smoking and drinking cessation, establishing a cardiac preadaptation plan including education, nutrition optimization, sports training, social support, and reducing anxiety, infection prevention, carbohydrate loading (sugar prestorage), establishment of an electronic health platform, *etc.* The intraoperative care package includes local nasal treatment to eliminate staphylococcus colonization, skin preparation, depilation scheme, dressing changes, prevention of hypothermia, keeping venous access open, rigid sternum fixation, and hemostasis. Whole-process management of patients in the perioperative period includes intensive glycemic control, pain management, delirium screening, drug anticoagulation, early extubation, biomarkers for early identification of high-risk patients with acute kidney injury, and goal-directed recommendations (*i.e.*, blood pressure, cardiac index, systemic venous oxygen saturation, and urine volume). Fluid management therapy is a cooperative multiteam effort, including nutritionists, early cardiac rehabilitation therapists, and physiotherapists.

Left atrial appendage occlusion (LAAO) is a minimally invasive intervention guided by medical imaging equipment[6]. A device is positioned in the left atrial appendage (LAA) by percutaneous venipuncture to prevent thrombi from entering the blood circulation in patients with atrial fibrillation. Medical staff are concerned about the consequences of and low compliance with long-term use of oral anticoagulants and the high risk of bleeding. Therefore, LAAO has been applied as an alternative[7,8]. At present, the two most commonly used LAAO devices worldwide are the Watchman implant system and the Amplatzer cardiac plug. The Watchman device has been approved by Federal Drug Administration as an alternative for stroke prevention and

**P-Reviewer:** Spartalis M**S-Editor:** Yan JP**L-Editor:** A**P-Editor:** Yan JP

it is the most widely used LAAO closure device[9]. Studies have shown that the effectiveness of LAAO against thrombus formation is similar to that of oral warfarin, and it has advantages in preventing stroke and maintaining quality of life[10-13]. In long-term follow-up, the incidence of both bleeding and stroke decreased significantly. LAAO was also found to be suitable for patients with atrial fibrillation who cannot tolerate oral anticoagulants, have a high risk of bleeding, have anticoagulant contraindications, and for whom anticoagulation did not prevent stroke[14-16]. The Watchman device was also found to reduce the incidence of perioperative complications, hemorrhagic stroke, stroke disability and mortality, cardiovascular events, and all-cause mortality, and to improve clinical outcomes and prognosis[17-20]. With ongoing advances in perioperative care, LAAO will continue to develop as an effective alternative strategy to prevent stroke in patients with atrial fibrillation.

In dextrocardia, the apex of the heart points to or is located on the right side of the chest[21,22]. Using the longitudinal axis of the heart as a reference, dextrocardia can be seen as either situs solitus, in which the abdominal organs are in their normal positions, or situs invertus, in which the abdominal organs are horizontally reversed or “mirrored”[23]. Mirror-image dextrocardia is a rare anomaly, with an incidence of about 1:10,000 in the general population[24]. There have been few published reports of LAAO in patients with dextrocardia, which is surgically challenging because of the anatomical anomalies, surgical risk, and complication monitoring that must be considered[25,26]. There have also been no reports on the application of the ERAS model to LAAO. This case describes our experience with ERAS following the 2019 accelerated cardiac surgery rehabilitation perioperative nursing guidelines for perioperative care of a patient with dextrocardiac LAAO.

## CASE PRESENTATION

### *Chief complaints*

The patient presented to the outpatient facility with atrial fibrillation.

### *History of present illness*

The patient reported having experienced occasional palpitations and discomfort without obvious chest tightness and pain, and presented with fluent speech, unclear articulation, hearing loss, and mild activity impairment of the left lower limb.

### *History of past illness*

The patient had a history of cerebral infarction, hypertension, cholecystectomy, prostatic hyperplasia surgery, and fractures of both upper limbs and the left lower limb. Long-term oral aspirin was discontinued in the previous month because of hematochezia.

### *Personal and family history*

No family history.

### *Physical examination*

On presentation, the patient's body temperature was 37 °C, the pulse was 89 beats/min, respiration rate was 18 breaths/min, blood pressure was 143/76 mmHg, and the numerical rating scale pain score was 0. Twelve-lead electrocardiography revealed atrial fibrillation with a change in the ST-T segment.

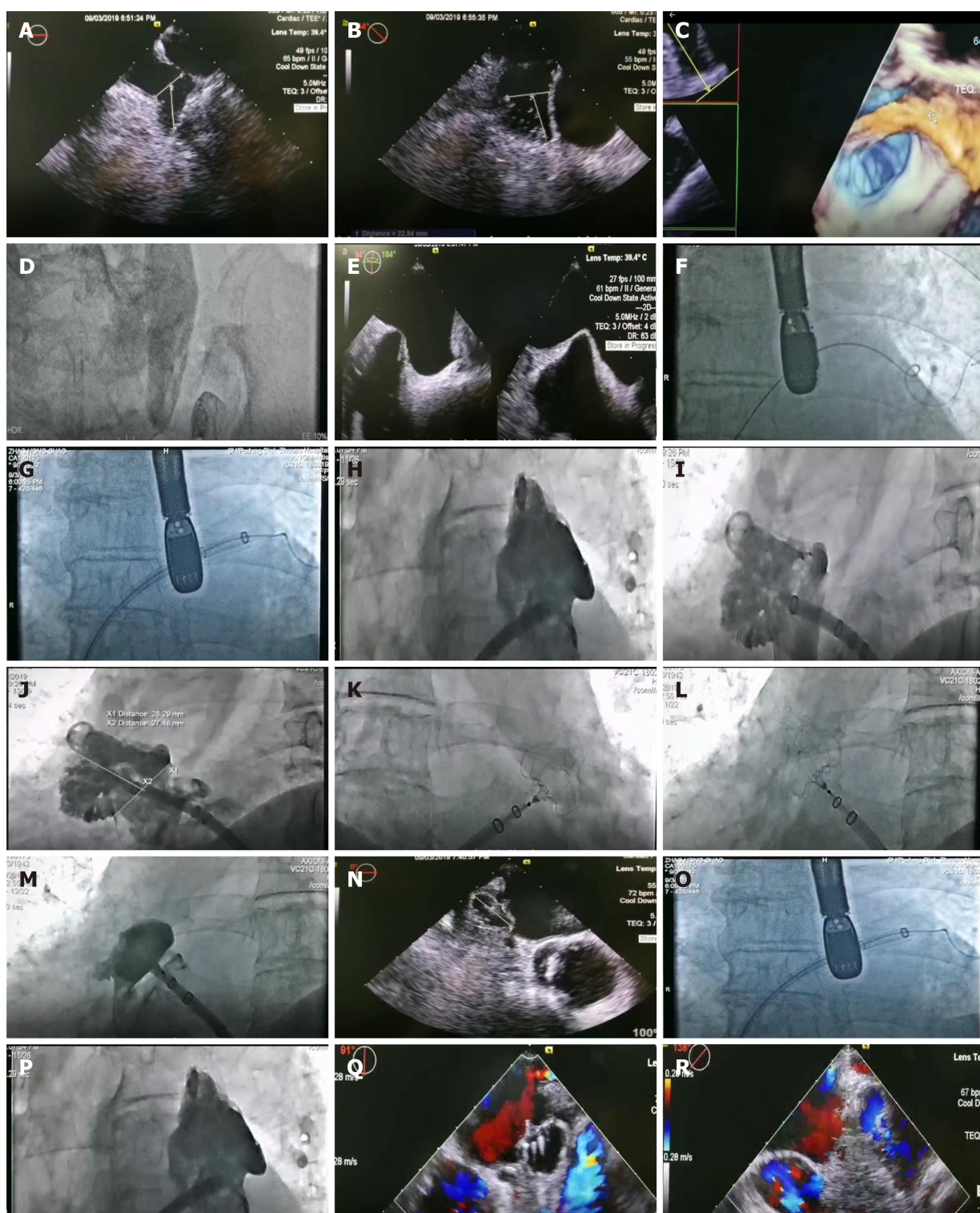
### *Imaging examinations*

Twelve-lead electrocardiography revealed atrial fibrillation with a change in the ST-T segment.

## FINAL DIAGNOSIS

The diagnosis was arrhythmia, paroxysmal atrial fibrillation, cardiac function New York Heart Association level II, level II very high-risk hypertension, sequelae of cerebral infarction, and visceral inversion (Figure 1).





**Figure 1 Details of the surgical procedure.** A: Transesophageal echocardiography; B: Dextrocardia (45°); C: Morphology of left atrial appendage; D: Left femoral vein puncture; E: Atrial septum puncture; F: Superior pulmonary vein of guide wire; G: Sheath follow up; H: Auricle not fully exposed; I: Right anterior oblique cardiography; J: Occluder selection; K: Implantation of sealing umbrella; L: Pulling and plugging the closure umbrella; M: Release the closure umbrella; N: Multi angle compression ratio (24%-27%); O: No residual shunt (0°); P: 1.5mm residual shunt (45°); Q: No residual shunt (90°); R: No residual shunt (135°).

## TREATMENT

Percutaneous LAAO was performed under general intravenous anesthesia (Figure 1).

## OUTCOME AND FOLLOW-UP

After the LAAO procedure, the patient was admitted to the CCU. His vital signs were closely monitored and found to be stable following surgery. At 18 h, the heart rate was 75 beats/min, average blood pressure was 139/80 mmHg, average O<sub>2</sub> saturation was 97%, and the urine volume was 2100 mL. At 19 h, the blood pressure was 197/99 mmHg, the heart rate was 64/min, O<sub>2</sub> saturation was 92%, and the urine volume was 900 mL. Infusion of 0.9% normal saline 250 mL + 10 mg isosorbide nitrate was maintained at 10 mL/h, as advised by the doctor. At 19 h 15 min, the blood pressure was 190/85 mmHg, the heart rate was 64 beats/min, and the O<sub>2</sub> saturation was 95%. At 20 h, the blood pressure was 172/94 mmHg, heart rate was 69 beats/min, O<sub>2</sub> saturation was 97%, and the blood pressure was 135/68 mmHg.

Puncture wounds were treated by finger compression to stop bleeding. If after 20 min no bleeding had occurred, then an elastic bandage was applied for compression. A 1 kg sandbag was applied for 6 h and a right lower limb brake was applied for 12 h. The wound dressing was changed daily. TEE on the first day after the procedure showed that the position of the umbrella was good, and that the residual shunt was about 2 mm behind the lower edge of the umbrella. No procedure-associated complications occurred during hospitalization or in the 12 d after the procedure. Follow-up echocardiography on October 18, 2019, 45 d after the procedure, and November 21, 2019 found that the occluder was in a good position, with a residual shunt of 2 mm around the lower edge of the umbrella. There had been no serious arrhythmia, bleeding, or cerebrovascular accident (Figure 1).

## DISCUSSION

Dextrocardia situs inversus totalis is a rare congenital cardiac anomaly[26] in which the relationship of the great arteries is normal or transposed, as in mirror dextrocardia (coordinated cardiac circulation). Uncoordinated cardiac circulation usually shows congenital transposition of great arteries[27]. In patients with mirror dextrocardia, the main challenge for surgeons is the reversal of the whole heart, and in this case, the ECG leads were placed in the mirror mode (*i.e.*, reversed). The fluoroscopy image is reversed horizontally, and the catheter is rotated in the opposite direction from normal [28]. The risks of coronary atherosclerosis and acute myocardial infarction in those with mirror dextrocardia are not different from those in normal individuals.

### Anatomical characteristics of LAA

LAA is a remnant of the primitive atrium in the embryo. It has pectinate and trabecular muscle a unique rough endocardium[11]. It usually has three anatomical regions, the mouth, neck, and leaf and a morphology usually described as chicken wing, cactus, windsock, and cauliflower, which are present in different proportions[29, 30] and appear different when observed from different angles. Some studies have reported that the LAA regulates pressure and volume load, releases atrial natriuretic peptide and B-type natriuretic peptide, and regulates hemodynamics.

### Capacity load

The increase of volumetric load blood pressure after cardiac interventions may be related to excess intraoperative infusion. The left ventricular cardiac ejection fraction of the patient, who weighed 79.8-80 kg, was 56%. Fluid loss was  $[(4 \times 10) + (2 \times 10) + (1 \times 60)] \times 9 = 1080$  mL and replenishment was complete within 2 h after the start of anesthesia[31,32]. The volume of fluid replenishment at 1 h was  $1080/2 + 110 = 650$  mL, with an additional 650 mL at 2 h. After that, a physiological requirement of 110 mL/h was maintained. The patient was given antibiotics (0.9% normal saline 100 mL + cefuroxime 1500 mg), sodium lactate ringer injection 500 mL + 5% glucose, normal saline 500 mL + heparin 5000 U within 2 h after the start of anesthesia. The total of 2100 mL, which was more than needed, may have contributed to the postoperative elevated blood pressure. It was agreed that the total intraoperative fluid given to the patient was not likely to have exceeded 1500 mL.

### Nursing guidance by ERAS recommendations

The preoperative nutritional status of the patient was good; he did not smoke or drink. His hemoglobin was 136 g/L, and he was infection-free. An electronic health platform allowed for establishment of a real-time hospital community with an application for those with coronary heart disease to participate in a cardiac preconditioning plan that



**Table 1 Nursing procedures guided by the enhanced recovery after surgery model**

Phase	Project	Level of evidence	Recommendation	Remarks
Preoperative	Hemoglobin	IIA, C-LD	Yes	Preoperative measurement of hemoglobin to assist risk stratification
	Albumin	IIA, C-LD	Yes	Preoperative assessment of albumin contributes to risk stratification
	Correcting malnutrition	IIA, C-LD	Yes	Recommend correcting nutritional deficiencies where feasible
	Smoking and drinking	I, C-LD	Yes	Patients were advised to stop 4 wk prior to elective surgery
	Carbohydrate load	IIB, C-LD	Yes	Carbohydrate loading (sugar prestocking) can be performed 2-4 h before general anesthesia
	Infection prevention	IA	Yes	Cephalosporins are recommended for 30-60 min before surgery
	E-health platform	IIA, C-LD	Yes	Establish electronic health education platform
	Cardiac preconditioning program	IIA, B-NR	Yes	These include education, nutrition optimization, sports training, social support, and mindfulness stress reduction training to reduce anxiety
Intraoperative	Implementation care package	I, B-R	Yes	Including local intranasal therapy to eliminate staphylococcal colonization  Cephalosporins were injected within 60 min before skin incision and redone in cases over 4 h  Skin preparation, depilation plan, dressing change after every 48 h
	Recovery temperature	III, B-R	No	Avoid high temperature during cardiopulmonary bypass reheating, that is the core temperature should not be > 37.9 °C
	Rigid sternum fraction	IIA, B-R	No	Rigid sternum fraction is beneficial in patients undergoing sternotomy
	Bleeding prevention	I, A	No	Tranexamic acid or amino hexic acid is recommended for cardiopulmonary bypass
Postoperative	Enhanced glycemic control	IIA, B-NR	Yes	Factors of postoperative hyperglycemia: glucose toxicity, oxidative stress, prethrombotic effect, inflammation
	Insulin infusion to treat hyperglycemia	IIA, B-NR	No	Insulin infusion is recommended to treat perioperative hyperglycemia
	Pain management	I, B-NR	No	Prescription of acetaminophen, tramadol, dexmedetomidine, pregabalin, gabapentin, <i>etc.</i>
	Hypothermia	I, B-NR	Yes	Warm blankets, elevated room temperature, heat perfusion and intravenous infusion are recommended for postoperative use
	Delirium	I, B-NR	Yes	At least one delirium screening is recommended for each nursing class
	Anticoagulant drugs	IIA, C-LD	Yes	Drug anticoagulation is recommended to reduce the risk of thrombosis
	Early extubation	IIA, B-NR	Yes	Strategies are recommended to ensure that the tube is extubated within 6 h of surgery
	Acute renal injury	IIA, B-R	Yes	Biomarkers are recommended for early identification of at-risk patients early and guide the reduction of AKI
	Goal-directed fluid therapy	I, B-R	Yes	Goal-directed fluid therapy is recommended to reduce postoperative complications
	Other	Unrated	Yes	Cardiopulmonary bypass, perfusion, mechanical ventilation at low tidal volume, early postoperative enteral feeding and postoperative mobilization are recommended  It is recommended that the recommendations be adjusted to achieve the goals through multiteam collaboration (dietitians, early cardiac rehabilitation therapists, and physical therapists)

AKI: Acute kidney injury.

included education, nutrition optimization, sports training, social support, and anxiety reduction. A self-rating anxiety scale was used to assess the anxiety level of the patient when he was admitted to hospital on August 29. His score was 65, indicating moderate anxiety. International studies have shown that music therapy can improve the mood of patients, promote mental health, and reduce anxiety and depression symptoms[33-35]. Chu *et al*[36] and others have shown that music therapy can improve anxiety and

depression in patients with Alzheimer's disease. Studies in China have shown that five-element music therapy improved the sleep quality of patients with heart failure and anxiety and that Wuxing music combined with Baduanjin had a positive effect on the psychology of patients with poor health status[37,38]. Music therapy was used in the care of this patient. Six pieces of music were selected and played at 8:00-8:30 in the morning and 20:00-20:30 in the evening. The volume was 40-60 DB. On September 6, the SAS score was 46, and the anxiety state had significantly improved. Music therapy was easy to provide and not limited by the venue, and was enjoyed by the patient (Table 1).

## CONCLUSION

Mirror dextrocardia has typical clinical characteristics. Because of the high prevalence and mortality of atrial fibrillation of patients with mirror dextrocardia, LAAO has an important role in treatment, which continues to be confirmed[39,40]. LAAO is an ideal choice for patients with atrial fibrillation. The 2019 nursing guidelines for accelerated cardiac surgery recovery optimize the clinical nursing path of patients with LAAO and can reduce perioperative complications and ensure the patient safety. The application of music therapy can reduce patient anxiety and is suitable for the entire process of treatment and nursing care.

## ACKNOWLEDGEMENTS

The authors would like to express their gratitude to Wong F, for performance of the transesophageal echocardiography assessment; to Liu YX, for serving as the patient's anesthesiologist; and to Zheng QQ, who performed language translation activities for the case report.

## REFERENCES

- 1 Engelman DT, Ben Ali W, Williams JB, Perrault LP, Reddy VS, Arora RC, Roselli EE, Khojenezhad A, Gerdisch M, Levy JH, Lobdell K, Fletcher N, Kirsch M, Nelson G, Engelman RM, Gregory AJ, Boyle EM. Guidelines for Perioperative Care in Cardiac Surgery: Enhanced Recovery After Surgery Society Recommendations. *JAMA Surg* 2019; **154**: 755-766 [PMID: 31054241 DOI: 10.1001/jamasurg.2019.1153]
- 2 Kubitz JC, Schulte-Uentrop L, Zoellner C, Lemke M, Messner-Schmitt A, Kalbacher D, Sill B, Reichensperner H, Koell B, Girdauskas E. Establishment of an enhanced recovery after surgery protocol in minimally invasive heart valve surgery. *PLoS One* 2020; **15**: e0231378 [PMID: 32271849 DOI: 10.1371/journal.pone.0231378]
- 3 McGinagle KL, Eldrup-Jorgensen J, McCall R, Freeman NL, Pascarella L, Farber MA, Marston WA, Crouner JR. A systematic review of enhanced recovery after surgery for vascular operations. *J Vasc Surg* 2019; **70**: 629-640.e1 [PMID: 30922754 DOI: 10.1016/j.jvs.2019.01.050]
- 4 Sola M, Ramm CJ, Kolarczyk LM, Teeter EG, Yeung M, Caranasos TG, Vavalle JP. Application of a Multidisciplinary Enhanced Recovery After Surgery Pathway to Improve Patient Outcomes After Transcatheter Aortic Valve Implantation. *Am J Cardiol* 2016; **118**: 418-423 [PMID: 27344271 DOI: 10.1016/j.amjcard.2016.05.015]
- 5 Zaouter C, Imbault J, Labrousse L, Abdelmoumen Y, Coiffic A, Colonna G, Jansens JL, Ouattara A. Association of Robotic Totally Endoscopic Coronary Artery Bypass Graft Surgery Associated With a Preliminary Cardiac Enhanced Recovery After Surgery Program: A Retrospective Analysis. *J Cardiothorac Vasc Anesth* 2015; **29**: 1489-1497 [PMID: 26119408 DOI: 10.1053/j.jvca.2015.03.003]
- 6 Alsagheir A, Koziarz A, Belley-Côté EP, Whitlock RP. Left Atrial Appendage Occlusion: A Narrative Review. *J Cardiothorac Vasc Anesth* 2019; **33**: 1753-1765 [PMID: 30857852 DOI: 10.1053/j.jvca.2019.01.054]
- 7 Holmes DR Jr, Doshi SK, Kar S, Price MJ, Sanchez JM, Sievert H, Valderrabano M, Reddy VY. Left Atrial Appendage Closure as an Alternative to Warfarin for Stroke Prevention in Atrial Fibrillation: A Patient-Level Meta-Analysis. *J Am Coll Cardiol* 2015; **65**: 2614-2623 [PMID: 26088300 DOI: 10.1016/j.jacc.2015.04.025]
- 8 Chow DHF, Wong YH, Park JW, Lam YY, De Potter T, Rodés-Cabau J, Asmarats L, Sandri M, Sideris E, McCaw T, Lee RJ, Sievert H, Søndergaard L, De Backer O. An overview of current and emerging devices for percutaneous left atrial appendage closure. *Trends Cardiovasc Med* 2019; **29**: 228-236 [PMID: 30205924 DOI: 10.1016/j.tcm.2018.08.008]
- 9 Francisco ARG, Infante de Oliveira E, Nobre Menezes M, Carrilho Ferreira P, Canas da Silva P, Nobre Â, Pinto FJ. Combined MitraClip implantation and left atrial appendage occlusion using the

- Watchman device: A case series from a referral center. *Rev Port Cardiol* 2017; **36**: 525-532 [PMID: 28673783 DOI: 10.1016/j.repc.2016.11.012]
- 10 **Chanda A**, Reilly JP. Left Atrial Appendage Occlusion for Stroke Prevention. *Prog Cardiovasc Dis* 2017; **59**: 626-635 [PMID: 28457791 DOI: 10.1016/j.pcad.2017.04.003]
  - 11 **Naksuk N**, Padmanabhan D, Yogeswaran V, Asirvatham SJ. Left Atrial Appendage: Embryology, Anatomy, Physiology, Arrhythmia and Therapeutic Intervention. *JACC Clin Electrophysiol* 2016; **2**: 403-412 [PMID: 29759858 DOI: 10.1016/j.jacep.2016.06.006]
  - 12 **Glikson M**, Wolff R, Hindricks G, Mandrola J, Camm AJ, Lip GYH, Fauchier L, Betts TR, Lewalter T, Saw J, Tzikas A, Sternik L, Nietlispach F, Berti S, Sievert H, Bertog S, Meier B. EHRA/EAPCI expert consensus statement on catheter-based left atrial appendage occlusion - an update. *EuroIntervention* 2020; **15**: 1133-1180 [PMID: 31474583 DOI: 10.4244/EIJY19M08\_01]
  - 13 **Reddy VY**, Sievert H, Halperin J, Doshi SK, Buchbinder M, Neuzil P, Huber K, Whisenant B, Kar S, Swarup V, Gordon N, Holmes D; PROTECT AF Steering Committee and Investigators. Percutaneous left atrial appendage closure vs warfarin for atrial fibrillation: a randomized clinical trial. *JAMA* 2014; **312**: 1988-1998 [PMID: 25399274 DOI: 10.1001/jama.2014.15192]
  - 14 **Berti S**, Santoro G, Brscic E, Montorfano M, Vignali L, Danna P, Tondo C, D'Amico G, Stabile A, Saccà S, Patti G, Rapacciuolo A, Poli A, Golino P, Magnavacchi P, De Caterina A, Meucci F, Pezzulich B, Rezzaghi M, Stolicova M, Tarantini G. Left atrial appendage closure using AMPLATZER™ devices: A large, multicenter, Italian registry. *Int J Cardiol* 2017; **248**: 103-107 [PMID: 28797952 DOI: 10.1016/j.ijcard.2017.07.052]
  - 15 **Lee OH**, Kim JS, Pak HN, Hong GR, Shim CY, Uhm JS, Cho IJ, Joung B, Yu CW, Lee HJ, Kang WC, Shin ES, Choi RK, Lim DS, Jang Y. Feasibility of Left Atrial Appendage Occlusion for Left Atrial Appendage Thrombus in Patients With Persistent Atrial Fibrillation. *Am J Cardiol* 2018; **121**: 1534-1539 [PMID: 29631803 DOI: 10.1016/j.amjcard.2018.02.045]
  - 16 **Lempereur M**, Aminian A, Freixa X, Gafoor S, Shakir S, Omran H, Berti S, Santoro G, Kefer J, Landmesser U, Nielsen-Kudsk JE, Cruz-Gonzalez I, Kanagaratnam P, Nietlispach F, Ibrahim R, Sievert H, Schillinger W, Park JW, Gloekler S, Tzikas A. Left Atrial Appendage Occlusion in Patients With Atrial Fibrillation and Previous Major Gastrointestinal Bleeding (from the Amplatzer Cardiac Plug Multicenter Registry). *Am J Cardiol* 2017; **120**: 414-420 [PMID: 28595859 DOI: 10.1016/j.amjcard.2017.04.046]
  - 17 **Price MJ**. Safety and Efficacy of Transcatheter Left Atrial Appendage Closure for Stroke Prevention in Patients with Atrial Fibrillation. *Prog Cardiovasc Dis* 2018; **60**: 542-549 [PMID: 29339165 DOI: 10.1016/j.pcad.2018.01.002]
  - 18 **Wiebe J**, Franke J, Lehn K, Hofmann I, Vaskelyte L, Bertog S, Sievert H. Percutaneous Left Atrial Appendage Closure With the Watchman Device: Long-Term Results Up to 5 Years. *JACC Cardiovasc Interv* 2015; **8**: 1915-1921 [PMID: 26738659 DOI: 10.1016/j.jcin.2015.07.040]
  - 19 **Hutt E**, Wazni OM, Saliba WI, Kanj M, Tarakji KG, Aguilera J, Barakat AF, Rasmussen P, Uchino K, Russman A, Hussain S, Wisco D, Kapadia S, Lindsay BD, Hussein AA. Left atrial appendage closure device implantation in patients with prior intracranial hemorrhage. *Heart Rhythm* 2019; **16**: 663-668 [PMID: 30521942 DOI: 10.1016/j.hrthm.2018.11.022]
  - 20 **Reddy VY**, Doshi SK, Kar S, Gibson DN, Price MJ, Huber K, Horton RP, Buchbinder M, Neuzil P, Gordon NT, Holmes DR Jr; PREVAIL and PROTECT AF Investigators. 5-Year Outcomes After Left Atrial Appendage Closure: From the PREVAIL and PROTECT AF Trials. *J Am Coll Cardiol* 2017; **70**: 2964-2975 [PMID: 29103847 DOI: 10.1016/j.jacc.2017.10.021]
  - 21 **Perloff JK**. The cardiac malpositions. *Am J Cardiol* 2011; **108**: 1352-1361 [PMID: 21861958 DOI: 10.1016/j.amjcard.2011.06.055]
  - 22 **Li Y**, Fang JB. Nursing strategy and complication prevention of cardiac resynchronization therapy for a patient with dextrocardia. *Huli Xuebao* 2018; **25**: 59-61
  - 23 **Qutbi M**. SPECT myocardial perfusion imaging in patients with Dextrocardia. *J Nucl Cardiol* 2019; **26**: 1197-1204 [PMID: 31062220 DOI: 10.1007/s12350-019-01732-w]
  - 24 **Yilmaz S**, Demirtas A, Tokpinar A, Niyazi A. Dextrocardia and Situs Inversus Totalis in a Turkish Subject: A Case Report. *Int J Morphol* 2019; **37**: 900-902
  - 25 **González-Cordero A**, López-Puebla J, Franqui-Rivera H. Implantation of a completely right sided subcutaneous cardioverter-defibrillator in a patient with situs inversus dextrocardia. *Indian Pacing Electrophysiol J* 2019; **19**: 72-74 [PMID: 30468861 DOI: 10.1016/j.ipej.2018.11.010]
  - 26 **Onan B**, Aydin U, Kahraman Z, Bakir I. Robotic atrial septal defect closure and tricuspid annuloplasty in a case of situs inversus totalis with dextrocardia. *J Robot Surg* 2017; **11**: 87-90 [PMID: 27344445 DOI: 10.1007/s11701-016-0619-3]
  - 27 **Zhou GB**, Ma J, Zhang JL, Guo XG, Yang JD, Liu SW, Ouyang FF. Catheter ablation of supraventricular tachycardia in patients with dextrocardia and situs inversus. *J Cardiovasc Electrophysiol* 2019; **30**: 557-564 [PMID: 30661266 DOI: 10.1111/jce.13847]
  - 28 **He J**, Sun Y, Zhang X, Wang Y, Zhong J, Lin F, Liu Y. Emergent percutaneous coronary intervention for acute myocardial infarction in patients with mirror dextrocardia: case reports and brief review. *Cardiovasc Diagn Ther* 2016; **6**: 267-273 [PMID: 27280091 DOI: 10.21037/cdt.2015.12.12]
  - 29 **Barbero U**, Ho SY. Anatomy of the atria. *Herzschr Elektrophys* 2017; **28**: 347-354
  - 30 **López-Mínguez JR**, Nogales-Asensio JM, Infante De Oliveira E, De Gama Ribeiro V, Ruiz-Salmerón R, Arzamendi-Aizpurua D, Costa M, Gutiérrez-García H, Fernández-Díaz JA, Martín-Yuste V, Rama-Merchán JC, Moreno-Gómez R, Benedicto-Buendía A, Íñiguez-Romo A. Long-term Event Reduction After Left Atrial Appendage Closure. Results of the Iberian Registry II. *Rev Esp Cardiol*

- (*Engl Ed*) 2019; **72**: 449-455 [PMID: [29754808](#) DOI: [10.1016/j.rec.2018.03.017](#)]
- 31 **Caliskan E**, Cox JL, Holmes DR Jr, Meier B, Lakkireddy DR, Falk V, Salzberg SP, Emmert MY. Interventional and surgical occlusion of the left atrial appendage. *Nat Rev Cardiol* 2017; **14**: 727-743 [PMID: [28795688](#) DOI: [10.1038/nrcardio.2017.107](#)]
  - 32 **Huang WQ**, Xu X. Expert consensus on fluid therapy during anesthesia operation. Annual Meeting of Anesthesiology Branch of Beijing Medical Association. 2014; 24-25
  - 33 **Vaudreuil R**, Avila L, Bradt J, Pasquina P. Music therapy applied to complex blast injury in interdisciplinary care: a case report. *Disabil Rehabil* 2019; **41**: 2333-2342 [PMID: [29688085](#) DOI: [10.1080/09638288.2018.1462412](#)]
  - 34 **Wood C**, Cutshall SM, Wiste RM, Gentes RC, Rian JS, Tipton AM, Ann-Marie D, Mahapatra S, Carey EC, Strand JJ. Implementing a Palliative Medicine Music Therapy Program: A Quality Improvement Project. *Am J Hosp Palliat Care* 2019; **36**: 603-607 [PMID: [30845807](#) DOI: [10.1177/1049909119834878](#)]
  - 35 **Sihvonen AJ**, Särkämö T, Leo V, Tervaniemi M, Altenmüller E, Soinila S. Music-based interventions in neurological rehabilitation. *Lancet Neurol* 2017; **16**: 648-660 [PMID: [28663005](#) DOI: [10.1016/S1474-4422\(17\)30168-0](#)]
  - 36 **Chu H**, Yang CY, Lin Y, Ou KL, Lee TY, O'Brien AP, Chou KR. The impact of group music therapy on depression and cognition in elderly persons with dementia: a randomized controlled study. *Biol Res Nurs* 2014; **16**: 209-217 [PMID: [23639952](#) DOI: [10.1177/1099800413485410](#)]
  - 37 **Gao J**, Yi X, Wu CX, Bai DX, Ye Y, Zhu R, Wu S. Application effect of noon ebb flow timing five element music therapy in patients with chronic heart failure anxiety. *Zhonghua Huli Zazhi* 2016; **51**: 443-448
  - 38 **Geng YQ**. Research on the intervention effect of Baduanjin and Five-notes music on mental sub-health state. Nanjing University of Traditional Chinese Medicine (Dissertation), 2013
  - 39 **Schnabel RB**, Yin X, Gona P, Larson MG, Beiser AS, McManus DD, Newton-Cheh C, Lubitz SA, Magnani JW, Ellinor PT, Seshadri S, Wolf PA, Vasan RS, Benjamin EJ, Levy D. 50 year trends in atrial fibrillation prevalence, incidence, risk factors, and mortality in the Framingham Heart Study: a cohort study. *Lancet* 2015; **386**: 154-162 [PMID: [25960110](#) DOI: [10.1016/S0140-6736\(14\)61774-8](#)]
  - 40 **Lin JJ**, Fan YQ. Nursing care of 4 patients with transcatheter closure of left atrial appendage. *Zhonghua Huli Zazhi* 2015; **50**: 629-631



Published by **Baishideng Publishing Group Inc**  
7041 Koll Center Parkway, Suite 160, Pleasanton, CA 94566, USA

**Telephone:** +1-925-3991568

**E-mail:** [bpgoffice@wjgnet.com](mailto:bpgoffice@wjgnet.com)

**Help Desk:** <https://www.f6publishing.com/helpdesk>

<https://www.wjgnet.com>

