

World Journal of *Clinical Cases*

World J Clin Cases 2021 December 26; 9(36): 11122-11508



Contents

Thrice Monthly Volume 9 Number 36 December 26, 2021

REVIEW

- 11122** Diet and microbiome in the beginning of the sequence of gut inflammation
Ceballos D, Hernández-Camba A, Ramos L

MINIREVIEWS

- 11148** Stem cell therapy: A promising treatment for COVID-19
Zheng ZX

ORIGINAL ARTICLE

Case Control Study

- 11156** Association between serum Sestrin2 level and diabetic peripheral neuropathy in type 2 diabetic patients
Mao EW, Cheng XB, Li WC, Kan CX, Huang N, Wang HS, Hou NN, Sun XD
- 11165** Plasma brain natriuretic peptide, platelet parameters, and cardiopulmonary function in chronic obstructive pulmonary disease
Guo HJ, Jiang F, Chen C, Shi JY, Zhao YW

Retrospective Cohort Study

- 11173** Analysis of the incidence and influencing factors of hyponatremia before ¹³¹I treatment of differentiated thyroid carcinoma
Cao JJ, Yun CH, Xiao J, Liu Y, Wei W, Zhang W

Retrospective Study

- 11183** Cognitive magnetic resonance imaging-ultrasound fusion transperineal targeted biopsy combined with randomized biopsy in detection of prostate cancer
Pang C, Wang M, Hou HM, Liu JY, Zhang ZP, Wang X, Zhang YQ, Li CM, Zhang W, Wang JY, Liu M
- 11193** Nomogram based on inflammation-related markers for predicting survival of patients undergoing hepatectomy for hepatocellular carcinoma
Pu T, Li ZH, Jiang D, Chen JM, Guo Q, Cai M, Chen ZX, Xie K, Zhao YJ, Liu FB
- 11208** Association of frailty with in-hospital outcomes in elderly patients with heart failure
Kang YP, Chen LY, Zhu JJ, Liu WX, Ma CS
- 11220** COVID-19 pandemic and exacerbation of ulcerative colitis
Suda T, Takahashi M, Katayama Y, Tamano M
- 11228** Surgical perspectives of symptomatic omphalomesenteric duct remnants: Differences between infancy and beyond
Kang A, Kim SH, Cho YH, Kim HY

- 11237** Clustering cases of *Chlamydia psittaci* pneumonia mimicking COVID-19 pneumonia
Zhao W, He L, Xie XZ, Liao X, Tong DJ, Wu SJ, Liu J
- 11248** Sodium nitroprusside injection immediately before balloon inflation during percutaneous coronary intervention
Yu Y, Yang BP
- 11255** Machine learning approach to predict acute kidney injury after liver surgery
Dong JF, Xue Q, Chen T, Zhao YY, Fu H, Guo WY, Ji JS
- 11265** Application effect for a care bundle in optimizing nursing of patients with severe craniocerebral injury
Gao Y, Liao LP, Chen P, Wang K, Huang C, Chen Y, Mou SY

Clinical Trials Study

- 11276** Influence of pontic design of anterior fixed dental prosthesis on speech: A clinical case study
Wan J, Cai H, Wang T, Chen JY

Observational Study

- 11285** Real-world data on the infliximab biosimilar CT-P13 (Remsima®) in inflammatory bowel disease
Huguet JM, Cortés X, Bosca-Watts MM, Aguas M, Maroto N, Martí L, Amorós C, Paredes JM
- 11300** Correlation of periodontal inflamed surface area with glycemic status in controlled and uncontrolled type 2 diabetes mellitus
Anil K, Vadakkekuttikal RJ, Radhakrishnan C, Parambath FC
- 11311** Audiological characteristics and exploratory treatment of a rare condition of acute-otitis-media-associated sudden sensorineural hearing loss
Cao X, Yi HJ
- 11320** Yield of testing for micronutrient deficiencies associated with pancreatic exocrine insufficiency in a clinical setting: An observational study
Jalal M, Campbell JA, Tesfaye S, Al-Mukhtar A, Hopper AD

Prospective Study

- 11330** Birthing ball on promoting cervical ripening and its influence on the labor process and the neonatal blood gas index
Shen HC, Wang H, Sun B, Jiang LZ, Meng Q

CASE REPORT

- 11338** Mucormycosis – resurgence of a deadly opportunist during COVID-19 pandemic: Four case reports
Upadhyay S, Bharara T, Khandait M, Chawdhry A, Sharma BB
- 11346** Ductal breast carcinoma metastasized to the rectum: A case report and review of the literature
Ban B, Zhang K, Li JN, Liu TJ, Shi J

- 11355** De Garengeot hernia with avascular necrosis of the appendix: A case report
Yao MQ, Yi BH, Yang Y, Weng XQ, Fan JX, Jiang YP
- 11362** Mature mediastinal bronchogenic cyst with left pericardial defect: A case report
Zhu X, Zhang L, Tang Z, Xing FB, Gao X, Chen WB
- 11369** Difficulties in diagnosing anorectal melanoma: A case report and review of the literature
Apostu RC, Stefanescu E, Scurtu RR, Kacso G, Drasovean R
- 11382** Solid pseudopapillary neoplasm of the pancreas in a young male with main pancreatic duct dilatation: A case report
Nakashima S, Sato Y, Imamura T, Hattori D, Tamura T, Koyama R, Sato J, Kobayashi Y, Hashimoto M
- 11392** Acute myocardial infarction in a young man with ankylosing spondylitis: A case report
Wan ZH, Wang J, Zhao Q
- 11400** Acute appendicitis complicated by mesenteric vein thrombosis: A case report
Yang F, Guo XC, Rao XL, Sun L, Xu L
- 11406** Inguinal endometriosis: Ten case reports and review of literature
Li SH, Sun HZ, Li WH, Wang SZ
- 11419** Dramatic response to immunotherapy in an epidermal growth factor receptor-mutant non-small cell lung cancer: A case report
Li D, Cheng C, Song WP, Ni PZ, Zhang WZ, Wu X
- 11425** Three-dimensional inlay-guided endodontics applied in variant root canals: A case report and review of literature
Yan YQ, Wang HL, Liu Y, Zheng TJ, Tang YP, Liu R
- 11437** Ectopic pregnancy implanted under the diaphragm: A rare case report
Wu QL, Wang XM, Tang D
- 11443** Ear ischemia induced by endovascular therapy for arteriovenous fistula of the sigmoid sinus: A case report
Li W, Zhang SS, Gao XR, Li YX, Ge HJ
- 11448** Giant schwannoma of thoracic vertebra: A case report
Zhou Y, Liu CZ, Zhang SY, Wang HY, Nath Varma S, Cao LQ, Hou TT, Li X, Yao BJ
- 11457** Severe digital ischemia coexists with thrombocytopenia in malignancy-associated antiphospholipid syndrome: A case report and review of literature
Chen JL, Yu X, Luo R, Liu M
- 11467** Rare spontaneous extensive annular intramural esophageal dissection with endoscopic treatment: A case report
Hu JW, Zhao Q, Hu CY, Wu J, Lv XY, Jin XH

- 11475** Mucinous cystic neoplasm of the liver: A case report
Yu TY, Zhang JS, Chen K, Yu AJ
- 11482** Retroperitoneal parasitic fetus: A case report
Xia B, Li DD, Wei HX, Zhang XX, Li RM, Chen J
- 11487** De novo mutation loci and clinical analysis in a child with sodium taurocholate cotransport polypeptide deficiency: A case report
Liu HY, Li M, Li Q
- 11495** Surgery for hepatocellular carcinoma with tumor thrombosis in inferior vena cava: A case report
Zhang ZY, Zhang EL, Zhang BX, Zhang W

LETTER TO THE EDITOR

- 11504** Advantages and issues of concern regarding approaches to peripheral nerve block for total hip arthroplasty
Crisci M, Cuomo A, Forte CA, Bimonte S, Esposito G, Tracey MC, Cascella M

ABOUT COVER

Editorial Board Member of *World Journal of Clinical Cases*, Moises Rodriguez-Gonzalez, MD, Adjunct Professor, Senior Researcher, Department of Pediatric Cardiology, Hospital Universitario Puerta del Mar, Cadiz 11009, Spain. doctormoisesrodriguez@gmail.com

AIMS AND SCOPE

The primary aim of *World Journal of Clinical Cases* (WJCC, *World J Clin Cases*) is to provide scholars and readers from various fields of clinical medicine with a platform to publish high-quality clinical research articles and communicate their research findings online.

WJCC mainly publishes articles reporting research results and findings obtained in the field of clinical medicine and covering a wide range of topics, including case control studies, retrospective cohort studies, retrospective studies, clinical trials studies, observational studies, prospective studies, randomized controlled trials, randomized clinical trials, systematic reviews, meta-analysis, and case reports.

INDEXING/ABSTRACTING

The WJCC is now indexed in Science Citation Index Expanded (also known as SciSearch®), Journal Citation Reports/Science Edition, Scopus, PubMed, and PubMed Central. The 2021 Edition of Journal Citation Reports® cites the 2020 impact factor (IF) for WJCC as 1.337; IF without journal self cites: 1.301; 5-year IF: 1.742; Journal Citation Indicator: 0.33; Ranking: 119 among 169 journals in medicine, general and internal; and Quartile category: Q3. The WJCC's CiteScore for 2020 is 0.8 and Scopus CiteScore rank 2020: General Medicine is 493/793.

RESPONSIBLE EDITORS FOR THIS ISSUE

Production Editor: Ji-Hong Lin; Production Department Director: Xu Guo; Editorial Office Director: Jin-Lei Wang.

NAME OF JOURNAL

World Journal of Clinical Cases

ISSN

ISSN 2307-8960 (online)

LAUNCH DATE

April 16, 2013

FREQUENCY

Thrice Monthly

EDITORS-IN-CHIEF

Bao-Gan Peng

EDITORIAL BOARD MEMBERS

<https://www.wjnet.com/2307-8960/editorialboard.htm>

PUBLICATION DATE

December 26, 2021

COPYRIGHT

© 2021 Baishideng Publishing Group Inc

INSTRUCTIONS TO AUTHORS

<https://www.wjnet.com/bpg/gerinfo/204>

GUIDELINES FOR ETHICS DOCUMENTS

<https://www.wjnet.com/bpg/GerInfo/287>

GUIDELINES FOR NON-NATIVE SPEAKERS OF ENGLISH

<https://www.wjnet.com/bpg/gerinfo/240>

PUBLICATION ETHICS

<https://www.wjnet.com/bpg/GerInfo/288>

PUBLICATION MISCONDUCT

<https://www.wjnet.com/bpg/gerinfo/208>

ARTICLE PROCESSING CHARGE

<https://www.wjnet.com/bpg/gerinfo/242>

STEPS FOR SUBMITTING MANUSCRIPTS

<https://www.wjnet.com/bpg/GerInfo/239>

ONLINE SUBMISSION

<https://www.f6publishing.com>

De novo mutation loci and clinical analysis in a child with sodium taurocholate cotransport polypeptide deficiency: A case report

Hui-Yan Liu, Meng Li, Qi Li

ORCID number: Hui-Yan Liu 0000-0002-6940-1633; Meng Li 0000-0002-2908-635X; Qi Li 0000-0002-9012-4562.

Author contributions: Liu HY, Li M and Li Q performed the diagnostic investigations and treatments; Liu HY reviewed the literature and contributed to manuscript drafting; Li M and Li Q revised the manuscript; all authors issued final approval for the version to be submitted.

Informed consent statement:

Informed written consent was obtained from the patient for publication of this report and any accompanying images.

Conflict-of-interest statement: The authors declare that they have no conflicts of interest.

CARE Checklist (2016) statement:

The authors have read the CARE Checklist (2016), and the manuscript was prepared and revised according to the CARE Checklist (2016).

Supported by Yunnan Science Foundation Project, No. 2019-81960102.

Country/Territory of origin: China

Specialty type: Pediatrics

Provenance and peer review:

Hui-Yan Liu, Meng Li, Qi Li, Department of Pediatrics, the First Affiliated Hospital of Kunming Medical University, Kunming 650000, Yunnan Province, China

Corresponding author: Qi Li, PhD, Professor, Department of Pediatrics, the First Affiliated Hospital of Kunming Medical University, No. 295 Xichang Road, Kunming 650000, Yunnan Province, China. 412289442@qq.com

Abstract

BACKGROUND

Sodium taurocholate cotransport polypeptide (NTCP) deficiency disease is a genetic metabolic disorder due to mutations in the *SLC10A1* gene and impaired bile acid salt uptake by the basolateral membrane transport protein NTCP in hepatocytes. A variety of clinical manifestations and genetic mutation loci have been reported for this disease. However, specific therapeutic measures are lacking, and the long-term effects are unknown.

CASE SUMMARY

An infant with elevated bile acids and behavioral neurodevelopmental delay failed to respond to bile acid-lowering therapy. Genetic testing for metabolic liver disease revealed that the child had NTCP deficiency due to the *SLC10A1* mutation: *c.422dupA (p.Y141X)*, which is a novel mutation site. The current follow-up revealed a gradual decrease in bile acid levels after 1 year of age, but the child still had behavioral neurodevelopmental delays.

CONCLUSION

The clinical manifestations, genetic characteristics, treatment and long-term prognosis due to NTCP deficiency remain poorly defined and need to be further confirmed by more studies and reports.

Key Words: Sodium taurocholate cotransport polypeptide; *SLC10A1* gene; Hypercholesterolemia; Behavioral neurodevelopmental delay; Children; Case report

©The Author(s) 2021. Published by Baishideng Publishing Group Inc. All rights reserved.

Core Tip: The mutation loci and clinical manifestations of sodium taurocholate

Unsolicited article; Externally peer reviewed.

Peer-review model: Single blind

Peer-review report's scientific quality classification

Grade A (Excellent): 0

Grade B (Very good): 0

Grade C (Good): C, C

Grade D (Fair): 0

Grade E (Poor): 0

Open-Access: This article is an open-access article that was selected by an in-house editor and fully peer-reviewed by external reviewers. It is distributed in accordance with the Creative Commons Attribution NonCommercial (CC BY-NC 4.0) license, which permits others to distribute, remix, adapt, build upon this work non-commercially, and license their derivative works on different terms, provided the original work is properly cited and the use is non-commercial. See: <http://creativecommons.org/licenses/by-nc/4.0/>

Received: August 14, 2021

Peer-review started: August 14, 2021

First decision: September 29, 2021

Revised: October 10, 2021

Accepted: November 18, 2021

Article in press: November 18, 2021

Published online: December 26, 2021

P-Reviewer: Navarrete Arellano M, Rodrigues AT

S-Editor: Wang JL

L-Editor: Filipodia

P-Editor: Wang JL



cotransport polypeptide deficiency disease are currently under further investigation. Our case emphasizes the need to re-examine the clinical manifestations, prognosis and interventions associated with hypercholesterolemia due to this disease and suggests that behavioral neurodevelopmental delay may also be a clinical manifestation of this disease.

Citation: Liu HY, Li M, Li Q. De novo mutation loci and clinical analysis in a child with sodium taurocholate cotransport polypeptide deficiency: A case report. *World J Clin Cases* 2021; 9(36): 11487-11494

URL: <https://www.wjgnet.com/2307-8960/full/v9/i36/11487.htm>

DOI: <https://dx.doi.org/10.12998/wjcc.v9.i36.11487>

INTRODUCTION

Sodium taurocholate cotransport polypeptide (NTCP) is a carrier protein encoded by solute carrier family 10 member 1 (*SLC10A1*), 23 kbp in length, located on chromosome 14q24.2 and containing five exons. The protein product, NTCP, consists of 349 amino acid residues and has a molecular weight of 38 kDa. NTCP is located in the basolateral membrane of hepatocytes and is a sodium-dependent transporter protein involved in the transport of bile acids from the blood to the hepatocytes to maintain the uninterrupted hepatic-intestinal circulation of bile salts, and its deficiency leads to elevated levels of bile acids in the blood (hypercholesterolemia)[1-3]. Several genetic mutation loci have been found to contribute to the disease, with hypercholestasis as the main manifestation and some cases accompanied by disorders of lipid metabolism and cholestatic liver disease. Here, we report a case of a newly identified mutated locus and suggest that behavioral neurodevelopmental delay may also be a clinical manifestation of the disease.

CASE PRESENTATION

Chief complaints

Elevated bile acids in an 11-mo-old patient.

History of present illness

The child was hospitalized in a local hospital after birth due to a "neonatal infection". After improvement of liver function, she was found to have elevated bile acids and was discharged from the hospital after treatment with "anti-infective drugs and ursodeoxycholic acid" to promote bile acid excretion and continued to take "ursodeoxycholic acid (15 mg/kg per time, bid)" for more than 9 mo after discharge. The bile acid level did not improve significantly. There was no history of vomiting and diarrhea during the disease, no yellow staining of skin and sclera, no voluntary scratching and no white clay-like stools. Mental, diet and sleep condition were sound, and urine and stool were normal.

History of past illness

The child was hospitalized in a local hospital after birth due to a "neonatal infection".

Personal and family history

The child was a gestation 3 production 3, gestational age 39 wk, born at full term, birth weight 2970 g, head held up at 3 mo after birth, could sit up on her own and recognize people at 7 mo, can crawl at present, cannot stand unassisted, can babble and combine vowels and consonants, like 'ma ma ma ma' and 'da da da da,' can wave goodbye and has other gestures. Her parents denied any history of trauma, surgery or blood transfusion, and there were no special circumstances with her family history. Both of her parents and two elder brothers had no elevated bile acids, and her motor-intellectual development was normal.

Physical examination

Body temperature 36.4 °C, respiration 32 times/min, heart rate 112 times/min, weight 9 kg (percentiles (P) 50-75), height 75 cm (P75) and head circumference 43 cm (P25-50). General condition: no yellowish staining of the skin; no pigmentation; no petechiae and hemorrhages; no enlargement of superficial lymph nodes; no deformity of skull and facial features; fontane 0.3 cm × 0.3 cm; the sclera was not yellowish; the lips and mouth were pink; the heart and lungs functioned properly; the abdomen was in proper condition; the liver and spleen were not enlarged; and the nervous system functioned properly.

Psychomotor development assessment: the development screen test, an intelligence development screening test for children aged 0-6 years in China, showed a developmental quotient of 73, which is equivalent to 8 mo of age for intellectual development, 8 mo of age for motor development and 10 mo of age for social adaptation, with suspected psychomotor developmental delay (test results of developmental quotient 70-84 are considered suspicious).

Laboratory examinations

Blood, urine and stool routine were in proper condition. Liver function was shown in Table 1. No abnormal laboratory results of renal function, cardiac enzymes, thyroid function, serum ion, anemia and blood lipids were found. Immunoglobulin and complement assay were in proper condition. Epstein-Barr virus DNA was negative. Cytomegalovirus DNA was negative. Hepatitis pathogenesis qualitative set were negative, and 25-hydroxy vitamin D level was mildly deficient (57 ng/mL, reference value less than 60 ng/mL is deficiency).

Further examination: in conjunction with the child's medical history and clinical presentation, genetic testing for metabolic liver disease revealed a pure mutation in the *SLC10A1* gene at *c.422dupA*, resulting in a nonsense mutation in amino acid *p.Y141X* (see Figure 1). According to the American College of Medical Genetics guidelines, this mutation was judged to be pathogenic, but there were no reports of mutations at this locus in the literature database and no results of pathogenicity analysis. The parents of the child were both heterozygous for this locus by lineage verification analysis. In the present case, the child was female, and both parents were carriers of the heterozygous variant. Both had no clinical manifestations, consistent with autosomal recessive inheritance.

Imaging examinations

Abdominal ultrasound: no abnormality was found in liver, biliary tract, pancreas and spleen.

FINAL DIAGNOSIS

NTCP deficiency disease.

TREATMENT

She was treated with phenobarbital, rifampicin and difenacoum for 2 wk, vitamin D supplementation, intensive psycho-behavioral developmental interventions and other symptomatic supportive treatments, with no significant decrease in bile acids and normal liver enzymes on dynamic review.

OUTCOME AND FOLLOW-UP

After the age of 1 year, the bile acid level of this child showed a gradual decrease to a level of about 130 µmol/L. There was no liver enzyme damage, no skin pruritus and no white clay-like stools. Current follow-up at 20 mo 4 d, the child's head circumference was 46 cm (P50), length was 80 cm (P75), weight was 11.5 kg (P50-75). The results of the Gesell Developmental Diagnostic Scale: gross motor score was 89 at the normal state (developmental age 17.8 mo); fine motor score was 77 at the borderline state (developmental age 15.4 mo); adaptive ability score was 78 at borderline state (developmental age 15.6 mo); language ability score was 70 at the delayed state

Table 1 Dynamic changes of liver function in the patient

Age (mo)	Day 5	2 mo 20 d	5 mo 20 d	9 mo	9 mo 16 d	10 mo 17 d	11 mo 2 d	11 mo 17 d	12 mo	13 mo 15 d	17 mo	20 mo
Total protein (65-85 g/L)	49	56.6	60.1	61.4	64.4	74.2	66.1	68.5	69	72	65.5	67
Glutamic pyruvic transaminase(7-40 μ/L)	43.2	45.4	40.2	38.4	42.6	61.8	21.9	8.7	11.2	32.2	18	21
Glutamic oxaloacetic transaminase (13-35 μ/L)	32.0	40.9	31.0	23.3	35.1	86.6	37.4	30.8	32.0	35.8	39.0	35.0
Albumin (40-55 g/L)	30.5	41.4	42.7	40.7	42.5	43.9	40.1	44.2	43.0	47.0	40.6	42.0
Alkaline phosphatase (< 28 IU/L)	400.0	573.6	572.0	479.2	384.2	327.0	336.0	461.7	432.0	342.9	472.0	435.0
Total bilirubin (3.4-17.1 μmol/L)	131.5	7.0	3.9	3.1	5.4	3.8	2.9	3.6	3.0	4.5	5.7	5.2
Indirect bilirubin (≤ 3.4 μmol/L)	126.3	3.3	2.3	2.6	3.0	1.3	2.4	3.1	2.5	3.2	2.4	2.8
Direct bilirubin (1.7-10.2 μmol/L)	5.2	3.6	1.6	0.5	2.4	2.5	0.5	0.5	0.5	1.3	3.3	2.4
Total bile acid (≤ 10 μmol/L)	231.9	193.0	239.6	235.1	210.7	543.3	576.1	533.0	220.0	180.2	145.4	137.0

(developmental age 14.0 mo); and personal-social development score was 75 at the delayed state (developmental age 15.0 mo). The child was not developing well except for gross motor development. The family was advised to strengthen the psycho-behavioral developmental intervention and follow up on the clinical and biochemical characteristics of the child.

DISCUSSION

NTCP deficiency disease is a newly identified genetic metabolic disorder characterized by significant and persistent hypercholesterolemia. As of July 2021, more than 90 cases of NTCP deficiency have been reported in 12 studies, with a common feature of hypercholestasis, an inheritance pattern consistent with autosomal recessive inheritance, and possible involvement in the development of neonatal hyperbilirubinemia, early infantile cholestasis and gestational cholestasis[4-15]. NTCP deficiency disorders currently lack specific treatment. *SLC10A1* gene analysis can help to confirm the diagnosis in patients with this disease in time while avoiding unnecessary tests and interventions[7]. The *SLC10A1* gene variant *c.800C > T* (*p.Ser267Phe*) is the most common among reported patients with NTCP-deficient disease[12], especially in Southeast Asian patients, with an allele frequency of 95.5%[13] and occupies an absolute dominance in the *SLC10A1* variant spectrum. In addition, *c.263T > C* (*p.Ile88Thr*)[14], *c.755G > A* (*p.Arg252His*)[4], *c.615 618del* (*p.Ser206Profs* 12*)[15], *c.595A > C* (*p.Ser199Arg*)[11] and other *SLC10A1* variant types were detected. However, the *c.422dupA* (*p.Y141X*) mutation locus, in this case, has not been reported, and the new

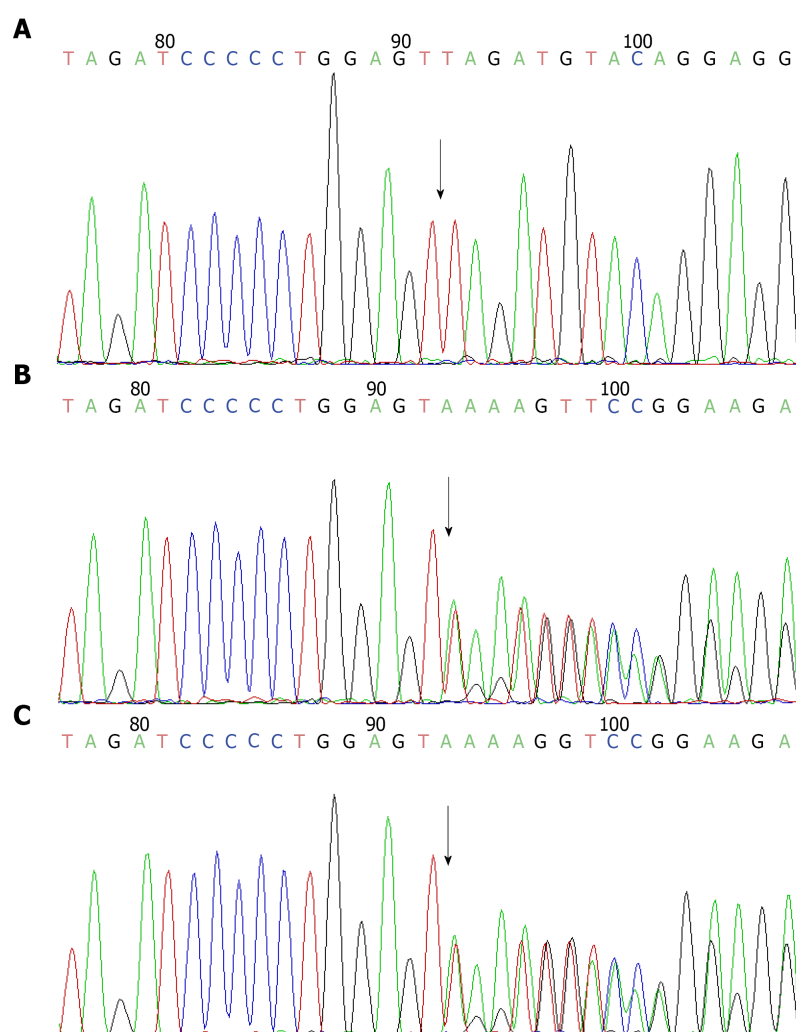


Figure 1 Sanger sequencing of the *SLC10A1* gene of the child and parents. A: Child; B: Father; C: Mother.

nonsense variant *c.422dupA* (*p.Y141X*) enriches the *SLC10A1* mutation spectrum and clinical manifestations in a child with elevated bile acids as the predominant phenotype with motor mental retardation.

The first international case of an NTCP-deficient child was reported in 2015 by Dutch authors with a mutation at *c.755G > A* (*p. Arg252His*) and a clinical phenotype of extremely elevated bile acids (up to 1500 μM , reference value < 16.3), accompanied by mild hypotonia, growth retardation and delayed motor milestones[4]. As reported in the latest follow-up, the child remained developmentally delayed and required special education but had normal height and weight development. Another case reported total bile acid levels exceeding 1000 $\mu\text{mol/L}$ until 4 years of age but gradually decreasing to between 500 and 800 $\mu\text{mol/L}$ after 5 years of age[16]. In other case reports of *SLC10A1* mutations, hypercholesterolemia was usually reported as the main manifestation, with some cases accompanied by clinical phenotypes such as disorders of lipid metabolism and cholestatic liver disease.

Multiple clinical studies have reported that *c.800C > T* (*p.Ser267Phe*)[6], *c.595A > C* (*p.Ser199Arg*)[11], *c.263T > C* (*p.Ile88Thr*)[14] and *c.615 618del* (*p. Ser206Profs* 12*)[15] loci mutations were found in patients with dyslipidemia and sex hormone disorders, and NTCP deficient individuals were more prone to vitamin D deficiency, sex hormone disorder and dyslipidemia. In a literature report[7], children with *c.800C > T* (*p.Ser267Phe*) pure mutation were between 25% and 75% of the same age group in terms of height and weight, 61% had jaundice (yellowing of eyes or skin), 23.1% had hepatomegaly and proceeded with histopathological features including hepatocyte destruction, periportal inflammation and fibrosis, resembling mild chronic viral hepatitis. In addition, Chen *et al*[10] reported that 2 patients with NTCP deficiency with pure mutations of *p. Ser267Phe* had intracranial pressure in late gestation. In summary, previous studies have reported that hypercholesterolemia is the main

manifestation of the disease, and some cases are associated with lipid metabolism disorders and cholestatic liver disease. Most scholars believe that the manifestation of motor retardation in NTCP-deficient children is still a mystery except the first international report of a child with NTCP deficiency who had mild hypotonia and growth retardation clinical phenotype. However, in the context of this paper, we should re-examine the clinical manifestations, prognosis and interventions related to hypercholesterolemia caused by this disease, and behavioral neurodevelopmental delay may also be one of the clinical manifestations of this disease.

In addition to NTCP, there are also *OATP1B1* and *OATP1B3* (encoded by *SLCO1B1* and *SLCO1B3*, respectively), which also function in the uptake of bilirubin into hepatocytes[17,18]. In animal experiments by Roscam Abbing *et al*[19], it was shown that due to the strong compensatory effect of *OATP1B1/1B3*, mice were able to maintain normal plasma total bile acid levels even when NTCP uptake function was inhibited. However, normal bile acids do not predict an unimpaired liver function, and it was found that the compensation of *OATP1B3* can lead to bile deposition in hepatocytes. Over time the massive deposition of bile pigments can lead to damage of hepatocytes and bile ducts and even increase the risk of gallstones[20,21]. Similarly, Mao *et al*[22] observed in an animal test model of knockout mice with *SLC10A1* gene that *SLC10A1* deficiency resulted in various abnormal manifestations of the gallbladder, including gallbladder wall thickening, gallbladder enlargement (wall thickening), gallbladder enlargement with black-green bile and diaphragm cap malformation. Furthermore, in an animal model by Zhang *et al*[23], it was observed that the metabolism of tyrosine, glycine, taurine, fatty acids and glycerophospholipids as well as the biosynthesis of tryptophan, pantothenic acid and coenzyme A were significantly dysregulated in NTCP knockout mice by metabolic pathway analysis, suggesting that NTCP is closely associated with these metabolic pathways. It is worth suggesting that several amino acids such as tyrosine and tryptophan are closely related to neurological development in humans; thus, the developmental delay associated with NTCP deficiency disease should be taken seriously. Whether it is related to abnormal metabolic pathways should be further investigated.

There is a lack of specific therapeutic agents for NTCP-deficient disease; symptomatic supportive therapy is the main management. The long-term effects of long-term hypercholesterolemia are unknown. According to the current study data, the disease lacks specific therapeutic measures, but the short-term clinical outcome of patients tends to be good, and no serious adverse prognosis such as death or cirrhosis due to this disease has been reported so far[4-16]. Therefore, no other relevant medication has been given in this case for the time being.

CONCLUSION

The clinical phenotype, genetic features, treatment and long-term prognosis due to NTCP deficiency disease are still poorly defined and need to be further confirmed by more studies and findings. However, to summarize the current literature, hypercholesterolemia is the main manifestation of the disease. Lipid metabolism disorders, cholestatic liver disease and mental-behavioral developmental delay may also be clinical phenotypes. According to current research data, the disease lacks specific therapeutic measures and requires further research findings and follow-up. Thus, in children with persistent hypercholesterolemia, *SLC10A1* can be used as the primary screening gene test, and the child's growth and development, liver function, 25-hydroxy vitamin D, lipids, sex hormones and other biochemical indicators related to lipid metabolism should be closely monitored for a comprehensive assessment to achieve a better outcome for this group of children.

ACKNOWLEDGEMENTS

We would like to thank the patients and their families for their participation in this study.

REFERENCES

- 1 Hagenbuch B, Meier PJ. Molecular cloning, chromosomal localization, and functional

- characterization of a human liver Na⁺/bile acid cotransporter. *J Clin Invest* 1994; **93**: 1326-1331 [PMID: 8132774 DOI: 10.1172/JCI117091]
- 2 **Hagenbuch B**, Dawson P. The sodium bile salt cotransport family SLC10. *Pflugers Arch* 2004; **447**: 566-570 [PMID: 12851823 DOI: 10.1007/s00424-003-1130-z]
 - 3 **Anwer MS**, Stieger B. Sodium-dependent bile salt transporters of the SLC10A transporter family: more than solute transporters. *Pflugers Arch* 2014; **466**: 77-89 [PMID: 24196564 DOI: 10.1007/s00424-013-1367-0]
 - 4 **Vaz FM**, Paulusma CC, Huidekoper H, de Ru M, Lim C, Koster J, Ho-Mok K, Bootsma AH, Groen AK, Schaap FG, Oude Elferink RP, Waterham HR, Wanders RJ. Sodium taurocholate cotransporting polypeptide (SLC10A1) deficiency: conjugated hypercholanemia without a clear clinical phenotype. *Hepatology* 2015; **61**: 260-267 [PMID: 24867799 DOI: 10.1002/hep.27240]
 - 5 **Zou TT**, Zhu Y, Wan CM, Liao Q. Clinical features of sodium-taurocholate cotransporting polypeptide deficiency in pediatric patients: case series and literature review. *Transl Pediatr* 2021; **10**: 1045-1054 [PMID: 34012853 DOI: 10.21037/tp-20-360]
 - 6 **Liu R**, Chen C, Xia X, Liao Q, Wang Q, Newcombe PJ, Xu S, Chen M, Ding Y, Li X, Liao Z, Li F, Du M, Huang H, Dong R, Deng W, Wang Y, Zeng B, Pan Q, Jiang D, Zeng H, Sham P, Cao Y, Maxwell PH, Gao ZL, Peng L. Homozygous p.Ser267Phe in SLC10A1 is associated with a new type of hypercholanemia and implications for personalized medicine. *Sci Rep* 2017; **7**: 9214 [PMID: 28835676 DOI: 10.1038/s41598-017-07012-2]
 - 7 **Dong C**, Zhang BP, Wang H, Xu H, Zhang C, Cai ZS, Wang DW, Shu SN, Huang ZH, Luo XP. Clinical and histopathologic features of sodium taurocholate cotransporting polypeptide deficiency in pediatric patients. *Medicine (Baltimore)* 2019; **98**: e17305 [PMID: 31574858 DOI: 10.1097/MD.00000000000017305]
 - 8 **Li H**, Qiu JW, Lin GZ, Deng M, Lin WX, Cheng Y, Song YZ. Clinical and genetic analysis of a pediatric patient with sodium taurocholate cotransporting polypeptide deficiency. *Zhongguo Dang Dai Er Ke Za Zhi* 2018; **20**: 279-284 [PMID: 29658451 DOI: 10.7499/j.issn.1008-8830.2018.04.005]
 - 9 **Yan YY**, Wang MX, Gong JY, Liu LL, Setchell KDR, Xie XB, Wang NL, Li W, Wang JS. Abnormal Bilirubin Metabolism in Patients With Sodium Taurocholate Cotransporting Polypeptide Deficiency. *J Pediatr Gastroenterol Nutr* 2020; **71**: e138-e141 [PMID: 33093374 DOI: 10.1097/MPG.0000000000002862]
 - 10 **Chen R**, Deng M, Rauf YM, Lin GZ, Qiu JW, Zhu SY, Xiao XM, Song YZ. Intrahepatic Cholestasis of Pregnancy as a Clinical Manifestation of Sodium-Taurocholate Cotransporting Polypeptide Deficiency. *Tohoku J Exp Med* 2019; **248**: 57-61 [PMID: 31142693 DOI: 10.1620/tjem.248.57]
 - 11 **Li H**, Deng M, Guo L, Qiu JW, Lin GZ, Long XL, Xiao XM, Song YZ. Clinical and molecular characterization of four patients with NTCP deficiency from two unrelated families harboring the novel SLC10A1 variant c.595A > C (p.Ser199Arg). *Mol Med Rep* 2019; **20**: 4915-4924 [PMID: 31661128 DOI: 10.3892/mmr.2019.10763]
 - 12 **Deng M**, Mao M, Guo L, Chen FP, Wen WR, Song YZ. Clinical and molecular study of a pediatric patient with sodium taurocholate cotransporting polypeptide deficiency. *Exp Ther Med* 2016; **12**: 3294-3300 [PMID: 27882152 DOI: 10.3892/etm.2016.3752]
 - 13 **Tan HJ**, Deng M, Qiu JW, Wu JF, Song YZ. Monozygotic Twins Suffering From Sodium Taurocholate Cotransporting Polypeptide Deficiency: A Case Report. *Front Pediatr* 2018; **6**: 354 [PMID: 30525015 DOI: 10.3389/fped.2018.00354]
 - 14 **Qiu JW**, Deng M, Cheng Y, Atif RM, Lin WX, Guo L, Li H, Song YZ. Sodium taurocholate cotransporting polypeptide (NTCP) deficiency: Identification of a novel *SLC10A1* mutation in two unrelated infants presenting with neonatal indirect hyperbilirubinemia and remarkable hypercholanemia. *Oncotarget* 2017; **8**: 106598-106607 [PMID: 29290974 DOI: 10.18632/oncotarget.22503]
 - 15 **Van Herpe F**, Waterham HR, Adams CJ, Mannens M, Bikker H, Vaz FM, Cassiman D. NTCP deficiency and persistently raised bile salts: an adult case. *J Inher Metab Dis* 2017; **40**: 313-315 [PMID: 28283843 DOI: 10.1007/s10545-017-0031-9]
 - 16 **Vaz FM**, Huidekoper HH, Paulusma CC. Extended Abstract: Deficiency of Sodium Taurocholate Cotransporting Polypeptide (SLC10A1): A New Inborn Error of Metabolism with an Attenuated Phenotype. *Dig Dis* 2017; **35**: 259-260 [PMID: 28249272 DOI: 10.1159/000450984]
 - 17 **Van Dyke RW**, Stephens JE, Scharschmidt BF. Bile acid transport in cultured rat hepatocytes. *Am J Physiol* 1982; **243**: G484-G492 [PMID: 7149031 DOI: 10.1152/ajpgi.1982.243.6.G484]
 - 18 **Hagenbuch B**, Meier PJ. The superfamily of organic anion transporting polypeptides. *Biochim Biophys Acta* 2003; **1609**: 1-18 [PMID: 12507753 DOI: 10.1016/s0005-2736(02)00633-8]
 - 19 **Roscam Abbing RLP**, Slijepcevic D, Donkers JM, Havinga R, Duijst S, Paulusma CC, Kuiper J, Kuipers F, Groen AK, Oude Elferink RPJ, van de Graaf SFJ. Blocking Sodium-Taurocholate Cotransporting Polypeptide Stimulates Biliary Cholesterol and Phospholipid Secretion in Mice. *Hepatology* 2020; **71**: 247-258 [PMID: 31136002 DOI: 10.1002/hep.30792]
 - 20 **Appleby RN**, Nolan JD, Johnston IM, Pattni SS, Fox J, Walters JR. Novel associations of bile acid diarrhoea with fatty liver disease and gallstones: a cohort retrospective analysis. *BMJ Open Gastroenterol* 2017; **4**: e000178 [PMID: 29119003 DOI: 10.1136/bmjgast-2017-000178]
 - 21 **Wang G**, Han T, Wang S, Chen M, Sun Y, Fu Z. Peroxisome Proliferator-Activated Receptor- γ Prevents Cholesterol Gallstone Formation in C57bl Mice by Regulating Bile Acid Synthesis and Enterohepatic Circulation. *Biomed Res Int* 2018; **2018**: 7475626 [PMID: 30105244 DOI: 10.1155/2018/7475626]

- 22 **Mao F**, Wang MX, Hou X, Zhou Z, Yan YY, Fang LJ, Tan Z, Fang WY, Liu T, He W, Li C, Xie XB, Lu SQ, Sui J, Wang F, Han J, Wang JS, Li W. NTCP Deficiency Causes Gallbladder Abnormalities in Mice and Human Beings. *Cell Mol Gastroenterol Hepatol* 2021; **11**: 831-839 [PMID: [32919083](#) DOI: [10.1016/j.jcmgh.2020.09.001](#)]
- 23 **Zhang Q**, He Z, Liu Z, Gong L. Integrated plasma and liver gas chromatography mass spectrometry and liquid chromatography mass spectrometry metabolomics to reveal physiological functions of sodium taurocholate cotransporting polypeptide (NTCP) with an Ntcp knockout mouse model. *J Chromatogr B Analyt Technol Biomed Life Sci* 2021; **1165**: 122531 [PMID: [33545502](#) DOI: [10.1016/j.jchromb.2021.122531](#)]



Published by **Baishideng Publishing Group Inc**
7041 Koll Center Parkway, Suite 160, Pleasanton, CA 94566, USA

Telephone: +1-925-3991568

E-mail: bpgoffice@wjgnet.com

Help Desk: <https://www.f6publishing.com/helpdesk>

<https://www.wjgnet.com>

