

# World Journal of *Clinical Cases*

*World J Clin Cases* 2022 March 26; 10(9): 2660-2975



## Contents

Thrice Monthly Volume 10 Number 9 March 26, 2022

### REVIEW

- 2660** Role of metabolites derived from gut microbiota in inflammatory bowel disease  
*Zheng L, Wen XL, Duan SL*

### MINIREVIEWS

- 2678** Roles of Wnt/ $\beta$ -catenin signaling pathway related microRNAs in esophageal cancer  
*Chu CY, Wang R, Liu XL*
- 2687** Animal models applied to acute-on-chronic liver failure: Are new models required to understand the human condition?  
*Gama JFG, Cardoso LMDF, Lagrota-Candido JM, Alves LA*

### ORIGINAL ARTICLE

#### Case Control Study

- 2700** Associations between coagulation factor XII, coagulation factor XI, and stability of venous thromboembolism: A case-control study  
*Meng Y, Li Y, Ye YJ, Ma Q, Zhang JB, Qin H, Deng YY, Tian HY*

#### Retrospective Cohort Study

- 2710** Nomogram to predict the risk of endoscopic removal failure with forceps/baskets for treating submandibular stones  
*Huang Y, Liang PS, Yang YC, Cai WX, Tao Q*
- 2721** Association between anesthesia technique and complications after hip surgery in the elderly population  
*Guo LS, Wang LN, Xiao JB, Zhong M, Zhao GF*

#### Retrospective Study

- 2733** Perforating and nonperforating indications in repeated surgeries for Crohn's disease  
*Shen WS, Huang XH, Liu RQ, Li CY, Li Y, Zhu WM*
- 2743** Treatment of *Pneumocystis jirovecii* pneumonia in non-human immunodeficiency virus-infected patients using a combination of trimethoprim-sulfamethoxazole and caspofungin  
*Wu HH, Fang SY, Chen YX, Feng LF*
- 2751** Acute kidney injury in traumatic brain injury intensive care unit patients  
*Huang ZY, Liu Y, Huang HF, Huang SH, Wang JX, Tian JF, Zeng WX, Lv RG, Jiang S, Gao JL, Gao Y, Yu XX*
- 2764** Enucleation combined with guided bone regeneration in small and medium-sized odontogenic jaw cysts  
*Cao YT, Gu QH, Wang YW, Jiang Q*

**Clinical Trials Study**

- 2773 Determination of the ED<sub>95</sub> of intranasal sufentanil combined with intranasal dexmedetomidine for moderate sedation during endoscopic ultrasonography

Zou Y, Li N, Shao LJZ, Liu FK, Xue FS, Tao X

**Observational Study**

- 2783 Overexpression of Ubiquilin4 is associated with poor prognosis in patients with cervical cancer

Wang LN, Huang KJ, Wang L, Cheng HY

**Randomized Clinical Trial**

- 2792 Peplau's interpersonal relationship theory combined with bladder function training on patients with prostate cancer

Yang XH, Wu LF, Yan XY, Zhou Y, Liu X

**SYSTEMATIC REVIEWS**

- 2801 Efficacy of bone grafts in jaw cystic lesions: A systematic review

Wang J, Yao QY, Zhu HY

**CASE REPORT**

- 2811 Short stature associated with a novel mutation in the aggrecan gene: A case report and literature review

Yin LP, Zheng HX, Zhu H

- 2818 Treatment with sorafenib plus camrelizumab after splenectomy for primary splenic angiosarcoma with liver metastasis: A case report and literature review

Pan D, Li TP, Xiong JH, Wang SB, Chen YX, Li JF, Xiao Q

- 2829 Sarcomatoid intrahepatic cholangiocarcinoma with good patient prognosis after treatment with Huaier granules following hepatectomy: A case report

Feng JY, Li XP, Wu ZY, Ying LP, Xin C, Dai ZZ, Shen Y, Wu YF

- 2836 Sequential occurrence of T790M mutation and small cell lung cancer transformation in EGFR-positive lung adenocarcinoma: A case report

Hong E, Chen XE, Mao J, Zhou JJ, Chen L, Xu JY, Tao W

- 2844 Early diagnosis of Gitelman syndrome in a young child: A case report

Wu CY, Tsai MH, Chen CC, Kao CH

- 2851 Congenital intestinal malrotation with gastric wall defects causing extensive gut necrosis and short gut syndrome: A case report

Wang Y, Gu Y, Ma D, Guo WX, Zhang YF

- 2858 Delusional parasitosis as premotor symptom of parkinson's disease: A case report

Oh M, Kim JW, Lee SM

- 2864** Laninamivir-induced ischemic enterocolitis: A case report  
*Suzuki C, Kenzaka T*
- 2871** Intramural pregnancy after *in vitro* fertilization and embryo transfer: A case report  
*Xie QJ, Li X, Ni DY, Ji H, Zhao C, Ling XF*
- 2878** Bilateral ureteral reimplantation in a patient with an intraperitoneal ectopic bipenis: A case report  
*Jia YT, Shi BL, Zhang J, Li YY, Zhu J*
- 2883** Lumbar disc sequestration mimicking a tumor: Report of four cases and a literature review  
*Li ST, Zhang T, Shi XW, Liu H, Yang CW, Zhen P, Li SK*
- 2895** Parasitic leiomyoma in the trocar site after laparoscopic myomectomy: A case report  
*Roh CK, Kwon HJ, Jung MJ*
- 2901** Giant nontraumatic myositis ossificans in a child: A case report  
*Xia AN, Wang JS*
- 2908** Paradoxical carbon dioxide embolism during laparoscopic hepatectomy without intracardiac shunt: A case report  
*Jeon S, Hong JM, Lee HJ, Kim Y, Kang H, Hwang BY, Lee D, Jung YH*
- 2916** Local hyperthermia combined with chemotherapy for the treatment of multiple recurrences of undifferentiated pleomorphic sarcoma: A case report  
*Zhou YT, Wang RY, Zhang Y, Li DY, Yu J*
- 2923** Acute coronary artery stent thrombosis caused by a spasm: A case report  
*Meng LP, Wang P, Peng F*
- 2931** Turner syndrome with primary myelofibrosis, cirrhosis and ovarian cystic mass: A case report  
*Xu LW, Su YZ, Tao HF*
- 2938** Esophageal myoepithelial carcinoma: Four case reports  
*Lu H, Zhao HP, Liu YY, Yu J, Wang R, Gao JB*
- 2948** Ipsilateral hemifacial microsomia with dextrocardia and pulmonary hypoplasia: A case report  
*Guo R, Chang SH, Wang BQ, Zhang QG*
- 2954** Upper gastrointestinal bleeding from a Mallory-Weiss tear associated with transesophageal echocardiography during successful cardiopulmonary resuscitation: A case report  
*Tang MM, Fang DF, Liu B*
- 2961** Malignant struma ovarii with papillary carcinoma combined with retroperitoneal lymph node metastasis: A case report  
*Xiao W, Zhou JR, Chen D*



- 2969** Occult colon cancer with sepsis as the primary manifestation identified by bone marrow puncture: A case report

*Wang HJ, Zhou CJ*

**ABOUT COVER**

Editorial Board Member of *World Journal of Clinical Cases*, Arunchai Chang, MD, Assistant Professor, Lecturer, Staff Physician, Division of Gastroenterology, Department of Internal Medicine, Hatyai Hospital, Hatyai 90110, Songkhla, Thailand. busmdcu58@gmail.com

**AIMS AND SCOPE**

The primary aim of *World Journal of Clinical Cases* (WJCC, *World J Clin Cases*) is to provide scholars and readers from various fields of clinical medicine with a platform to publish high-quality clinical research articles and communicate their research findings online.

WJCC mainly publishes articles reporting research results and findings obtained in the field of clinical medicine and covering a wide range of topics, including case control studies, retrospective cohort studies, retrospective studies, clinical trials studies, observational studies, prospective studies, randomized controlled trials, randomized clinical trials, systematic reviews, meta-analysis, and case reports.

**INDEXING/ABSTRACTING**

The WJCC is now indexed in Science Citation Index Expanded (also known as SciSearch®), Journal Citation Reports/Science Edition, Scopus, PubMed, and PubMed Central. The 2021 Edition of Journal Citation Reports® cites the 2020 impact factor (IF) for WJCC as 1.337; IF without journal self cites: 1.301; 5-year IF: 1.742; Journal Citation Indicator: 0.33; Ranking: 119 among 169 journals in medicine, general and internal; and Quartile category: Q3. The WJCC's CiteScore for 2020 is 0.8 and Scopus CiteScore rank 2020: General Medicine is 493/793.

**RESPONSIBLE EDITORS FOR THIS ISSUE**

Production Editor: *Ying-Yi Yuan*, Production Department Director: *Xiang Li*, Editorial Office Director: *Jin-Lei Wang*.

**NAME OF JOURNAL**

*World Journal of Clinical Cases*

**ISSN**

ISSN 2307-8960 (online)

**LAUNCH DATE**

April 16, 2013

**FREQUENCY**

Thrice Monthly

**EDITORS-IN-CHIEF**

Bao-Gan Peng, Jerzy Tadeusz Chudek, George Kontogeorgos, Maurizio Serati, Ja Hyeon Ku

**EDITORIAL BOARD MEMBERS**

<https://www.wjgnet.com/2307-8960/editorialboard.htm>

**PUBLICATION DATE**

March 26, 2022

**COPYRIGHT**

© 2022 Baishideng Publishing Group Inc

**INSTRUCTIONS TO AUTHORS**

<https://www.wjgnet.com/bpg/gerinfo/204>

**GUIDELINES FOR ETHICS DOCUMENTS**

<https://www.wjgnet.com/bpg/GerInfo/287>

**GUIDELINES FOR NON-NATIVE SPEAKERS OF ENGLISH**

<https://www.wjgnet.com/bpg/gerinfo/240>

**PUBLICATION ETHICS**

<https://www.wjgnet.com/bpg/GerInfo/288>

**PUBLICATION MISCONDUCT**

<https://www.wjgnet.com/bpg/gerinfo/208>

**ARTICLE PROCESSING CHARGE**

<https://www.wjgnet.com/bpg/gerinfo/242>

**STEPS FOR SUBMITTING MANUSCRIPTS**

<https://www.wjgnet.com/bpg/GerInfo/239>

**ONLINE SUBMISSION**

<https://www.f6publishing.com>



Retrospective Study

# Enucleation combined with guided bone regeneration in small and medium-sized odontogenic jaw cysts

Yi-Ting Cao, Qin-Hua Gu, Yi-Wei Wang, Qian Jiang

**Specialty type:** Surgery

**Provenance and peer review:**

Unsolicited article; Externally peer reviewed.

**Peer-review model:** Single blind

**Peer-review report's scientific quality classification**

Grade A (Excellent): 0  
Grade B (Very good): B  
Grade C (Good): 0  
Grade D (Fair): 0  
Grade E (Poor): 0

**P-Reviewer:** Zhu H

**Received:** August 26, 2021

**Peer-review started:** August 26, 2021

**First decision:** November 17, 2021

**Revised:** November 26, 2021

**Accepted:** February 19, 2022

**Article in press:** February 19, 2022

**Published online:** March 26, 2022



**Yi-Ting Cao**, Department of Pediatric Dentistry, Shanghai Ninth People's Hospital, Shanghai Jiao Tong University School of Medicine; College of Stomatology, Shanghai Jiao Tong University; National Center for Stomatology; National Clinical Research Center for Oral Diseases; Shanghai Key Laboratory of Stomatology, Shanghai 200011, China

**Qin-Hua Gu**, Department of Stomatology, Shanghai Ninth People's Hospital Huangpu Branch, Shanghai Jiao Tong University, School of Medicine, Shanghai 200125, China

**Yi-Wei Wang**, Department of Oral Medicine, Huai'an Stomatological Hospital, Huai'an 223300, Jiangsu Province, China

**Qian Jiang**, Department of Oral Surgery, Shanghai Ninth People's Hospital, Shanghai Jiao Tong University School of Medicine; College of Stomatology, Shanghai Jiao Tong University; National Center for Stomatology; National Clinical Research Center for Oral Diseases; Shanghai Key Laboratory of Stomatology, Shanghai 200011, China

**Corresponding author:** Qian Jiang, MD, PhD, Attending Doctor, Department of Oral Surgery, Shanghai Ninth People's Hospital, Shanghai Jiao Tong University School of Medicine; College of Stomatology, Shanghai Jiao Tong University; National Center for Stomatology; National Clinical Research Center for Oral Diseases; Shanghai Key Laboratory of Stomatology, No. 639 Zhizhaoju Road, Shanghai 200011, China. [jiangqian720@163.com](mailto:jiangqian720@163.com)

## Abstract

### BACKGROUND

The odontogenic jaw cyst is a cavity containing liquid, semifluid or gaseous components, with the development of the disease. In recent years, with the rapid development of oral materials and the transformation of treatment of jaw cysts, more options are available for treatment of postoperative bone defect of jaw cysts. Guided bone regeneration (GBR) places biomaterials in the bone defect, and then uses biofilm to separate the proliferative soft tissue and the slow-growing bone tissue to maintain the space for bone regeneration, which is widely used in the field of implantology.

### AIM

To observe the clinical effect of GBR in repairing bone defect after enucleation of small and medium-sized odontogenic jaw cysts.

### METHODS

From June 2018 to September 2020, 13 patients (7 male, 6 female) with odontogenic jaw cysts were treated in the Department of Oral Surgery, Ninth People's Hospital, Shanghai Jiao Tong University School of Medicine. Adults without hypertension, heart disease, diabetes or other systemic diseases were selected. The diagnosis was based on the final pathological results: 11 cases were diagnosed as apical cysts, one as primordial cyst, and one as dentigerous cyst. The lesions were located in the maxilla in seven cases, and in the mandible in six cases. All cases were treated with the same method of enucleation combined with GBR.

## RESULTS

Three to four months after the operation, the boundary between the implant site and the surrounding normal stroma was not obvious in patients with small-sized odontogenic jaw cysts. The patients with tooth defects were treated with implant after 6 mo. For the patients with medium-sized odontogenic jaw cysts, the density of the center of the implant area was close to the normal mass at 6 mo after surgery, and there was a clear boundary between the periphery of the implant area and the normal mass. The boundary between the periphery of the implant area and the normal mass was blurred at 8-9 mo after surgery. Patients with tooth defects were treated with implants at > 6 mo after the operation.

## CONCLUSION

Enucleation combined with guided bone regeneration in small and medium-sized odontogenic jaw cysts can shorten the time of osteogenesis, increase the amount of new bone formation, reduce complications, and improve quality of life.

**Key Words:** Enucleation; Bone defect; Guided bone regeneration; Small and medium-sized; Odontogenic jaw cysts

©The Author(s) 2022. Published by Baishideng Publishing Group Inc. All rights reserved.

**Core Tip:** This was a retrospective study to observe the clinical effect of guided bone regeneration (GBR) in repairing bone defect after enucleation of small and medium-sized odontogenic jaw cysts. The application of odontogenic jaw cysts extraction combined with GBR can shorten the time of osteogenesis, increase the amount of new bone formation, reduce complications, and improve quality of life. GBR has good prospects for application in the treatment of small and medium-sized odontogenic jaw cysts.

**Citation:** Cao YT, Gu QH, Wang YW, Jiang Q. Enucleation combined with guided bone regeneration in small and medium-sized odontogenic jaw cysts. *World J Clin Cases* 2022; 10(9): 2764-2772

**URL:** <https://www.wjgnet.com/2307-8960/full/v10/i9/2764.htm>

**DOI:** <https://dx.doi.org/10.12998/wjcc.v10.i9.2764>

## INTRODUCTION

The odontogenic jaw cyst is a cavity containing liquid, semi-fluid or gaseous components, which is usually derived from odontogenic tissue or epithelium or residual epithelium[1]. The incidence rate of odontogenic jaw cysts was 10.7% in a US study on oral biopsies from a dental school[2]. Development of the disease can lead to bone destruction, absorption or displacement of adjacent teeth[3]. Clinically, odontogenic jaw cysts can be divided into root, primary, dentigerous and calcification cysts[4]. Conventional surgical curettage is mostly used clinically, and cysts are removed at one time. The disadvantage is that it may cause pathological fracture or damage of adjacent tissues[5]. For larger jaw cysts (more than 4 cm), fenestration and decompression should be performed first, and the second stage curettage should be performed when the cyst cavity has shrunk, in order to reduce the recurrence rate[6,7]. The mechanism of healing after enucleation of jaw cysts is autogenous blood filling of the bone cavity, coagulation. However, it takes a long time to heal. Some studies have shown that the average healing time of the defect caused by small jaw cysts is 1 year, while that of larger jaw cysts is 2-5 years[7,8]. In recent years, with the rapid development of oral materials and transformation of treatment of jaw cysts, more options[9,10] are available for treatment of postoperative bone defect of jaw cysts, such as autogenous bone graft[9],  $\beta$ -tricalcium phosphate for bone substitution[10]. Guided bone regeneration (GBR) involves placing biomaterials in the bone defect, and using biofilms to separate the proliferative soft tissue and the slow-growing bone tissue to maintain the space for bone regeneration, which is widely used in the field of implantology[11]. In view of increasing bone width and height with GBR, the

purpose of this study was to observe the clinical effect of GBR in repairing bone defect after enucleation of small and medium-sized odontogenic jaw cysts (the maximum diameter: 1.0 cm-4.0 cm)[6,7].

## MATERIALS AND METHODS

### General information

From June 2018 to September 2020, 13 patients with odontogenic jaw cysts were treated in the Department of Oral Surgery, Ninth People's Hospital, Shanghai Jiao Tong University School of Medicine. Adults without hypertension, heart disease, diabetes or other systemic diseases were selected. The diagnosis was based on the final pathological results: 11 cases were diagnosed as apical cysts, one as primordial cyst, and one as dentigerous cyst. The lesions were located in the maxilla in seven cases, and in the mandible in six cases. There were seven men and six women, aged 25-61 years (mean  $37.2 \pm 11.1$  years) (Supplementary Table 1).

### Surgical methods

(1) Cyst enucleation: trapezoidal or triangular flap gingival sulcus incision was used. After mucoperiosteal flap elevation, an anterior vertical releasing incision was provided for optimum visualization. Sharp dissection using a pair of scissors was done superficial to the cyst wall in order to separate the mucoperiosteal flap without compromising its integrity. While the cystic lesion was identified and enucleated in total, mild adhesions to the lingual mucoperiosteum were released through blunt dissection using the surgical curette. The cyst was enucleated and sent to pathology during surgery; (2) Treatment of bone cavity: cyst tissue was scraped off completely, the cavity was washed with a large amount of normal saline, and the cavity was ground intermittently with a planter at 3000 r/min; and (3) GBR: The residual defect left behind by the cystic lesion was filled with a xenograft bone (Bio-Oss, Geistlich Pharma, Princeton, NJ, United States) soaked in sterile normal saline and covered by a resorbable collagen membrane (Bio-Gide, Geistlich Pharma, Princeton, NJ, United States). The coverage was about 3 mm from the cyst surface to the defect area. The mucoperiosteal flap was re-approximated and closed with Vicryl 4-0 interrupted sutures (Polyglactin 910, ETHICON, Somerville, NJ, United States) (Figure 1A-F).

### Postoperative management

Antibiotics were given intravenously to prevent infection for 1-2 d after the operation. Gargling was used to maintain oral hygiene. The suture was removed 10 d later. After 1, 3-4, 6, 8-9 and 12 mo, CBCT (i-CAT, Imaging Sciences International, Hatfield, PA, United States) was performed to check the healing of the defect area.

## RESULTS

### Operation conditions

The range of incision should be determined according to preoperative imaging examination, combined with imaging and clinical conditions. All patients had destruction of the bone plate. Twelve of the 13 patients were operated upon through the maxillobuccal gingiva (CBCT showed that the labial or buccal plate was damaged), and one was operated upon through the palatal median mucinous membrane (CBCT showed that the palatal plate was damaged and the labial plate was intact). Trapezoidal incision was used in 11 cases, and angular-shaped incision was used in two because the lesion was located in the posterior molar area.

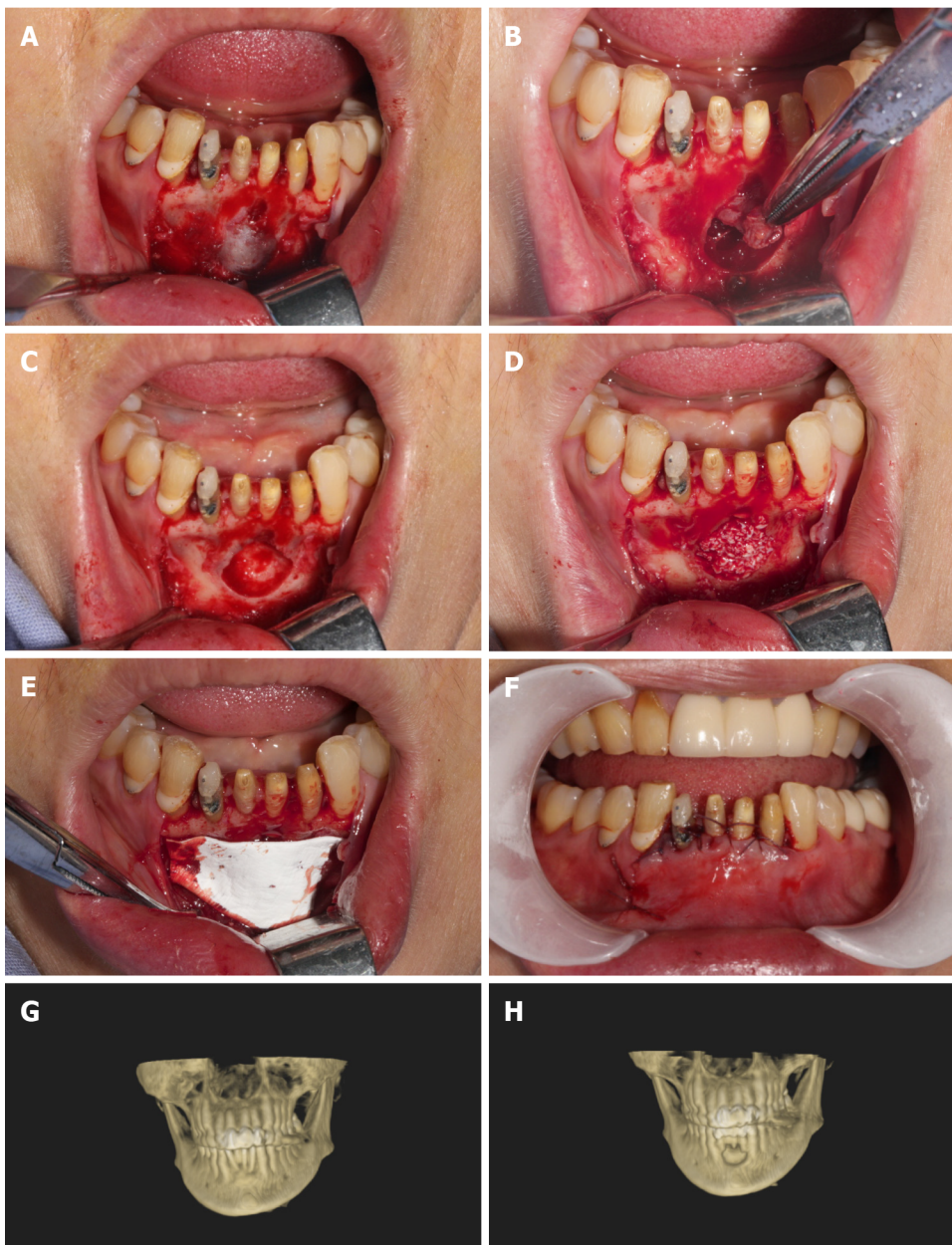
### Treatment of diseased teeth

Before the operation, 11 patients underwent root canal therapy for the diseased teeth and their apices in the cystic cavity; three patients without root canal treatment; and eight diseased teeth were not worth extracting. There were two cases of root canal therapy after the operation. So far, four cases have completed implant restoration of missing teeth.

### Photographic observation of healing of cystic cavity

The maxillofacial cysts caused destruction of the labial (buccal) or palatal plates; the maximum diameter of which was 1.0 cm-4.0 cm. Small-sized lesions ( $\geq 1.0$  cm,  $\leq 2.5$  cm) were found in six cases, and medium-sized lesions ( $> 2.5$  cm,  $< 4.0$  cm) in seven. Three to four months after the operation, the boundary between the implant site and the surrounding normal stroma was not obvious in patients with small-sized lesions (Figure 1G and H). The patients with tooth defects were treated with implants. For the patients with median-sized lesions, the density of the center of the implant area was close to the normal mass at 6 mo after the operation, and there was a clear boundary between the periphery of the





DOI: 10.12998/wjcc.v10.i9.2764 Copyright ©The Author(s) 2022.

**Figure 1 Photographic observation of cystic cavity.** A: Trapezoidal flap gingival sulcus incision, exposed bone surface; B: Cyst enucleation; C: Bone cavity; D: Implanted bone powder (Bio-Oss, Geistlich Pharma, Princeton, NJ, United States); E: Overed by a resorbable collagen membrane (Bio-Gide, Geistlich Pharma, Princeton, NJ, United States); F: Suture; G: Preoperative; H: Postoperative.

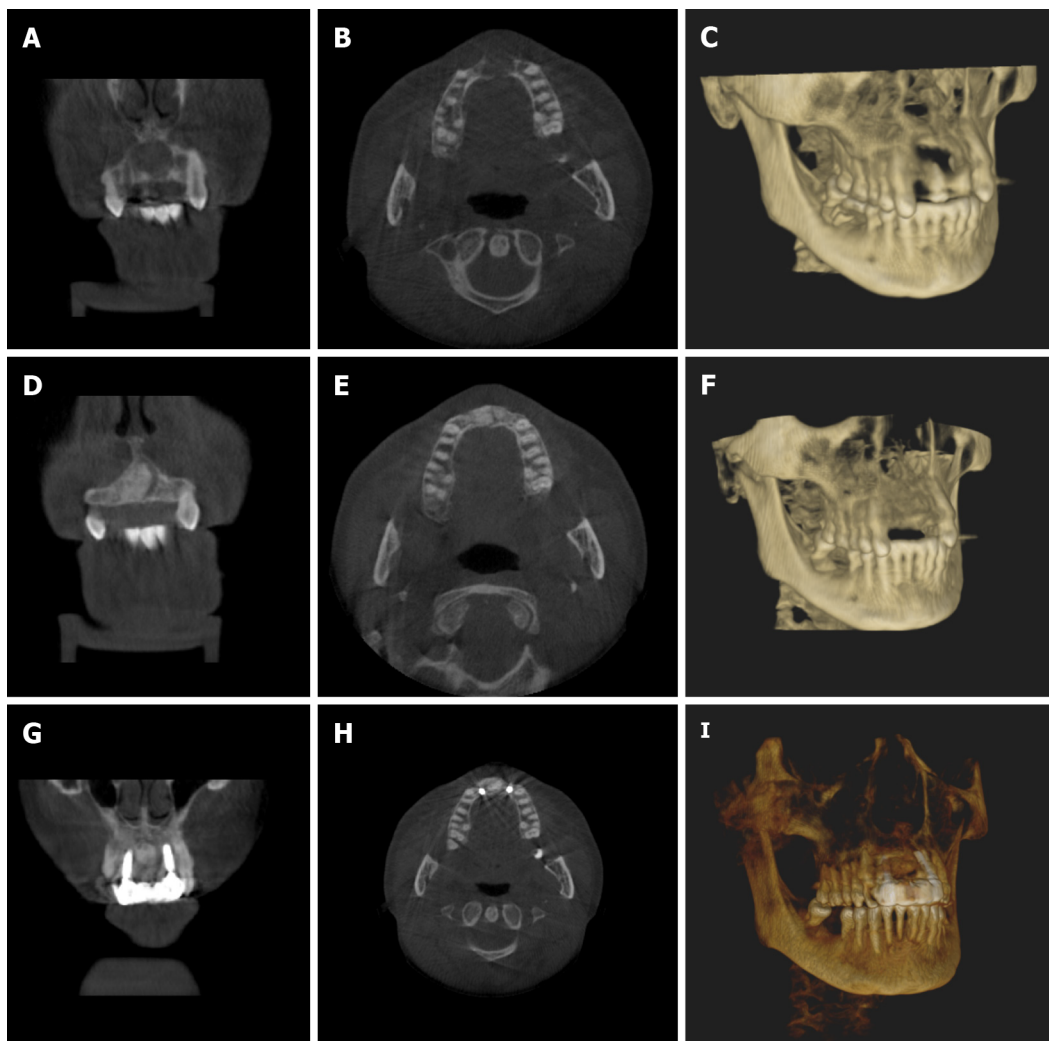
implant area and the normal mass. The boundary between the periphery of the implant area and the normal mass was blurred at 8-9 mo after the operation. For medium-sized lesions, the patients with dentition defect were treated with implant repair for 8-9 mo (Figure 2A-I).

#### **Clinical observation of postoperative treatment effect**

The immediate postoperative period was uneventful, and the surgical wound healed remarkably well. The patients were satisfied with the operation. Pathological examination supported the preoperative diagnosis. Follow-up examinations at 1, 3, 6, 9 and 12 mo after cyst enucleation and GBR revealed no clinical recurrence of the lesion (Supplementary Table 2).

## **DISCUSSION**

Odontogenic jaw cyst is a common cause of jaw defect. For jaw defect after odontogenic jaw cyst enucleation, there is no universal treatment. In the past, most of the methods used were tissue self-healing. Chiapasco *et al*[12] evaluated spontaneous bone healing after enucleation of large mandibular



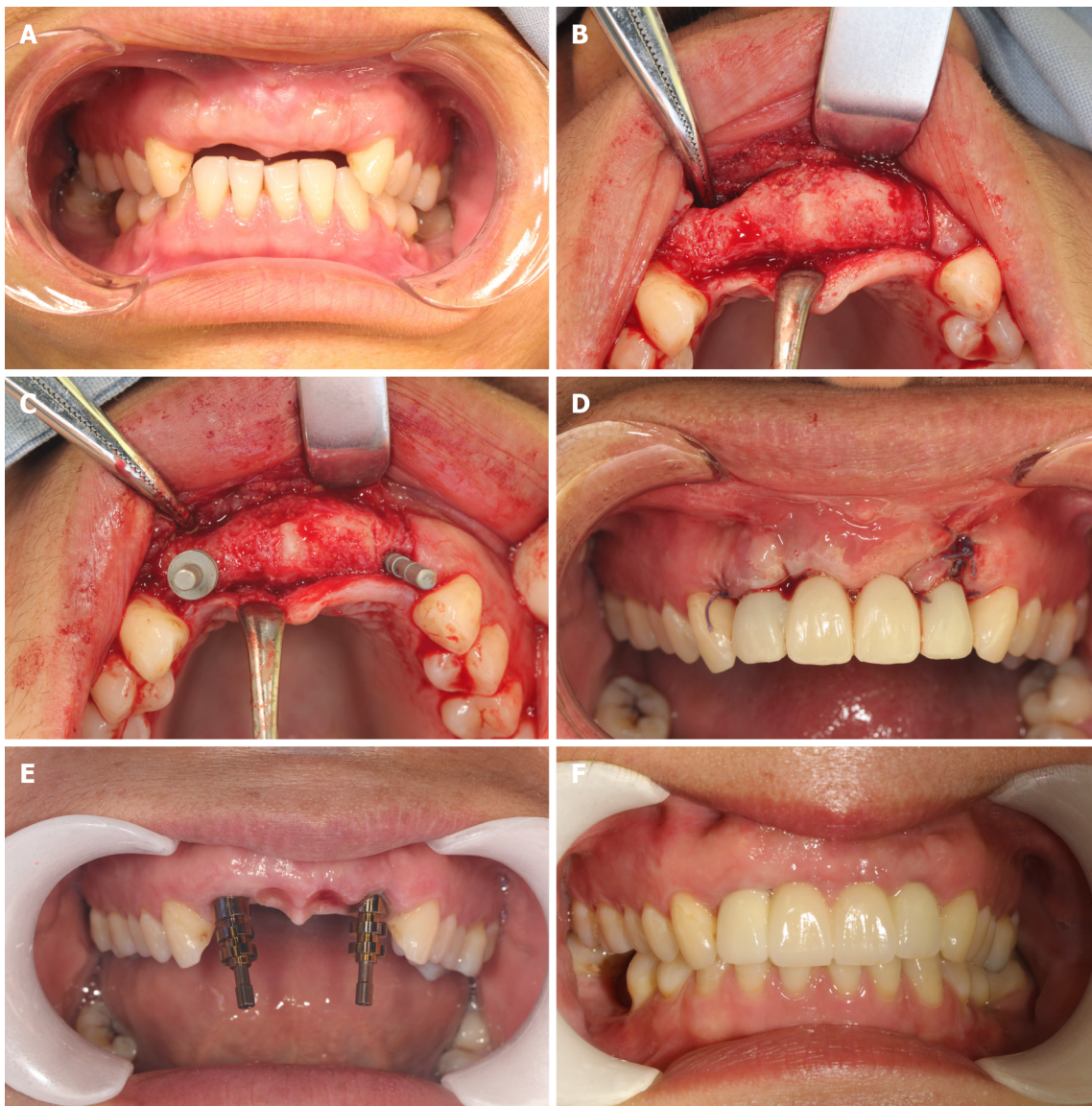
DOI: 10.12998/wjcc.v10.i9.2764 Copyright ©The Author(s) 2022.

**Figure 2** The patients with tooth defects were treated with implants. A-C: Preoperative imaging; D-F: The imaging of six month after operation; G, H, and I: The imaging of nine month after operation, implant surgery; A, D, and G: Coronal plane; B, E, and H: Horizontal plane; C, F, and I: Three-dimensional reconstruction.

cysts with a computerized analysis of postoperative panoramic radiographs, which showed mean reduction in size of the residual cavity of 12.34% after 6 mo, 43.46% after 1 year, and 81.30% after 2 years, and increase in bone density was 37% after 6 mo, 48.27% after 12 mo, and 91.01% after 24 mo. Rabin Chacko *et al*[7] evaluated spontaneous bone regeneration after enucleation of odontogenic jaw cysts (diameter 1.4 cm-15 cm) with a computerized analysis of postoperative panoramic radiographs, which showed mean reduction in size of the residual cavity of 25.85% after 6 mo, 57.13% after 9 mo, 81.03% after 1 year and 100% after 2 years. Li[13] used CBCT to explore the natural outcome of jaw defect after curettage of odontogenic jaw cysts. CBCT images showed that the cytoplasm around the cyst was regenerated and reconstructed, and the cyst cavity was gradually reduced. The formation rate differed with the size of the original capsule, which was maintained at about 50% and 80% at 6 mo and 12 mo, respectively, after the operation.

In recent years, with the emergence of high-quality biomaterials, a large number of studies have been carried out on the treatment of jaw lesions with exogenous implants as filling materials. At present, the commonly used xenogeneic bone meal mainly comes from cattle, such as Geistlich Bio-Oss®. Kim *et al* [14] conducted a follow-up observation of 20 patients with cysts filled with xenogeneic bone meal materials after curettage, and found that there was more new bone formation 3 mo after the operation. Tonetti *et al*[15] applied the material to the treatment of alveolar defect caused by periodontal disease, and showed that the xenogeneic bone meal had good bone-forming ability. Although these allogeneic materials lack active components, such as osteoblasts, which do not have the ability to induce bone formation, their porous structure can guide bone tissue regeneration. Yin *et al*[16] found that after curettage of cysts with Geistlich Bio-Oss®, new bone formation was found in the defect area 1 and 3 mo after the operation, and bone integration occurred 6 mo later. Our study also found that after curettage combined with GBR for the treatment of odontogenic jaw cysts with small lesion area, the defect area healed well 3-4 mo after the operation, which was similar to the surrounding normal density, and the





DOI: 10.12998/wjcc.v10.i9.2764 Copyright ©The Author(s) 2022.

**Figure 3 Clinical observation of postoperative treatment effect.** A: Six months after cyst enucleation combined with guided bone regeneration (GBR); B-D: Nine months after cyst enucleation combined with GBR, implant surgery and immediate restoration; E and F: Final implant-supported prosthesis.

boundary between the two was not clear. After enucleation combined with GBR, the defect area healed well 6-8 mo after the operation, which was similar to the surrounding normal density. It is suggested that this treatment method has a definite effect on promoting the healing of maxillofacial cysts after surgery. Compared with the simple enucleation method, the time of osteogenesis was significantly shortened. For patients with simultaneous cyst and tooth extraction, this treatment method can shorten the time of tooth formation, implant the missing teeth as soon as possible, and shorten the disease course. This is particularly important for patients with anterior teeth cysts. Maxillary anterior tooth area is an important oral aesthetic area, which is exposed by lip tissue in the maximum movement state. The loss of teeth in this area not only causes the loss of function of the missing tooth area, but also has a significant impact on the facial appearance, language, pronunciation and mental health of patients. Studies have shown that the natural healing time of large bone defects after cyst surgery takes 2-5 years, and there may be insufficient bone height and width, which brings challenges for later implantation. Therefore, how to shorten the time of missing teeth and provide sufficient bone for implant has become an urgent problem. In our study, a 50-year-old female patient presented with residual roots of 12, 11, 12, 22. CBCT showed that the size of the cyst in the area of #12-22 was 29.8 mm × 21.3 mm, and the buccal and lingual bone walls were absorbed. At the follow-up visit 6 mo after #12,11,21,22 extraction + cyst enucleation + GBR, it was found that the bone mass in the edentulous area and the buccal alveolar bone fullness were well recovered. CBCT showed that the width of alveolar bone and the height were adequate. An implant operation was performed at #12 and #22 sites, and the initial stability of the implants was greater than 35N, so immediate repair was carried out (Figures 2 and 3). This shortened the time of missing teeth and patient satisfaction was high. At present, five cases of missing teeth in the



cyst area have been repaired by implants, which significantly shortened the time of missing teeth, and the patients were satisfied.

All 13 patients were treated with surgical enucleation and primary bone defect repair using GBR with xenograft and resorbable collagen membrane, along with a recurrence-free follow-up period. There was no infection after bone grafting. The possible reasons may be the following. (1) After bone grafting, biomaterial scaffolds play an important role in mandibular regeneration. Complete filling of biomaterial scaffolds in the capsule cavity is conducive to blood clotting to stabilize the defect area, and then promote mandibular regeneration; (2) intact biofilm is also important, which can block the influence of extraluminal soft tissue on bone regeneration; and (3) when the wound was closed, the base of the soft tissue valve was supported by biological scaffold and biofilm, and sutured tightly to avoid infection in the surgical area.

This study had some limitations, including small sample size and short follow-up time. In the future, we need to expand the sample size and continue to delay the return visit time. In addition, a reasonable control group should be set up for prospective comparison.

## CONCLUSION

The application of odontogenic jaw cysts extraction combined with GBR can shorten the time of osteogenesis, increase the amount of new bone formation, reduce complications, and improve quality of life. It has good prospects for application in the treatment of odontogenic jaw cysts. However, this study also has some limits, such as insufficient sample size and short follow-up time, we need further to increase the sample size, the results obtained will be more persuasive.

## ARTICLE HIGHLIGHTS

### **Research background**

The odontogenic jaw cyst is a cavity containing liquid, semifluid or gaseous components, with the development of the disease. In recent years, with the rapid development of oral materials and the transformation of treatment of jaw cysts, more options are available for treatment of postoperative bone defect of jaw cysts. Guided bone regeneration (GBR) places biomaterials in the bone defect, and then uses biofilm to separate the proliferative soft tissue and the slow-growing bone tissue to maintain the space for bone regeneration, which is widely used in the field of implantology.

### **Research motivation**

This was a retrospective study to observe the clinical effect of guided bone regeneration (GBR) in repairing bone defect after enucleation of small and medium-sized odontogenic jaw cysts. The application of odontogenic jaw cysts extraction combined with GBR can shorten the time of osteogenesis, increase the amount of new bone formation, reduce complications, and improve quality of life. GBR has good prospects for application in the treatment of small and medium-sized odontogenic jaw cysts.

### **Research objectives**

To observe the clinical effect of GBR in repairing bone defect after enucleation of small and medium-sized odontogenic jaw cysts.

### **Research methods**

From June 2018 to September 2020, 13 patients (7 male, 6 female) with odontogenic jaw cysts were treated in the Department of Oral Surgery, Ninth People's Hospital, Shanghai Jiao Tong University School of Medicine. Adults without hypertension, heart disease, diabetes or other systemic diseases were selected. The diagnosis was based on the final pathological results: 11 cases were diagnosed as apical cysts, one as primordial cyst, and one as dentigerous cyst. The lesions were located in the maxilla in seven cases, and in the mandible in six cases. All cases were treated with the same method of enucleation combined with GBR.

### **Research results**

Three to four months after the operation, the boundary between the implant site and the surrounding normal stroma was not obvious in patients with small-sized odontogenic jaw cysts. The patients with tooth defects were treated with implant after 6 mo. For the patients with medium-sized odontogenic jaw cysts, the density of the center of the implant area was close to the normal mass at 6 mo after surgery, and there was a clear boundary between the periphery of the implant area and the normal mass. The boundary between the periphery of the implant area and the normal mass was blurred at 8-9 mo after

surgery. Patients with tooth defects were treated with implants at > 6 mo after the operation.

### Research conclusions

Enucleation combined with guided bone regeneration in small and medium-sized odontogenic jaw cysts can shorten the time of osteogenesis, increase the amount of new bone formation, reduce complications, and improve quality of life.

### Research perspectives

The application of odontogenic jaw cysts extraction combined with GBR can shorten the time of osteogenesis, increase the amount of new bone formation, reduce complications, and improve quality of life. It has good prospects for application in the treatment of odontogenic jaw cysts.

## FOOTNOTES

**Author contributions:** Jiang Q designed and performed the research and wrote the paper; Cao YT performed the research and wrote the paper; Gu QH and Wang YW performed the research.

**Supported by** the National Natural Science Foundation of China, No. 31800816; Fundamental Research Program Funding of the Ninth People's Hospital Affiliated to Shanghai Jiao Tong University School of Medicine, No. JYZZ109.

**Institutional review board statement:** The study was reviewed and approved by the [Ethics Committee of the Ninth People's Hospital, Shanghai Jiao Tong University School of Medicine] Institutional Review Board [Approval No. SH9H-2020-T391-1].

**Informed consent statement:** All involved patients gave their informed consent written prior to study inclusion.

**Conflict-of-interest statement:** We have no financial relationships to disclose.

**Data sharing statement:** No additional data are available.

**Open-Access:** This article is an open-access article that was selected by an in-house editor and fully peer-reviewed by external reviewers. It is distributed in accordance with the Creative Commons Attribution NonCommercial (CC BY-NC 4.0) license, which permits others to distribute, remix, adapt, build upon this work non-commercially, and license their derivative works on different terms, provided the original work is properly cited and the use is non-commercial. See: <https://creativecommons.org/licenses/by-nc/4.0/>

**Country/Territory of origin:** China

**ORCID number:** Yi-Ting Cao 0000-0002-0606-342X; Qin-Hua Gu 0000-0002-9339-1041; Yi-Wei Wang 0000-0002-8738-9316; Qian Jiang 0000-0001-6920-7470.

**S-Editor:** Liu JH

**L-Editor:** A

**P-Editor:** Liu JH

## REFERENCES

- 1 **Rajendra Santosh AB**, Boyd D, Laxminarayana KK. Clinical Outline of Oral Diseases. *Dent Clin North Am* 2020; **64**: 1-10 [PMID: 31735220 DOI: 10.1016/j.cden.2019.08.001]
- 2 **Rajendra Santosh AB**. Odontogenic Cysts. *Dent Clin North Am* 2020; **64**: 105-119 [PMID: 31735221 DOI: 10.1016/j.cden.2019.08.002]
- 3 **Zhao Y**, Liu B, Zhao YF. Controversies Regarding the Management of Teeth Associated with Cystic Lesions of the Jaws. *Chin J Dent Res* 2019; **22**: 81-92 [PMID: 31172136 DOI: 10.3290/j.cjdr.a42512]
- 4 **Speight PM**, Takata T. New tumour entities in the 4th edition of the World Health Organization Classification of Head and Neck tumours: odontogenic and maxillofacial bone tumours. *Virchows Arch* 2018; **472**: 331-339 [PMID: 28674741 DOI: 10.1007/s00428-017-2182-3]
- 5 **de Moraes ATL**, Soares HA, Viana Pinheiro JJ, Ribeiro Ribeiro AL. Marsupialization before enucleation as a treatment strategy for a large calcifying odontogenic cyst: Case report. *Int J Surg Case Rep* 2020; **67**: 239-244 [PMID: 32070818 DOI: 10.1016/j.ijscr.2020.01.031]
- 6 **Shah N**, Logani A, Kumar V. A minimally invasive surgical approach for large cyst-like periapical lesions: a case series. *Gen Dent* 2014; **62**: e1-e5 [PMID: 24401356]
- 7 **Chacko R**, Kumar S, Paul A, Arvind. Spontaneous Bone Regeneration After Enucleation of Large Jaw Cysts: A Digital Radiographic Analysis of 44 Consecutive Cases. *J Clin Diagn Res* 2015; **9**: ZC84-ZC89 [PMID: 26501020 DOI: 10.7860/JCDR/2015/13394.6524]

- 8 **Rubio ED**, Mombrú CM. Spontaneous Bone Healing after Cysts Enucleation without Bone Grafting Materials: A Randomized Clinical Study. *Craniomaxillofac Trauma Reconstr* 2015; **8**: 14-22 [PMID: [25709749](#) DOI: [10.1055/s-0034-1384738](#)]
- 9 **Aludden HC**, Mordenfeld A, Hallman M, Dahlin C, Jensen T. Lateral ridge augmentation with Bio-Oss alone or Bio-Oss mixed with particulate autogenous bone graft: a systematic review. *Int J Oral Maxillofac Surg* 2017; **46**: 1030-1038 [PMID: [28366452](#) DOI: [10.1016/j.ijom.2017.03.008](#)]
- 10 **Bohner M**, Santoni BLG, Döbelin N.  $\beta$ -tricalcium phosphate for bone substitution: Synthesis and properties. *Acta Biomater* 2020; **113**: 23-41 [PMID: [32565369](#) DOI: [10.1016/j.actbio.2020.06.022](#)]
- 11 **Mordini L**, Hur Y, Ogata Y, Finkelman M, Cavani F, Steffensen B. Volumetric Changes Following Lateral Guided Bone Regeneration. *Int J Oral Maxillofac Implants* 2020; **35**: e77-e85 [PMID: [32991654](#) DOI: [10.11607/jomi.7524](#)]
- 12 **Chiapasco M**, Rossi A, Motta JJ, Crescentini M. Spontaneous bone regeneration after enucleation of large mandibular cysts: a radiographic computed analysis of 27 consecutive cases. *J Oral Maxillofac Surg* 2000; **58**: 942-8; discussion 949 [PMID: [10981973](#) DOI: [10.1053/joms.2000.8732](#)]
- 13 Li X. The study of bone tissue repair after curettage of mandibular cyst by CBCT. *Qingdao Daxue* 2018 [DOI: [10.1007/s10561-011-9257-1](#)]
- 14 **Kim YK**, Yun PY, Lee HJ, Ahn JY, Kim SG. Ridge preservation of the molar extraction socket using collagen sponge and xenogeneic bone grafts. *Implant Dent* 2011; **20**: 267-272 [PMID: [21753734](#) DOI: [10.1097/ID.0b013e3182166afc](#)]
- 15 **Tonetti MS**, Cortellini P, Lang NP, Suvan JE, Adriaens P, Dubravec D, Fonzar A, Fourmoussis I, Rasperini G, Rossi R, Silvestri M, Topoll H, Wallkamm B, Zybutz M. Clinical outcomes following treatment of human intrabony defects with GTR/bone replacement material or access flap alone. A multicenter randomized controlled clinical trial. *J Clin Periodontol* 2004; **31**: 770-776 [PMID: [15312100](#) DOI: [10.1111/j.1600-051X.2004.00562.x](#)]
- 16 **Yin XN**, Wang XM. Application of Bio-Oss® in bone repair after jaw cyst operation. *Quankeyixue linchuang yu Jiaoyu* 2011; **6**: 677-678 [DOI: [10.5137/1019-5149.jtn.5216-11.1](#)]



Published by **Baishideng Publishing Group Inc**  
7041 Koll Center Parkway, Suite 160, Pleasanton, CA 94566, USA

**Telephone:** +1-925-3991568

**E-mail:** [bpgoffice@wjgnet.com](mailto:bpgoffice@wjgnet.com)

**Help Desk:** <https://www.f6publishing.com/helpdesk>

<https://www.wjgnet.com>

