

World Journal of *Clinical Cases*

World J Clin Cases 2022 February 26; 10(6): 1754-2052



Contents

Thrice Monthly Volume 10 Number 6 February 26, 2022

OPINION REVIEW

- 1754** Gut-brain axis: Focus on gut metabolites short-chain fatty acids
Guo C, Huo YJ, Li Y, Han Y, Zhou D

MINIREVIEWS

- 1764** Association between direct-acting antiviral agents in hepatitis C virus treatment and hepatocellular carcinoma occurrence and recurrence: The endless debate
Kamal A, Elsheaita A, Abdelnabi M

ORIGINAL ARTICLE

Retrospective Cohort Study

- 1775** Effects of bilirubin on perioperative myocardial infarction and its long-term prognosis in patients undergoing percutaneous coronary intervention
Li Y, Li DB, Zhao LD, Lv QB, Wang Y, Ren YF, Zhang WB
- 1787** Disease exacerbation is common in inflammatory bowel disease patients treated with immune checkpoint inhibitors for malignancy
Rubin SJS, Balabanis T, Gubatan J, Habtezion A
- 1795** Multidrug-resistant organisms in intensive care units and logistic analysis of risk factors
Han Y, Zhang J, Zhang HZ, Zhang XY, Wang YM

Retrospective Study

- 1806** Change and impact of left ventricular global longitudinal strain during transcatheter aortic valve implantation
Zhang H, Xie JJ, Li RJ, Wang YL, Niu BR, Song L, Li J, Yang Y

Observational Study

- 1815** Early detection of noise-induced hearing loss
Meng ZL, Chen F, Zhao F, Gu HL, Zheng Y
- 1826** Empathetic nursing with mindful cognitive therapy for fatigue, depression, and negative emotions in leukemia patients undergoing long-term chemotherapy
Lu YY, Lu XM, Shao CY, Wang CC, Xu TT, Zhang BL

Prospective Study

- 1834** Superior pancreatic lymphadenectomy with portal vein priority *via* posterior common hepatic artery approach in laparoscopic radical gastrectomy
Zhang YJ, Xiang RC, Li J, Liu Y, Xie SM, An L, Li HL, Mai G

Randomized Controlled Trial

- 1843** Systematic nursing interventions in gastric cancer: A randomized controlled study
He F, He RX

META-ANALYSIS

- 1852** Impact of adding opioids to paravertebral blocks in breast cancer surgery patients: A systematic review and meta-analysis
Chen MH, Chen Z, Zhao D

CASE REPORT

- 1863** Multiple different remote epidural hematomas after craniotomy: A case report
He Q, Tao CY, Fu RH, You C
- 1869** Tuberculous pericarditis-a silent and challenging disease: A case report
Lucero OD, Bustos MM, Ariza Rodríguez DJ, Perez JC
- 1876** Transileocolic endovascular treatment by a hybrid approach for severe acute portal vein thrombosis with bowel necrosis: Two case reports
Shirai S, Ueda T, Sugihara F, Yasui D, Saito H, Furuki H, Kim S, Yoshida H, Yokobori S, Hayashi H, Kumita SI
- 1883** Efficacy of EGFR-TKI sequential therapy in patients with EGFR exon 19 insertion-positive non-small-cell lung cancer: A case report
Shan BB, Li Y, Zhao C, An XQ, Zhang QM
- 1889** Novel compound heterozygous variants in the TAF6 gene in a patient with Alazami-Yuan syndrome: A case report
Lin SZ, Feng JH, Sun LP, Ma HW, Wang WQ, Li JY
- 1896** Asymmetric limb weakness in Guillain-Barré syndrome: Three case reports
Hu M, Li X, Wong HY, Feng XG, Wang YZ, Zhang GR
- 1903** Modified treatment of knee osteoarthritis complicated with femoral varus deformity: A case report
Xu SM, Li W, Zhang DB, Bi HY, Gu GS
- 1909** Novel HNF1A gene mutation in maturity-onset diabetes of the young: A case report
Xu Q, Kan CX, Hou NN, Sun XD
- 1914** Cerebral corridor creator for resection of trigone ventricular tumors: Two case reports
Liu XW, Lu WR, Zhang TY, Hou XS, Fa ZQ, Zhang SZ
- 1922** Left abdominal wall proliferative myositis resection and patch repair: A case report
Xing RW, Nie HQ, Zhou XF, Zhang FF, Mou YH
- 1929** Concurrent ankylosing spondylitis and myelodysplastic syndrome: A case report
Xu GH, Lin J, Chen WQ

- 1937** Life-threatening subclavian artery bleeding following percutaneous coronary intervention with stent implantation: A case report and review of literature
Shi F, Zhang Y, Sun LX, Long S
- 1946** Cryptogenic organizing pneumonia associated with pregnancy: A case report
Lee YJ, Kim YS
- 1952** Eosinophilia complicated with venous thromboembolism: A case report
Su WQ, Fu YZ, Liu SY, Cao MJ, Xue YB, Suo FF, Liu WC
- 1961** Neck and mediastinal hematoma caused by a foreign body in the esophagus with diagnostic difficulties: A case report
Wang LP, Zhou ZY, Huang XP, Bai YJ, Shi HX, Sheng D
- 1966** Therapeutic endoscopy of a Dieulafoy lesion in a 10-year-old girl: A case report
Chen Y, Sun M, Teng X
- 1973** Cavernous hemangioma of an intrapancreatic accessory spleen mimicking a pancreatic tumor: A case report
Huang JY, Yang R, Li JW, Lu Q, Luo Y
- 1981** Surgery and antibiotics for the treatment of lupus nephritis with cerebral abscesses: A case report
Hu QD, Liao LS, Zhang Y, Zhang Q, Liu J
- 1991** Median arcuate ligamentum syndrome: Four case reports
Kim JE, Rhee PL
- 1998** Novel ABCB4 mutations in an infertile female with progressive familial intrahepatic cholestasis type 3: A case report
Liu TF, He JJ, Wang L, Zhang LY
- 2007** Primary duodenal dedifferentiated liposarcoma: A case report and literature review
Kim NI, Lee JS, Choi C, Nam JH, Choi YD, Kim HJ, Kim SS
- 2015** Implant site development using titanium plate and platelet-rich fibrin for congenitally missed maxillary lateral incisors: A case report
Zhang TS, Mudalal M, Ren SC, Zhou YM
- 2023** Successful embolization of an intrahepatic portosystemic shunt using balloon-occluded retrograde transvenous obliteration: A case report
Saito H, Murata S, Sugihara F, Ueda T, Yasui D, Miki I, Hayashi H, Kumita SI
- 2030** Bilateral pneumothorax and pneumomediastinum during colonoscopy in a patient with intestinal Behcet's disease: A case report
Mu T, Feng H
- 2036** Acute kidney injury due to intravenous detergent poisoning: A case report
Park S, Ryu HS, Lee JK, Park SS, Kwon SJ, Hwang WM, Yun SR, Park MH, Park Y

- 2045** Vaginal enterocele after cystectomy: A case report

Liu SH, Zhang YH, Niu HT, Tian DX, Qin F, Jiao W

ABOUT COVER

Editorial Board Member of *World Journal of Clinical Cases*, Navdeep Singh, MBBS, MS, Assistant Professor, Division of Transplantation, Department of Surgery, The Ohio State University, Columbus, OH 43210, United States.
navdeep.singh@osumc.edu

AIMS AND SCOPE

The primary aim of *World Journal of Clinical Cases* (WJCC, *World J Clin Cases*) is to provide scholars and readers from various fields of clinical medicine with a platform to publish high-quality clinical research articles and communicate their research findings online.

WJCC mainly publishes articles reporting research results and findings obtained in the field of clinical medicine and covering a wide range of topics, including case control studies, retrospective cohort studies, retrospective studies, clinical trials studies, observational studies, prospective studies, randomized controlled trials, randomized clinical trials, systematic reviews, meta-analysis, and case reports.

INDEXING/ABSTRACTING

The WJCC is now indexed in Science Citation Index Expanded (also known as SciSearch®), Journal Citation Reports/Science Edition, Scopus, PubMed, and PubMed Central. The 2021 Edition of Journal Citation Reports® cites the 2020 impact factor (IF) for WJCC as 1.337; IF without journal self cites: 1.301; 5-year IF: 1.742; Journal Citation Indicator: 0.33; Ranking: 119 among 169 journals in medicine, general and internal; and Quartile category: Q3. The WJCC's CiteScore for 2020 is 0.8 and Scopus CiteScore rank 2020: General Medicine is 493/793.

RESPONSIBLE EDITORS FOR THIS ISSUE

Production Editor: *Ying-Yi Yuan*, Production Department Director: *Xu Guo*, Editorial Office Director: *Jin-Lei Wang*.

NAME OF JOURNAL

World Journal of Clinical Cases

ISSN

ISSN 2307-8960 (online)

LAUNCH DATE

April 16, 2013

FREQUENCY

Thrice Monthly

EDITORS-IN-CHIEF

Bao-Gan Peng, Jerzy Tadeusz Chudek, George Kontogeorgos, Maurizio Serati, Ja Hyeon Ku

EDITORIAL BOARD MEMBERS

<https://www.wjgnet.com/2307-8960/editorialboard.htm>

PUBLICATION DATE

February 26, 2022

COPYRIGHT

© 2022 Baishideng Publishing Group Inc

INSTRUCTIONS TO AUTHORS

<https://www.wjgnet.com/bpg/gerinfo/204>

GUIDELINES FOR ETHICS DOCUMENTS

<https://www.wjgnet.com/bpg/GerInfo/287>

GUIDELINES FOR NON-NATIVE SPEAKERS OF ENGLISH

<https://www.wjgnet.com/bpg/gerinfo/240>

PUBLICATION ETHICS

<https://www.wjgnet.com/bpg/GerInfo/288>

PUBLICATION MISCONDUCT

<https://www.wjgnet.com/bpg/gerinfo/208>

ARTICLE PROCESSING CHARGE

<https://www.wjgnet.com/bpg/gerinfo/242>

STEPS FOR SUBMITTING MANUSCRIPTS

<https://www.wjgnet.com/bpg/GerInfo/239>

ONLINE SUBMISSION

<https://www.f6publishing.com>



Therapeutic endoscopy of a Dieulafoy lesion in a 10-year-old girl: A case report

Ying Chen, Mei Sun, Xu Teng

Specialty type: Gastroenterology and hepatology

Provenance and peer review:

Unsolicited article; Externally peer reviewed.

Peer-review model: Single blind

Peer-review report's scientific quality classification

Grade A (Excellent): 0
Grade B (Very good): 0
Grade C (Good): C, C
Grade D (Fair): D
Grade E (Poor): 0

P-Reviewer: Oda M, Yoshimatsu K

Received: August 16, 2021

Peer-review started: August 16, 2021

First decision: October 22, 2021

Revised: October 27, 2021

Accepted: January 14, 2022

Article in press: January 14, 2022

Published online: February 26, 2022



Ying Chen, Mei Sun, Xu Teng, Department of Pediatrics, Shengjing Hospital of China Medical University, Shenyang 110004, Liaoning Province, China

Corresponding author: Xu Teng, MD, Associate Professor, Department of Pediatrics, Shengjing Hospital of China Medical University, Sanhao Street Heping District, Shenyang 110004, Liaoning Province, China. tengx@sj-hospital.org

Abstract

BACKGROUND

There are multiple causes of sudden gastrointestinal bleeding in children. Reports of Dieulafoy lesions (DLs) in children are scarce. DLs can be fatal without appropriate treatment.

CASE SUMMARY

We present a retrospective analysis of the clinical manifestations, endoscopic features, and treatment of a Chinese girl with a DL, as well as a review of the relevant literature. A 10-year-old girl was admitted to our hospital with sudden massive hematemesis and melena. Abdominal computed tomography revealed suspected submucosal bleeding in the stomach. Finally, the disease was diagnosed with endoscopy due to the typical manifestations. We used electrocoagulation and hemoclips under endoscopy for hemostasis. No recurrence of hematemesis was identified during 4-wk' follow-up.

CONCLUSION

DLs in children are rare but an important cause of sudden gastrointestinal hemorrhage. Many pediatricians are inexperienced and often miss or delay diagnosis. Endoscopy as early as possible is the first choice for diagnosis and treatment.

Key Words: Pediatric; Dieulafoy lesion; Endoscopy; Treatment; Case report

©The Author(s) 2022. Published by Baishideng Publishing Group Inc. All rights reserved.

Core Tip: Dieulafoy lesions (DLs) are vascular abnormalities consisting of tortuous, dilated aberrant submucosal vessels. We present a 10-year-old girl with acute gastrointestinal hemorrhage due to a DL. We used electrocoagulation and hemoclips under endoscopy for hemostasis. This case highlights that while DLs in children are rare, they can be an important cause of sudden gastrointestinal hemorrhage. Many pediatricians are inexperienced and often miss or delay diagnosis. Endoscopy as early as possible is the first choice for diagnosis and treatment.

Citation: Chen Y, Sun M, Teng X. Therapeutic endoscopy of a Dieulafoy lesion in a 10-year-old girl: A case report. *World J Clin Cases* 2022; 10(6): 1966-1972

URL: <https://www.wjgnet.com/2307-8960/full/v10/i6/1966.htm>

DOI: <https://dx.doi.org/10.12998/wjcc.v10.i6.1966>

INTRODUCTION

The most common causes of acute gastrointestinal hemorrhage are peptic ulcers and esophageal and gastroduodenal erosions[1]. However, even after careful investigations, such as endoscopy and barium studies, obscure gastrointestinal hemorrhages remain a clinical challenge. Dieulafoy lesions (DLs), also known as Dieulafoy disease, are a rare but fatal cause of gastrointestinal hemorrhage[2]. DLs are defined as vascular abnormalities consisting of tortuous, dilated aberrant submucosal vessels that do not undergo normal distal branching or tapering and subsequently protrudes through a minute defect into the overlying mucosa without ulceration[3]. DLs are scarce and it is hard to determine their true incidence in children. We performed a literature search on PubMed, Medline, and Embase, using the MeSH terms Dieulafoy lesion, Dieulafoy disease, Dieulafoy ulcer, and caliber persistent artery. Only 26 case reports of pediatric DLs were reported worldwide during 1995–2021, and there has been no literature review of DLs in children. Early diagnosis and appropriate treatment are vital. DLs must be considered in the differential diagnosis of gastrointestinal hemorrhage of unknown origin and not just in adults. We report a 10-year-old girl presenting with hematemesis and melena who was diagnosed with DL and successfully treated with electrocoagulation and hemoclips, and our experience in the diagnosis and treatment of DL in this child, and provide some data on DLs to pediatricians.

CASE PRESENTATION

Chief complaints

A 10-year-old Chinese girl with a history of hematemesis was admitted to the Pediatric Intensive Care Unit of Shengjing Hospital of China Medical University with massive hematemesis and melena.

History of present illness

The girl presented with recurrent hematemesis 4–6 times 24 h before admission, with no obvious regularity. She denied overeating or eating excitant food. She did not take in any corrosive or sharp foreign body. She presented with the usual upper abdominal pain. As usual, there was no acid reflux or heartburn. She complained of belching and black stools.

History of past illness

At the age of 8 years, she was hospitalized with massive hematemesis. No erosions or ulcers were detected by endoscopy. After 4 d of treatment with blood transfusions and proton pump inhibitors, the active bleeding stopped, and the patient was discharged with our lack of understanding of DLs.

Personal and family history

She denied any surgical history and was not taking any medication. She denied any history of drug or food allergies. There were no known significant gastrointestinal conditions in the family.

Physical examination

On her admission physical examination, her temperature was 36.5 °C, heart rate 134 beats/min, blood pressure 96/56 mmHg, respiratory rate 25 breaths/min, and body weight 40 kg. She was pale, but her abdominal examination was unremarkable. No other physical abnormalities were noted.

Laboratory examinations

Her initial laboratory testing revealed microcytic anemia. The coagulation test showed decreased

fibrinogen. Liver function and myocardial enzymes were normal. In renal function, blood urea nitrogen (BUN) level was elevated, and creatinine was normal. The high level of BUN is an important signal for upper intestinal bleeding. The results of other laboratory tests were unremarkable. [Table 1](#) shows the details of the test results.

Imaging examinations

Abdominal enhanced computed tomography showed that the stomach was visibly dilated and filled with fluid, and blood clots were visible ([Figure 1](#)).

FINAL DIAGNOSIS

On the day of admission, she was managed with a proton pump inhibitor (1 mg/kg/d), fasting, gastrointestinal decompression, and nutritional support. According to the document "Standardize the diagnosis and treatment of acute non-variceal upper gastrointestinal bleeding based on the update guidelines", gastric lavage was performed with norepinephrine and ice saline[4]. She stopped vomiting but developed another massive melena and her hemoglobin decreased to 6.9 g/dL. Two units of packed red blood cells were transfused.

To find the cause and stop the bleeding, she was transferred to our department. After repeated communication with her parents, gastroscopy with a transparent hood over the head was urgently performed. To fully expose the observation field, we injected gas into the gastric cavity to expand the folds of the gastric mucosa. Then, we used normal saline to clean the blood scab covering the mucosal surface of the gastric body and fundus. Meanwhile, the residual blood in the stomach was continuously sucked out. A careful examination revealed the presence of an actively bleeding protruding vessel in the posterior wall of the body of the stomach ([Figure 2A](#)). Based on the patient's history and typical endoscopic manifestation, DL was finally diagnosed.

TREATMENT

We treated the DL with electrocoagulation hemostatic forceps (FD-410LR; Olympus) and hemoclips [ROCC-D-26-195; Micro-Tech (Nanjing) Co. Ltd]. We inserted the hemostatic forceps to the bleeding site through the biopsy hole and accurately clamped the upper end of the bleeding artery. Electrocoagulation lasted 2–3 s and the power used in electrocoagulation (ESG-400) was 40 W. Two endoscopic hemoclips were applied, which achieved full control of the bleeding ([Figure 2B](#)). The hemoclips were opened to the maximum, perpendicular to the lesion, and clamped on the mucosa on both sides of the bleeding lesion, placing the bleeding focus in the middle. After sealing the bleeding focus, the two clips were fixed in an upright position and could not move, which indicated that the clips were firmly clamped. After the active bleeding had stopped and the residual blood in the stomach was sucked up, further examination of the gastric and duodenal mucosa showed no other bleeding spots, erosions, or ulcers ([Figure 3](#)).

OUTCOME AND FOLLOW-UP

The patient had no further complaints at her follow-up at the outpatient clinic 4 wk later.

DISCUSSION

DL, first described by the French pathologist Dieulafoy, manifests with spontaneous recurrent gastrointestinal bleeding. It is observed in 0.3%–6.7% of cases of upper gastrointestinal bleeding[5]. There are no accurate statistics on the incidence of this disease in children. From 1995 to 2021, only sporadic cases were reported in children worldwide. DL is a large penetrating artery that is a normal vessel with an unexpectedly large diameter. The vessel caliber is 1–3 mm. This penetrating artery creates a small wall defect with fibrinoid necrosis at the base. The mechanisms of the pathological bleeding of DLs remain unknown. Newborn cases suggest that DLs can be congenital, and a congenital anomaly may develop acute ruptures. Mechanical friction, chemical corrosion, or drugs can induce the rupture of the protruding vessel and massive bleeding[6,7]. In adults, DLs are more common in men than women, and in middle-aged and older people[8]. Unlike adult patients, pediatric cases do not appear to have a gender predominance[9].

The small nature of the lesion and the special sites of the hemorrhage are two features of DLs. Most lesions are in the proximal stomach, particularly within 6–10 cm of the lesser curvature of the stomach,

Table 1 Laboratory data

Item	Measured value	Range of normal value
White blood cell	$12.7 \times 10^9/L$	$4-10 \times 10^9/L$
Hemoglobin	7.8 g/dL	12-15.5 g/dL
Hematocrit	22.25%	37%-47%
Platelet count	$134 \times 10^9/L$	$100-300 \times 10^9/L$
Prothrombin time	15.3 s	9.4-12.5 s
International normalized ratio	1.4	0.8-1.2
Fibrinogen	1.7 g/L	2-4 g/L
Albumin	35.6 g/L	35-53 g/L
Alanine transaminase	8 U/L	0-40 U/L
Glutamic oxalacetic transaminase	14 U/L	5-34 U/L
Blood urea nitrogen	8.95 mmol/L	2.5-7.2 mmol/L
Creatinine	40.1 μ mol/L	45-84 μ mol/L
Creatine kinase	63 U/L	< 145 U/L

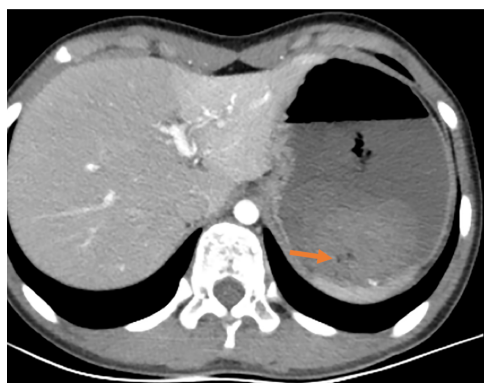


Figure 1 Abdominal enhanced computed tomography. It showed that the stomach was visibly dilated and filled with fluid, with blood clots visible. The arrow indicates the blood clot.

where blood supply comes directly from the arteriae gastrica sinistra[10]. Nongastric sites, such as the duodenum, jejunum, ileum, rectum, and even the bronchus, are also involved in DLs[11]. In our case, the DL was located in the posterior wall of the body of the stomach.

It is challenging to diagnose DL because of the features of the disease. Endoscopy, angiography, and surgical search are the primary diagnostic modalities. Red blood cell scintigraphy can also detect the site of bleeding. Undoubtedly, endoscopy is the most feasible method. Initial endoscopy can precisely diagnose over 71% of cases[12]. As subtle lesions can exist, multiple endoscopies are needed in some patients. The endoscopic visual criteria of DLs include: (1) Active arterial spurting or micro pulsatile streaming from a mucosal defect < 3 mm; (2) Visualization of a vessel protruding from a slight defect or normal mucosa; or (3) A fresh blood clot adherent to a minute mucosal defect or a normal-appearing mucosa[13,14]. To clearly and safely diagnose a DL, the following principles should be included in an endoscopic examination[15]: (1) During the period of active bleeding, emergency endoscopy should be performed under anti-shock therapy; (2) The DL may be exposed by cleaning the gastric cavity with moderate endoscopic perfusion; (3) During endoscopy, patients may change their body position, if necessary; (4) The search for the cause of the hemorrhage, especially sudden massive hematemesis, should not be stopped after finding a mild peptic ulcer and esophageal varicose veins; and (5) If a DL is suspected, a focal tissue biopsy is strictly prohibited.

Timely endoscopy and treatment can decrease the mortality of DL[16]. Endoscopy is recommended as the first-line method of treatment[17]. Endoscopic treatments include thermal electrocoagulation, heat probe coagulation, laser photocoagulation, regional injection with epinephrine, sclerotherapy, norepinephrine injection, band ligation, and hemoclips[18,19]. Mechanical banding and hemoclips are more effective than thermal electrocoagulation and injection[13]. It has been reported that 23 patients with lesions were found under emergency endoscopy, and all lesions were successfully sealed with

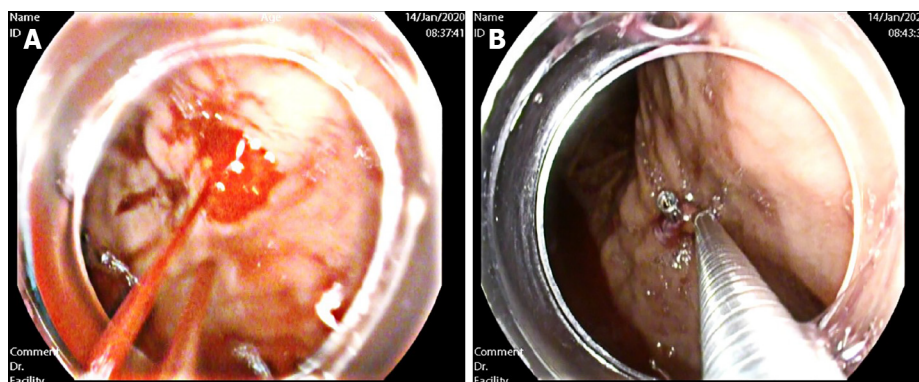


Figure 2 Endoscopic exam. A: Endoscopic changes before hemostasis. The presence of an actively bleeding protruding vessel in the posterior wall of the body of the stomach; B: Endoscopic hemostasis. Electrocoagulation lasted 2-3 s and the power used in electrocoagulation was 40 W. Two endoscopic hemoclips were applied, which achieved full control of the bleeding.

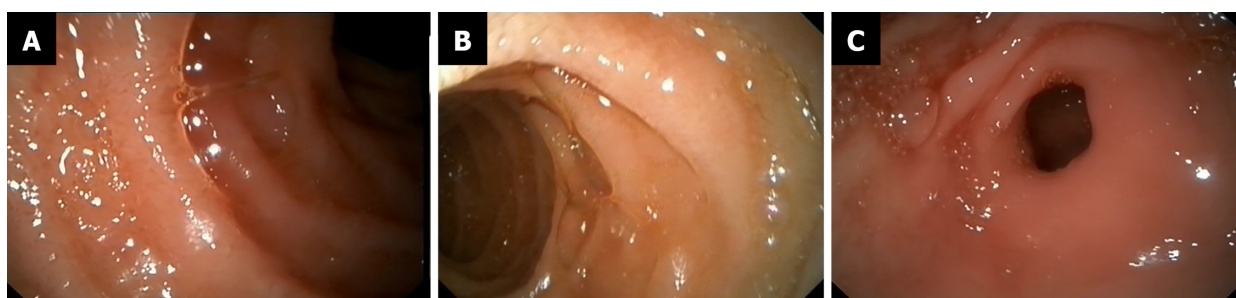


Figure 3 Endoscopic appearance of other parts after hemostasis. A and B: Duodenal mucosa showed no other bleeding spots, erosions, or ulcers; C: Gastric antrum was normal.

hemoclips for hemostasis. During follow-up, there was no recurrence, suggesting that hemoclips are preferred for endoscopic treatment of DLs[20]. The combination of electrocoagulation and hemoclips may be more reliable. This procedure was adopted in our case.

For patients who fail in endoscopic therapy, angiography with gel foam embolization is suggested [21]. Surgical management, previously regarded as the only treatment available, is reserved for patients who are refractory to endoscopy and angiography. Endoscopy combined with laparoscopic surgery is a new procedure that is less invasive than traditional surgery and more readily accepted by patients[22].

Our patient's endoscopic appearance was a typical manifestation of DL. Electrocoagulation and hemoclip treatment were effective, and no active bleeding occurred during follow-up. This case suggests that although DL is a rare occurrence in children, we cannot ignore it, especially in patients with sudden, acute, severe, or unexplained gastrointestinal bleeding. Moreover, the timing of endoscopy is important. If the patient's condition permits, gastroscopy should be undertaken as early as possible. Besides diagnostic purpose, endoscopic hemostasis can also be performed.

CONCLUSION

DL, as a cause of life-threatening bleeding, is a rare occurrence in the pediatric population. However, pediatricians should be aware of it as a differential diagnosis of pediatric gastrointestinal bleeding. Endoscopy is still the primary diagnostic tool and the first-line method of treatment. Early diagnosis and treatment are of great significance for a good prognosis in children.

ACKNOWLEDGEMENTS

We thank International Science Editing for editing this manuscript.

FOOTNOTES

Author contributions: Chen Y and Teng X performed the literature, collected all the data related to the case report and contributed to manuscript drafting; Sun M and Teng X reviewed the literature; all authors have read and approved the final manuscript.

Informed consent statement: All authors read and approved the manuscript. Written informed consent was obtained from the patient's parent for publication of this Case report and any accompanying images.

Conflict-of-interest statement: The authors report no conflicts of interest.

CARE Checklist (2016) statement: The authors have read the CARE Checklist (2016), and the manuscript was prepared and revised according to the CARE Checklist (2016).

Open-Access: This article is an open-access article that was selected by an in-house editor and fully peer-reviewed by external reviewers. It is distributed in accordance with the Creative Commons Attribution NonCommercial (CC BY-NC 4.0) license, which permits others to distribute, remix, adapt, build upon this work non-commercially, and license their derivative works on different terms, provided the original work is properly cited and the use is non-commercial. See: <http://creativecommons.org/licenses/by-nc/4.0/>

Country/Territory of origin: China

ORCID number: Ying Chen 0000-0003-1378-9621; Mei Sun 0000-0003-1497-6912; Xu Teng 0000-0002-0566-5859.

S-Editor: Wu YXJ

L-Editor: A

P-Editor: Wu YXJ

REFERENCES

- 1 **Lirio RA.** Management of Upper Gastrointestinal Bleeding in Children: Variceal and Nonvariceal. *Gastrointest Endosc Clin N Am* 2016; **26**: 63-73 [PMID: 26616897 DOI: 10.1016/j.giec.2015.09.003]
- 2 **Zamulko OY, Zamulko AO, Dawson MJ.** Introducing GIST and Dieulafoy - Think of Them in GI Bleeding and Anemia. *S D Med* 2019; **72**: 528-530 [PMID: 31985905]
- 3 **Inayat F, Ullah W, Hussain Q, Hurairah A.** Dieulafoy's lesion of the oesophagus: a case series and literature review. *BMJ Case Rep* 2017; **2017** [PMID: 28062437 DOI: 10.1136/bcr-2016-218100]
- 4 **Bai Y, Li ZS.** Standardize the diagnosis and treatment of acute non-variceal upper gastrointestinal bleeding based on the update guidelines. *Zhongguo Neike Zazhi* 2019; **58**: 161-163 [DOI: 10.3760/cma.j.issn.0578-1426.2019.03.001]
- 5 **Chaer RA, Helton WS.** Dieulafoy's disease. *J Am Coll Surg* 2003; **196**: 290-296 [PMID: 12595057 DOI: 10.1016/S1072-7515(02)01801-X]
- 6 **Chen QK, He GX, Zhu ZH.** Diagnosis of digestive disease. 2nd ed. Beijing: People's Medical Publishing House 2006: 418
- 7 **Gambhire PA, Jain SS, Rathi PM, Amarapurkar AD.** Dieulafoy disease of stomach--an uncommon cause of gastrointestinal system bleeding. *J Assoc Physicians India* 2014; **62**: 526-528 [PMID: 25856921]
- 8 **Holleran G, Hussey M, McNamara D.** Small bowel Dieulafoy lesions: An uncommon cause of obscure bleeding in cirrhosis. *World J Gastrointest Endosc* 2016; **8**: 568-571 [PMID: 27621769 DOI: 10.4253/wjge.v8.i16.568]
- 9 **Senger JL, Kanthan R.** The Evolution of Dieulafoy's Lesion Since 1897: Then and Now-A Journey through the Lens of a Pediatric Lesion with Literature Review. *Gastroenterol Res Pract* 2012; **2012**: 432517 [PMID: 22474434 DOI: 10.1155/2012/432517]
- 10 **Tang P, Wu T, Li C, Lv C, Huang J, Deng Z, Ding Q.** Dieulafoy disease of the bronchus involving bilateral arteries: A case report and literature review. *Medicine (Baltimore)* 2019; **98**: e17798 [PMID: 31689858 DOI: 10.1097/MD.00000000000017798]
- 11 **Joarder AI, Faruque MS, Nur-E-Elahi M, Jahan I, Siddiqui O, Imdad S, Islam MS, Ahmed HS, Haque MA.** Dieulafoy's lesion: an overview. *Mymensingh Med J* 2014; **23**: 186-194 [PMID: 24584397]
- 12 **Driver CP, Bruce J.** An unusual cause of massive gastric bleeding in a child. *J Pediatr Surg* 1997; **32**: 1749-1750 [PMID: 9434017 DOI: 10.1016/s0022-3468(97)90524-8]
- 13 **Chung IK, Kim EJ, Lee MS, Kim HS, Park SH, Lee MH, Kim SJ, Cho MS.** Bleeding Dieulafoy's lesions and the choice of endoscopic method: comparing the hemostatic efficacy of mechanical and injection methods. *Gastrointest Endosc* 2000; **52**: 721-724 [PMID: 11115902 DOI: 10.1067/mge.2000.108040]
- 14 **Apiratpracha W, Ho JK, Powell JJ, Yoshida EM.** Acute lower gastrointestinal bleeding from a dieulafoy lesion proximal to the anorectal junction post-orthotopic liver transplant. *World J Gastroenterol* 2006; **12**: 7547-7548 [PMID: 17167849 DOI: 10.3748/wjg.v12.i46.7547]
- 15 **Xu X, Zhang YS, Yuan J, Zhang ZY.** Diagnosis and treatment of dieulafoy disease. *Zhongguo Weichangbingxue Ganbingxue Zazhi* 2009; **18**: 870-871
- 16 **Alshumrani G, Almuaikael M.** Angiographic findings and endovascular embolization in Dieulafoy disease: a case report and literature review. *Diagn Interv Radiol* 2006; **12**: 151-154 [PMID: 16972222]

- 17 **Jeon HK**, Kim GH. Endoscopic Management of Dieulafoy's Lesion. *Clin Endosc* 2015; **48**: 112-120 [PMID: [25844338](#) DOI: [10.5946/ce.2015.48.2.112](#)]
- 18 **Baxter M**, Aly EH. Dieulafoy's lesion: current trends in diagnosis and management. *Ann R Coll Surg Engl* 2010; **92**: 548-554 [PMID: [20883603](#) DOI: [10.1308/003588410X12699663905311](#)]
- 19 **Alis H**, Oner OZ, Kalayci MU, Dolay K, Kapan S, Soylu A, Aygun E. Is endoscopic band ligation superior to injection therapy for Dieulafoy lesion? *Surg Endosc* 2009; **23**: 1465-1469 [PMID: [19125307](#) DOI: [10.1007/s00464-008-0255-8](#)]
- 20 **Li F**, Li YX, Shen L. Endoscopic diagnosis and treatment of 23 Dieulafoy's disease. *J Clin Intern Med* 2011; **19**: 821-822 [DOI: [10.3969/j.issn.1001-9057.2019.007.004](#)]
- 21 **Ganganah O**, Guo S, Chiniah M, Sah SK, Wu J. Endobronchial ultrasound and bronchial artery embolization for Dieulafoy's disease of the bronchus in a teenager: A case report. *Respir Med Case Rep* 2015; **16**: 20-23 [PMID: [26744645](#) DOI: [10.1016/j.rmcr.2015.04.007](#)]
- 22 **Yilmaz TU**, Kozan R. Duodenal and jejunal Dieulafoy's lesions: optimal management. *Clin Exp Gastroenterol* 2017; **10**: 275-283 [PMID: [29158686](#) DOI: [10.2147/CEG.S122784](#)]



Published by **Baishideng Publishing Group Inc**
7041 Koll Center Parkway, Suite 160, Pleasanton, CA 94566, USA

Telephone: +1-925-3991568

E-mail: bpgoffice@wjgnet.com

Help Desk: <https://www.f6publishing.com/helpdesk>

<https://www.wjgnet.com>

