

World Journal of *Clinical Cases*

World J Clin Cases 2022 January 14; 10(2): 397-752



Contents

Thrice Monthly Volume 10 Number 2 January 14, 2022

EDITORIAL

- 397 New trends in treatment of muscle fatigue throughout rehabilitation of elderlies with motor neuron diseases
Mohamed A

MINIREVIEWS

- 401 What emotion dimensions can affect working memory performance in healthy adults? A review
Hou TY, Cai WP
- 412 Quadrilateral plate fractures of the acetabulum: Classification, approach, implant therapy and related research progress
Zhou XF, Gu SC, Zhu WB, Yang JZ, Xu L, Fang SY

ORIGINAL ARTICLE

Case Control Study

- 426 Methylprednisolone accelerate chest computed tomography absorption in COVID-19: A three-centered retrospective case control study from China
Lin L, Xue D, Chen JH, Wei QY, Huang ZH

Retrospective Study

- 437 Analysis of photostimulable phosphor image plate artifacts and their prevalence
Elkhateeb SM, Aloyouny AY, Omer MMS, Mansour SM
- 448 N6-methyladenine-modified DNA was decreased in Alzheimer's disease patients
Lv S, Zhou X, Li YM, Yang T, Zhang SJ, Wang Y, Jia SH, Peng DT
- 458 Inflammation-related indicators to distinguish between gastric stromal tumors and leiomyomas: A retrospective study
Zhai YH, Zheng Z, Deng W, Yin J, Bai ZG, Liu XY, Zhang J, Zhang ZT
- 469 Relationship between Ki-67 and CD44 expression and microvascular formation in gastric stromal tumor tissues
Ma B, Huang XT, Zou GJ, Hou WY, Du XH
- 477 Modified surgical method of supra- and infratentorial epidural hematoma and the related anatomical study of the squamous part of the occipital bone
Li RC, Guo SW, Liang C
- 485 Combined molybdenum target X-ray and magnetic resonance imaging examinations improve breast cancer diagnostic efficacy
Gu WQ, Cai SM, Liu WD, Zhang Q, Shi Y, Du LJ

- 492 Value of thyroglobulin combined with ultrasound-guided fine-needle aspiration cytology for diagnosis of lymph node metastasis of thyroid carcinoma

Zhang LY, Chen Y, Ao YZ

- 502 Locking compression plate + T-type steel plate for postoperative weight bearing and functional recovery in complex tibial plateau fractures

Li HF, Yu T, Zhu XF, Wang H, Zhang YQ

- 511 Effect of Mirena placement on reproductive hormone levels at different time intervals after artificial abortion

Jin XX, Sun L, Lai XL, Li J, Liang ML, Ma X

- 518 Diagnostic value of artificial intelligence automatic detection systems for breast BI-RADS 4 nodules

Lyu SY, Zhang Y, Zhang MW, Zhang BS, Gao LB, Bai LT, Wang J

Clinical Trials Study

- 528 Analysis of 20 patients with laparoscopic extended right colectomy

Zheng HD, Xu JH, Liu YR, Sun YF

Observational Study

- 538 Knowledge, attitude, practice and factors that influence the awareness of college students with regards to breast cancer

Zhang QN, Lu HX

- 547 Diagnosing early scar pregnancy in the lower uterine segment after cesarean section by intracavitary ultrasound

Cheng XL, Cao XY, Wang XQ, Lin HL, Fang JC, Wang L

- 554 Impact of failure mode and effects analysis-based emergency management on the effectiveness of craniocerebral injury treatment

Shao XL, Wang YZ, Chen XH, Ding WJ

- 563 Predictive value of alarm symptoms in Rome IV irritable bowel syndrome: A multicenter cross-sectional study

Yang Q, Wei ZC, Liu N, Pan YL, Jiang XS, Tantai XX, Yang Q, Yang J, Wang JJ, Shang L, Lin Q, Xiao CL, Wang JH

Prospective Study

- 576 5-min mindfulness audio induction alleviates psychological distress and sleep disorders in patients with COVID-19

Li J, Zhang YY, Cong XY, Ren SR, Tu XM, Wu JF

META-ANALYSIS

- 585 Efficacy and safety of argatroban in treatment of acute ischemic stroke: A meta-analysis

Ly B, Guo FF, Lin JC, Jing F

SCIENTOMETRICS

- 594 Biologic therapy for Crohn's disease over the last 3 decades
Shen JL, Zhou Z, Cao JS, Zhang B, Hu JH, Li JY, Liu XM, Juengpanich S, Li MS, Feng X

CASE REPORT

- 607 Novel compound heterozygous GPR56 gene mutation in a twin with lissencephaly: A case report
Lin WX, Chai YY, Huang TT, Zhang X, Zheng G, Zhang G, Peng F, Huang YJ
- 618 Patients with SERPINC1 rs2227589 polymorphism found to have multiple cerebral venous sinus thromboses despite a normal antithrombin level: A case report
Liao F, Zeng JL, Pan JG, Ma J, Zhang ZJ, Lin ZJ, Lin LF, Chen YS, Ma XT
- 625 Successful management of delirium with dexmedetomidine in a patient with haloperidol-induced neuroleptic malignant syndrome: A case report
Yang CJ, Chiu CT, Yeh YC, Chao A
- 631 Malignant solitary fibrous tumor in the central nervous system treated with surgery, radiotherapy and anlotinib: A case report
Zhang DY, Su L, Wang YW
- 643 Anesthesia and perioperative management for giant adrenal Ewing's sarcoma with inferior vena cava and right atrium tumor thrombus: A case report
Wang JL, Xu CY, Geng CJ, Liu L, Zhang MZ, Wang H, Xiao RT, Liu L, Zhang G, Ni C, Guo XY
- 656 Full-endoscopic spine surgery treatment of lumbar foraminal stenosis after osteoporotic vertebral compression fractures: A case report
Zhao QL, Hou KP, Wu ZX, Xiao L, Xu HG
- 663 Ethambutol-induced optic neuropathy with rare bilateral asymmetry onset: A case report
Sheng WY, Wu SQ, Su LY, Zhu LW
- 671 Vitrectomy with residual internal limiting membrane covering and autologous blood for a secondary macular hole: A case report
Ying HF, Wu SQ, Hu WP, Ni LY, Zhang ZL, Xu YG
- 677 Intervertebral bridging ossification after kyphoplasty in a Parkinson's patient with Kummell's disease: A case report
Li J, Liu Y, Peng L, Liu J, Cao ZD, He M
- 685 Synovial chondromatosis of the hip joint in a 6 year-old child: A case report
Yi RB, Gong HL, Arthur DT, Wen J, Xiao S, Tang ZW, Xiang F, Wang KJ, Song ZQ
- 691 Orthodontic retreatment of an adult woman with mandibular backward positioning and temporomandibular joint disorder: A case report
Yu LY, Xia K, Sun WT, Huang XQ, Chi JY, Wang LJ, Zhao ZH, Liu J

- 703** Autosomal recessive spinocerebellar ataxia type 4 with a *VPS13D* mutation: A case report
Huang X, Fan DS
- 709** Primary adrenal diffuse large B-cell lymphoma with normal adrenal cortex function: A case report
Fan ZN, Shi HJ, Xiong BB, Zhang JS, Wang HF, Wang JS
- 717** Varicella-zoster virus-associated meningitis, encephalitis, and myelitis with sporadic skin blisters: A case report
Takami K, Kenzaka T, Kumabe A, Fukuzawa M, Eto Y, Nakata S, Shinohara K, Endo K
- 725** Tension pneumocephalus following endoscopic resection of a mediastinal thoracic spinal tumor: A case report
Chang CY, Hung CC, Liu JM, Chiu CD
- 733** Accelerated Infliximab Induction for Severe Lower Gastrointestinal Bleeding in a Young Patient with Crohn's Disease: A Case Report
Zeng J, Shen F, Fan JG, Ge WS
- 741** Occupational fibrotic hypersensitivity pneumonia in a halogen dishes manufacturer: A case report
Wang M, Fang HH, Jiang ZF, Ye W, Liu RY
- 747** Using a fretsaw in treating chronic penial incarceration: A case report
Zhao Y, Xue XQ, Huang HF, Xie Y, Ji ZG, Fan XR

ABOUT COVER

Associate Editor of *World Journal of Clinical Cases*, Bruno Ramos Chrcanovic, DDS, MSc, PhD, Associate Professor, Department of Prosthodontics, Malmö University, Malmö 241 21, Sweden. bruno.chrcanovic@mau.se

AIMS AND SCOPE

The primary aim of *World Journal of Clinical Cases* (WJCC, *World J Clin Cases*) is to provide scholars and readers from various fields of clinical medicine with a platform to publish high-quality clinical research articles and communicate their research findings online.

WJCC mainly publishes articles reporting research results and findings obtained in the field of clinical medicine and covering a wide range of topics, including case control studies, retrospective cohort studies, retrospective studies, clinical trials studies, observational studies, prospective studies, randomized controlled trials, randomized clinical trials, systematic reviews, meta-analysis, and case reports.

INDEXING/ABSTRACTING

The WJCC is now indexed in Science Citation Index Expanded (also known as SciSearch®), Journal Citation Reports/Science Edition, Scopus, PubMed, and PubMed Central. The 2021 Edition of Journal Citation Reports® cites the 2020 impact factor (IF) for WJCC as 1.337; IF without journal self cites: 1.301; 5-year IF: 1.742; Journal Citation Indicator: 0.33; Ranking: 119 among 169 journals in medicine, general and internal; and Quartile category: Q3. The WJCC's CiteScore for 2020 is 0.8 and Scopus CiteScore rank 2020: General Medicine is 493/793.

RESPONSIBLE EDITORS FOR THIS ISSUE

Production Editor: *Jia-Hui Li*; Production Department Director: *Xu Guo*; Editorial Office Director: *Jim-Lai Wang*.

NAME OF JOURNAL

World Journal of Clinical Cases

ISSN

ISSN 2307-8960 (online)

LAUNCH DATE

April 16, 2013

FREQUENCY

Thrice Monthly

EDITORS-IN-CHIEF

Bao-Gan Peng, Jerzy Tadeusz Chudek, George Kontogeorgos, Maurizio Serati, Ja Hyeon Ku

EDITORIAL BOARD MEMBERS

<https://www.wjgnet.com/2307-8960/editorialboard.htm>

PUBLICATION DATE

January 14, 2022

COPYRIGHT

© 2022 Baishideng Publishing Group Inc

INSTRUCTIONS TO AUTHORS

<https://www.wjgnet.com/bpg/gerinfo/204>

GUIDELINES FOR ETHICS DOCUMENTS

<https://www.wjgnet.com/bpg/GerInfo/287>

GUIDELINES FOR NON-NATIVE SPEAKERS OF ENGLISH

<https://www.wjgnet.com/bpg/gerinfo/240>

PUBLICATION ETHICS

<https://www.wjgnet.com/bpg/GerInfo/288>

PUBLICATION MISCONDUCT

<https://www.wjgnet.com/bpg/gerinfo/208>

ARTICLE PROCESSING CHARGE

<https://www.wjgnet.com/bpg/gerinfo/242>

STEPS FOR SUBMITTING MANUSCRIPTS

<https://www.wjgnet.com/bpg/GerInfo/239>

ONLINE SUBMISSION

<https://www.f6publishing.com>



Tension pneumocephalus following endoscopic resection of a mediastinal thoracic spinal tumor: A case report

Chao-Yuan Chang, Cheng-Che Hung, Ju-Mien Liu, Cheng-Di Chiu

ORCID number: Chao-Yuan Chang 0000-0002-6112-9495; Cheng-Che Hung 0000-0001-6461-6312; Ju-Mien Liu 0000-0001-5025-9166; Cheng-Di Chiu 0000-0003-0369-0935.

Author contributions: Chiu CD designed the study; Liu JM and Hung CC acquired the patient's data; Chang CY analyzed and interpreted the data and drafted the manuscript; Chang CY and Chiu CD revised the manuscript critically for important intellectual content; all authors read and approved the final manuscript.

Informed consent statement: The patient has provided informed consent for publication of this case report and any accompanying images.

Conflict-of-interest statement: The authors declare that they have no competing interests.

CARE Checklist (2016) statement: The authors have read the CARE Checklist (2016), and the manuscript was prepared and revised according to the CARE Checklist (2016).

Supported by China Medical University Hospital (No. DMR-107-063).

Country/Territory of origin: Taiwan

Chao-Yuan Chang, Cheng-Che Hung, Cheng-Di Chiu, Department of Neurosurgery, China Medical University Hospital, Taichung 40447, Taiwan

Ju-Mien Liu, Department of Pathology, Puli Christian Hospital, Nantou 54041, Taiwan

Corresponding author: Cheng-Di Chiu, MD, PhD, Associate Professor, Deputy Director, Department of Neurosurgery, China Medical University Hospital, No. 2 Yu-Der Road, North Area, Taichung, Taiwan 40447, Taiwan. cdchiu4046@gmail.com

Abstract

BACKGROUND

Pneumocephalus is a rare complication presenting in the postoperative period of a thoracoscopic operation. We report a case in which tension pneumocephalus occurred after thoracoscopic resection as well as the subsequent approach of surgical management.

CASE SUMMARY

A 66-year-old man who received thoracoscopic resection to remove an intrathoracic, posterior mediastinal, dumbbell-shaped, pathology-proven neurogenic tumor. The patient then reported experiencing progressively severe headaches, especially when in an upright position. A brain computed tomography scan at a local hospital disclosed extensive pneumocephalus. Revision surgery for resection of the pseudomeningocele and repair of the cerebrospinal fluid leakage was thus arranged for the patient. During the operation, we traced the cerebrospinal fluid leakage and found that it might have derived from incomplete endoscopic clipping around the tumor stump near the dural sac at the T3 level. After that, we wrapped and sealed all the possible origins of the leakage with autologous fat, tissue glue, gelfoam, and duraseal layer by layer. The patient recovered well, and the computed tomography images showed resolution of the pneumocephalus.

CONCLUSION

This report and literature review indicated that the risk of developing a tension pneumocephalus cannot be ignored and should be monitored carefully after thoracoscopic tumor resection.

Key Words: Tension pneumocephalus; Neurogenic tumor; Thoracoscope; Case report

©The Author(s) 2022. Published by Baishideng Publishing Group Inc. All rights reserved.

Specialty type: Surgery**Provenance and peer review:**

Unsolicited article; Externally peer reviewed.

Peer-review model: Single blind**Peer-review report's scientific quality classification**

Grade A (Excellent): 0

Grade B (Very good): B

Grade C (Good): C

Grade D (Fair): 0

Grade E (Poor): 0

Open-Access: This article is an open-access article that was selected by an in-house editor and fully peer-reviewed by external reviewers. It is distributed in accordance with the Creative Commons Attribution NonCommercial (CC BY-NC 4.0) license, which permits others to distribute, remix, adapt, build upon this work non-commercially, and license their derivative works on different terms, provided the original work is properly cited and the use is non-commercial. See: <http://creativecommons.org/licenses/by-nc/4.0/>

Received: August 19, 2021

Peer-review started: August 19, 2021

First decision: November 1, 2021

Revised: November 12, 2021

Accepted: December 7, 2021

Article in press: December 7, 2021

Published online: January 14, 2022

P-Reviewer: Elpek GO, Kim JW

S-Editor: Wang JL

L-Editor: Filipodia

P-Editor: Wang JL



Core Tip: Pneumocephalus is a rare complication that presents during the postoperative period following a thoracoscopic resection of spinal dumbbell tumors. Here, we present a potential method for resolving tension pneumocephalus and present our detailed experiences following the thoracoscopic resection of a posterior mediastinal dumbbell tumor, together with a review of the literature. The risks of experiencing pneumocephalus following thoracoscopic resection for a spinal tumor cannot be neglected because intraoperative repair is difficult to assess.

Citation: Chang CY, Hung CC, Liu JM, Chiu CD. Tension pneumocephalus following endoscopic resection of a mediastinal thoracic spinal tumor: A case report. *World J Clin Cases* 2022; 10(2): 725-732

URL: <https://www.wjgnet.com/2307-8960/full/v10/i2/725.htm>

DOI: <https://dx.doi.org/10.12998/wjcc.v10.i2.725>

INTRODUCTION

Tension pneumocephalus (TP) is defined as the presence of air in the intracranial space, causing intracranial hypertension and a mass effect[1,2]. The clinical presentation of TP may include headache, nausea, vomiting, vertigo, aphasia, hemiparesis, altered levels of consciousness, and frontal lobe syndrome[1-4]. Because most symptoms associated with TP are non-specific, the diagnosis primarily depends on imaging findings. The formation of TP can be fatal if not diagnosed early and treated properly[5].

Spinal dumbbell tumors accounted for 17% to 22% of all spinal cord tumors according to previous reports[6,7] and are classified as epidural, intradural, or paravertebral depending on the locations involved[6]. Laminectomy with costotransversectomy has been presented as an effective method for the resection of thoracic dumbbell tumors involving large intraspinal and paraspinal regions[8,9]. Anterior approaches may also be feasible for the treatment of tumors that only involve the paraspinal region[10]. However, complications may develop after surgery, including pleural injury, bleeding, damage to the spinal cord, and cerebrospinal fluid leakage[8-10]. Few cases have been reported regarding the occurrence and management of pneumocephalus following the thoracoscopic resection of a neurogenic tumor[11,12]. We report a case in which TP developed after a thoracoscopic resection and describe the subsequent surgical management approach.

CASE PRESENTATION

Chief complaints

A 66-year-old man described suffering from severe headache and vomiting, which became exaggerated with postural changes, following treatment with thoracoscopic resection to remove a neurogenic tumor.

History of present illness

The symptoms appeared starting on the 7th postoperative day.

History of past illness

The patient was previously diagnosed with a thoracic spinal dumbbell tumor.

Personal and family history

None.

Physical examination

The patient was sent to our emergency department, where a neurological examination showed clear consciousness (Glasgow coma scale: E4V5M6) with drowsiness and disorientation, no cranial nerve abnormalities, and full muscle power in all four limbs. Preoperatively, the patient's body temperature was 36.4 °C, blood pressure was

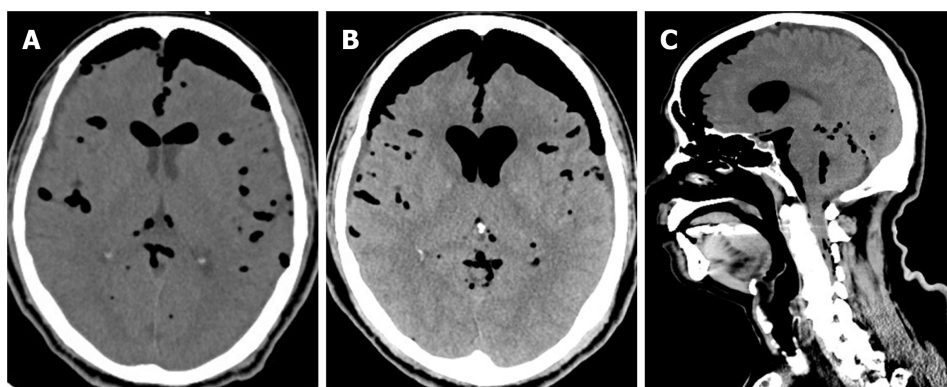


Figure 1 Computed tomography scans of the patient's brain showing tension pneumocephalus. A: Non-contrast views of preoperative brain computed tomography images; B-C: Images of axial (B) and sagittal view (C) show progressive tension pneumocephalus, pneumoventricle, and air leak in the spinal canal.

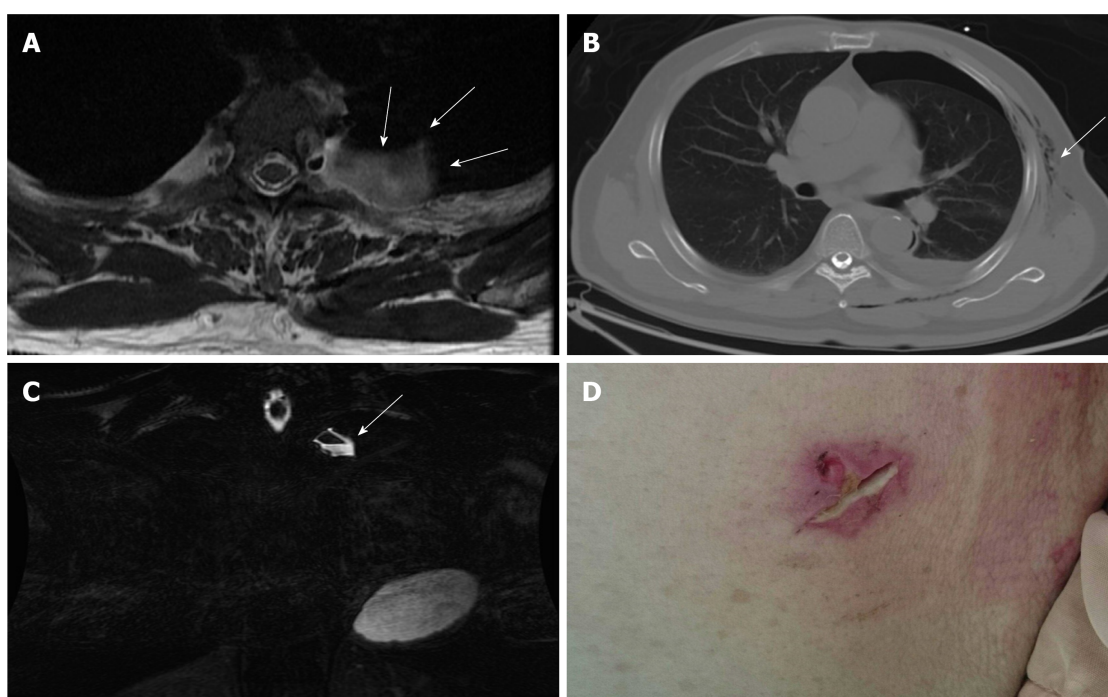


Figure 2 Pre-operative evaluations. A-B: T2-weighted magnetic resonance imaging in axial view (A) and fast spin echo, fat-suppression coronal view (B) showing a cystic pouch laterally surrounding the spinal nerve root at left T3 level (arrow), which may be derived from the neural foramen of the L3 level. The air-fluid level was also demonstrated (arrow); C) Axial view of chest computed tomography showing pneumothorax and subcutaneous emphysema (arrow); D) Poorly healing previous thoracoscopic access wound.

145/73 mmHg, heart rate was 90 bpm, and respiratory rate was 16 breaths per minute. The patient had normal heart and clear lungs sounds.

Laboratory examinations

Before the surgery, the patient presented with normal white blood cell, neutrophil, lymphocyte, and monocyte counts, and slight decreases in red blood cell count ($3.48 \times 10^6/\mu\text{L}$), hemoglobin concentration (11.0 g/dL), and hematocrit level (31.7%) were detected.

Imaging examinations

A brain computed tomography scan demonstrated TP and pneumoventricle with the air extending down into the intraspinal space, and the progression of TP was found 3 d after his admission to the intensive care unit (Figure 1). A magnetic resonance imaging scan of the thoracic spine disclosed a left T2/T3 pseudomeningocele with air-fluid level, while a chest computed tomography demonstrated pneumothorax and subcutaneous emphysema around the poorly healing previous thoracoscopic access

Table 1 Reported cases which pneumocephalus developed after surgical treatments for spinal or posterior mediastinal tumor

Ref.	Article type	Cases with pneumocephalus	Histology	Spinal region	Relation to dura
Trujillo-Reyes <i>et al</i> , 2014	Case report	1/1	Schwannoma	Thoracic	ND
Huang <i>et al</i> , 2005	Case report	1/1	Neurilemmoma	Thoracic	ND
Nam <i>et al</i> , 2019	Case series	18/20	Schwannoma (<i>n</i> = 16)/ Meningioma (<i>n</i> = 4)	Cervical (15%)Thoracic (60%)Lumbar (25%)	IDEM
Kim <i>et al</i> , 2008	Case report	1/1	Myxopapillary ependymoma	Lumbar	IDEM
Özdemir <i>et al</i> , 2017	Case report	1/1	ND	Lumbar	IDEM
Bilsky <i>et al</i> , 2000	Case report	1/3	Neurofibroma	Thoracic	ND

ND: No data; IDEM: Intradural-extramedullary.

Table 2 Reported cases which pneumocephalus developed after surgical treatments for spinal or posterior mediastinal tumor

Ref.	Surgical approach	Clinical symptoms	CSF leakage	Interventions
Trujillo-Reyes <i>et al</i> , 2014	VATS	Headache, vomiting	ND	Bed rest, oxygen
Huang <i>et al</i> , 2005	VATS	Headache, progressive loss of consciousness	Postoperative chest tube drainage amount increased	Bilateral frontal burr hole, Trendelenburg position
Nam <i>et al</i> , 2019	Posterior (laminectomy+ durotomy)	Headache	Intraoperative duratomy and primary suture with artificial dural and fibroblastic glue	Bed rest, analgesics
Kim <i>et al</i> , 2008	Posterior (laminectomy+ durotomy)	Headache, restless	Intraoperative duratomy and primary suture with fibroblastic glue	Bed rest, hydration
Özdemir <i>et al</i> , 2017	Posterior (laminectomy + durotomy)	Headache, nausea, vomiting	ND	Bed rest, hydration
Bilsky <i>et al</i> , 2000	Posteriorlateral thoracotomy	Lethargy, confusion	Postoperative chest tube drainage amount increased	Discontinue chest tube, bed rest

CSF: Cerebrospinal fluid; VATS: Video-assisted thoracoscopic surgery; ND: No data.

wound (Figure 2). The thoracic spinal neurofibroma had been almost totally removed but was complicated with pneumothorax, cerebrospinal fluid (CSF) leakage, and TP.

Histological examination

The tumor was pathologically proven to be a neurogenic tumor consisting of neurofibroma (Figure 3). According to the postoperative microscopic examination, the cyst contained chronic inflammation of tissue and no residual tumor.

FINAL DIAGNOSIS

The presented case was diagnosed with tension pneumocephalus after a thoracoscopic resection to remove a neurogenic tumor.

TREATMENT

He then was admitted to the intensive care unit for further close monitoring and medical treatments including full hydration, prophylactic antibiotics use, O₂ supplementation, lying absolutely flat, and primary suturing and debridement of the chest

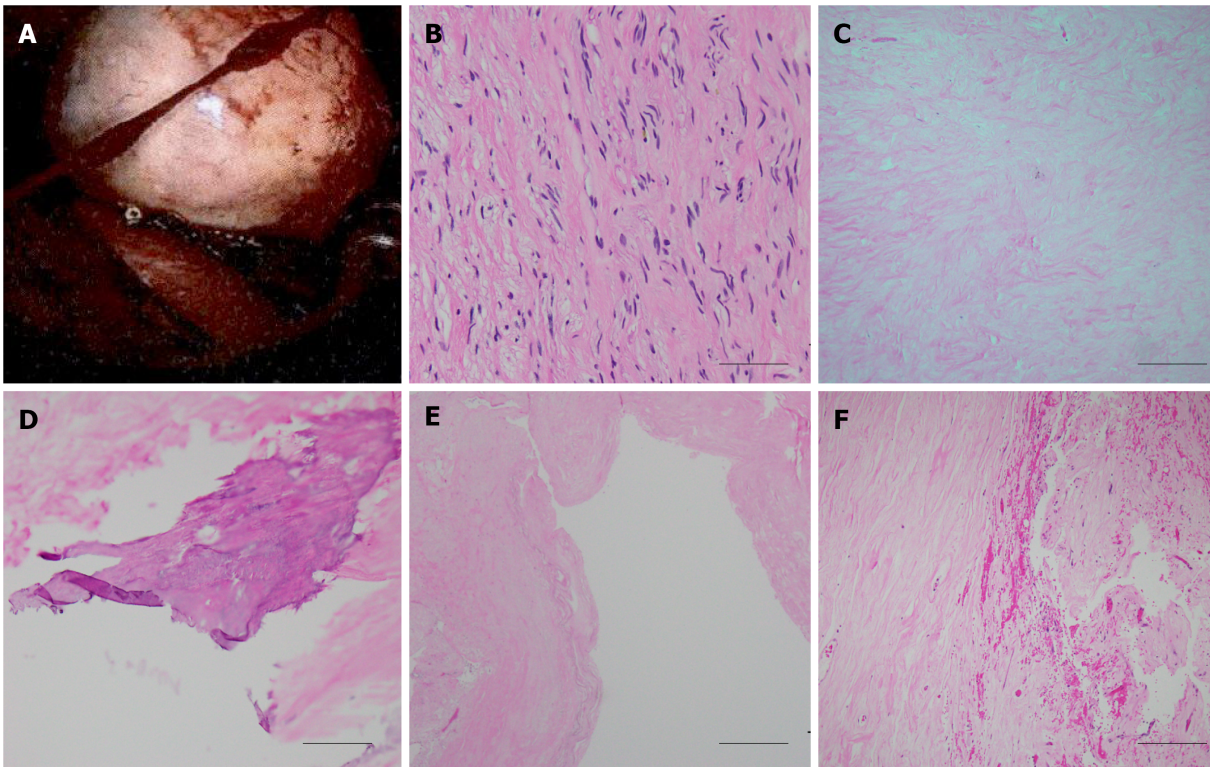


Figure 3 Histological examination of the spinal tumor. A: Intraoperative image of the posterior mediastinal tumor demonstrated well-defined border, which was pathologically proved to be neurogenic tumor; B-F: A histological image of the neurofibroma showing bland spindle cells with wavy nuclei and pale eosinophilic cytoplasm (scale bar 50 μ m) (B), secondary degeneration of hyalinization (scale bar 200 μ m) (C), calcification (scale bar 100 μ m) (D), cyst (scale bar 500 μ m) (E), and hemorrhage (scale bar 200 μ m) (F).

wound. However, the symptoms did not improve. Thus, surgical treatments were performed to repair the CSF leakages. Following a left T2-3 hemilaminectomy and costotransversectomy, a cystic meningocele was found. After the cyst pouch was totally removed, the previous remnant tumor stump and surgical clip were explored meticulously. CSF leaking from the surgical clip near the dura was disclosed. The leakage site was wrapped with autologous fat, gelfoam, tissue glue, and duraseal in a layer-by-layer manner (Figure 4). Finally, the wound was closed in a layer-by-layer manner with a Jackson-Pratt tube that was left in the surgical field.

OUTCOME AND FOLLOW-UP

At the 2-wk follow-up and evaluation, the patient denied experiencing any further headaches. The follow-up brain computed tomography scan showed resolution of the pneumocephalus, pneumoventricle, pneumothorax, and pneumospine (Figure 5).

DISCUSSION

The reported theories of pneumocephalus development include the “ball-valve theory” and “inverted soda bottle effect” [13,14]. The possible mechanisms to develop pneumocephalus after thoracoscopic resection include dural tearing with persistent cerebrospinal fluid leakage, such that air can gain access from the leakage site to the intradural space and reach the cranial cavity. The negative pressure produced by chest tube suction can even deteriorate the CSF extravasation. On the other hand, an upright head position also allows the air to easily enter the intradural space from the leakage site. Relatedly, in our case, a poorly healing thoracoscopic access wound resulted in pneumothorax and an aggravating pneumocephalus. Based on the imaging results of the current case, TP was indicated by two imaging characteristics. One, the “Mt. Fuji sign,” means that subdural air with increased tension is separating and compressing the bilateral frontal lobes and widening the interhemispheric space, such that the

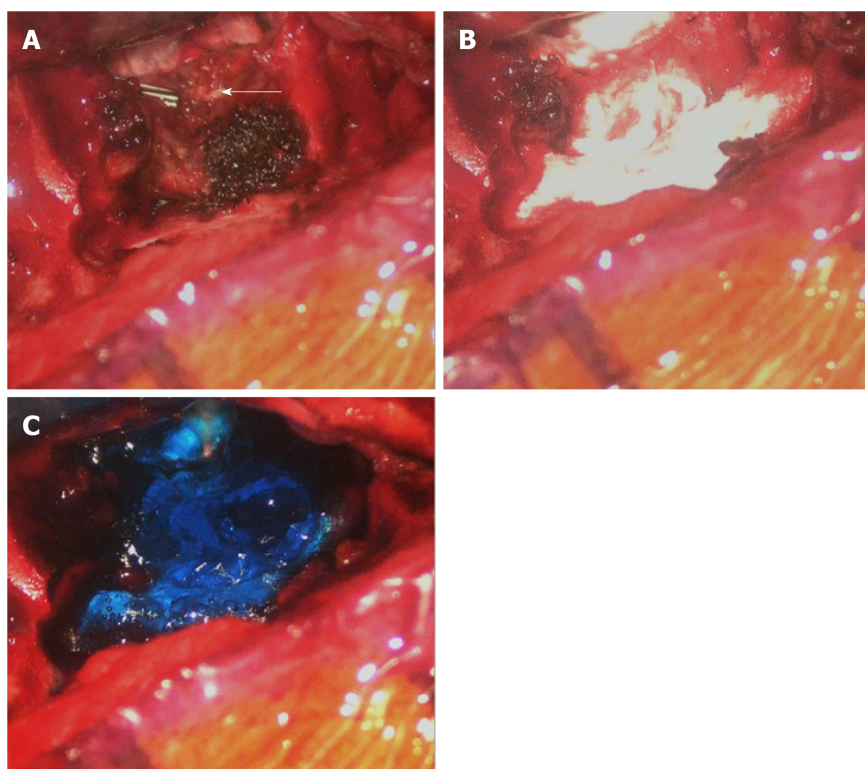


Figure 4 Intraoperative images of the surgical repair. A: Cerebrospinal fluid leakage might derive from the previous endoscopic clipped tumor stump near the dural sac of the T3 level (arrow); B-C: Repairing of the leakage sites with tissue glue, gelfoam, and dural seal.

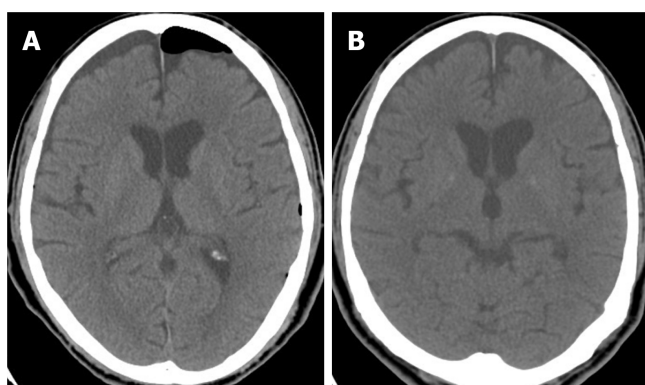


Figure 5 Post-operative computed tomography images demonstrate successful repair. A-B: Axial view of brain computed tomography on the 5th (A) and 15th postoperative day (B) showing resolution of pneumocephalus and pneumoventricle through subdural effusion accumulation without brain parenchymal compression.

resulting image resembles the silhouette of Mt. Fuji. The other, the “air bubble sign,” indicates that multiple air bubbles are scattered through the cistern, with these air bubbles putatively entering the subarachnoid space due to tearing of the arachnoid membrane caused by increased tension in the subdural space[2,3]. This appeared to apply in our case, with the source of intracranial air being a spinal dural defect that resulted in air also being apparent in the spinal cord, ventricle, and basal cistern[12].

We performed the literature review using a search of English literature from PubMed, in which the source of databases ranged from 2000 to 2019. The key words and criteria for search engine was represented as “pneumocephalus [title] AND spinal tumor” where 11 results were generated. We further summarized the reported cases in which pneumocephalus developed after surgical treatments for spinal or posterior mediastinal tumor and specified their subsequent interventions (Tables 1, 2). Though only 23 cases in which pneumocephalus developed after surgical treatments for spinal or posterior mediastinal tumor had been reported within the recent 10 years, most patients can be treated only by conservative medical therapeutic strategies, including

highly concentrated O₂ supplementation to accelerate the resorption of intracranial air, bed rest with the head laid flat to minimize CSF leakage from the dural defect, avoidance of the Valsalva maneuver, and prophylactic antibiotics use if meningitis is highly suspected (Tables 1, 2). Surgical intervention consisting of the evacuation of the intracranial air and repair of the dural defect is indicated when the above conservative treatments fail, when the recurrence of pneumocephalus occurs, or when there are signs of increasing intracranial pressure[1-4,12]. In our case for progressive pneumocephalus, we preferred to conduct surgical intervention rather than conservative treatment. The direct method of dura repair was chosen in consideration to the developing CSF fistula. Then, the intracranial air was evacuated until the CSF leakage site was sealed completely. Initial frontal burr hole decompression for pneumocephalus was demonstrated in a similar case for rapid consciousness change and cranial nerve palsy under the impression of increased intracranial pressure signs, of which the clinical signs were improved postoperatively[12]. In our opinion, the direct method for dural repair can obliterate the origin of CSF leakage and fistula formation. Thus, the pneumocephalus may be absorbed spontaneously as long as there is no further air getting access[15].

Intraoperative primary repair with suturing is highly recommended for preventing postoperative CSF leakage[16]. However, the primary closure of a durotomy may be difficult because of its location (*e.g.*, in the case of ventral or far-lateral durotomies), a large dural defect, poor tensile strength of the dura, or a minimal invasive wound limiting the exposure and access[15]. Several alternative methods of durotomy repair have been described. For example, an additional dorsal durotomy for far-lateral or dorsal defects can allow such defects to be more easily visualized and plugged with autograft or suturing[15], while autograft coverage with dural sealant in cases of durotomies that cannot be repaired primarily due to limited visibility or access[15,17], an aneurysm clip, or a titanium clip have also been reported[18,19]. In our case, as the CSF leakage might have derived from the previous endoscopically clipped tumor stump near the dural sac at the T3 level, such that it would have been difficult to perform a primary suture repair. Thus, we plugged and wrapped the stump with an autograft of fat, tissue glue, gelfoam, and duraseal (Figure 4).

CONCLUSION

The risk of getting a pneumocephalus after thoracoscopic resection of a spinal tumor cannot be neglected since the intraoperative repair is hard to access. The direct approach for dural repair may be an attemptable way to eliminate the CSF leakages.

REFERENCES

- 1 Kankane VK, Jaiswal G, Gupta TK. Posttraumatic delayed tension pneumocephalus: Rare case with review of literature. *Asian J Neurosurg* 2016; **11**: 343-347 [PMID: 27695534 DOI: 10.4103/1793-5482.180904]
- 2 Schirmer CM, Heilman CB, Bhardwaj A. Pneumocephalus: case illustrations and review. *Neurocrit Care* 2010; **13**: 152-158 [PMID: 20405340 DOI: 10.1007/s12028-010-9363-0]
- 3 Ishiwata Y, Fujitsu K, Sekino T, Fujino H, Kubokura T, Tsubone K, Kuwabara T. Subdural tension pneumocephalus following surgery for chronic subdural hematoma. *J Neurosurg* 1988; **68**: 58-61 [PMID: 3335913 DOI: 10.3171/jns.1988.68.1.0058]
- 4 Harvey JJ, Harvey SC, Belli A. Tension pneumocephalus: the neurosurgical emergency equivalent of tension pneumothorax. *BJR Case Rep* 2016; **2**: 20150127 [PMID: 30363668 DOI: 10.1259/bjrcr.20150127]
- 5 Dabdoub CB, Salas G, Silveira Edo N, Dabdoub CF. Review of the management of pneumocephalus. *Surg Neurol Int* 2015; **6**: 155 [PMID: 26500801 DOI: 10.4103/2152-7806.166195]
- 6 Ozawa H, Kokubun S, Aizawa T, Hoshikawa T, Kawahara C. Spinal dumbbell tumors: an analysis of a series of 118 cases. *J Neurosurg Spine* 2007; **7**: 587-93 [DOI: 10.3171/spi-07/12/587]
- 7 Hirano K, Imagama S, Sato K, Kato F, Yukawa Y, Yoshihara H, Kamiya M, Deguchi M, Kanemura T, Matsubara Y, Inoh H, Kawakami N, Takatsu T, Ito Z, Wakao N, Ando K, Tauchi R, Muramoto A, Matsuyama Y, Ishiguro N. Primary spinal cord tumors: review of 678 surgically treated patients in Japan. A multicenter study. *Eur Spine J* 2012; **21**: 2019-2026 [PMID: 22581192 DOI: 10.1007/s00586-012-2345-5]
- 8 Li Y, Wang B, Li L, Lü G. Posterior surgery *versus* combined laminectomy and thoracoscopic surgery for treatment of dumbbell-type thoracic cord tumor: A long-term follow-up. *Clin Neurol Neurosurg* 2018; **166**: 31-35 [PMID: 29408769 DOI: 10.1016/j.clineuro.2018.01.019]
- 9 Ando K, Imagama S, Ito Z, Tauchi R, Muramoto A, Matsui H, Matsumoto T, Ishiguro N. Removal of

- thoracic dumbbell tumors through a single-stage posterior approach: its usefulness and limitations. *J Orthop Sci* 2013; **18**: 380-387 [PMID: [23512015](#) DOI: [10.1007/s00776-013-0370-9](#)]
- 10 **Chen X**, Ma Q, Wang S, Zhang H, Huang D. Surgical treatment of posterior mediastinal neurogenic tumors. *J Surg Oncol* 2019; **119**: 807-813 [PMID: [30653663](#) DOI: [10.1002/jso.25381](#)]
- 11 **Trujillo-Reyes JC**, Rami-Porta R, Navarro AK, Belda-Sanchis J. Tension pneumocephalus: a rare complication after resection of a neurogenic tumour by thoracoscopic surgery. *Eur J Cardiothorac Surg* 2014; **46**: 145 [PMID: [24174217](#) DOI: [10.1093/ejcts/ezt522](#)]
- 12 **Huang YK**, Lu MS, Liu YH, Wu YC, Liu HP. Pneumocephalus after thoracoscopic excision of posterior mediastinal tumor. *J Formos Med Assoc* 2005; **104**: 848-851 [PMID: [16496066](#)]
- 13 **Dandy WE**. Pneumocephalus (intracranial pneumatocele or aerocele). *Archives of Surgery* 1926; **12**: 949-82 [DOI: [10.1001/archsurg.1926.01130050003001](#)]
- 14 **HOROWITZ M**. INTRACRANIAL PNEUMOCOELE. AN UNUSUAL COMPLICATION FOLLOWING MASTOID SURGERY. *J Laryngol Otol* 1964; **78**: 128-134 [PMID: [14126276](#) DOI: [10.1017/s0022215100061910](#)]
- 15 **Barber SM**, Fridley JS, Konakondla S, Nakhla J, Oyelese AA, Telfeian AE, Gokaslan ZL. Cerebrospinal fluid leaks after spine tumor resection: avoidance, recognition and management. *Ann Transl Med* 2019; **7**: 217 [PMID: [31297382](#) DOI: [10.21037/atm.2019.01.04](#)]
- 16 **Dafford EE**, Anderson PA. Comparison of dural repair techniques. *Spine J* 2015; **15**: 1099-1105 [PMID: [23973097](#) DOI: [10.1016/j.spinee.2013.06.044](#)]
- 17 **Epstein NE**. A review article on the diagnosis and treatment of cerebrospinal fluid fistulas and dural tears occurring during spinal surgery. *Surg Neurol Int* 2013; **4**: S301-S317 [PMID: [24163783](#) DOI: [10.4103/2152-7806.111427](#)]
- 18 **Beier AD**, Barrett RJ, Soo TM. Aneurysm clips for durotomy repair: technical note. *Oper Neurosurg (Hagerstown)* 2010; **66**: E124-E125 [PMID: [20173581](#) DOI: [10.1227/01.NEU.0000365423.19998.3D](#)]
- 19 **Faulkner ND**, Finn MA, Anderson PA. Hydrostatic comparison of nonpenetrating titanium clips vs conventional suture for repair of spinal durotomies. *Spine (Phila Pa 1976)* 2012; **37**: E535-9 [DOI: [10.1097/brs.0b013e31824cf756](#)]



Published by **Baishideng Publishing Group Inc**
7041 Koll Center Parkway, Suite 160, Pleasanton, CA 94566, USA

Telephone: +1-925-3991568

E-mail: bpgoffice@wjgnet.com

Help Desk: <https://www.f6publishing.com/helpdesk>

<https://www.wjgnet.com>

