

World Journal of *Clinical Cases*

World J Clin Cases 2022 March 26; 10(9): 2660-2975



Contents

Thrice Monthly Volume 10 Number 9 March 26, 2022

REVIEW

- 2660 Role of metabolites derived from gut microbiota in inflammatory bowel disease
Zheng L, Wen XL, Duan SL

MINIREVIEWS

- 2678 Roles of Wnt/ β -catenin signaling pathway related microRNAs in esophageal cancer
Chu CY, Wang R, Liu XL
- 2687 Animal models applied to acute-on-chronic liver failure: Are new models required to understand the human condition?
Gama JFG, Cardoso LMDF, Lagrota-Candido JM, Alves LA

ORIGINAL ARTICLE

Case Control Study

- 2700 Associations between coagulation factor XII, coagulation factor XI, and stability of venous thromboembolism: A case-control study
Meng Y, Li Y, Ye YJ, Ma Q, Zhang JB, Qin H, Deng YY, Tian HY

Retrospective Cohort Study

- 2710 Nomogram to predict the risk of endoscopic removal failure with forceps/baskets for treating submandibular stones
Huang Y, Liang PS, Yang YC, Cai WX, Tao Q
- 2721 Association between anesthesia technique and complications after hip surgery in the elderly population
Guo LS, Wang LN, Xiao JB, Zhong M, Zhao GF

Retrospective Study

- 2733 Perforating and nonperforating indications in repeated surgeries for Crohn's disease
Shen WS, Huang XH, Liu RQ, Li CY, Li Y, Zhu WM
- 2743 Treatment of *Pneumocystis jirovecii* pneumonia in non-human immunodeficiency virus-infected patients using a combination of trimethoprim-sulfamethoxazole and caspofungin
Wu HH, Fang SY, Chen YX, Feng LF
- 2751 Acute kidney injury in traumatic brain injury intensive care unit patients
Huang ZY, Liu Y, Huang HF, Huang SH, Wang JX, Tian JF, Zeng WX, Lv RG, Jiang S, Gao JL, Gao Y, Yu XX
- 2764 Enucleation combined with guided bone regeneration in small and medium-sized odontogenic jaw cysts
Cao YT, Gu QH, Wang YW, Jiang Q

Clinical Trials Study

- 2773 Determination of the ED₉₅ of intranasal sufentanil combined with intranasal dexmedetomidine for moderate sedation during endoscopic ultrasonography

Zou Y, Li N, Shao LJZ, Liu FK, Xue FS, Tao X

Observational Study

- 2783 Overexpression of Ubiquilin4 is associated with poor prognosis in patients with cervical cancer

Wang LN, Huang KJ, Wang L, Cheng HY

Randomized Clinical Trial

- 2792 Peplau's interpersonal relationship theory combined with bladder function training on patients with prostate cancer

Yang XH, Wu LF, Yan XY, Zhou Y, Liu X

SYSTEMATIC REVIEWS

- 2801 Efficacy of bone grafts in jaw cystic lesions: A systematic review

Wang J, Yao QY, Zhu HY

CASE REPORT

- 2811 Short stature associated with a novel mutation in the aggrecan gene: A case report and literature review

Yin LP, Zheng HX, Zhu H

- 2818 Treatment with sorafenib plus camrelizumab after splenectomy for primary splenic angiosarcoma with liver metastasis: A case report and literature review

Pan D, Li TP, Xiong JH, Wang SB, Chen YX, Li JF, Xiao Q

- 2829 Sarcomatoid intrahepatic cholangiocarcinoma with good patient prognosis after treatment with Huaier granules following hepatectomy: A case report

Feng JY, Li XP, Wu ZY, Ying LP, Xin C, Dai ZZ, Shen Y, Wu YF

- 2836 Sequential occurrence of T790M mutation and small cell lung cancer transformation in EGFR-positive lung adenocarcinoma: A case report

Hong E, Chen XE, Mao J, Zhou JJ, Chen L, Xu JY, Tao W

- 2844 Early diagnosis of Gitelman syndrome in a young child: A case report

Wu CY, Tsai MH, Chen CC, Kao CH

- 2851 Congenital intestinal malrotation with gastric wall defects causing extensive gut necrosis and short gut syndrome: A case report

Wang Y, Gu Y, Ma D, Guo WX, Zhang YF

- 2858 Delusional parasitosis as premotor symptom of parkinson's disease: A case report

Oh M, Kim JW, Lee SM

- 2864** Laninamivir-induced ischemic enterocolitis: A case report
Suzuki C, Kenzaka T
- 2871** Intramural pregnancy after *in vitro* fertilization and embryo transfer: A case report
Xie QJ, Li X, Ni DY, Ji H, Zhao C, Ling XF
- 2878** Bilateral ureteral reimplantation in a patient with an intraperitoneal ectopic bipenis: A case report
Jia YT, Shi BL, Zhang J, Li YY, Zhu J
- 2883** Lumbar disc sequestration mimicking a tumor: Report of four cases and a literature review
Li ST, Zhang T, Shi XW, Liu H, Yang CW, Zhen P, Li SK
- 2895** Parasitic leiomyoma in the trocar site after laparoscopic myomectomy: A case report
Roh CK, Kwon HJ, Jung MJ
- 2901** Giant nontraumatic myositis ossificans in a child: A case report
Xia AN, Wang JS
- 2908** Paradoxical carbon dioxide embolism during laparoscopic hepatectomy without intracardiac shunt: A case report
Jeon S, Hong JM, Lee HJ, Kim Y, Kang H, Hwang BY, Lee D, Jung YH
- 2916** Local hyperthermia combined with chemotherapy for the treatment of multiple recurrences of *undifferentiated pleomorphic sarcoma*: A case report
Zhou YT, Wang RY, Zhang Y, Li DY, Yu J
- 2923** Acute coronary artery stent thrombosis caused by a spasm: A case report
Meng LP, Wang P, Peng F
- 2931** Turner syndrome with primary myelofibrosis, cirrhosis and ovarian cystic mass: A case report
Xu LW, Su YZ, Tao HF
- 2938** Esophageal myoepithelial carcinoma: Four case reports
Lu H, Zhao HP, Liu YY, Yu J, Wang R, Gao JB
- 2948** Ipsilateral hemifacial microsomia with dextrocardia and pulmonary hypoplasia: A case report
Guo R, Chang SH, Wang BQ, Zhang QG
- 2954** Upper gastrointestinal bleeding from a Mallory-Weiss tear associated with transesophageal echocardiography during successful cardiopulmonary resuscitation: A case report
Tang MM, Fang DF, Liu B
- 2961** Malignant struma ovarii with papillary carcinoma combined with retroperitoneal lymph node metastasis: A case report
Xiao W, Zhou JR, Chen D

- 2969** Occult colon cancer with sepsis as the primary manifestation identified by bone marrow puncture: A case report

Wang HJ, Zhou CJ

ABOUT COVER

Editorial Board Member of *World Journal of Clinical Cases*, Arunchai Chang, MD, Assistant Professor, Lecturer, Staff Physician, Division of Gastroenterology, Department of Internal Medicine, Hatyai Hospital, Hatyai 90110, Songkhla, Thailand. busmdcu58@gmail.com

AIMS AND SCOPE

The primary aim of *World Journal of Clinical Cases* (WJCC, *World J Clin Cases*) is to provide scholars and readers from various fields of clinical medicine with a platform to publish high-quality clinical research articles and communicate their research findings online.

WJCC mainly publishes articles reporting research results and findings obtained in the field of clinical medicine and covering a wide range of topics, including case control studies, retrospective cohort studies, retrospective studies, clinical trials studies, observational studies, prospective studies, randomized controlled trials, randomized clinical trials, systematic reviews, meta-analysis, and case reports.

INDEXING/ABSTRACTING

The WJCC is now indexed in Science Citation Index Expanded (also known as SciSearch®), Journal Citation Reports/Science Edition, Scopus, PubMed, and PubMed Central. The 2021 Edition of Journal Citation Reports® cites the 2020 impact factor (IF) for WJCC as 1.337; IF without journal self cites: 1.301; 5-year IF: 1.742; Journal Citation Indicator: 0.33; Ranking: 119 among 169 journals in medicine, general and internal; and Quartile category: Q3. The WJCC's CiteScore for 2020 is 0.8 and Scopus CiteScore rank 2020: General Medicine is 493/793.

RESPONSIBLE EDITORS FOR THIS ISSUE

Production Editor: *Ying-Yi Yuan*, Production Department Director: *Xiang Li*, Editorial Office Director: *Jin-Lei Wang*.

NAME OF JOURNAL

World Journal of Clinical Cases

ISSN

ISSN 2307-8960 (online)

LAUNCH DATE

April 16, 2013

FREQUENCY

Thrice Monthly

EDITORS-IN-CHIEF

Bao-Gan Peng, Jerzy Tadeusz Chudek, George Kontogeorgos, Maurizio Serati, Ja Hyeon Ku

EDITORIAL BOARD MEMBERS

<https://www.wjgnet.com/2307-8960/editorialboard.htm>

PUBLICATION DATE

March 26, 2022

COPYRIGHT

© 2022 Baishideng Publishing Group Inc

INSTRUCTIONS TO AUTHORS

<https://www.wjgnet.com/bpg/gerinfo/204>

GUIDELINES FOR ETHICS DOCUMENTS

<https://www.wjgnet.com/bpg/GerInfo/287>

GUIDELINES FOR NON-NATIVE SPEAKERS OF ENGLISH

<https://www.wjgnet.com/bpg/gerinfo/240>

PUBLICATION ETHICS

<https://www.wjgnet.com/bpg/GerInfo/288>

PUBLICATION MISCONDUCT

<https://www.wjgnet.com/bpg/gerinfo/208>

ARTICLE PROCESSING CHARGE

<https://www.wjgnet.com/bpg/gerinfo/242>

STEPS FOR SUBMITTING MANUSCRIPTS

<https://www.wjgnet.com/bpg/GerInfo/239>

ONLINE SUBMISSION

<https://www.f6publishing.com>



Retrospective Cohort Study

Nomogram to predict the risk of endoscopic removal failure with forceps/baskets for treating submandibular stones

Yun Huang, Pei-Sheng Liang, Yao-Cheng Yang, Wei-Xin Cai, Qian Tao

Specialty type: Dentistry, oral surgery and medicine

Provenance and peer review:

Unsolicited article; Externally peer reviewed.

Peer-review model: Single blind

Peer-review report's scientific quality classification

Grade A (Excellent): 0
Grade B (Very good): B, B
Grade C (Good): 0
Grade D (Fair): 0
Grade E (Poor): 0

P-Reviewer: Aoun G, Dawasaz AA

Received: August 24, 2021

Peer-review started: August 24, 2021

First decision: November 17, 2021

Revised: November 26, 2021

Accepted: February 12, 2022

Article in press: February 12, 2022

Published online: March 26, 2022



Yun Huang, Pei-Sheng Liang, Yao-Cheng Yang, Wei-Xin Cai, Qian Tao, Department of Oral and Maxillofacial Surgery, Hospital of Stomatology, Guanghua School of Stomatology, Sun Yat-Sen University, Guangzhou 510055, Guangdong Province, China

Yun Huang, Pei-Sheng Liang, Yao-Cheng Yang, Wei-Xin Cai, Qian Tao, Department of Oral and Maxillofacial Surgery, Guangdong Provincial Key Laboratory of Stomatology, Guangzhou 510055, Guangdong Province, China

Corresponding author: Qian Tao, MD, PhD, Chief Doctor, Professor, Department of Oral and Maxillofacial Surgery, Hospital of Stomatology, Guanghua School of Stomatology, Sun Yat-Sen University, No. 56 Lingyuanxi Road, Guangzhou 510055, Guangdong Province, China. taoqian@mail.sysu.edu.cn

Abstract

BACKGROUND

Endoscopic removal with forceps/baskets is favored in treating submandibular stones due to its minimal invasiveness. However, recent studies have found that endoscopic removal failure (ERF) is not unusual, and stones in such cases still need to be removed with other surgical methods. If the risk of ERF can be predicted preoperatively, it could be helpful for surgeons when choosing the appropriate therapy.

AIM

To develop a predictive nomogram for the risk of ERF when treating submandibular stones based on their preoperative clinical features.

METHODS

A total of 180 patients with 211 submandibular stones treated from January 2012 to December 2020 were included in the current study. Based on the preoperative clinical features of the stones, independent risk factors for ERF were identified by logistic regression analysis. The stones were then randomly divided into training and testing sets. A nomogram was constructed to predict the risk of ERF using the training set and then validated using both sets. The predictive performance of the nomogram was assessed by calibration curves and the concordance index (C-index).

RESULTS

Three independent predictors, location ($P = 0.040$), transverse diameter ($P < 0.001$)

and longitudinal diameter ($P < 0.001$) measured on the cone beam computed tomography (CBCT) images of the submandibular stones, were identified and included in the predictive nomogram. Calibration curves of the nomogram showed good agreement between the predicted and observed probabilities in both sets. The C-index in the training set was 0.917 (95%CI, 0.875-0.959) and that in the testing set was 0.925 (95%CI, 0.862-0.989).

CONCLUSION

A nomogram based on the location, transverse and longitudinal diameters on CBCT images of submandibular stones showed satisfactory efficacy in predicting the risk of ERF preoperatively when treating submandibular stones.

Key Words: Endoscopic removal failure; Submandibular stones; Cone beam computed tomography; Location; Diameter; Nomogram

©The Author(s) 2022. Published by Baishideng Publishing Group Inc. All rights reserved.

Core Tip: A predictive nomogram based on the objective and measurable preoperative clinical features of submandibular stones was constructed in the present study; the nomogram helps to determine the risk of endoscopic removal failure preoperatively and aids in the selection of appropriate surgical methods.

Citation: Huang Y, Liang PS, Yang YC, Cai WX, Tao Q. Nomogram to predict the risk of endoscopic removal failure with forceps/baskets for treating submandibular stones. *World J Clin Cases* 2022; 10(9): 2710-2720

URL: <https://www.wjgnet.com/2307-8960/full/v10/i9/2710.htm>

DOI: <https://dx.doi.org/10.12998/wjcc.v10.i9.2710>

INTRODUCTION

Endoscopic stone removal, in which stones are removed with forceps/baskets during endoscopy, plays an important role in treating salivary lithiasis[1-5]. For most surgeons and patients, endoscopic stone removal is favored because of its high visibility and minimal invasiveness. However, studies in recent years have found that many submandibular stones fail to be removed by the forceps/baskets under endoscopy, which means endoscopic removal failure (ERF) in treating submandibular stones is not unusual[6-8]. Fruitless attempts to repeatedly perform endoscopic removal with forceps/baskets will greatly prolong the operation time and increase the risk of severe postoperative complications, such as ductal avulsion and perforation[5,9]. Therefore, the clinical features of the stones should be carefully considered when selecting endoscopic removal, which has pros and cons[2,3,10]. Currently, however, a broad consensus has not been reached regarding the indications of endoscopic removal for submandibular stones, leading to improper surgical choice in some cases[7,8].

Therefore, in this study, we aimed to identify the risk factors for ERF and construct and validate a predictive nomogram, a useful statistical tool, to identify the risk of ERF preoperatively when treating submandibular stones and to aid in clinical therapeutic decision making.

MATERIALS AND METHODS

Patients

This retrospective study enrolled patients with submandibular stones treated at the Hospital of Stomatology, Sun Yat-Sen University, from January 2012 to December 2020. The inclusion criteria were as follows: (1) availability of complete clinical information and CBCT images; (2) attempted stone localization by introducing an endoscope through the ductal orifice and removal with forceps or baskets under the endoscope; and (3) satisfactory surgical outcomes without residual stones. The detailed exclusion criteria and data screening process are shown in [Figure 1](#).

Ethics

The study was approved by the Medical Ethics Committee of Hospital of Stomatology, Sun Yat-Sen University (No. KQEC-2019-41) and was performed in accordance with the Declaration of Helsinki in regard to medical protocols and ethics.

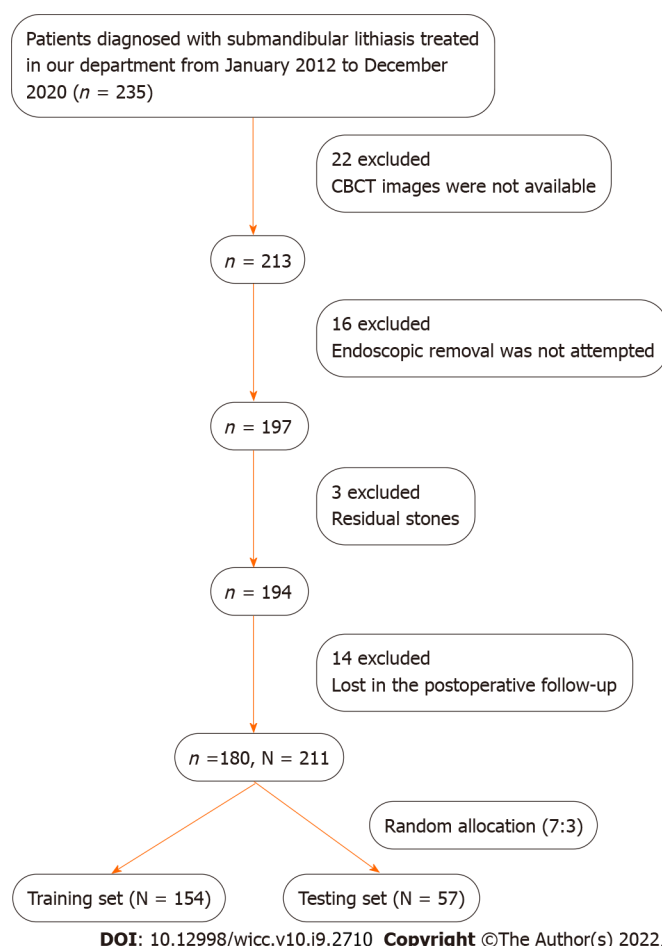


Figure 1 Study flowchart. A total of 180 patients with 211 submandibular stones were finally enrolled in this study and then randomly separated into training and testing sets at a ratio of 7:3. N: Number of stones; n: Number of patients; CBCT: Cone beam computed tomography.

Data acquisition

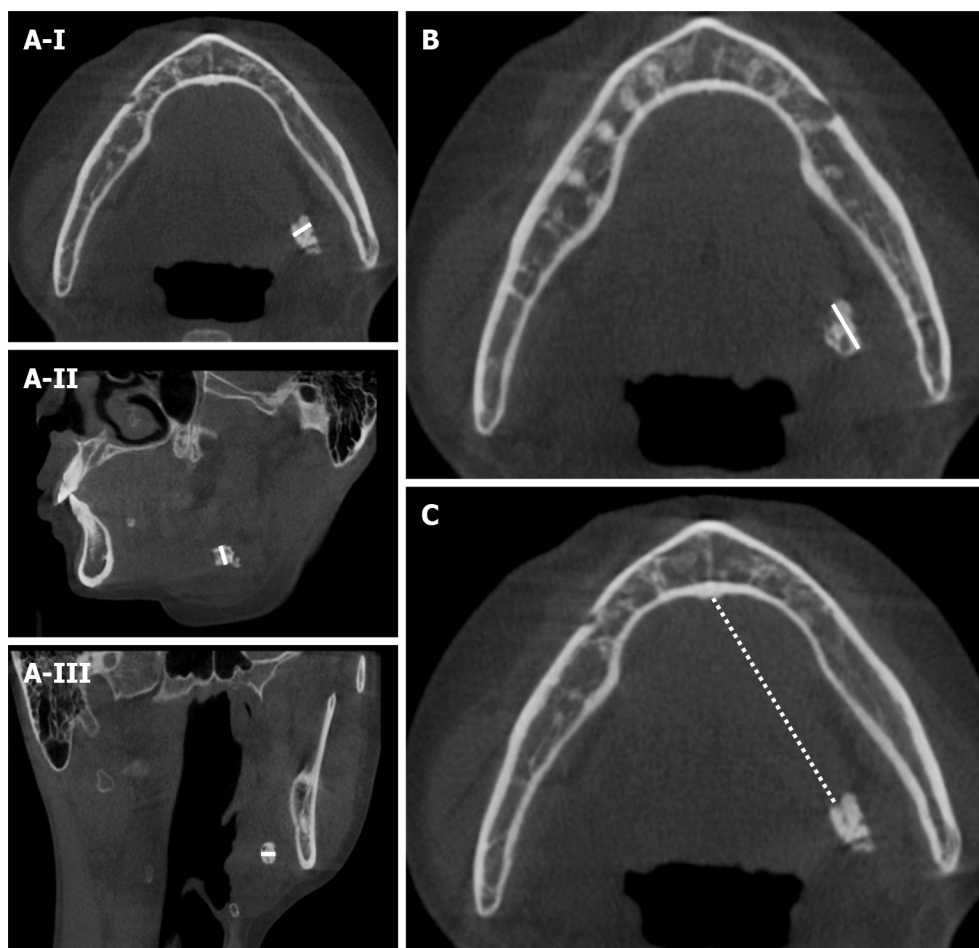
Clinical data, including sex, age, intraductal stone treatment history, involved sides, number of stones in the same gland, palpation, CBCT images (New Tom Inc., Italy), and results of endoscopic removal were collected for the patients who met the criteria. The average location, transverse diameter (TD) and longitudinal diameter (LD) of all the stones on CBCT images were recorded after evaluation by 3 blinded experienced surgeons. As demonstrated in Figure 2, the location of the stone was defined as the distance between its anterior edge and the midpoint of the glossal bony cortex of the mandible in axial CBCT views. The TD of the stone was defined as the maximum width on its axial, coronal and sagittal sections. The LD of the stone was defined as its maximum length on the axial CBCT views. We attempted to remove all of the stones included in our study with forceps or baskets after locating them with an endoscope (Karl Storz Inc., Germany), as shown in Figure 3. All endoscopic removals were performed by the same three experienced surgeons (Q.T., G.L., and H.L.).

Statistical analysis

Statistical analyses were performed with SPSS 25.0 software (SPSS Inc., Chicago), and the statistical methods of this study were reviewed by Zhi-Wei Li from the Department of Medical Statistics and Epidemiology, Sun Yat-Sen University.

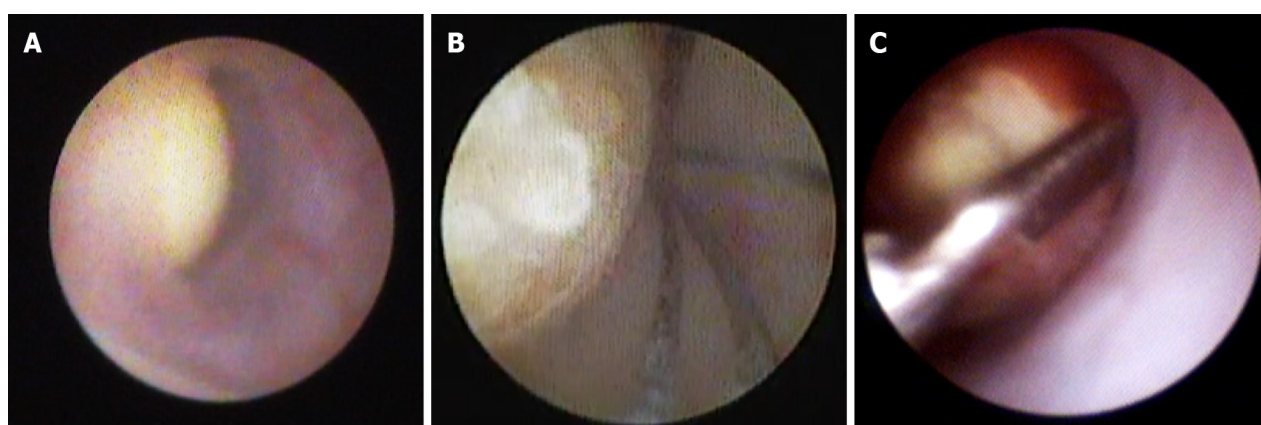
Receiver operating characteristic (ROC) curve analysis was performed, and Youden's index was calculated to determine the optimal cutoff points for the location, TD and LD of the stones. According to the new classification criteria of the World Health Organization, 44 years was considered the cutoff value for age.

Pearson's chi-squared test was used to explore the correlations between the clinical variables of the stones and ERF. Next, univariate and multivariate logistic regression analyses were used to identify the independent risk factors. Then, ROC curve analysis was carried out, and the area under the curve (AUC) was calculated to assess the predictive performance of the univariate and multivariate combined models. For the model with the best predictive performance, Youden's index was calculated to determine the optimal cutoff value, and the accuracy, sensitivity, specificity, positive predictive value (PPV) and negative predictive value (NPV) were calculated to evaluate the model.



DOI: 10.12998/wjcc.v10.i9.2710 Copyright ©The Author(s) 2022.

Figure 2 Measurements of the location, transverse diameter and longitudinal diameter of submandibular stones. A-I: Measures the width of stones in the axial cone beam computed tomography (CBCT) views (white line); A-II: Measures the width of stones in the sagittal CBCT views (white line); A-III: Measures the width of stones in the coronal CBCT views (white line); B: Measures the longitudinal diameter of stones in the axial CBCT views (white line); C: Measures the distance between the anterior edge of the stone and the midpoint of the glossal cortex of the mandible in the axial CBCT views, which was defined as the location of the stone (white dotted line).



DOI: 10.12998/wjcc.v10.i9.2710 Copyright ©The Author(s) 2022.

Figure 3 Endoscopic removal of submandibular stones. A: It was captured while locating the stones under an endoscope; B: It was captured while attempting to grasp the stone with a stone basket; C: It was captured while attempting to grasp the stone with forceps.

Establishment and validation of the nomogram

All stones were randomly divided into the training and testing sets at a ratio of 7:3 using an R-generated random number (random seeds of 123). With the 'rms' package in R software (version 4.0.3) and based on the training set, a nomogram was constructed using the independent factors from the best model

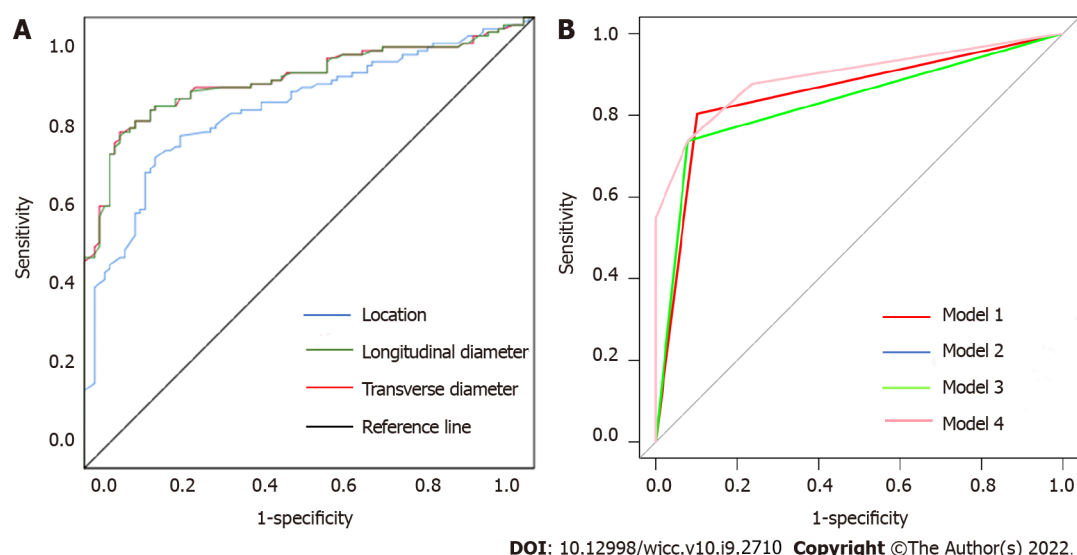


Figure 4 Receiver operating characteristic curve analysis. A: To determine the optimal cutoff points for the location, transverse diameter (TD) and longitudinal diameter (LD) of the stones; B: To compare the predictive performance of the univariate and multivariate combined models. In B, the univariate model of TD, LD and location correspond to models 1, 2 and 3, respectively. Model 2 and model 3 are so close that it is difficult to distinguish them graphically. The multivariate combined model corresponds to model 4.

above to identify the risk of ERF. The predictive performance of the nomogram was evaluated by calibration curves and the C-index.

RESULTS

Clinical features of the enrolled patients and stones

A total of 180 patients with 211 stones who underwent endoscopic removal attempts were finally included in further analyses; 100 of the patients were female. The average age of the patients was 41.4 ± 13.5 years old (17-75 years old).

Thirty-four stones were confirmed to have an intraductal stone treatment history, such as intraductal irrigation and intraductal dilatation, which might result in ductal stenosis after the treatment. A total of 52.6% of the stones involved the glands on the right side. Thirty-one stones were found to be multiple, and 77 were unpalpable. The average location, TD and LD of the stones were 3.48 ± 1.51 cm, 5.17 ± 2.01 mm and 4.97 ± 1.48 mm, respectively. Endoscopic removal was successful in 89 cases but failed in 122 attempts. The preoperative clinical variables of all the enrolled stones are shown in Table 1.

Correlations between clinical features of the stones and ERF

The optimal cutoff points for the location, TD and LD were 3.76 cm, 4.97 mm and 5.14 mm, respectively, as demonstrated in Figure 4A and Table 2. These three factors, together with the age of patients, were then used to divide patients into subgroups according to the cutoff values in further statistical analysis. Correlations between the clinical features of the stones and ERF are shown in Table 3; palpation ($P < 0.001$), location ($P < 0.001$), TD ($P < 0.001$) and LD ($P < 0.001$) were significantly associated with ERF.

Identification of the independent risk factors and predictive performance comparison

As demonstrated in Table 4, three independent risk factors were identified by univariate and multivariate logistic regression analyses, including the location (OR = 8.796, 95%CI, 3.673-22.661, $P = 0.040$), TD (OR = 10.287, 95%CI, 3.301-35.269, $P < 0.001$) and LD (OR = 4.412, 95%CI, 1.256-15.575, $P < 0.001$) of the stones.

Comparisons of the predictive performance of the univariate models and multivariate combined model are shown in Figure 4B. The multivariate combined model, based on the three independent risk factors, had the best predictive performance with an AUC of 0.920, accuracy of 84.8%, sensitivity of 77.9%, specificity of 94.3%, PPV of 95.0% and NPV of 75.7%.

Construction and validation of the predictive nomogram

A total of 154 stones were selected randomly for the training set, while the remaining 57 were included in the testing set. Based on the data from the training set, the location, TD and LD of the stones were incorporated when constructing the nomogram model for predicting the risk of ERF, as shown in Figure 5. Calibration curves of the nomogram are shown in Figure 6; good agreement was found

Table 1 Clinical features of the enrolled stones

Variables		
Sex		
Male		99 (46.9%)
Female		112 (53.1%)
Age of the patient		
< 44 yr		123 (58.3%)
≥ 44 yr		88 (41.7%)
Intraductal stone treatment history		
Yes		34 (16.1%)
No		177 (83.9%)
Involved side		
Left		100 (47.4%)
Right		111 (52.6%)
Amounts of stones		
Single		180 (85.3%)
Multiple		31 (14.7%)
Palpation		
Positive		134 (63.6%)
Negative		77 (36.4%)
Location/cm		
Range		0.42-5.69
Mean		3.48 ± 1.51
TD/mm		
Range		1.23-12.00
Mean		5.17 ± 2.01
LD/mm		
Range		0.57-9.26
Mean		4.97 ± 1.48
Surgical methods		
Endoscopic removal		89 (42.2%)
ERF		122 (57.8%)

TD: Transverse diameter; LD: Longitudinal diameter; ERF: Endoscopic removal failure.

between the predicted and observed probabilities in both sets. The C-index of the model in the training set was 0.917 (95%CI, 0.875-0.959), and that in the testing set was 0.925 (95%CI, 0.862-0.989).

DISCUSSION

At present, the preservation of glandular functions and minimal invasiveness have become the focuses of treating submandibular stones[8,11,12]. Endoscopic stone removal with forceps/baskets has allowed the incision-free treatment of submandibular stones and has been favored due to its ability to be directly visualized endoscopically and its minimally invasive nature. The procedure not only avoids the need for an incision but also helps with stone positioning, ductal expansion, plug removal, and tiny stone clearance. However, studies in recent years have found that endoscopic removal with forceps/baskets failed to achieve satisfactory therapeutic effects in some cases of submandibular stones[10,13]. It has

Table 2 Cutoff values for the location, transverse and longitudinal diameter of the enrolled stones

Variables	Cutoff	Youden's index	Sensitivity	Specificity
Location/cm	3.76	0.581	0.719	0.862
TD/mm	4.97	0.675	0.787	0.877
LD/mm	5.14	0.638	0.730	0.908

TD: Transverse diameter; LD: Longitudinal diameter; ERF: Endoscopic removal failure.

Table 3 Results of Pearson's chi-square test

Variables		Endoscopic removal	ERF	χ^2	P value
Sex	Male	42	57	0.005	0.946
	Female	47	65		
Age of the patient	< 44	54	69	0.359	0.549
	≥ 44	35	53		
Intraductal stone treatment history	Yes	12	22	0.788	0.244
	No	77	100		
Involved side	Left	43	57	0.052	0.819
	Right	46	65		
Amounts of stones	Single	74	106	0.005	0.945
	Multiple	15	16		
Palpation	Positive	38	96	28.764	< 0.001 ^a
	Negative	51	26		
Location	< 3.76 cm	75	38	58.382	< 0.001 ^a
	≥ 3.76 cm	14	84		
TD	< 4.97 mm	76	28	80.274	< 0.001 ^a
	≥ 4.97 mm	13	94		
LD	< 5.14 mm	82	32	34.586	< 0.001 ^a
	≥ 5.14 mm	7	90		

^aP < 0.05. ERF: Endoscopic removal failure; TD: Transverse diameter; LD: Longitudinal diameter; CI: Confidence interval.

been reported that the procedure might have limitations when removing the submandibular stones in the following cases[2,6,14,15]: (1) Posteriorly located stones; (2) very large stones; (3) irregular stones and (4) stones trapped by ductal stenosis. After repeatedly fruitless attempts at endoscopic removal, such submandibular stones still need to be removed with other surgical methods, such as transoral incision and even gland excision[7,8,16]. Under these circumstances, repeated fruitless attempts with endoscopy and forceps/baskets will greatly prolong the operation time and increase the risk of ductal perforation, resulting in severe swelling of the submaxillary area and even postoperative airway obstruction.

If the risk of ERF can be predicted before the surgery, unsuccessful endoscopic removal can be avoided to a large extent, and the patients will be able to truly benefit from this minimally invasive procedure. Based on the clinical records of 211 stones at our institution, all preoperative factors that can fully and objectively reflect the clinical features of submandibular stones were collected. According to the results of Pearson's chi-squared test and univariate logistic regression analysis, the palpation, location, TD and LD of the stones were associated with the outcomes of endoscopic removal. Multivariate logistic regression analysis finally identified stone location, TD and LD on cone beam computed tomography images as independent risk factors for ERF.

The results of our study are consistent with those of previous studies[6,8,10,17]. Cox *et al*[18] pointed out that the location and size of the stones significantly affected the success rate of endoscopic removal for submandibular stones. Kondo *et al*[10] found that the success rate of endoscopic removal for anterior

Table 4 Results of univariate and multivariate logistic regression analyses

Variables	Univariate			Multivariate		
	Odds ratio	95%CI	P value	Odds ratio	95%CI	P value
Sex	1.288	0.745-2.228	0.366	-	-	-
Age of the patient	1.185	0.680-2.066	0.549	-	-	-
Intraductal stone treatment history	1.412	0.658-3.029	0.376	-	-	-
Involved side	1.066	0.617-1.842	0.819	-	-	-
Amounts of stones	1.026	0.496-2.123	0.945	-	-	-
Palpation	4.955	2.710-9.061	< 0.001 ^a	-	-	-
Location/cm	11.842	5.956-23.547	< 0.001 ^a	8.796	3.672-22.661	0.040 ^a
TD/mm	19.626	9.516-40.481	< 0.001 ^a	10.287	3.301-35.269	< 0.001 ^a
LD/mm	32.946	13.791-78.106	< 0.001 ^a	4.412	1.256-15.575	< 0.001 ^a

^aP < 0.05. TD: Transverse diameter; LD: Longitudinal diameter; CI: Confidence interval.

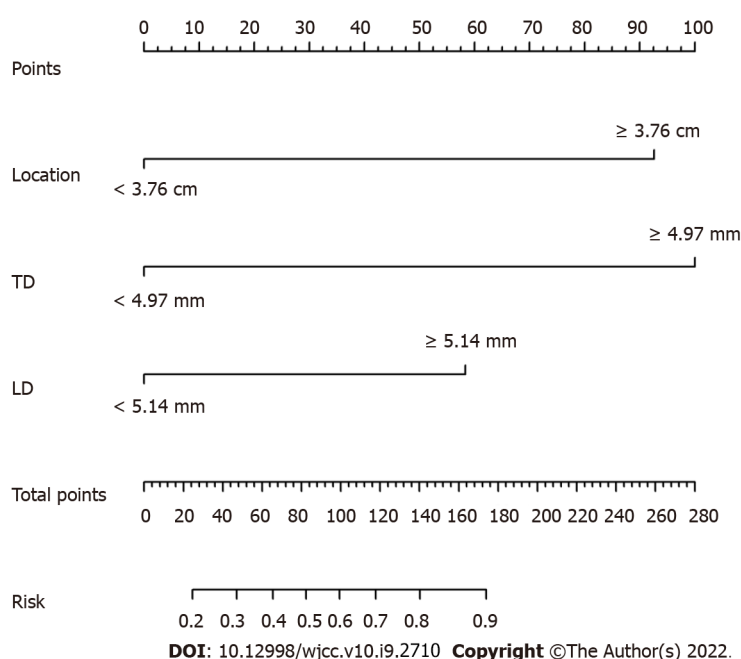


Figure 5 Predictive nomogram for the risk of endoscopic removal failure. Each factor was given a point, and the total points for an individual stone could be obtained by summing all points. The predictive risk of endoscopic removal failure was identified by the total points according to the scale at the bottom. TD: Transverse diameter; LD: Longitudinal diameter.

stones was higher than that for stones located in the posterior segment of the duct, and the transverse diameter of the stones was significantly correlated with successful endoscopic removal. Foletti *et al*[6] reported that submandibular stones located in the middle or posterior third of the duct with a transverse diameter less than 4 mm could be removed by forceps/baskets under endoscopy. Koch *et al* [17] believed that endoscopic removal could be adopted for anterior submandibular stones with transverse diameters less than 5 mm. Marchal *et al*[19] found that endoscopic removal could be selected when the transverse diameter of the stones was less than 3 mm. Fabie *et al*[8] believed that the benefits of applying other surgical methods to remove submandibular stones increased when the transverse diameter was greater than 6 mm. In the opinion of Walveka *et al*[15], the shapes and locations of the stones were the main factors that affected the success rate of endoscopic removal. However, previous studies have not proposed specific methods for measuring the preoperative location and size of submandibular stones and have not reached a broad consensus on the indications for endoscopic removal.

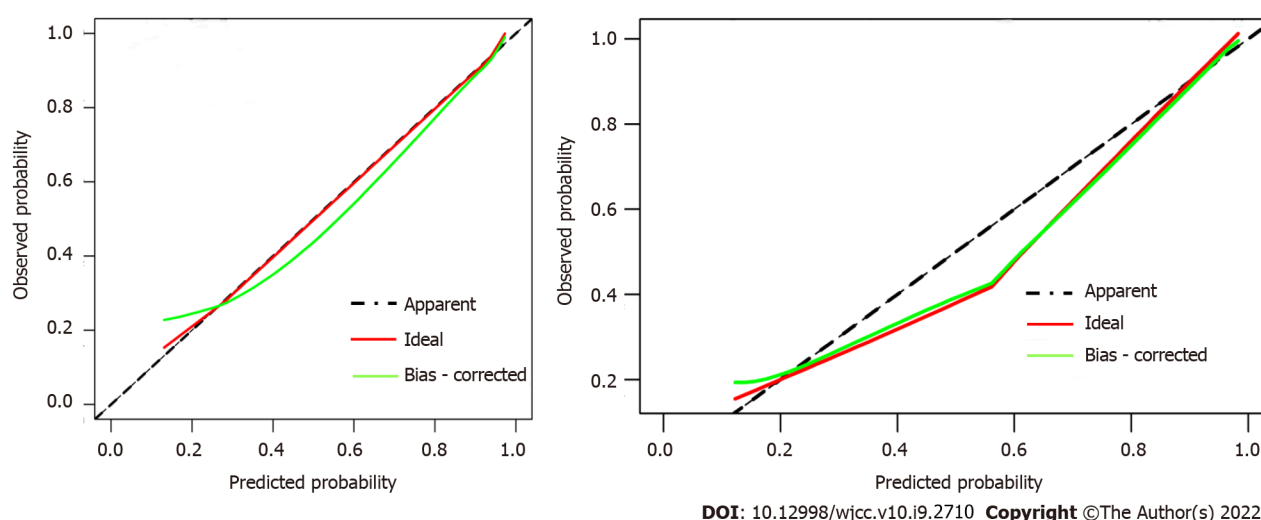


Figure 6 Calibration curves of the nomogram in both sets. They showed good agreement between the predicted (X-axis) and observed (Y-axis) probabilities. The dotted line represents the apparent match.

In contrast to previous studies, our current study first defined the specific methods for the preoperative measurement of stone location and size and used these measurable and objective independent risk factors to construct an effective nomogram for quantifying the indications for endoscopic stone removal. The midpoint of the glossal bony cortex of the mandible is regarded as the marker for measuring the stone location because it is close to the ductal orifice and can be clearly visualized on CBCT images. The distance between this point and the anterior edge of stones also represents the depth to which the endoscope and forceps/baskets should be lowered into the ductal system, providing guidance during the process of endoscopic removal.

Nevertheless, there are some limitations to our current study. Due to its retrospective nature, information bias may have been present during the data collection procedure. Additionally, this study was a single-center analysis, and a limited number of samples were included. It is essential to assess the nomogram at multiple institutes with a larger population. Moreover, our present model does not include anatomical variations of the Wharton duct, which can also affect the success rate of endoscopic removal but are difficult to inspect with preoperative examinations. Despite these disadvantages, this was the first study to construct a noninvasive predictive nomogram to predict ERF when treating submandibular stones preoperatively and that could serve as a reference for surgeons to personalize treatment plans for patients.

CONCLUSION

The location, transverse diameter and longitudinal diameter of submandibular stones on CBCT images are independent risk factors for ERF. A nomogram based on these three factors helps to predict the risk of ERF for submandibular stones.

ARTICLE HIGHLIGHTS

Research background

Recent studies have found that the favored minimally invasive endoscopic removal, in which clear stones with forceps/baskets, failed to remove submandibular stones in most cases.

Research motivation

To predict the risk of endoscopic removal failure (ERF) for submandibular stones based on their preoperative clinical features.

Research objectives

In the current study, we aimed to construct a predictive model to figure out the risk of ERF for treating submandibular stones before the surgery.

Research methods

The preoperative clinical data of submandibular stones attempted to be treated by endoscopic removal with forceps/baskets in our department from January 2012 to December 2020 were collected. Correlations between clinical variables of the stones and ERF were explored by Pearson's chi-squared test. Univariate and multivariate logistic regression analyses were then used to identify the independent risk factors of ERF. Finally, the nomogram based on the independent risk factors was constructed and validated to predict the risk of ERF for individual submandibular stone.

Research results

The palpation, location, transverse diameter and longitudinal diameter of submandibular stones were significantly associated with ERF. And the location, transverse diameter and longitudinal diameter of submandibular stones on cone beam computed tomography images were independent factors for ERF with forceps/baskets. A nomogram based on these three factors had satisfying predictive efficiency.

Research conclusions

A nomogram based on the location, transverse diameter and longitudinal diameter helps to predict the risk of ERF with forceps/baskets for submandibular stones.

Research perspectives

Feasible preoperative measurements of anatomical variations of the Wharton duct are needed to be included in the further study. Also, it is essential to assess the predictive nomogram at multiple institutes with a larger population.

ACKNOWLEDGEMENTS

We thank Zhi-Wei Li for his help in statistical analyses.

FOOTNOTES

Author contributions: Tao Q and Huang Y designed the study; Huang Y, Liang PS, Yang YC and Cai WX performed the research; Huang Y, Liang PS and Yang YC contributed the analytic tools; Huang Y, Liang PS and Yang YC analyzed the data and wrote the manuscript; all authors have read and approved the final manuscript.

Supported by Guangdong Basic and Applied Basic Research Foundation, No. 2019A1515012139.

Institutional review board statement: The study was approved by the Medical Ethics Committee of Hospital of Stomatology, Sun Yat-Sen University (No. KQEC-2019-41).

Informed consent statement: Informed consent was obtained from the patient for the publication of images.

Conflict-of-interest statement: The authors declare that they have no conflict of interest to report.

Data sharing statement: Statistical code and dataset are available from the corresponding author at taoqian@mail.sysu.edu.cn.

STROBE statement: All the authors have read the STROBE Statement—checklist of items, and the manuscript was prepared and revised according to the STROBE Statement—checklist of items.

Open-Access: This article is an open-access article that was selected by an in-house editor and fully peer-reviewed by external reviewers. It is distributed in accordance with the Creative Commons Attribution NonCommercial (CC BY-NC 4.0) license, which permits others to distribute, remix, adapt, build upon this work non-commercially, and license their derivative works on different terms, provided the original work is properly cited and the use is non-commercial. See: <https://creativecommons.org/licenses/by-nc/4.0/>

Country/Territory of origin: China

ORCID number: Yun Huang 0000-0003-3374-1019; Pei-Sheng Liang 0000-0002-1262-6516; Yao-Cheng Yang 0000-0001-7995-6301; Wei-Xin Cai 0000-0002-9859-7460; Qian Tao 0000-0001-8172-7954.

S-Editor: Liu JH

L-Editor: A

P-Editor: Liu JH

REFERENCES

- 1 **Nahlieli O**, Nakar LH, Nazarian Y, Turner MD. Sialoendoscopy: A new approach to salivary gland obstructive pathology. *J Am Dent Assoc* 2006; **137**: 1394-1400 [PMID: [17012718](#) DOI: [10.14219/jada.archive.2006.0051](#)]
- 2 **Walvekar RR**, Bomeli SR, Carrau RL, Schaitkin B. Combined approach technique for the management of large salivary stones. *Laryngoscope* 2009; **119**: 1125-1129 [PMID: [19358166](#) DOI: [10.1002/lary.20203](#)]
- 3 **Zenk J**, Koch M, Klintworth N, König B, Konz K, Gillespie MB, Iro H. Sialendoscopy in the diagnosis and treatment of sialolithiasis: a study on more than 1000 patients. *Otolaryngol Head Neck Surg* 2012; **147**: 858-863 [PMID: [22753615](#) DOI: [10.1177/0194599812452837](#)]
- 4 **Schwartz N**, Hazkani I, Goshen S. Combined approach sialendoscopy for management of submandibular gland sialolithiasis. *Am J Otolaryngol* 2015; **36**: 632-635 [PMID: [26052045](#) DOI: [10.1016/j.amjoto.2015.04.001](#)]
- 5 **Wolf G**, Langer C, Wittekindt C. [Sialolithiasis: Current Diagnostics and Therapy]. *Laryngorhinootologie* 2019; **98**: 815-823 [PMID: [31739357](#) DOI: [10.1055/a-0896-9572](#)]
- 6 **Foletti JM**, Graillon N, Avignon S, Guyot L, Chossegros C. Salivary Calculi Removal by Minimally Invasive Techniques: A Decision Tree Based on the Diameter of the Calculi and Their Position in the Excretory Duct. *J Oral Maxillofac Surg* 2018; **76**: 112-118 [PMID: [28683302](#) DOI: [10.1016/j.joms.2017.06.009](#)]
- 7 **Sigismund PE**, Zenk J, Koch M, Schapher M, Rudes M, Iro H. Nearly 3,000 salivary stones: some clinical and epidemiologic aspects. *Laryngoscope* 2015; **125**: 1879-1882 [PMID: [25994240](#) DOI: [10.1002/lary.25377](#)]
- 8 **Fabie JE**, Kompelli AR, Naylor TM, Nguyen SA, Lentsch EJ, Gillespie MB. Gland-preserving surgery for salivary stones and the utility of sialendoscopes. *Head Neck* 2019; **41**: 1320-1327 [PMID: [30549387](#) DOI: [10.1002/hed.25560](#)]
- 9 **Nahlieli O**. Complications of sialendoscopy: personal experience, literature analysis, and suggestions. *J Oral Maxillofac Surg* 2015; **73**: 75-80 [PMID: [25443381](#) DOI: [10.1016/j.joms.2014.07.028](#)]
- 10 **Kondo N**, Yoshihara T, Yamamura Y, Kusama K, Sakitani E, Seo Y, Tachikawa M, Kujirai K, Ono E, Maeda Y, Nojima T, Tamiya A, Sato E, Nonaka M. Treatment outcomes of sialendoscopy for submandibular gland sialolithiasis: The minor axis of the sialolith is a regulative factor for the removal of sialoliths in the hilum of the submandibular gland using sialendoscopy alone. *Auris Nasus Larynx* 2018; **45**: 772-776 [PMID: [28935124](#) DOI: [10.1016/j.anl.2017.09.003](#)]
- 11 **Harrison JD**. Causes, natural history, and incidence of salivary stones and obstructions. *Otolaryngol Clin North Am* 2009; **42**: 927-947, Table of Contents [PMID: [19962002](#) DOI: [10.1016/j.otc.2009.08.012](#)]
- 12 **Yoshimura Y**, Morishita T, Sugihara T. Salivary gland function after sialolithiasis: scintigraphic examination of submandibular glands with 99mTc-pertechnetate. *J Oral Maxillofac Surg* 1989; **47**: 704-10; discussion 710 [PMID: [2543802](#) DOI: [10.1016/s0278-2391\(89\)80009-6](#)]
- 13 **Walvekar RR**, Carrau RL, Schaitkin B. Endoscopic sialolith removal: orientation and shape as predictors of success. *Am J Otolaryngol* 2009; **30**: 153-156 [PMID: [19410118](#) DOI: [10.1016/j.amjoto.2008.03.007](#)]
- 14 **Singh PP**, Gupta V. Sialendoscopy: introduction, indications and technique. *Indian J Otolaryngol Head Neck Surg* 2014; **66**: 74-78 [PMID: [24605306](#) DOI: [10.1007/s12070-013-0675-1](#)]
- 15 **Kopeć T**, Wierzbicka M, Kałużny J, Młodkowska A, Szyfter W. Sialendoscopy and sialendoscopically-assisted operations in the treatment of lithiasis of the submandibular and parotid glands: our experience of 239 cases. *Br J Oral Maxillofac Surg* 2016; **54**: 767-771 [PMID: [27185233](#) DOI: [10.1016/j.bjoms.2016.04.026](#)]
- 16 **Turner MD**. Combined Surgical Approaches for the Removal of Submandibular Gland Sialoliths. *Atlas Oral Maxillofac Surg Clin North Am* 2018; **26**: 145-151 [PMID: [30077322](#) DOI: [10.1016/j.cxom.2018.05.005](#)]
- 17 **Koch M**, Zenk J, Iro H. Algorithms for treatment of salivary gland obstructions. *Otolaryngol Clin North Am* 2009; **42**: 1173-1192, Table of Contents [PMID: [19962014](#) DOI: [10.1016/j.otc.2009.08.002](#)]
- 18 **Cox D**, Chan L, Veivers D. Prognostic factors for therapeutic sialendoscopy. *J Laryngol Otol* 2018; **132**: 275-278 [PMID: [28490396](#) DOI: [10.1017/S0022215117000822](#)]
- 19 **Marchal F**, Dulguerov P. Sialolithiasis management: the state of the art. *Arch Otolaryngol Head Neck Surg* 2003; **129**: 951-956 [PMID: [12975267](#) DOI: [10.1001/archotol.129.9.951](#)]



Published by **Baishideng Publishing Group Inc**
7041 Koll Center Parkway, Suite 160, Pleasanton, CA 94566, USA

Telephone: +1-925-3991568

E-mail: bpgoffice@wjgnet.com

Help Desk: <https://www.f6publishing.com/helpdesk>

<https://www.wjgnet.com>

