

World Journal of *Clinical Cases*

World J Clin Cases 2022 February 26; 10(6): 1754-2052



Contents

Thrice Monthly Volume 10 Number 6 February 26, 2022

OPINION REVIEW

- 1754 Gut-brain axis: Focus on gut metabolites short-chain fatty acids
Guo C, Huo YJ, Li Y, Han Y, Zhou D

MINIREVIEWS

- 1764 Association between direct-acting antiviral agents in hepatitis C virus treatment and hepatocellular carcinoma occurrence and recurrence: The endless debate
Kamal A, Elsheaita A, Abdelnabi M

ORIGINAL ARTICLE

Retrospective Cohort Study

- 1775 Effects of bilirubin on perioperative myocardial infarction and its long-term prognosis in patients undergoing percutaneous coronary intervention
Li Y, Li DB, Zhao LD, Lv QB, Wang Y, Ren YF, Zhang WB
- 1787 Disease exacerbation is common in inflammatory bowel disease patients treated with immune checkpoint inhibitors for malignancy
Rubin SJS, Balabanis T, Gubatan J, Habtezion A
- 1795 Multidrug-resistant organisms in intensive care units and logistic analysis of risk factors
Han Y, Zhang J, Zhang HZ, Zhang XY, Wang YM

Retrospective Study

- 1806 Change and impact of left ventricular global longitudinal strain during transcatheter aortic valve implantation
Zhang H, Xie JJ, Li RJ, Wang YL, Niu BR, Song L, Li J, Yang Y

Observational Study

- 1815 Early detection of noise-induced hearing loss
Meng ZL, Chen F, Zhao F, Gu HL, Zheng Y
- 1826 Empathetic nursing with mindful cognitive therapy for fatigue, depression, and negative emotions in leukemia patients undergoing long-term chemotherapy
Lu YY, Lu XM, Shao CY, Wang CC, Xu TT, Zhang BL

Prospective Study

- 1834 Superior pancreatic lymphadenectomy with portal vein priority *via* posterior common hepatic artery approach in laparoscopic radical gastrectomy
Zhang YJ, Xiang RC, Li J, Liu Y, Xie SM, An L, Li HL, Mai G

Randomized Controlled Trial

- 1843** Systematic nursing interventions in gastric cancer: A randomized controlled study
He F, He RX

META-ANALYSIS

- 1852** Impact of adding opioids to paravertebral blocks in breast cancer surgery patients: A systematic review and meta-analysis
Chen MH, Chen Z, Zhao D

CASE REPORT

- 1863** Multiple different remote epidural hematomas after craniotomy: A case report
He Q, Tao CY, Fu RH, You C
- 1869** Tuberculous pericarditis-a silent and challenging disease: A case report
Lucero OD, Bustos MM, Ariza Rodríguez DJ, Perez JC
- 1876** Transileocolic endovascular treatment by a hybrid approach for severe acute portal vein thrombosis with bowel necrosis: Two case reports
Shirai S, Ueda T, Sugihara F, Yasui D, Saito H, Furuki H, Kim S, Yoshida H, Yokobori S, Hayashi H, Kumita SI
- 1883** Efficacy of EGFR-TKI sequential therapy in patients with EGFR exon 19 insertion-positive non-small-cell lung cancer: A case report
Shan BB, Li Y, Zhao C, An XQ, Zhang QM
- 1889** Novel compound heterozygous variants in the TAF6 gene in a patient with Alazami-Yuan syndrome: A case report
Lin SZ, Feng JH, Sun LP, Ma HW, Wang WQ, Li JY
- 1896** Asymmetric limb weakness in Guillain-Barré syndrome: Three case reports
Hu M, Li X, Wong HY, Feng XG, Wang YZ, Zhang GR
- 1903** Modified treatment of knee osteoarthritis complicated with femoral varus deformity: A case report
Xu SM, Li W, Zhang DB, Bi HY, Gu GS
- 1909** Novel HNF1A gene mutation in maturity-onset diabetes of the young: A case report
Xu Q, Kan CX, Hou NN, Sun XD
- 1914** Cerebral corridor creator for resection of trigone ventricular tumors: Two case reports
Liu XW, Lu WR, Zhang TY, Hou XS, Fa ZQ, Zhang SZ
- 1922** Left abdominal wall proliferative myositis resection and patch repair: A case report
Xing RW, Nie HQ, Zhou XF, Zhang FF, Mou YH
- 1929** Concurrent ankylosing spondylitis and myelodysplastic syndrome: A case report
Xu GH, Lin J, Chen WQ

- 1937** Life-threatening subclavian artery bleeding following percutaneous coronary intervention with stent implantation: A case report and review of literature
Shi F, Zhang Y, Sun LX, Long S
- 1946** Cryptogenic organizing pneumonia associated with pregnancy: A case report
Lee YJ, Kim YS
- 1952** Eosinophilia complicated with venous thromboembolism: A case report
Su WQ, Fu YZ, Liu SY, Cao MJ, Xue YB, Suo FF, Liu WC
- 1961** Neck and mediastinal hematoma caused by a foreign body in the esophagus with diagnostic difficulties: A case report
Wang LP, Zhou ZY, Huang XP, Bai YJ, Shi HX, Sheng D
- 1966** Therapeutic endoscopy of a Dieulafoy lesion in a 10-year-old girl: A case report
Chen Y, Sun M, Teng X
- 1973** Cavernous hemangioma of an intrapancreatic accessory spleen mimicking a pancreatic tumor: A case report
Huang JY, Yang R, Li JW, Lu Q, Luo Y
- 1981** Surgery and antibiotics for the treatment of lupus nephritis with cerebral abscesses: A case report
Hu QD, Liao LS, Zhang Y, Zhang Q, Liu J
- 1991** Median arcuate ligamentum syndrome: Four case reports
Kim JE, Rhee PL
- 1998** Novel ABCB4 mutations in an infertile female with progressive familial intrahepatic cholestasis type 3: A case report
Liu TF, He JJ, Wang L, Zhang LY
- 2007** Primary duodenal dedifferentiated liposarcoma: A case report and literature review
Kim NI, Lee JS, Choi C, Nam JH, Choi YD, Kim HJ, Kim SS
- 2015** Implant site development using titanium plate and platelet-rich fibrin for congenitally missed maxillary lateral incisors: A case report
Zhang TS, Mudalal M, Ren SC, Zhou YM
- 2023** Successful embolization of an intrahepatic portosystemic shunt using balloon-occluded retrograde transvenous obliteration: A case report
Saito H, Murata S, Sugihara F, Ueda T, Yasui D, Miki I, Hayashi H, Kumita SI
- 2030** Bilateral pneumothorax and pneumomediastinum during colonoscopy in a patient with intestinal Behcet's disease: A case report
Mu T, Feng H
- 2036** Acute kidney injury due to intravenous detergent poisoning: A case report
Park S, Ryu HS, Lee JK, Park SS, Kwon SJ, Hwang WM, Yun SR, Park MH, Park Y

- 2045** Vaginal enterocele after cystectomy: A case report

Liu SH, Zhang YH, Niu HT, Tian DX, Qin F, Jiao W

ABOUT COVER

Editorial Board Member of *World Journal of Clinical Cases*, Navdeep Singh, MBBS, MS, Assistant Professor, Division of Transplantation, Department of Surgery, The Ohio State University, Columbus, OH 43210, United States.
navdeep.singh@osumc.edu

AIMS AND SCOPE

The primary aim of *World Journal of Clinical Cases* (WJCC, *World J Clin Cases*) is to provide scholars and readers from various fields of clinical medicine with a platform to publish high-quality clinical research articles and communicate their research findings online.

WJCC mainly publishes articles reporting research results and findings obtained in the field of clinical medicine and covering a wide range of topics, including case control studies, retrospective cohort studies, retrospective studies, clinical trials studies, observational studies, prospective studies, randomized controlled trials, randomized clinical trials, systematic reviews, meta-analysis, and case reports.

INDEXING/ABSTRACTING

The WJCC is now indexed in Science Citation Index Expanded (also known as SciSearch®), Journal Citation Reports/Science Edition, Scopus, PubMed, and PubMed Central. The 2021 Edition of Journal Citation Reports® cites the 2020 impact factor (IF) for WJCC as 1.337; IF without journal self cites: 1.301; 5-year IF: 1.742; Journal Citation Indicator: 0.33; Ranking: 119 among 169 journals in medicine, general and internal; and Quartile category: Q3. The WJCC's CiteScore for 2020 is 0.8 and Scopus CiteScore rank 2020: General Medicine is 493/793.

RESPONSIBLE EDITORS FOR THIS ISSUE

Production Editor: *Ying-Yi Yuan*, Production Department Director: *Xu Guo*, Editorial Office Director: *Jin-Lei Wang*.

NAME OF JOURNAL

World Journal of Clinical Cases

ISSN

ISSN 2307-8960 (online)

LAUNCH DATE

April 16, 2013

FREQUENCY

Thrice Monthly

EDITORS-IN-CHIEF

Bao-Gan Peng, Jerzy Tadeusz Chudek, George Kontogeorgos, Maurizio Serati, Ja Hyeon Ku

EDITORIAL BOARD MEMBERS

<https://www.wjgnet.com/2307-8960/editorialboard.htm>

PUBLICATION DATE

February 26, 2022

COPYRIGHT

© 2022 Baishideng Publishing Group Inc

INSTRUCTIONS TO AUTHORS

<https://www.wjgnet.com/bpg/gerinfo/204>

GUIDELINES FOR ETHICS DOCUMENTS

<https://www.wjgnet.com/bpg/GerInfo/287>

GUIDELINES FOR NON-NATIVE SPEAKERS OF ENGLISH

<https://www.wjgnet.com/bpg/gerinfo/240>

PUBLICATION ETHICS

<https://www.wjgnet.com/bpg/GerInfo/288>

PUBLICATION MISCONDUCT

<https://www.wjgnet.com/bpg/gerinfo/208>

ARTICLE PROCESSING CHARGE

<https://www.wjgnet.com/bpg/gerinfo/242>

STEPS FOR SUBMITTING MANUSCRIPTS

<https://www.wjgnet.com/bpg/GerInfo/239>

ONLINE SUBMISSION

<https://www.f6publishing.com>



Novel *ABCB4* mutations in an infertile female with progressive familial intrahepatic cholestasis type 3: A case report

Tian-Fu Liu, Jing-Jing He, Liang Wang, Ling-Yi Zhang

Specialty type: Gastroenterology and hepatology

Provenance and peer review: Unsolicited article; Externally peer reviewed.

Peer-review model: Single blind

Peer-review report's scientific quality classification

Grade A (Excellent): 0
Grade B (Very good): B
Grade C (Good): 0
Grade D (Fair): D
Grade E (Poor): 0

P-Reviewer: Shao Y, Shariati MBH

Received: August 29, 2021

Peer-review started: August 29, 2021

First decision: November 16, 2021

Revised: November 25, 2021

Accepted: January 11, 2022

Article in press: January 11, 2022

Published online: February 26, 2022



Tian-Fu Liu, Jing-Jing He, Liang Wang, Ling-Yi Zhang, Department of Hepatology, Lanzhou University Second Hospital, Lanzhou 730030, Gansu Province, China

Corresponding author: Ling-Yi Zhang, MD, Professor, Department of Hepatology, Lanzhou University Second Hospital, No. 82 Cuiyingmen, Chengguan District, Lanzhou 730030, Gansu Province, China. zhanglymd@126.com

Abstract

BACKGROUND

Mutations that occur in the *ABCB4* gene, which encodes multidrug-resistant protein 3, underlie the occurrence of progressive familial intrahepatic cholestasis type 3 (PFIC3). Clinical signs of intrahepatic cholestasis due to gene mutations typically first appear during infancy or childhood. Reports of PFIC3 occurring in adults are rare.

CASE SUMMARY

This is a case study of a 32-year-old infertile female Chinese patient with a 15-year history of recurrent abnormal liver function. Her primary clinical signs were elevated levels of alkaline phosphatase and γ -glutamyl transpeptidase. Other possible reasons for liver dysfunction were eliminated in this patient, resulting in a diagnosis of PFIC3. The diagnosis was confirmed using gene detection and histological analyses. Assessments using genetic sequencing analysis indicated the presence of two novel heterozygous mutations in the *ABCB4* gene, namely, a 2950C>T; p.A984V mutation (exon 24) and a 667A>G; p.I223V mutation (exon 7). After receiving ursodeoxycholic acid (UDCA) treatment, the patient's liver function indices improved, and she successfully became pregnant by *in vitro* fertilization. However, the patient developed intrahepatic cholestasis of pregnancy in the first trimester. Fortunately, treatment with UDCA was safe and effective.

CONCLUSION

These novel *ABCB4* heterozygous mutations have a variety of clinical phenotypes. Continued follow-up is essential for a comprehensive understanding of PFIC3.

Key Words: Progressive familial intrahepatic cholestasis type 3; *ABCB4* gene; Infertility; Intrahepatic cholestasis of pregnancy; Case report

©The Author(s) 2022. Published by Baishideng Publishing Group Inc. All rights reserved.

Core Tip: This is the first case report of an adult patient with progressive familial intrahepatic cholestasis type 3 (PFIC3) and infertility. Gene detection was central to making a definitive diagnosis. The novel *ABCB4* heterozygous mutations observed exhibited a variety of clinical phenotypes. A genetic predisposition to infertility may also be present in this patient and requires further research. The discovery of these new mutations has enriched the information on the clinical features of PFIC3 and contributed to a more comprehensive understanding of *ABCB4* disease.

Citation: Liu TF, He JJ, Wang L, Zhang LY. Novel *ABCB4* mutations in an infertile female with progressive familial intrahepatic cholestasis type 3: A case report. *World J Clin Cases* 2022; 10(6): 1998-2006

URL: <https://www.wjgnet.com/2307-8960/full/v10/i6/1998.htm>

DOI: <https://dx.doi.org/10.12998/wjcc.v10.i6.1998>

INTRODUCTION

Progressive familial intrahepatic cholestasis (PFIC) comprises several rare, hereditary autosomal-recessive hepatic diseases that occur predominantly in neonates and infants. Intrahepatic cholestasis is the primary clinical sign observed in patients with PFIC[1]. As the disease progresses, patients develop liver fibrosis, which progresses to cirrhosis and eventually hepatic failure[2]. Based on the specific mutations in the gene, six types of PFIC have been defined, among which classical types 1, 2 and 3 are more common[3]. In terms of biochemical and histological characteristics, there are significant differences between PFIC3 and other types (Table 1). In particular, PFIC3 presents with elevated serum γ -glutamyl transpeptidase (GGT)[4]. We found few reports of cases of PFIC3 in our search of the published literature, which included the last ten years. In particular, fertility in adult PFIC3 patients has not been reported.

CASE PRESENTATION

Chief complaints

A 32-year-old female patient had experienced abnormal serum liver enzyme levels for 15 years.

History of present illness

Fifteen years previously, the patient was diagnosed with abnormal serum liver enzyme levels during the course of a high school physical examination. As she did not exhibit any symptoms of overall liver dysfunction, no action was taken at that time. Four years later, liver function index abnormalities were observed during an occupational health examination. The patient was admitted to a local hospital with no apparent cause of her abnormal serum enzyme levels. The patient was treated with some liver-protective drugs, but her liver function indices did not improve. The patient was not experiencing any adverse effects at that time and did not actively have her liver function indices monitored in subsequent years. One month prior to her admission to our hospital, the patient visited a maternal and child health hospital due to infertility, but routine examination on admission revealed significantly abnormal liver function indices. For further diagnosis and treatment, she was admitted to the Department of Hepatology at our hospital.

History of past illness

Thirteen years previously, the patient had undergone splenectomy due to a ruptured spleen caused by a car accident and recovered well.

Personal and family history

During her ten years of marriage, the patient experienced continued infertility and did not take any infertility medications or oral contraceptives. One year previously, salpingography at a maternal and child health hospital showed partial obstruction of the fallopian tube, and the natural conception rate was low. The fertility tests of the patient's spouse were normal. Therefore, *in vitro* fertilization (IVF)-assisted reproduction was recommended. However, due to financial reasons, the patient did not receive IVF.

The patient indicated that she did not have a history of alcohol intake or the use of any hepatotoxic drugs. Her father had undergone surgery years previously to treat intrahepatic bile duct stones and recovered well from the surgery. Her mother, who died from a brain hemorrhage three years earlier, did not have liver disease in her medical history. Her brother's liver function was normal.

Table 1 Gene, clinical and histological features of different types of progressive familial intrahepatic cholestasis type 3

	PFIC1	PFIC2	PFIC3
Gene	<i>ATP8B1</i>	<i>ABCB11</i>	<i>ABCB4</i>
Protein	FIC1	BSEP	MDR3
Serum ALT	+	++	+
Serum GGT	Normal	Normal	Elevated
Serum TBA	++	+++	+
Liver histology	Mild cholestasis, mild lobular fibrosis	Cholestasis, portal fibrosis, giant cell hepatitis, hepatocellular necrosis	Bile ductular proliferation, inflammatory infiltrate, and biliary fibrosis

PFIC: Progressive familial intrahepatic cholestasis; FIC1: Familial intrahepatic cholestasis 1; BSEP: Bile salt export pump; MDR3: Multidrug resistance class 3; ALT: Alanine aminotransferase; GGT: γ -glutamyl transpeptidase; TBA: Total bile acid.

Physical examination

The patient's vital signs were all stable, and physical examination revealed no noteworthy positive signs.

Laboratory examinations

Analysis of her laboratory data (November 3, 2020) revealed the following results: total bilirubin, 28.1 $\mu\text{mol/L}$; direct bilirubin, 16.1 $\mu\text{mol/L}$; alanine aminotransferase (ALT), 151 U/L; aspartate aminotransferase (AST), 119 U/L; alkaline phosphatase (ALP), 226 U/L; GGT, 1025 U/L; total bile acid (TBA), 17.2 $\mu\text{mol/L}$; and albumin, 41.8 g/L (Table 2). Several markers for hepatitis viruses (hepatitis A, B, C, and E) were determined to be negative. The analyses for antibodies to cytomegalovirus antibodies and Epstein-Barr virus DNA were also negative. All autoimmune antibodies, including antimitochondrial and antinuclear lupus-related antibodies and Sjogren's syndrome-related antibodies were negative. We also assessed serum copper levels as well as ferritin and ceruloplasmin, and the levels were within normal ranges. Routine blood analysis, coagulation function, thyroid function, and several additional laboratory test results were found to be unremarkable.

Imaging examinations

Abdominal magnetic resonance imaging (MRI) revealed an increased hepatic interstitium and multiple patchy abnormal signal shadows in hepatic segments VII and VIII. The presence of nodule regeneration was considered after enhanced examination using gadolinium-ethoxybenzyl-diethylenetriamine penta-acetic acid, which is a hepatocellular-specific contrast agent. No obstructions associated with the extrahepatic and intrahepatic bile ducts were observed following detailed examination using magnetic resonance cholangiopancreatography (Figure 1). Cardiac ultrasound and chest radiography showed no abnormalities.

Specialized examinations

We examined the sclera of the patient's eyes for Kayser-Fleischer rings, but no rings were present. The transient elastography assessment for liver fibrosis was 14.6 kPa.

Pathological findings and immunohistochemical staining

With the consent of the patient, we performed an ultrasound-guided liver biopsy. Pathological examination revealed cholestatic liver fibrosis (modified Scheuer score S2). An analysis of histological samples revealed a significant decrease in multidrug-resistant protein 3 (MDR3) protein staining compared to the levels of staining observed in samples from healthy subjects (Figure 2).

Gene mutational analysis

Genomic DNA was purified from peripheral blood samples. Based on Illumina NovaSeq® 6000 instruments and the xGen® sequencing Exome Research Panel, high-throughput sequencing was used to detect genomic mutations. The genetic testing results revealed two novel heterozygous mutations in the *ABCB4* gene: a 2950C>T; p.A984V mutation (exon 24) and a 667A>G; p.I223V mutation (exon 7) (Figure 3).

Table 2 Liver function throughout the course of the disease

	Admission	Discharge	Before pregnancy	13 th week of pregnancy	21 th week of pregnancy	30 th week of pregnancy
ALT (7-41 U/L)	151	18	12	85	28	21
AST (13-35U/L)	119	48	38	109	59	53
TBil (3.0-21.0 μ mol/L)	28.1	14.1	21.1	27.4	21.5	33.2
DBil (0.1-6.8 μ mol/L)	16.1	9.3	12.0	15.3	11.3	20.8
GGT (7-45U/L)	1025	459	301	470	199	148
ALP (35-100 U/L)	226	126	147	223	133	251
TBA (0.0-10.0 μ mol/L)	17.2	19.9	15.3	40.5	52.1	81.8

ALT: Alanine aminotransferase; AST: Aspartate aminotransferase; ALP: Alkaline phosphatase; GGT: γ -glutamyl transpeptidase; TBil: total bilirubin; DBil: Direct bilirubin; TBA: Total bile acid.

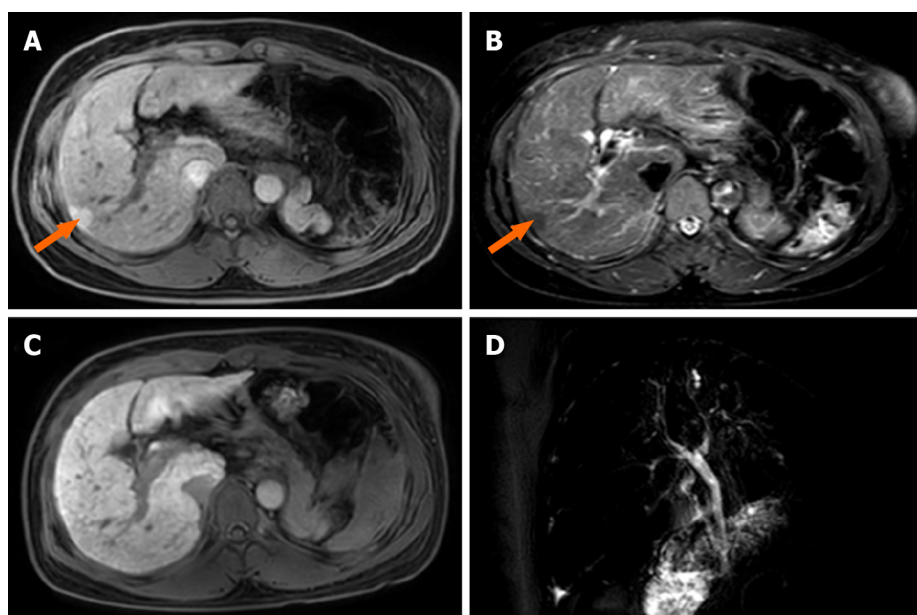


Figure 1 Liver magnetic resonance images. A: T1-weighted image. The size and shape of the liver are normal, and patchy low signal intensity can be seen in the SVII segment, with a diameter of approximately 15 mm. Loss of spleen; B: T2W spectral attenuated inversion recovery image. The interstitium increased in the liver, and the lesions in the SVII segment showed high signal intensity; C: Gadolinium-ethoxybenzyl-diethylenetriamine penta-acetic acid 15MIN_Delay image. The signal intensity of SVII segment lesions was basically consistent with that of normal liver; D: Magnetic resonance cholangiopancreatography image. No stricture or dilatation of the intrahepatic or extrahepatic bile duct was observed.

FINAL DIAGNOSIS

According to the above case data, the patient's liver function, particularly the increase in serum GGT, was abnormal for many years. Immunohistochemical analysis of liver tissue showed that MDR3 staining was significantly decreased, and gene detection showed that there were two heterozygous mutations in the *ABCB4* gene. The final diagnosis of the presented case was PFIC3.

TREATMENT

The patient received treatment with ursodeoxycholic acid (UDCA) 750 mg/d.

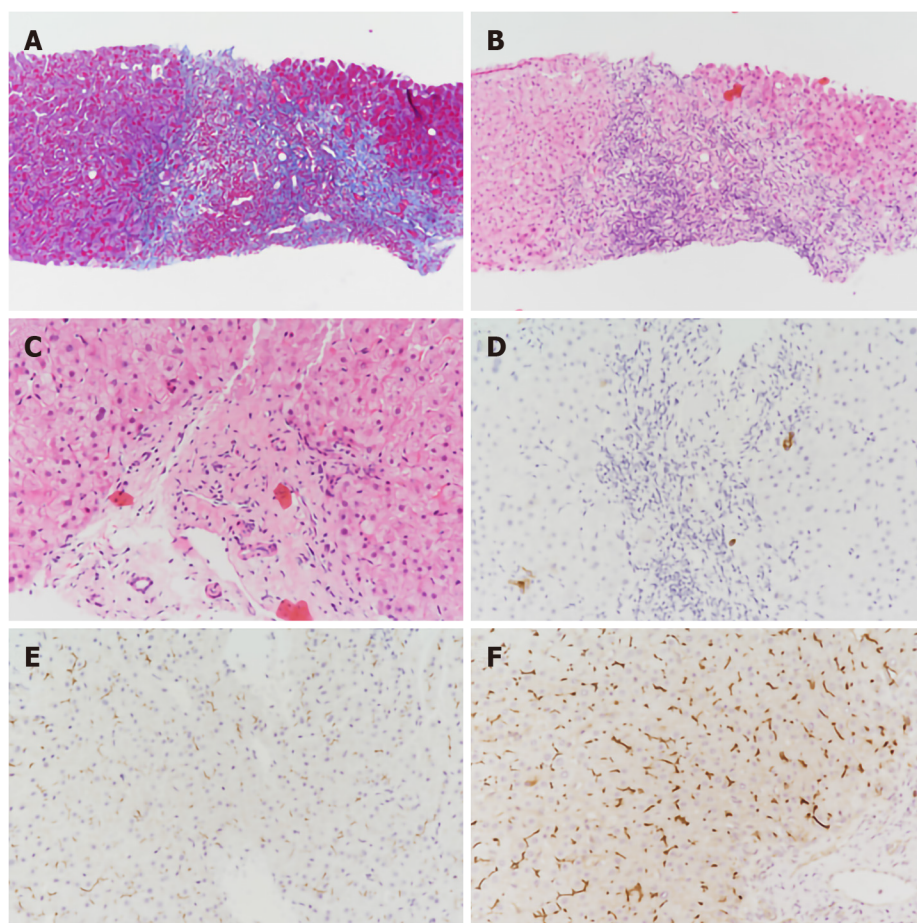


Figure 2 Pathological examination of liver biopsy specimens. A: The interstitial fibrous tissue in the portal area proliferates, and the fibrous septum is formed (Masson; original magnification $\times 100$); B: The portal area was enlarged with moderate mixed inflammatory cell infiltration and mild interfacial inflammation (hematoxylin and eosin; original magnification $\times 100$); C: Irregular arrangement of the epithelium of the small bile duct in the portal area (hematoxylin and eosin; original magnification $\times 200$); D: Absence of small bile duct in part of the portal area (CK7; original magnification $\times 200$); E: Multidrug resistance protein 3 (MDR3) protein staining decreased significantly (immunohistochemical staining; original magnification $\times 200$); F: Liver biopsy specimens from a healthy person showing normal expression of the MDR3 protein (immunohistochemical staining; original magnification $\times 200$).

OUTCOME AND FOLLOW-UP

When the patient was discharged, the GGT decreased significantly, and the other liver function indices were close to the normal values (Table 2). After consulting with family members and saving money, the patient went to the maternal and child health care hospital again, successfully became pregnant *via* IVF, and stopped UDCA treatment on her own. Skin pruritus occurred at the 13th week of pregnancy, and serological examination showed that her liver function was significantly abnormal, in particular, TBA was higher than the initial value. The diagnosis was PFIC3 combined with intrahepatic cholestasis of pregnancy (ICP), and UDCA therapy was recommended. Her symptoms of itching were subsequently alleviated, and all liver function indices except TBA were improved. Fortunately, fetal indicators were normal. The liver function test results during the course of the disease are shown in Table 2.

DISCUSSION

PFIC3 occurs rarely and is primarily a sporadic disease[5], and the incidence of PFIC3 in the general population has not been reported definitively. A previous assessment of disease occurrence demonstrated that PFIC3 incidence might be 1 in 500000 people[6]. Patients exhibiting PFIC3 commonly develop cholestasis later in childhood and up to adolescence. Individuals with PFIC3 often exhibit recurring episodes of pruritus, jaundice, pale clay-like stools, hepatosplenomegaly, and gastrointestinal bleeding, which can progress to cirrhosis and liver failure before the onset of adulthood[7,8]. Gastrointestinal bleeding that is associated with cirrhosis or the occurrence of portal hypertension is often the first presenting sign of the disorder in older children or young adults[9].

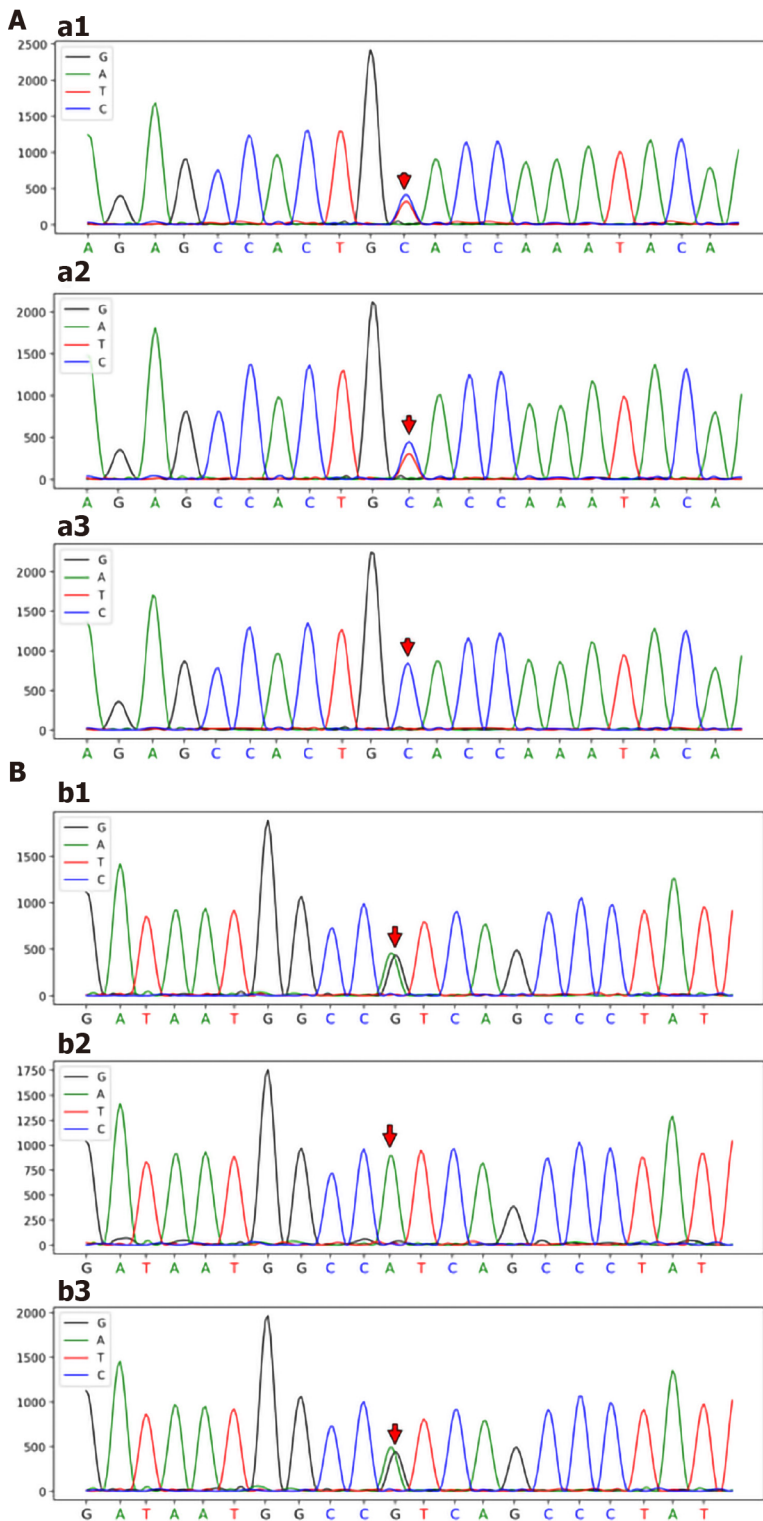


Figure 3 Sanger sequencing map. A: *ABCB4*_ex24 c.2950C>T (p.A984V) Sanger sequencing map; Patient: *ABCB4*_ex24 c.2950C>T (p.A984V) gene mutation (a1); Patient's father: *ABCB4*_ex24 c.2950C>T (p.A984V) gene mutation (a2); Patient's brother: No *ABCB4*_ex24 c.2950C>T (p.A984V) gene mutation (a3); B: *ABCB4*_ex7 c.667A>G (p.I223V) Sanger sequencing map; Patient: *ABCB4*_ex7 c.667A>G (p.I223V) gene mutation (b1); Patient's father: No *ABCB4*_ex7 c.667A>G (p.I223V) gene mutation (b2); Patient's brother: *ABCB4*_ex7 c.667A>G (p.I223V) gene mutation (b3).

In this case study, we analyzed a 32-year-old female Chinese patient who was asymptomatic. We used laboratory, MRI, and histological examinations to exclude other possible etiologies, including primary biliary cholangitis, Alagille syndrome, primary sclerosing cholangitis, Wilson's disease, and drug-induced liver injury. Subsequently, we highly suspected that this patient might have PFIC3 based on her high level of GGT. Therefore, we carried out a gene mutation analysis that revealed two novel heterozygous mutations in *ABCB4*, namely, a 2950C>T; p.A984V mutation and a 667A>G; p.I223V mutation. Based on immunostaining for MDR3 in liver samples and genetic testing, the patient was

diagnosed with PFIC3.

PFIC3 is caused by a mutation in the *ABCB4* gene, which encodes MDR3[10]. MDR3 is classified as a p-glycoprotein (pGp) and has been shown to be expressed in hepatocyte canalicular membranes[11]. The MDR3 protein transfers phospholipids from hepatocytes into the bile ducts[12]. Normally, phospholipids combine with bile salts that subsequently form microparticles. This process results in increased hydrophilicity and reduces the descaling effects produced by bile salts. These actions protect bile duct cells from toxic damage that can be induced by bile salts. A major function of phospholipids in the liver is to neutralize the detergent-like effects produced by hydrophobic bile salts[6,13]. Thus, defects in the MDR3 protein can result in damage to the biliary epithelium and bile canaliculi, which ultimately can produce cholestasis. It should be noted that the primary defect that occurs with MDR3 deficiency does not lead to the retention of bile acids in hepatocytes, so cholestasis is not a direct result of the disorder[14]. Symptoms, including cholestasis, develop as a result of the damage caused by the eventual cholangiopathy. Even patients who exhibit complete MDR3 deficiency may not present clinical symptoms for several years[15]. When MDR3 function is only partially lost, patients commonly exhibit slow disease progression[16]. Therefore, MDR3 deficiencies can result in a range of disease manifestations and ages at presentation.

Nearly 300 *ABCB4* variants that cause disease have been reported, of which approximately 50 are associated with PFIC3[7]. The age at which the patient first exhibits signs of cholestatic disease, severity of the liver disorder and response to treatment have been shown to be correlated with the different mutations that occur in the *ABCB4* gene[16]. Patients with homozygous mutations tend to exhibit progressive intrahepatic cholestasis, which usually leads to liver failure in early childhood and requires liver transplantation[17]. On the other hand, the age of disease onset in patients with heterozygous mutations is relatively high, and clinical symptoms are mild.

New evidence demonstrates a spectrum of diseases resulting from heterozygous mutations in *ABCB4*, ranging from the severe form seen in PFIC3 to milder, intermittent forms such as low-phospholipid-associated cholelithiasis syndrome (LPAC), ICP and adult-onset biliary fibrosis or cirrhosis[18-21]. Previous studies have shown that reduced or absent transport of phosphatidylcholine is indeed associated with intrahepatic sludge or stone formation[22]. The father of the patient had a genetic mutation in *ABCB4*, including a 2950C>T; p.A984V mutation, and his preexisting intrahepatic bile duct stone may have been a phenotypic form of LPAC[23]. Although the majority of cases of ICP present in the third trimester and are usually thought to be multifactorial in etiology, the patient's early pregnancy presentation may have been attributed to an underlying genetic susceptibility[24]. *ABCB4* gene defects are one of the major causes of biliary fibrosis, and Bernardo *et al*[25] reported that PFIC3-associated biliary fibrosis can be partially reversed after UDCA treatment. However, the coexistence of *ABCB4* variants and infertility has not been reported in previously published literature. While not proof of causality, the mutations identified in our patient certainly suggest a possible susceptibility for her rare and unique presentation.

Genetic sequencing of the *ABCB4* gene in our patient revealed two novel heterozygous mutations, namely, a 2950C>T; p.A984V mutation and a 667A>G; p.I223V mutation. These two mutations were not included in the Human Gene Mutation Database or the ClinVar database. The effects on function resulting from the two mutations were evaluated using Polymorphism Phenotyping v2, Sorting Intolerant from Tolerant, and MutationTaster[26-28]. The two novel mutations were predicted to have uncertain significance. Based on the familial identification, the locations of these two mutations were determined to be on different chromosomes, which resulted in a compound heterozygous mutation that might have resulted in a partial loss of function for MDR3. It is due to this compound heterozygous mutation that this patient has a rare and unique clinical phenotype.

UDCA is typically used as the initial treatment for PFIC3[29]. Some studies have shown that a dose of 10-30 mg/kg/day can successfully treat PFIC3 and resolve the presence of cholestasis in patients[2]. UDCA has been shown to be effective in two-thirds of PFIC3 patients. Korkut *et al*[30] reported that UDCA treatment was effective in improving conception in women who had intrahepatic cholestasis and were infertile. Here, the patient successfully became pregnant after UDCA treatment following a single IVF treatment, and UDCA treatment may have had some potential beneficial effects. The patient responded well to UDCA therapy. After UDCA treatment, the serum GGT in this patient decreased significantly, and the other liver function indices basically returned to normal. However, after the combination of ICP, UDCA improved the symptoms of pruritus and liver function, but TBA showed an upward trend. The increase in TBA may harm the fetus, so it is necessary to closely monitor the fetal index and deliver early if necessary. The remaining one-third of patients may require additional intervention due to the degree of disease progression and inadequate symptom relief. When other treatments are unsuccessful, liver transplantation has been shown to be effective in PFIC3 patients[31]. However, long-term follow-up to monitor the patient's liver function is necessary.

CONCLUSION

We were able to definitively diagnose PFIC3 in a 32-year-old female Chinese patient based on her

clinical symptoms, pathological examination, and gene detection. Successful gene detection was essential to the diagnosis. This case illustrates the heterogeneity of genetic mutations. These novel *ABCB4* heterozygous mutations have a variety of clinical phenotypes that respond well to UDCA therapy. A genetic predisposition to infertility may also be present in this patient, and this requires further research. The discovery of these new mutations has enriched the information on the clinical features of PFIC3 and contributed to a more comprehensive understanding of *ABCB4* disease.

ACKNOWLEDGEMENTS

The authors thank the patient for agreeing to report her case and for providing a detailed medical history.

FOOTNOTES

Author contributions: Liu TF reviewed the literature and was responsible for manuscript drafting and organization of illustrations; He JJ and Wang L analyzed and interpreted the pathological findings, immunohistochemical findings, and genetic mutations; Zhang LY was responsible for revision of the manuscript for important intellectual content; all authors issued final approval for the version to be submitted.

Supported by Natural Science Foundation of Gansu Province, No. 21JR7RA410.

Informed consent statement: Informed written consent was obtained from the patient for publication of this report and any accompanying images.

Conflict-of-interest statement: The authors declare that they have no conflict of interest.

CARE Checklist (2016) statement: The authors have read the CARE Checklist (2016), and the manuscript was prepared and revised according to the CARE Checklist (2016).

Open-Access: This article is an open-access article that was selected by an in-house editor and fully peer-reviewed by external reviewers. It is distributed in accordance with the Creative Commons Attribution NonCommercial (CC BY-NC 4.0) license, which permits others to distribute, remix, adapt, build upon this work non-commercially, and license their derivative works on different terms, provided the original work is properly cited and the use is non-commercial. See: <https://creativecommons.org/licenses/by-nc/4.0/>

Country/Territory of origin: China

ORCID number: Tian-Fu Liu 0000-0002-6909-5197; Jing-Jing He 0000-0002-1057-6375; Liang Wang 0000-0003-1620-7682; Ling-Yi Zhang 0000-0002-0434-7533.

S-Editor: Ma YJ

L-Editor: Webster JR

P-Editor: Ma YJ

REFERENCES

- 1 Bull LN, Thompson RJ. Progressive Familial Intrahepatic Cholestasis. *Clin Liver Dis* 2018; **22**: 657-669 [PMID: 30266155 DOI: 10.1016/j.cld.2018.06.003]
- 2 Gunaydin M, Bozkurter Cil AT. Progressive familial intrahepatic cholestasis: diagnosis, management, and treatment. *Hepat Med* 2018; **10**: 95-104 [PMID: 30237746 DOI: 10.2147/HMER.S137209]
- 3 Amirneni S, Haep N, Gad MA, Soto-Gutierrez A, Squires JE, Florentino RM. Molecular overview of progressive familial intrahepatic cholestasis. *World J Gastroenterol* 2020; **26**: 7470-7484 [PMID: 33384548 DOI: 10.3748/wjg.v26.i47.7470]
- 4 Srivastava A. Progressive familial intrahepatic cholestasis. *J Clin Exp Hepatol* 2014; **4**: 25-36 [PMID: 25755532 DOI: 10.1016/j.jceh.2013.10.005]
- 5 Gaur K, Sakhuja P. Progressive familial intrahepatic cholestasis: A comprehensive review of a challenging liver disease. *Indian J Pathol Microbiol* 2017; **60**: 2-7 [PMID: 28195083 DOI: 10.4103/0377-4929.200040]
- 6 Jacquemin E, De Vree JM, Cresteil D, Sokal EM, Sturm E, Dumont M, Scheffer GL, Paul M, Burdelski M, Bosma PJ, Bernard O, Hadchouel M, Elferink RP. The wide spectrum of multidrug resistance 3 deficiency: from neonatal cholestasis to cirrhosis of adulthood. *Gastroenterology* 2001; **120**: 1448-1458 [PMID: 11313315 DOI: 10.1053/gast.2001.23984]
- 7 Delaunay JL, Durand-Schneider AM, Dossier C, Falguières T, Gautherot J, Davit-Spraul A, Aït-Slimane T, Housset C, Jacquemin E, Maurice M. A functional classification of *ABCB4* variations causing progressive familial intrahepatic cholestasis type 3. *Hepatology* 2016; **63**: 1620-1631 [PMID: 26474921 DOI: 10.1002/hep.28300]
- 8 Chen HL, Wu SH, Hsu SH, Liou BY, Chen HL, Chang MH. Jaundice revisited: recent advances in the diagnosis and

- treatment of inherited cholestatic liver diseases. *J Biomed Sci* 2018; **25**: 75 [PMID: 30367658 DOI: 10.1186/s12929-018-0475-8]
- 9 **Jacquemin E.** Progressive familial intrahepatic cholestasis. *Clin Res Hepatol Gastroenterol* 2012; **36** Suppl 1: S26-S35 [PMID: 23141890 DOI: 10.1016/S2210-7401(12)70018-9]
 - 10 **Jansen PL, Müller MM.** Progressive familial intrahepatic cholestasis types 1, 2, and 3. *Gut* 1998; **42**: 766-767 [PMID: 9691911 DOI: 10.1136/gut.42.6.766]
 - 11 **Davit-Spraul A, Gonzales E, Baussan C, Jacquemin E.** The spectrum of liver diseases related to ABCB4 gene mutations: pathophysiology and clinical aspects. *Semin Liver Dis* 2010; **30**: 134-146 [PMID: 20422496 DOI: 10.1055/s-0030-1253223]
 - 12 **Keitel V, Burdelski M, Warskulat U, Köhlkamp T, Keppler D, Häussinger D, Kubitz R.** Expression and localization of hepatobiliary transport proteins in progressive familial intrahepatic cholestasis. *Hepatology* 2005; **41**: 1160-1172 [PMID: 15841457 DOI: 10.1002/hep.20682]
 - 13 **Guyot C, Stieger B.** Interaction of bile salts with rat canalicular membrane vesicles: evidence for bile salt resistant microdomains. *J Hepatol* 2011; **55**: 1368-1376 [PMID: 21703191 DOI: 10.1016/j.jhep.2011.04.014]
 - 14 **Oude Elferink RP, Paulusma CC.** Function and pathophysiological importance of ABCB4 (MDR3 P-glycoprotein). *Pflugers Arch* 2007; **453**: 601-610 [PMID: 16622704 DOI: 10.1007/s00424-006-0062-9]
 - 15 **Ziol M, Barbu V, Rosmorduc O, Frassati-Biaggi A, Barget N, Hermelin B, Scheffer GL, Bennouna S, Trinchet JC, Beaugrand M, Ganne-Carrié N.** ABCB4 heterozygous gene mutations associated with fibrosing cholestatic liver disease in adults. *Gastroenterology* 2008; **135**: 131-141 [PMID: 18482588 DOI: 10.1053/j.gastro.2008.03.044]
 - 16 **Reichert MC, Lammert F.** ABCB4 Gene Aberrations in Human Liver Disease: An Evolving Spectrum. *Semin Liver Dis* 2018; **38**: 299-307 [PMID: 30357767 DOI: 10.1055/s-0038-1667299]
 - 17 **Wu Z, Zhang S, Zhang L, Li M.** Novel ABCB4 mutation in a Chinese female patient with progressive familial intrahepatic cholestasis type 3: a case report. *Diagn Pathol* 2020; **15**: 39 [PMID: 32321542 DOI: 10.1186/s13000-020-00955-7]
 - 18 **Sticova E, Jirsa M.** ABCB4 disease: Many faces of one gene deficiency. *Ann Hepatol* 2020; **19**: 126-133 [PMID: 31759867 DOI: 10.1016/j.aohp.2019.09.010]
 - 19 **Lucena JF, Herrero JI, Quiroga J, Sangro B, Garcia-Foncillas J, Zabalegui N, Sola J, Herraiz M, Medina JF, Prieto J.** A multidrug resistance 3 gene mutation causing cholelithiasis, cholestasis of pregnancy, and adulthood biliary cirrhosis. *Gastroenterology* 2003; **124**: 1037-1042 [PMID: 12671900 DOI: 10.1053/gast.2003.50144]
 - 20 **Vitale G, Gitto S, Vukotic R, Raimondi F, Andreone P.** Familial intrahepatic cholestasis: New and wide perspectives. *Dig Liver Dis* 2019; **51**: 922-933 [PMID: 31105019 DOI: 10.1016/j.dld.2019.04.013]
 - 21 **van der Woerd WL, van Mil SW, Stapelbroek JM, Klomp LW, van de Graaf SF, Houwen RH.** Familial cholestasis: progressive familial intrahepatic cholestasis, benign recurrent intrahepatic cholestasis and intrahepatic cholestasis of pregnancy. *Best Pract Res Clin Gastroenterol* 2010; **24**: 541-553 [PMID: 20955958 DOI: 10.1016/j.bpg.2010.07.010]
 - 22 **Erlinger S.** Low phospholipid-associated cholestasis and cholelithiasis. *Clin Res Hepatol Gastroenterol* 2012; **36** Suppl 1: S36-S40 [PMID: 23141892 DOI: 10.1016/S2210-7401(12)70019-0]
 - 23 **Goubault P, Brunel T, Rode A, Bancel B, Mohkam K, Mabrut JY.** Low-Phospholipid Associated Cholelithiasis (LPAC) syndrome: A synthetic review. *J Visc Surg* 2019; **156**: 319-328 [PMID: 30922600 DOI: 10.1016/j.jvisurg.2019.02.006]
 - 24 **Johnston RC, Stephenson ML, Nageotte MP.** Novel heterozygous ABCB4 gene mutation causing recurrent first-trimester intrahepatic cholestasis of pregnancy. *J Perinatol* 2014; **34**: 711-712 [PMID: 25179380 DOI: 10.1038/jp.2014.86]
 - 25 **Frider B, Castillo A, Gordo-Gilart R, Bruno A, Amante M, Alvarez L, Mathet V.** Reversal of advanced fibrosis after long-term ursodeoxycholic acid therapy in a patient with residual expression of MDR3. *Ann Hepatol* 2015; **14**: 745-751 [PMID: 26256905]
 - 26 **Adzhubei I, Jordan DM, Sunyaev SR.** Predicting functional effect of human missense mutations using PolyPhen-2. *Curr Protoc Hum Genet* 2013; **Chapter 7**: Unit7.20 [PMID: 23315928 DOI: 10.1002/0471142905.hg0720s76]
 - 27 **Kumar P, Henikoff S, Ng PC.** Predicting the effects of coding non-synonymous variants on protein function using the SIFT algorithm. *Nat Protoc* 2009; **4**: 1073-1081 [PMID: 19561590 DOI: 10.1038/nprot.2009.86]
 - 28 **Schwarz JM, Rödelberger C, Schuelke M, Seelow D.** MutationTaster evaluates disease-causing potential of sequence alterations. *Nat Methods* 2010; **7**: 575-576 [PMID: 20676075 DOI: 10.1038/nmeth0810-575]
 - 29 **Stapelbroek JM, van Erpecum KJ, Klomp LW, Houwen RH.** Liver disease associated with canalicular transport defects: current and future therapies. *J Hepatol* 2010; **52**: 258-271 [PMID: 20034695 DOI: 10.1016/j.jhep.2009.11.012]
 - 30 **Korkut E, Kisacik B, Akcan Y, Belenli O, Bicik Z, Yucel O.** Two successive pregnancies after ursodeoxycholic acid therapy in a previously infertile woman with antimitochondrial antibody-negative primary biliary cirrhosis. *Fertil Steril* 2005; **83**: 761-763 [PMID: 15749512 DOI: 10.1016/j.fertnstert.2004.11.010]
 - 31 **Englert C, Grabhorn E, Richter A, Rogiers X, Burdelski M, Ganschow R.** Liver transplantation in children with progressive familial intrahepatic cholestasis. *Transplantation* 2007; **84**: 1361-1363 [PMID: 18049123 DOI: 10.1097/01.tp.0000282869.94152.4f]



Published by **Baishideng Publishing Group Inc**
7041 Koll Center Parkway, Suite 160, Pleasanton, CA 94566, USA

Telephone: +1-925-3991568

E-mail: bpgoffice@wjgnet.com

Help Desk: <https://www.f6publishing.com/helpdesk>

<https://www.wjgnet.com>

