

# World Journal of *Clinical Cases*

*World J Clin Cases* 2022 October 16; 10(29): 10391-10822



## STANDARD AND CONSENSUS

- 10391** Baishideng's Reference Citation Analysis database announces the first Article Influence Index of multidisciplinary scholars

Wang JL, Ma YJ, Ma L, Ma N, Guo DM, Ma LS

## REVIEW

- 10399** Cholecystectomy for asymptomatic gallstones: Markov decision tree analysis  
*Lee BJH, Yap QV, Low JK, Chan YH, Shelat VG*
- 10413** Liver transplantation for hepatocellular carcinoma: Historical evolution of transplantation criteria  
*Ince V, Sahin TT, Akbulut S, Yilmaz S*

## MINIREVIEWS

- 10428** Prostate only radiotherapy using external beam radiotherapy: A clinician's perspective  
*Lee JW, Chung MJ*

## ORIGINAL ARTICLE

## Retrospective Study

- 10435** Age-adjusted NT-proBNP could help in the early identification and follow-up of children at risk for severe multisystem inflammatory syndrome associated with COVID-19 (MIS-C)  
*Rodriguez-Gonzalez M, Castellano-Martinez A*
- 10451** Clinicopathological characteristics and prognosis of gastric signet ring cell carcinoma  
*Tian HK, Zhang Z, Ning ZK, Liu J, Liu ZT, Huang HY, Zong Z, Li H*
- 10467** Development and validation of a prognostic nomogram for decompensated liver cirrhosis  
*Zhang W, Zhang Y, Liu Q, Nie Y, Zhu X*

## Observational Study

- 10478** Effect of medical care linkage-continuous management mode in patients with posterior circulation cerebral infarction undergoing endovascular interventional therapy  
*Zhu FX, Ye Q*
- 10487** Effect of the COVID-19 pandemic on patients with presumed diagnosis of acute appendicitis  
*Akbulut S, Tuncer A, Ogut Z, Sahin TT, Koc C, Guldogan E, Karabulut E, Tanriverdi ES, Ozer A*

**EVIDENCE-BASED MEDICINE**

- 10501** Delineation of a SMARCA4-specific competing endogenous RNA network and its function in hepatocellular carcinoma

*Zhang L, Sun T, Wu XY, Fei FM, Gao ZZ*

**SYSTEMATIC REVIEWS**

- 10516** Comparison of laboratory parameters, clinical symptoms and clinical outcomes of COVID-19 and influenza in pediatric patients: A systematic review and meta-analysis

*Yu B, Chen HH, Hu XF, Mai RZ, He HY*

**CASE REPORT**

- 10529** Surgical treatment of bipolar segmental clavicle fracture: A case report

*Liang L, Chen XL, Chen Y, Zhang NN*

- 10535** Multiple disciplinary team management of rare primary splenic malignancy: Two case reports

*Luo H, Wang T, Xiao L, Wang C, Yi H*

- 10543** Klippel-Trenaunay-Weber syndrome with ischemic stroke: A case report

*Lee G, Choi T*

- 10550** Vedolizumab in the treatment of immune checkpoint inhibitor-induced colitis: Two case reports

*Zhang Z, Zheng CQ*

- 10559** Novel way of patent foramen ovale detection and percutaneous closure by intracardiac echocardiography: A case report

*Han KN, Yang SW, Zhou YJ*

- 10565** Treatment failure in a patient infected with *Listeria* sepsis combined with latent meningitis: A case report

*Wu GX, Zhou JY, Hong WJ, Huang J, Yan SQ*

- 10575** Three-in-one incidence of hepatocellular carcinoma, cholangiocellular carcinoma, and neuroendocrine carcinoma: A case report

*Wu Y, Xie CB, He YH, Ke D, Huang Q, Zhao KF, Shi RS*

- 10583** Intestinal microbiome changes in an infant with right atrial isomerism and recurrent necrotizing enterocolitis: A case report and review of literature

*Kaplina A, Zaikova E, Ivanov A, Volkova Y, Alkhova T, Nikiforov V, Latypov A, Khavkina M, Fedoseeva T, Pervunina T, Skorobogatova Y, Volkova S, Ulyantsev V, Kalinina O, Sitkin S, Petrova N*

- 10600** *Serratia fonticola* and its role as a single pathogen causing emphysematous pyelonephritis in a non-diabetic patient: A case report

*Villasuso-Alcocer V, Flores-Tapia JP, Perez-Garfias F, Rochel-Perez A, Mendez-Dominguez N*

- 10606** Cardiac myxoma shedding leads to lower extremity arterial embolism: A case report

*Meng XH, Xie LS, Xie XP, Liu YC, Huang CP, Wang LJ, Zhang GH, Xu D, Cai XC, Fang X*

- 10614** Extracorporeal membrane oxygenation in curing a young man after modified Fontan operation: A case report  
*Guo HB, Tan JB, Cui YC, Xiong HF, Li CS, Liu YF, Sun Y, Pu L, Xiang P, Zhang M, Hao JJ, Yin NN, Hou XT, Liu JY*
- 10622** Wandering small intestinal stromal tumor: A case report  
*Su JZ, Fan SF, Song X, Cao LJ, Su DY*
- 10629** Acute mesenteric ischemia secondary to oral contraceptive-induced portomesenteric and splenic vein thrombosis: A case report  
*Zhao JW, Cui XH, Zhao WY, Wang L, Xing L, Jiang XY, Gong X, Yu L*
- 10638** Perioperative anesthesia management in pediatric liver transplant recipient with atrial septal defect: A case report  
*Liu L, Chen P, Fang LL, Yu LN*
- 10647** Multiple tophi deposits in the spine: A case report  
*Chen HJ, Chen DY, Zhou SZ, Chi KD, Wu JZ, Huang FL*
- 10655** Myeloproliferative neoplasms complicated with  $\beta$ -thalassemia: Two case report  
*Xu NW, Li LJ*
- 10663** Synchronous renal pelvis carcinoma associated with small lymphocytic lymphoma: A case report  
*Yang HJ, Huang X*
- 10670** *Leclercia adecarboxylata* infective endocarditis in a man with mitral stenosis: A case report and review of the literature  
*Tan R, Yu JQ, Wang J, Zheng RQ*
- 10681** Progressive ataxia of cerebrotendinous xanthomatosis with a rare c.255+1G>T splice site mutation: A case report  
*Chang YY, Yu CQ, Zhu L*
- 10689** Intravesical explosion during transurethral resection of bladder tumor: A case report  
*Xu CB, Jia DS, Pan ZS*
- 10695** Submucosal esophageal abscess evolving into intramural submucosal dissection: A case report  
*Jiao Y, Sikong YH, Zhang AJ, Zuo XL, Gao PY, Ren QG, Li RY*
- 10701** Immune checkpoint inhibitor-associated arthritis in advanced pulmonary adenocarcinoma: A case report  
*Yang Y, Huang XJ*
- 10708** Chondroid syringoma of the lower back simulating lipoma: A case report  
*Huang QF, Shao Y, Yu B, Hu XP*
- 10713** Tension-reduced closure of large abdominal wall defect caused by shotgun wound: A case report  
*Li Y, Xing JH, Yang Z, Xu YJ, Yin XY, Chi Y, Xu YC, Han YD, Chen YB, Han Y*

- 10721** Myocardial bridging phenomenon is not invariable: A case report  
*Li HH, Liu MW, Zhang YF, Song BC, Zhu ZC, Zhao FH*
- 10728** Recurrent atypical leiomyoma in bladder trigone, confused with uterine fibroids: A case report  
*Song J, Song H, Kim YW*
- 10735** Eczema herpeticum *vs* dermatitis herpetiformis as a clue of dedicator of cytokinesis 8 deficiency diagnosis: A case report  
*Alshengeti A*
- 10742** Cutaneous allergic reaction to subcutaneous vitamin K<sub>1</sub>: A case report and review of literature  
*Zhang M, Chen J, Wang CX, Lin NX, Li X*
- 10755** Perithyroidal hemorrhage caused by hydrodissection during radiofrequency ablation for benign thyroid nodules: Two case reports  
*Zheng BW, Wu T, Yao ZC, Ma YP, Ren J*
- 10763** Malignant giant cell tumors of the tendon sheath of the right hip: A case report  
*Huang WP, Gao G, Yang Q, Chen Z, Qiu YK, Gao JB, Kang L*
- 10772** Atypical Takotsubo cardiomyopathy presenting as acute coronary syndrome: A case report  
*Wang ZH, Fan JR, Zhang GY, Li XL, Li L*
- 10779** Secondary light chain amyloidosis with Waldenström's macroglobulinemia and internodal marginal zone lymphoma: A case report  
*Zhao ZY, Tang N, Fu XJ, Lin LE*
- 10787** Bilateral occurrence of sperm granulomas in the left spermatic cord and on the right epididymis: A case report  
*Ly DY, Xie HJ, Cui F, Zhou HY, Shuang WB*
- 10794** Glucocorticoids combined with tofacitinib in the treatment of Castleman's disease: A case report  
*Liu XR, Tian M*
- 10803** Giant bilateral scrotal lipoma with abnormal somatic fat distribution: A case report  
*Chen Y, Li XN, Yi XL, Tang Y*
- 10811** Elevated procalcitonin levels in the absence of infection in procalcitonin-secreting hepatocellular carcinoma: A case report  
*Zeng JT, Wang Y, Wang Y, Luo ZH, Qing Z, Zhang Y, Zhang YL, Zhang JF, Li DW, Luo XZ*

**LETTER TO THE EDITOR**

- 10817** "Helicobacter pylori treatment guideline: An Indian perspective": Letter to the editor  
*Swarnakar R, Yadav SL*
- 10820** Effect of gender on the reliability of COVID-19 rapid antigen test among elderly  
*Nori W, Akram W*

**ABOUT COVER**

Editorial Board Member of *World Journal of Clinical Cases*, Natalia Stepanova, DSc, MD, PhD, Academic Research, Chief Doctor, Full Professor, Department of Nephrology and Dialysis, State Institution "Institute of Nephrology of the National Academy of Medical Sciences of Ukraine", Kyiv 04050, Ukraine. nmstep88@gmail.com

**AIMS AND SCOPE**

The primary aim of *World Journal of Clinical Cases* (WJCC, *World J Clin Cases*) is to provide scholars and readers from various fields of clinical medicine with a platform to publish high-quality clinical research articles and communicate their research findings online.

WJCC mainly publishes articles reporting research results and findings obtained in the field of clinical medicine and covering a wide range of topics, including case control studies, retrospective cohort studies, retrospective studies, clinical trials studies, observational studies, prospective studies, randomized controlled trials, randomized clinical trials, systematic reviews, meta-analysis, and case reports.

**INDEXING/ABSTRACTING**

The WJCC is now abstracted and indexed in Science Citation Index Expanded (SCIE, also known as SciSearch®), Journal Citation Reports/Science Edition, Current Contents®/Clinical Medicine, PubMed, PubMed Central, Scopus, Reference Citation Analysis, China National Knowledge Infrastructure, China Science and Technology Journal Database, and Superstar Journals Database. The 2022 Edition of Journal Citation Reports® cites the 2021 impact factor (IF) for WJCC as 1.534; IF without journal self cites: 1.491; 5-year IF: 1.599; Journal Citation Indicator: 0.28; Ranking: 135 among 172 journals in medicine, general and internal; and Quartile category: Q4. The WJCC's CiteScore for 2021 is 1.2 and Scopus CiteScore rank 2021: General Medicine is 443/826.

**RESPONSIBLE EDITORS FOR THIS ISSUE**

Production Editor: Hua-Ge Yin; Production Department Director: Xiang Li; Editorial Office Director: Jin-Lei Wang.

**NAME OF JOURNAL**

*World Journal of Clinical Cases*

**ISSN**

ISSN 2307-8960 (online)

**LAUNCH DATE**

April 16, 2013

**FREQUENCY**

Thrice Monthly

**EDITORS-IN-CHIEF**

Bao-Gan Peng, Jerzy Tadeusz Chudek, George Kontogeorgos, Maurizio Serati, Ja Hyeon Ku

**EDITORIAL BOARD MEMBERS**

<https://www.wjgnet.com/2307-8960/editorialboard.htm>

**PUBLICATION DATE**

October 16, 2022

**COPYRIGHT**

© 2022 Baishideng Publishing Group Inc

**INSTRUCTIONS TO AUTHORS**

<https://www.wjgnet.com/bpg/gerinfo/204>

**GUIDELINES FOR ETHICS DOCUMENTS**

<https://www.wjgnet.com/bpg/GerInfo/287>

**GUIDELINES FOR NON-NATIVE SPEAKERS OF ENGLISH**

<https://www.wjgnet.com/bpg/gerinfo/240>

**PUBLICATION ETHICS**

<https://www.wjgnet.com/bpg/GerInfo/288>

**PUBLICATION MISCONDUCT**

<https://www.wjgnet.com/bpg/gerinfo/208>

**ARTICLE PROCESSING CHARGE**

<https://www.wjgnet.com/bpg/gerinfo/242>

**STEPS FOR SUBMITTING MANUSCRIPTS**

<https://www.wjgnet.com/bpg/GerInfo/239>

**ONLINE SUBMISSION**

<https://www.f6publishing.com>



## Novel way of patent foramen ovale detection and percutaneous closure by intracardiac echocardiography: A case report

Kang-Ning Han, Shi-Wei Yang, Yu-Jie Zhou

**Specialty type:** Medicine, research and experimental

**Provenance and peer review:** Unsolicited article; Externally peer reviewed

**Peer-review model:** Single blind

**Peer-review report's scientific quality classification**

Grade A (Excellent): 0  
Grade B (Very good): B, B  
Grade C (Good): C  
Grade D (Fair): 0  
Grade E (Poor): 0

**P-Reviewer:** Caiati C, Italy; Gupta P, United States

**Received:** May 12, 2022

**Peer-review started:** May 12, 2022

**First decision:** July 14, 2022

**Revised:** July 17, 2022

**Accepted:** September 7, 2022

**Article in press:** September 7, 2022

**Published online:** October 16, 2022



**Kang-Ning Han, Shi-Wei Yang, Yu-Jie Zhou,** Department of Cardiology, Beijing Anzhen Hospital, Capital Medical University, Beijing 100029, China

**Corresponding author:** Yu-Jie Zhou, PhD, Doctor, Professor, Department of Cardiology, Beijing Anzhen Hospital, Capital Medical University, No.2 Anzhen Road, Chaoyang District, Beijing 100029, China. [azzyj12@163.com](mailto:azzyj12@163.com)

### Abstract

#### BACKGROUND

Patent foramen ovale (PFO) is the most common congenital heart disease and is associated with several diseases, including stroke and migraine. PFO diagnosis involves transoesophageal echocardiography, transthoracic echocardiography, and transcranial Doppler. Recent studies have shown that intracardiac echocardiography (ICE) can be used to diagnose and guide percutaneous transcatheter closure.

#### CASE SUMMARY

A 70-year-old male presented with paroxysmal dizziness and limb weakness for the past 3 mo. Magnetic resonance imaging revealed a history of stroke, and a bubble test revealed the presence of PFO. The patient was then transferred to our hospital for PFO closure. Under ICE guidance, the separation of the septum primum and septum secundum was unclear; we then used a Swartz catheter to confirm PFO by applying physical pressure on the right part of the atrial septum without using any contrast. The ICE continuously and clearly guided the procedure.

#### CONCLUSION

ICE can guide PFO closure in patients with a history of stroke. When PFO is not evident under ICE, a Swartz catheter can be used.

**Key Words:** Intracardiac echocardiography; Patent foramen ovale; Percutaneous patent foramen ovale closure; Case report

©The Author(s) 2022. Published by Baishideng Publishing Group Inc. All rights reserved.



**Core Tip:** Patent foramen ovale (PFO) is the most common congenital heart disease and is associated with several diseases, including stroke and migraine. PFO diagnosis involves transoesophageal echocardiography, transthoracic echocardiography, and transcranial Doppler. Recent studies have shown that intracardiac echocardiography (ICE) can be used to diagnose and guide percutaneous transcatheter closure. Here, we represent the use of ICE in PFO detection and closure for PFO patient with a history of stroke. Importantly, when PFO is unobvious, Swartz catheter can be used to physically separate the septum primum and septum secundum.

**Citation:** Han KN, Yang SW, Zhou YJ. Novel way of patent foramen ovale detection and percutaneous closure by intracardiac echocardiography: A case report. *World J Clin Cases* 2022; 10(29): 10559-10564

**URL:** <https://www.wjgnet.com/2307-8960/full/v10/i29/10559.htm>

**DOI:** <https://dx.doi.org/10.12998/wjcc.v10.i29.10559>

## INTRODUCTION

Patent foramen ovale (PFO) caused by failed fusion of the septum primum and septum secundum is the most common congenital heart disease and is present in approximately 25% of the general population [1]. Although most patients with PFO are asymptomatic, many studies have shown that PFO is implicated in diseases including migraine and decompression illness [2]. PFO may cause cryptogenic stroke, especially when accompanied by deep venous thrombosis and other structural abnormalities, which could be explained by the hypothesis that thrombi from the right heart system can directly pass the PFO to the left atrium when the pressure of the right heart increases [3]. However, the association between PFO and cryptogenic stroke remains unclear because the only one prospective longitudinal study has shown a negative result [1]. The Food and Drug Administration approved the use of percutaneous transcatheter closure (PTC) for PFO because closure can significantly decrease the rate of recurrent stroke. Furthermore, the Society for Cardiovascular Angiography and Interventions (SCAI) guidelines recommend PFO closure in patients with prior PFO-associated stroke [4]. PFO diagnosis involves transoesophageal echocardiography (TEE), transthoracic echocardiography (TTE), transcranial Doppler (TCD), and intracardiac echocardiography (ICE) [5]. TEE, with its relatively high resolution, was once considered the gold standard. Recently, a study has demonstrated the advantages of ICE in diagnosing and guiding PTC, including having higher resolution, the flexibility of obtaining multi-angle images, continuous guidance during the procedure, avoidance of general anaesthesia, and the capability of detecting other abnormalities [6]. Here, we shared one case of ICE use in diagnosis and PTC in a patient who had previously undergone cryptogenic stroke. We showed that if the PFO is not obvious, a Swartz catheter can be used.

## CASE PRESENTATION

### Chief complaints

A 70-year-old male presented with paroxysmal dizziness and limb weakness for the past 3 mo.

### History of present illness

Three months ago, the patient got a sudden paroxysmal dizziness and limb weakness. Two months prior, the patient experienced more severe dizziness, weakness, vomiting, and nausea. Then, the patient was admitted to our hospital.

### History of past illness

The patient has no history of hypertension, diabetes, hyperlipidaemia, coronary artery disease, or atrial fibrillation.

### Personal and family history

The patient had a 50-year smoking history (30 cigarettes per day). No family history.

### Physical examination

The patient has a muscular weakness of limbs.

### Laboratory examinations

Laboratory tests showed that the hemoglobin A1c level was 6.2% and fasting plasma glucose was 7.47



mmol/L.

### Imaging examinations

Three months prior, magnetic resonance imaging (MRI) of the local hospital showed remote cerebral infarction. Two months ago, MRI showed right cerebellar hemisphere infarction with local hemosiderin deposition. Echocardiography revealed ascending aortic enlargement, and the left ventricular ejection fraction was 59%. Bubble test of the right atrium indicated PFO.

## FINAL DIAGNOSIS

Final diagnosis is PFO.

## TREATMENT

PTC was then indicated according to the symptoms and examination findings[7]. Afterwards, we proceeded with the PFO confirmation using ICE. Firstly, the ICE catheter (Johnson & Johnson Medical, United States) was advanced into the right atrium from the left femoral vein, under fluoroscopic guidance. In the “home view”, the right atrium, right ventricle, tricuspid valve, and long axis of the right ventricular outflow tract can be observed (Figure 1A). Subsequently, by flexing the ICE catheter posteriorly and slightly tilting rightward, the transducer directly faced the interatrial septum, and the entire length of the interatrial septum became visible. However, we could not find the separation of the septum primum and septum secundum, even with the assistance of the colour Doppler test. Fortunately, PFO was confirmed using an 8.5 F Swartz sheath (Abbott, United States). The Swartz sheath was advanced into the inferior vena cava through the right femoral vein, and then to the right side of the interatrial septum. Then, by applying slight physical pressure on the right side of the interatrial septum, the septum primum was manually separated from septum secundum, which can avoid the use of aerated saline contrast and Valsalva maneuver (Figures 1B and 2A). Colour Doppler imaging confirmed right-to-left shunting (Figure 2B).

After careful measurement of the PFO and surrounding rims, the PTC procedure was performed and an Amplatzer PFO occluder (St. Jude Medical, United States) was implanted. The distal disk of the occluding device was first deployed in the left atrium through the withdrawal of the sheath (Figure 1C). The device and sheath were then pulled back against the atrial septum. When the left disk was in close contact with the septum, the right atrial disk of the occluding device was deployed *via* further sheath withdrawal (Figure 1D). After deployment, the position of the device was confirmed by ICE (Figure 2C), and the colour Doppler was used to ensure that there were no residual leaks (Figure 2D).

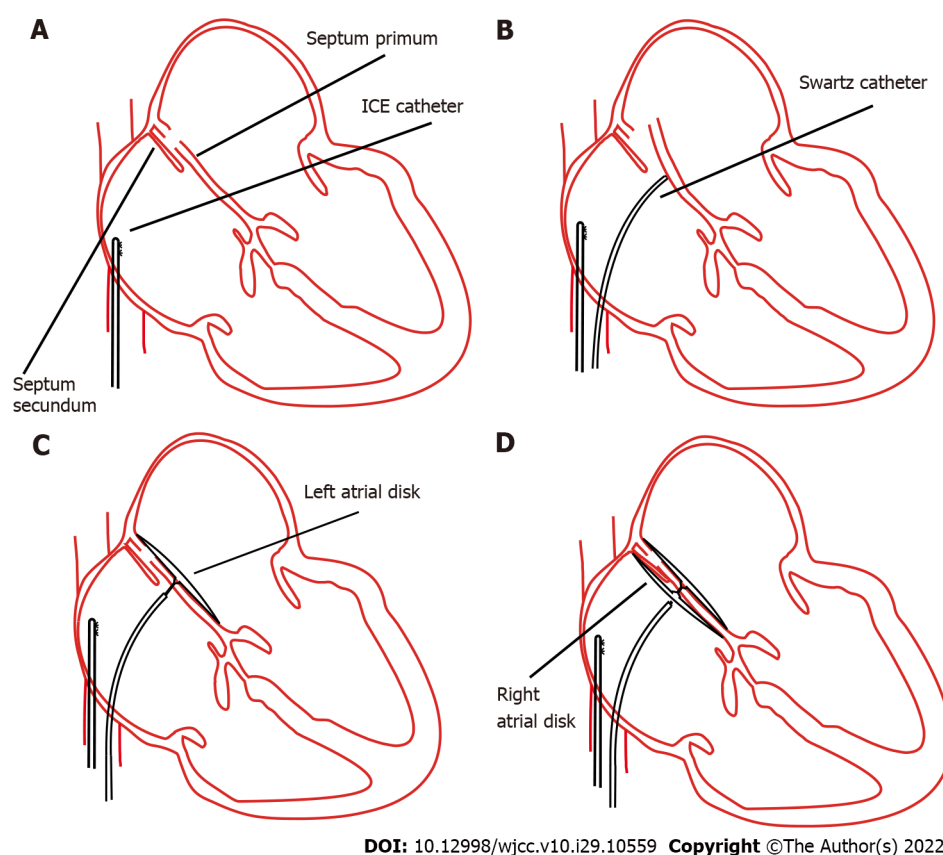
## OUTCOME AND FOLLOW-UP

The patient experienced no complications during the procedure. Three months later, the frequency and degree of dizziness significantly decreased. Furthermore, the patient did not have recurrent stroke, and his subjective quality of life improved.

## DISCUSSION

The association between PFO and stroke has not yet been consolidated. Our patient had a history of cryptogenic stroke, and according to the SCAI guidelines, we recommended performing PFO closure to prevent stroke. However, closure is fraught with possible complications during follow-up. Patients may develop complications, including arrhythmia, thrombus formation on the surface of the device, and even chest pain. Therefore, it is important to fully evaluate whether patients should undergo PFO closure, and long-term follow-up is needed.

As shown in previous studies, even though TEE was once considered the gold standard for detecting PFO, it has some limitations for diagnosis and PTC when compared to ICE. In our case, we demonstrated the detailed application of ICE to confirm PFO and guide PTC. Previous studies have shown that compared to TEE, ICE can find more abnormalities, including the Chiari network and atrial myxoma[8]. ICE can be used to easily visualise the posterior and inferior rims of the interatrial septum. Additionally, ICE can help visualise clinical problems such as lead endocarditis masses and post-lead extraction floating masses inside the right atrial chamber[9,10]. Moreover, TEE reportedly misses the diagnosis in approximately 10% of patients[11]. Furthermore, compared to TEE, ICE does not require general anaesthesia, an oesophageal probe, or assistance from an additional sonographer. Therefore,

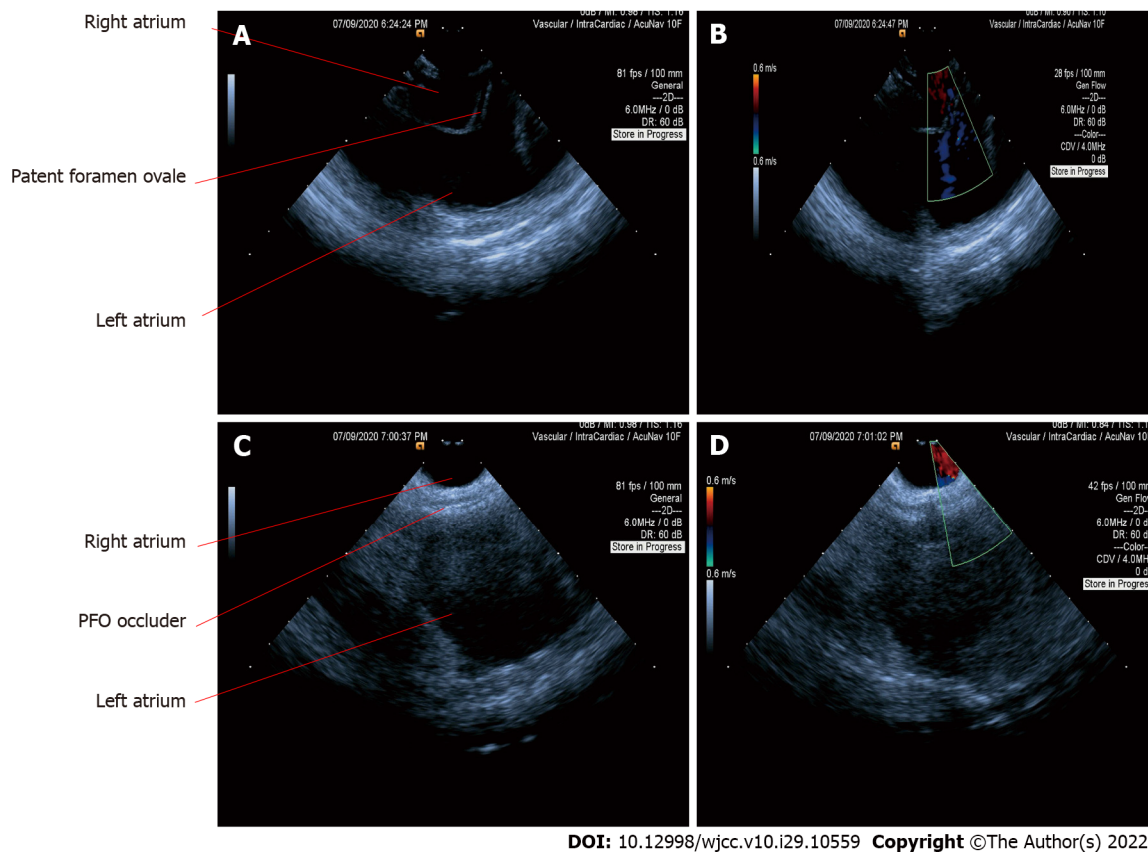


**Figure 1** Concept procedures for percutaneous patent foramen ovale closure through intracardiac echocardiography guidance. A: The intracardiac echocardiography catheter was advanced into the right atrium; B: The septum primum was artificially separated from the septum secundum by applying physical pressure using a Swartz sheath; C: Deployment of the right atrial disk; D: Complete deployment of right and left side disks. ICE: Intracardiac echocardiography.

complications related to general anaesthesia and intubation can be avoided, and interventional cardiologists can perform both the imaging and catheterisation procedures. In addition, it is difficult for the patients to do the Valsalva manoeuvre using TEE. When using ICE, a cardiologist can directly and efficiently obtain ideal images, which can decrease the operation and fluoroscopy time[12]. ICE can also be used to detect residual shunting immediately after PTC[13]. It can directly monitor procedure-related complications such as thrombus formation and pericardial effusion.

Although ICE can directly visualise the PFO and separation of the septum primum from the septum secundum or can be supported by a colour Doppler (Figures 2A and 2B), most PFO is asymptomatic and shunting may only occur when the right heart pressure increases. Therefore, it is necessary to manually create shunting. In our case, we used a Swartz sheath to further confirm PFO by manually applying physical pressure on the interatrial septum. To the best of our knowledge, the present study is the first to use a Swartz sheath. Previous studies used aerated saline bubbles assisted by the Valsalva manoeuvre or by coughing to increase right heart pressure and create shunting of the contrast. However, if the PFO is not apparent, the efficacy of the Valsalva manoeuvre or coughing becomes low; moreover, these approaches cannot be performed under general sedation. Furthermore, a study showed that saline contrast may cause cerebral ischaemic events[14]; therefore, our method could be safer. In patients who require atrial septal puncture, the Swartz sheath can be used for both detection and puncture without additional expense.

ICE can fully evaluate the surrounding structures, confirm that there are no other abnormalities, and measure the rims of PFO. It can also provide continuous guidance for septal puncture and closure deployment. Other diagnostic methods for PFO include TTE and TCD. TTE is the most commonly used method for the initial diagnosis, but this approach has relatively lower sensitivity. TCD can indirectly detect PFO by detecting shunting between the left and right atria, and its sensitivity is between those of TTE and TEE[15]. However, because TCD cannot directly observe shunting in the atrium, it can be difficult to distinguish between PFO, atrial septal defects, and intrapulmonary shunts. Although the sensitivities of TTE and TCD are lower than those of TEE and ICE, they are convenient and non-invasive. Therefore, we hypothesised that TTE and TCD can be used to screen for PFO. If the screening result is positive and the patient has a history of stroke, PFO closure and ICE will be the first choice. If the screening result is positive and the patient has no history of stroke, the patient needs to be followed up regularly because some PFO could automatically close with ageing.



DOI: 10.12998/wjcc.v10.i29.10559 Copyright ©The Author(s) 2022.

**Figure 2** Intracardiac echocardiography images in the diagnosis and closure of patent foramen ovale. A: Separation of the septum primum and septum secundum through a Swartz sheath; B: Patent foramen ovale (PFO) was confirmed using a colour Doppler; C: The septum primum and septum secundum were fixed together after complete deployment of right and left side disks; D: Confirmation of PFO closure using a colour Doppler. PFO: Patent foramen ovale.

## CONCLUSION

Detection and closure of PFO are of utmost significance. Here, we presented the use of ICE for PFO detection and closure in a patient with a history of stroke. More importantly, we demonstrated that when the PFO is not obvious, a Swartz catheter can be used to physically separate the septum primum and septum secundum.

## FOOTNOTES

**Author contributions:** Han KN drafted the manuscript; Yang SW and Zhou YJ interpreted and revised the manuscript; and all authors read and approved the final manuscript.

**Supported by** the National Key Research and Development Program of China, No. 2017YFC0908800.

**Informed consent statement:** Written informed consent was obtained from the patient for publication of this case report and any accompanying images.

**Conflict-of-interest statement:** All the authors report no relevant conflicts of interest for this article.

**CARE Checklist (2016) statement:** The authors have read the CARE Checklist (2016), and the manuscript was prepared and revised according to the CARE Checklist (2016).

**Open-Access:** This article is an open-access article that was selected by an in-house editor and fully peer-reviewed by external reviewers. It is distributed in accordance with the Creative Commons Attribution NonCommercial (CC BY-NC 4.0) license, which permits others to distribute, remix, adapt, build upon this work non-commercially, and license their derivative works on different terms, provided the original work is properly cited and the use is non-commercial. See: <https://creativecommons.org/licenses/by-nc/4.0/>

**Country/Territory of origin:** China

**ORCID number:** Kang-Ning Han 0000-0001-6603-1895; Shi-Wei Yang 0000-0002-6603-5746; Yu-Jie Zhou 0000-0002-9545-1984.

**Corresponding Author's Membership in Professional Societies:** Beijing Municipal Administration of Hospitals' Mission plan, SML20180601.

**S-Editor:** Wang JJ

**L-Editor:** A

**P-Editor:** Wang JJ

## REFERENCES

- 1 **Meissner I**, Khandheria BK, Heit JA, Petty GW, Sheps SG, Schwartz GL, Whisnant JP, Wiebers DO, Covalt JL, Petterson TM, Christianson TJ, Agmon Y. Patent foramen ovale: innocent or guilty? *J Am Coll Cardiol* 2006; **47**: 440-445 [PMID: 16412874 DOI: 10.1016/j.jacc.2005.10.044]
- 2 **Johansson MC**, Eriksson P, Dellborg M. The significance of patent foramen ovale: a current review of associated conditions and treatment. *Int J Cardiol* 2009; **134**: 17-24 [PMID: 19232760 DOI: 10.1016/j.ijcard.2009.01.049]
- 3 **Zietz A**, Sutter R, De Marchis GM. Deep Vein Thrombosis and Pulmonary Embolism Among Patients With a Cryptogenic Stroke Linked to Patent Foramen Ovale-A Review of the Literature. *Front Neurol* 2020; **11**: 336 [PMID: 32431661 DOI: 10.3389/fneur.2020.00336]
- 4 **Kavinsky CJ**, Szerlip M, Goldsweig AM, Falck-Ytter Y, Babatunde I, Morgan RL, Amin Z, Boudoulas KD, Carroll JD. SCAI Guidelines for the Management of Patent Foramen Ovale. *J Soc Cardiovasc Angiogr Interv* 2022; **1**: 100039 [DOI: 10.1016/j.jscvi.2022.100039]
- 5 **Homma S**, Messé SR, Rundek T, Sun YP, Franke J, Davidson K, Sievert H, Sacco RL, Di Tullio MR. Patent foramen ovale. *Nat Rev Dis Primers* 2016; **2**: 15086 [PMID: 27188965 DOI: 10.1038/nrdp.2015.86]
- 6 **Kavvouras C**, Vavuranakis M, Vaina S, Lampropoulos K, Bazoukis G, Tse G, Tousoulis D. Intracardiac echocardiography for percutaneous patent foramen ovale and atrial septal defect occlusion. *Herz* 2019; **44**: 445-449 [PMID: 29374291 DOI: 10.1007/s00059-017-4678-7]
- 7 **Farb A**, Ibrahim NG, Zuckerman BD. Patent Foramen Ovale after Cryptogenic Stroke - Assessing the Evidence for Closure. *N Engl J Med* 2017; **377**: 1006-1009 [PMID: 28902595 DOI: 10.1056/NEJMp1700218]
- 8 **Bartel T**, Konorza T, Arjumand J, Ebradlidge T, Eggebrecht H, Caspari G, Neudorf U, Erbel R. Intracardiac echocardiography is superior to conventional monitoring for guiding device closure of interatrial communications. *Circulation* 2003; **107**: 795-797 [PMID: 12591745 DOI: 10.1161/01.CIR.0000057547.00909.1C]
- 9 **Caiati C**, Luzzi G, Pollice P, Favale S, Lepera ME. A Novel Clinical Perspective on New Masses after Lead Extraction (Ghosts) by Means of Intracardiac Echocardiography. *J Clin Med* 2020; **9** [PMID: 32784437 DOI: 10.3390/JCM9082571]
- 10 **Caiati C**, Pollice P, Lepera ME, Favale S. Pacemaker Lead Endocarditis Investigated with Intracardiac Echocardiography: Factors Modulating the Size of Vegetations and Larger Vegetation Embolic Risk during Lead Extraction. *Antibiotics (Basel)* 2019; **8**: 228 [PMID: 31752363 DOI: 10.3390/antibiotics8040228]
- 11 **Augoustides JG**, Weiss SJ, Weiner J, Mancini J, Savino JS, Cheung AT. Diagnosis of patent foramen ovale with multiplane transesophageal echocardiography in adult cardiac surgical patients. *J Cardiothorac Vasc Anesth* 2004; **18**: 725-730 [PMID: 15650981 DOI: 10.1053/j.jvca.2004.08.009]
- 12 **Boccalandro F**, Baptista E, Muench A, Carter C, Smalling RW. Comparison of intracardiac echocardiography versus transesophageal echocardiography guidance for percutaneous transcatheter closure of atrial septal defect. *Am J Cardiol* 2004; **93**: 437-440 [PMID: 14969617 DOI: 10.1016/j.amjcard.2003.10.037]
- 13 **Mahmoud AN**, Elgendy IY, Agarwal N, Tobis JM, Mojaidi MK. Identification and Quantification of Patent Foramen Ovale-Mediated Shunts: Echocardiography and Transcranial Doppler. *Interv Cardiol Clin* 2017; **6**: 495-504 [PMID: 28886841 DOI: 10.1016/j.iccl.2017.05.002]
- 14 **Romero JR**, Frey JL, Schwamm LH, Demaerschalk BM, Chaliki HP, Parikh G, Burke RF, Babikian VL. Cerebral ischemic events associated with 'bubble study' for identification of right to left shunts. *Stroke* 2009; **40**: 2343-2348 [PMID: 19498192 DOI: 10.1161/STROKEAHA.109.549683]
- 15 **Di Tullio M**, Sacco RL, Venketasubramanian N, Sherman D, Mohr JP, Homma S. Comparison of diagnostic techniques for the detection of a patent foramen ovale in stroke patients. *Stroke* 1993; **24**: 1020-1024 [PMID: 8322376 DOI: 10.1161/01.str.24.7.1020]



Published by **Baishideng Publishing Group Inc**  
7041 Koll Center Parkway, Suite 160, Pleasanton, CA 94566, USA

**Telephone:** +1-925-3991568

**E-mail:** [bpgoffice@wjgnet.com](mailto:bpgoffice@wjgnet.com)

**Help Desk:** <https://www.f6publishing.com/helpdesk>

<https://www.wjgnet.com>

