

World Journal of *Clinical Cases*

World J Clin Cases 2022 July 16; 10(20): 6759-7186



Contents

Thrice Monthly Volume 10 Number 20 July 16, 2022

OPINION REVIEW

- 6759 Semaglutide might be a key for breaking the vicious cycle of metabolically associated fatty liver disease spectrum?

Cigrovski Berkovic M, Rezić T, Bilic-Curcic I, Mrzljak A

MINIREVIEWS

- 6769 Drainage of pancreatic fluid collections in acute pancreatitis: A comprehensive overview
Bansal A, Gupta P, Singh AK, Shah J, Samanta J, Mandavdhare HS, Sharma V, Sinha SK, Dutta U, Sandhu MS, Kochhar R

- 6784 Frontiers of COVID-19-related myocarditis as assessed by cardiovascular magnetic resonance

Luo Y, Liu BT, Yuan WF, Zhao CX

ORIGINAL ARTICLE

Case Control Study

- 6794 Urinary and sexual function changes in benign prostatic hyperplasia patients before and after transurethral columnar balloon dilatation of the prostate

Zhang DP, Pan ZB, Zhang HT

- 6803 Effects of the information-knowledge-attitude-practice nursing model combined with predictability intervention on patients with cerebrovascular disease

Huo HL, Gui YY, Xu CM, Zhang Y, Li Q

Retrospective Cohort Study

- 6811 Effects of Kampo medicine hangebyakujutsutemmato on persistent postural-perceptual dizziness: A retrospective pilot study

Miwa T, Kanemaru SI

Retrospective Study

- 6825 Longitudinal changes in personalized platelet count metrics are good indicators of initial 3-year outcome in colorectal cancer

Herold Z, Herold M, Lohinszky J, Szasz AM, Dank M, Somogyi A

- 6845 Efficacy of Kegel exercises in preventing incontinence after partial division of internal anal sphincter during anal fistula surgery

Garg P, Yagnik VD, Kaur B, Menon GR, Dawka S

Observational Study

- 6855 Influence of the water jet system vs cavitron ultrasonic surgical aspirator for liver resection on the remnant liver

Hanaki T, Tsuda A, Sunaguchi T, Goto K, Morimoto M, Murakami Y, Kihara K, Matsunaga T, Yamamoto M, Tokuyasu N, Sakamoto T, Hasegawa T, Fujiwara Y

- 6865** Critical values of monitoring indexes for perioperative major adverse cardiac events in elderly patients with biliary diseases

Zhang ZM, Xie XY, Zhao Y, Zhang C, Liu Z, Liu LM, Zhu MW, Wan BJ, Deng H, Tian K, Guo ZT, Zhao XZ

- 6876** Comparative study of surface electromyography of masticatory muscles in patients with different types of bruxism

Lan KW, Jiang LL, Yan Y

Randomized Controlled Trial

- 6890** Dural puncture epidural technique provides better anesthesia quality in repeat cesarean delivery than epidural technique: Randomized controlled study

Wang SY, He Y, Zhu HJ, Han B

SYSTEMATIC REVIEWS

- 6900** Network pharmacology-based strategy for predicting therapy targets of Sanqi and Huangjing in diabetes mellitus

Cui XY, Wu X, Lu D, Wang D

META-ANALYSIS

- 6915** Endoscopic submucosal dissection for early signet ring cell gastric cancer: A systematic review and meta-analysis

Weng CY, Sun SP, Cai C, Xu JL, Lv B

- 6927** Prognostic value of computed tomography derived skeletal muscle mass index in lung cancer: A meta-analysis

Pan XL, Li HJ, Li Z, Li ZL

CASE REPORT

- 6936** Autosomal dominant osteopetrosis type II resulting from a *de novo* mutation in the *CLCN7* gene: A case report

Song XL, Peng LY, Wang DW, Wang H

- 6944** Clinical expression and mitochondrial deoxyribonucleic acid study in twins with 14484 Leber's hereditary optic neuropathy: A case report

Chuenkongkaew WL, Chinkulkitnivat B, Lertrit P, Chirapapaisan N, Kaewsutthi S, Suktitipat B, Mitrpant C

- 6954** Management of the enteroatmospheric fistula: A case report

Cho J, Sung K, Lee D

- 6960** Lower lip recurrent keratoacanthoma: A case report

Liu XG, Liu XG, Wang CJ, Wang HX, Wang XX

- 6966** Optic disc coloboma associated with macular retinoschisis: A case report

Zhang W, Peng XY

- 6974** A 7-year-old boy with recurrent cyanosis and tachypnea: A case report
Li S, Chen LN, Zhong L
- 6981** Schwannomatosis patient who was followed up for fifteen years: A case report
Li K, Liu SJ, Wang HB, Yin CY, Huang YS, Guo WT
- 6991** Intentional replantation combined root resection therapy for the treatment of type III radicular groove with two roots: A case report
Tan D, Li ST, Feng H, Wang ZC, Wen C, Nie MH
- 6999** Clinical features and genetic variations of severe neonatal hyperbilirubinemia: Five case reports
Lin F, Xu JX, Wu YH, Ma YB, Yang LY
- 7006** Percutaneous transhepatic access for catheter ablation of a patient with heterotaxy syndrome complicated with atrial fibrillation: A case report
Wang HX, Li N, An J, Han XB
- 7013** Secondary positioning of rotationally asymmetric refractive multifocal intraocular lens in a patient with glaucoma: A case report
Fan C, Zhou Y, Jiang J
- 7020** Laparoscopic repair of diaphragmatic hernia associating with radiofrequency ablation for hepatocellular carcinoma: A case report
Tsunoda J, Nishi T, Ito T, Inaguma G, Matsuzaki T, Seki H, Yasui N, Sakata M, Shimada A, Matsumoto H
- 7029** Hypopituitary syndrome with pituitary crisis in a patient with traumatic shock: A case report
Zhang XC, Sun Y
- 7037** Solitary plasmacytoma of the left rib misdiagnosed as angina pectoris: A case report
Yao J, He X, Wang CY, Hao L, Tan LL, Shen CJ, Hou MX
- 7045** Secondary coronary artery ostial lesions: Three case reports
Liu XP, Wang HJ, Gao JL, Ma GL, Xu XY, Ji LN, He RX, Qi BYE, Wang LC, Li CQ, Zhang YJ, Feng YB
- 7054** Bladder perforation injury after percutaneous peritoneal dialysis catheterization: A case report
Shi CX, Li ZX, Sun HT, Sun WQ, Ji Y, Jia SJ
- 7060** Myotonic dystrophy type 1 presenting with dyspnea: A case report
Jia YX, Dong CL, Xue JW, Duan XQ, Xu MY, Su XM, Li P
- 7068** Novel mutation in the *SALL1* gene in a four-generation Chinese family with uraemia: A case report
Fang JX, Zhang JS, Wang MM, Liu L
- 7076** Malignant transformation of primary mature teratoma of colon: A case report
Liu J

- 7082** Treatment of pyogenic liver abscess by surgical incision and drainage combined with platelet-rich plasma: A case report
Wang JH, Gao ZH, Qian HL, Li JS, Ji HM, Da MX
- 7090** Left bundle branch pacing in a ventricular pacing dependent patient with heart failure: A case report
Song BX, Wang XX, An Y, Zhang YY
- 7097** Solitary fibrous tumor of the liver: A case report and review of the literature
Xie GY, Zhu HB, Jin Y, Li BZ, Yu YQ, Li JT
- 7105** MutL homolog 1 germline mutation c.(453+1_454-1)_(545+1_546-1)del identified in lynch syndrome: A case report and review of literature
Zhang XW, Jia ZH, Zhao LP, Wu YS, Cui MH, Jia Y, Xu TM
- 7116** Malignant histiocytosis associated with mediastinal germ cell tumor: A case report
Yang PY, Ma XL, Zhao W, Fu LB, Zhang R, Zeng Q, Qin H, Yu T, Su Y
- 7124** Immunoglobulin G4 associated autoimmune cholangitis and pancreatitis following the administration of nivolumab: A case report
Agrawal R, Guzman G, Karimi S, Giulianotti PC, Lora AJM, Jain S, Khan M, Boulay BR, Chen Y
- 7130** Portal vein thrombosis in a noncirrhotic patient after hemihepatectomy: A case report and review of literature
Zhang SB, Hu ZX, Xing ZQ, Li A, Zhou XB, Liu JH
- 7138** Microvascular decompression for a patient with oculomotor palsy caused by posterior cerebral artery compression: A case report and literature review
Zhang J, Wei ZJ, Wang H, Yu YB, Sun HT
- 7147** Topical halometasone cream combined with fire needle pre-treatment for treatment of primary cutaneous amyloidosis: Two case reports
Su YQ, Liu ZY, Wei G, Zhang CM
- 7153** Simultaneous robot-assisted approach in a super-elderly patient with urothelial carcinoma and synchronous contralateral renal cell carcinoma: A case report
Yun JK, Kim SH, Kim WB, Kim HK, Lee SW
- 7163** Nursing a patient with latent autoimmune diabetes in adults with insulin-related lipodystrophy, allergy, and exogenous insulin autoimmune syndrome: A case report
He F, Xu LL, Li YX, Dong YX
- 7171** Incidental diagnosis of medullary thyroid carcinoma due to persistently elevated procalcitonin in a patient with COVID-19 pneumonia: A case report
Saha A, Mukhopadhyay M, Paul S, Bera A, Bandyopadhyay T
- 7178** Macular hole following phakic intraocular lens implantation: A case report
Li XJ, Duan JL, Ma JX, Shang QL

LETTER TO THE EDITOR

- 7184** Is every microorganism detected in the intensive care unit a nosocomial infection? Isn't prevention more important than detection?

Yildirim F, Karaman I, Yildirim M

ABOUT COVER

Editorial Board Member of *World Journal of Clinical Cases*, Jie-Feng Huang, PhD, Associate Chief Physician, Associate Professor, Department of Orthopaedics and Traumatology, The First Affiliated Hospital of Zhejiang Chinese Medical University, Hangzhou 310006, Zhejiang Province, China. 40983285@qq.com

AIMS AND SCOPE

The primary aim of *World Journal of Clinical Cases* (WJCC, *World J Clin Cases*) is to provide scholars and readers from various fields of clinical medicine with a platform to publish high-quality clinical research articles and communicate their research findings online.

WJCC mainly publishes articles reporting research results and findings obtained in the field of clinical medicine and covering a wide range of topics, including case control studies, retrospective cohort studies, retrospective studies, clinical trials studies, observational studies, prospective studies, randomized controlled trials, randomized clinical trials, systematic reviews, meta-analysis, and case reports.

INDEXING/ABSTRACTING

The WJCC is now abstracted and indexed in Science Citation Index Expanded (SCIE, also known as SciSearch®), Journal Citation Reports/Science Edition, Current Contents®/Clinical Medicine, PubMed, PubMed Central, Scopus, Reference Citation Analysis, China National Knowledge Infrastructure, China Science and Technology Journal Database, and Superstar Journals Database. The 2022 Edition of Journal Citation Reports® cites the 2021 impact factor (IF) for WJCC as 1.534; IF without journal self cites: 1.491; 5-year IF: 1.599; Journal Citation Indicator: 0.28; Ranking: 135 among 172 journals in medicine, general and internal; and Quartile category: Q4. The WJCC's CiteScore for 2021 is 1.2 and Scopus CiteScore rank 2021: General Medicine is 443/826.

RESPONSIBLE EDITORS FOR THIS ISSUE

Production Editor: *Hua-Ge Yin*; Production Department Director: *Xu Guo*; Editorial Office Director: *Jin-Lei Wang*.

NAME OF JOURNAL

World Journal of Clinical Cases

ISSN

ISSN 2307-8960 (online)

LAUNCH DATE

April 16, 2013

FREQUENCY

Thrice Monthly

EDITORS-IN-CHIEF

Bao-Gan Peng, Jerzy Tadeusz Chudek, George Kontogeorgos, Maurizio Serati, Ja Hyeon Ku

EDITORIAL BOARD MEMBERS

<https://www.wjgnet.com/2307-8960/editorialboard.htm>

PUBLICATION DATE

July 16, 2022

COPYRIGHT

© 2022 Baishideng Publishing Group Inc

INSTRUCTIONS TO AUTHORS

<https://www.wjgnet.com/bpg/gerinfo/204>

GUIDELINES FOR ETHICS DOCUMENTS

<https://www.wjgnet.com/bpg/GerInfo/287>

GUIDELINES FOR NON-NATIVE SPEAKERS OF ENGLISH

<https://www.wjgnet.com/bpg/gerinfo/240>

PUBLICATION ETHICS

<https://www.wjgnet.com/bpg/GerInfo/288>

PUBLICATION MISCONDUCT

<https://www.wjgnet.com/bpg/gerinfo/208>

ARTICLE PROCESSING CHARGE

<https://www.wjgnet.com/bpg/gerinfo/242>

STEPS FOR SUBMITTING MANUSCRIPTS

<https://www.wjgnet.com/bpg/GerInfo/239>

ONLINE SUBMISSION

<https://www.f6publishing.com>



Lower lip recurrent keratoacanthoma: A case report

Xian-Guang Liu, Xing-Guang Liu, Cai-Jiao Wang, Han-Xi Wang, Xu-Xia Wang

Specialty type: Dentistry, oral surgery and medicine

Provenance and peer review: Unsolicited article; Externally peer reviewed.

Peer-review model: Single blind

Peer-review report's scientific quality classification

Grade A (Excellent): 0
Grade B (Very good): B, B
Grade C (Good): 0
Grade D (Fair): 0
Grade E (Poor): 0

P-Reviewer: Eccher A, Italy; Rattan V, India

Received: September 26, 2021

Peer-review started: September 26, 2021

First decision: March 14, 2022

Revised: March 16, 2022

Accepted: May 26, 2022

Article in press: May 26, 2022

Published online: July 16, 2022



Xian-Guang Liu, Xing-Guang Liu, Han-Xi Wang, Xu-Xia Wang, Department of Oral and Maxillofacial Surgery, Shandong University, Jinan 250100, Shandong Province, China

Cai-Jiao Wang, Department of Oral Pathology, Shandong University, Jinan 250100, Shandong Province, China

Corresponding author: Xu-Xia Wang, Doctor, Department of Oral and Maxillofacial Surgery, Shandong University, No. 44-1 Wenhua West Road, Jinan 250012, Shandong Province, China. wangxuxia2021@163.com

Abstract

BACKGROUND

This paper introduces a case of recurrent keratoacanthoma (KA). KA is a self-healing disease. Recurrence after surgical resection is rare. In this case, the local application of retinoic acid ointment after the second operation achieved a good prognosis after 2 years of follow-up.

CASE SUMMARY

A 76-year-old male patient was admitted to the hospital for "lower lip rupture and scab for 3 mo". Treatment: A rectangular incision was made in the healthy tissue about 3 mm outside the periphery of the lower lip mass, and a modified Bernard sliding flap was designed to completely remove the mass. Pathology showed (lower lip) KA. When the patient returned 6 mo after surgery, the middle mucosa of the lower lip had a bulge with a diameter of about 0.5 cm. The boundary was still clear, the surface was ulcerated. A recurrence of lower lip KA was suspected and a fan-shaped incision was performed in the healthy tissue about 5 mm outside the lesion to completely resect. Pathological showed lower lip KA had recurred. Topical application of tretinoin cream was applied once a day for 3 mo. The lower lip wounds were clean at the 2-year postoperative follow-up and the mucosa was normal.

CONCLUSION

Adjuvant retinoic acid treatment after KA surgical resection can achieve good results.

Key Words: Keratoacanthoma; Lower lip; Squamous cell carcinoma; Clinical features; Recurrence; Case report

©The Author(s) 2022. Published by Baishideng Publishing Group Inc. All rights reserved.

Core Tip: Keratoacanthoma of the lower lip is a rare benign tumour with unique clinical and pathological characteristics which are very similar to those of well-differentiated squamous cell carcinoma of the lower lip. This article reports on an elderly male patient with recurrent lower lip keratoacanthoma, describing its clinical and pathological characteristics and treatment measures. Through reviewing the relevant literature and analysing the causes of the disease, clinical manifestations, pathological characteristics, treatment options, and causes of recurrence, it is possible to further deepen the understanding of the disease and help determine the diagnosis and treatment.

Citation: Liu XG, Liu XG, Wang CJ, Wang HX, Wang XX. Lower lip recurrent keratoacanthoma: A case report. *World J Clin Cases* 2022; 10(20): 6960-6965

URL: <https://www.wjgnet.com/2307-8960/full/v10/i20/6960.htm>

DOI: <https://dx.doi.org/10.12998/wjcc.v10.i20.6960>

INTRODUCTION

This study presents the case of an elderly male patient with recurrent lower lip keratoacanthoma (KA), describing its clinical and pathological characteristics and treatment measures. This patient experienced a recurrence of a previous KA which was successfully treated with surgical resection. Local tretinoin cream was used after the second operation. No recurrence was seen at the 2-year follow-up and the cosmetic results were excellent. We believe that our study makes a significant contribution to the literature given the similar features of KA and squamous cell carcinoma. Our case study may therefore help clinicians find features and tests to make this distinction clearer in the clinical setting. Further, KA rarely recurs. In this case, tretinoin ointment was applied locally after the second surgical resection, and no recurrence occurred. Tretinoin as an anti-keratosis drug has a good effect on preventing recurrence after KA surgery.

CASE PRESENTATION

Chief complaints

Lower lip rupture and scab for 3 mo.

History of present illness

Three months ago, the patient felt that there was a "rice grain" size ulcer on the lower lip, and local itching associated with discomfort. No treatment was given. Recent one month, the lesions have gradually increased, highlighting the mucosal surface of the lower lip, accompanied by local pain. After the application of erythromycin ointment, the pain symptoms were reduced, and the size of the lesion remained unchanged.

History of past illness

The patient was in good health, denied a history of lower lip trauma and infection, denied a history of food and drug allergy, and denied a history of family genetic disease.

Personal and family history

The patient had a smoking and drinking history of 6 cigarettes and 100 mL, respectively, for 20 years.

Physical examination

An irregular bulge with a size of about 2.0 cm × 3.0 cm could be seen in the middle of the lower lip mucosa. The boundary was still clear, the surface was irregular and rough, with yellow-white exuding scabs, some local covered blood scabs, and a hard texture. There was also local tenderness, with the outer lesion border close to the border between the lips and skin, the inner border about 1 cm away from the vestibular sulcus, and local scabs on both sides. Palpable swollen lymph nodes were detected in the submandibular area on both sides, which were movable, tender, and about 1.0 cm in diameter at most.

Laboratory examinations

A rapid pathology examination during the operation revealed that the lesion was a KA. Postoperative routine pathology showed lower lip stratified squamous epithelium hyperplasia, local enlarged epithelial spikes, malakotomosis, and a large amount of epithelial keratinization. There was also infiltr-

ration of the lamina propria by lymphocytes and plasma cells. Tip (lower lip) KA ([Figure 1](#)).

FINAL DIAGNOSIS

Lower lip recurrent keratoacanthoma.

TREATMENT

A rectangular incision was made in the healthy tissue about 3 mm outside the periphery of the lower lip mass, and a modified Bernard sliding flap was designed to completely remove the mass, then, topical application of tretinoin cream was applied once a day for 3 mo.

OUTCOME AND FOLLOW-UP

There were no abnormalities in the follow-up visits 1, 3, 6, and 12 mo postoperatively. The lower lip wounds were clean at the 2-year postoperative follow-up and the mucosa was normal.

DISCUSSION

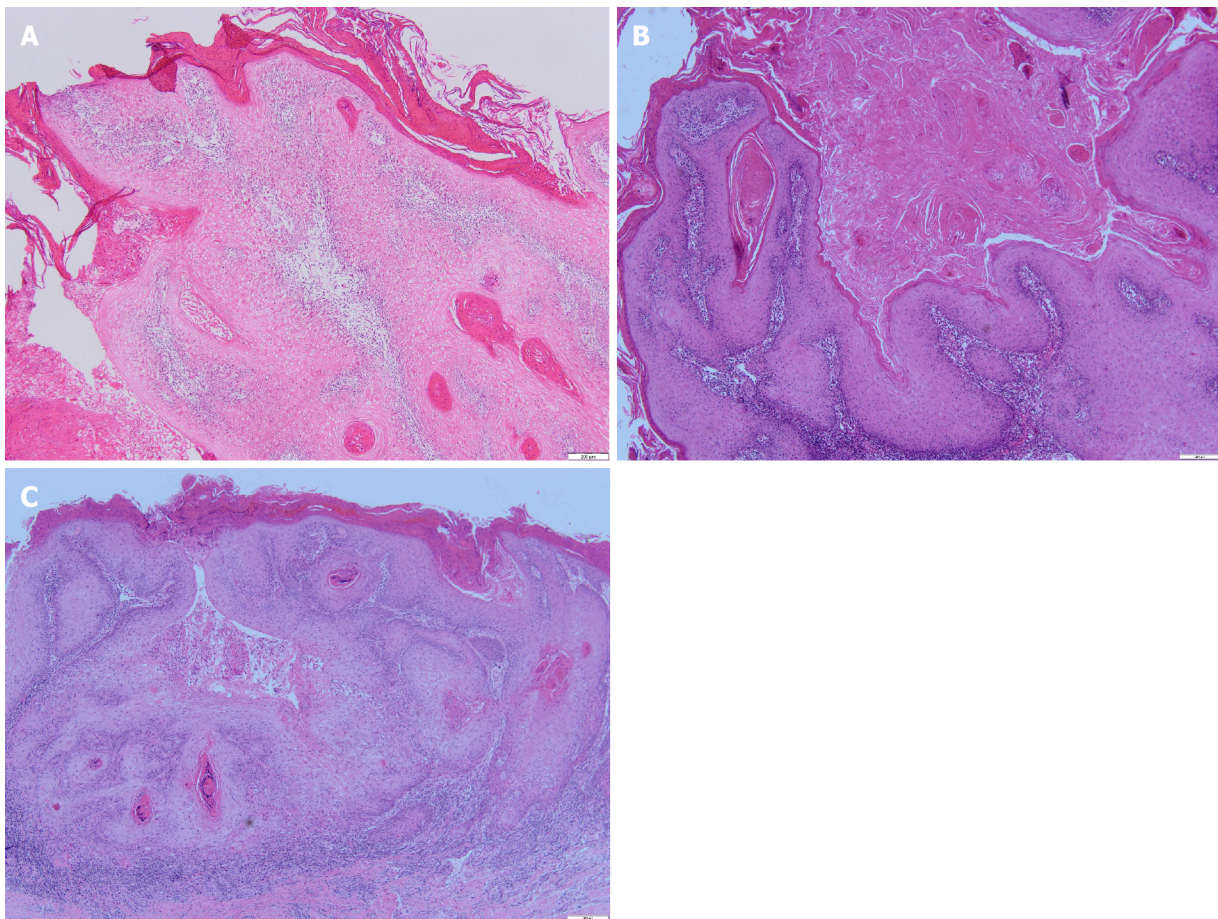
KA was first described by Jonathon Hutchinson in 1889 as a crater-like facial ulcer. In the field of skin pathology, there is no consensus on the pathological nature of KA. Although KA has clinical and histological features similar to squamous cell carcinoma (SCC), it is also considered to be a subtype of SCC, but even if KA is classified as a malignant tumour, its self-limiting nature and low likelihood of distant metastasis is very low, so that diagnosis of benign tumour is more inclined[1]. On microscopy, SCC shows pleomorphism of cells and nuclei and abnormal mitosis, which are different from KA. A large number of reports are more inclined to the biological behaviour of KA to be more like that of benign tumours[2].

The cause of KA remains unknown. Sunlight exposure and UV radiation accumulation are considered to be the main risk factors for KA[3]. Related causes include viral infections, especially human papillomavirus[2], reduced immune function[4], trauma[5], and genetic factors[6]. Ramos *et al*[7] suggested that the KA growth cycle is similar to the life cycle of hair follicles, hinting at the possibility that KA may be derived from hair follicle cells. Kamath *et al*[3] found that KA cells can differentiate into cells similar to those of the outer root sheath of hair follicles, further supporting the possibility that skin KA originates from hair follicles. Since the lip mucosa lacks the hair follicle structure of the skin, lip KA may be derived from other structures of the lip mucosa. Chauhan *et al*[8] reported that lip KA originate from ectopic sebaceous glands or surface epithelial cells. Wagner *et al*[9] analysed keratin and other related biomarkers by immunohistochemical and histochemical methods and concluded that KA tissue occurs on the outer root sheath of skin hair follicles, while in the lip mucosa it occurs in epithelial cells.

As a rare benign tumour, KA is more common in light-skinned people, and is more common in middle-aged and elderly people, especially those over 40 years old. It is more common in men, and it occurs in exposed areas, especially the head, face, and limbs, but it is rarely seen on the lips[5]. According to estimates by the World Health Organization, less than 8% of KAs occur on the lips[10]. KA is clinically divided into 4 types, the most common being the single type, while the multiple, marginal eccentric, and generalized rash types are rare. In this article, we introduce the clinical and pathological characteristics of a single case of KA of the lower lip. The clinical evolution of KA is divided into three stages: proliferation, maturation, and decomposition, which is the natural KA process of from onset to regression.

The lesions were small papules or dome-shaped nodules at first, and the central nodules were filled with keratin. Later, they formed crater-like bulges with keratinous plugs. The diameters of the lesions vary. They often grow rapidly and reach the peak size within 2 to 3 mo, after which a slow healing process starts, which lasts for more than 2-5 wk, and then the lesions gradually subside. Some lesions subside on their own within about 1 year, leaving local atrophy or a lighter pigmented scar[6]. Some scholars believe that the self-resolution of KA is related to apoptosis[11]. KA usually manifests as an isolated lesion, but it may also occur with other diseases, such as Muir-Torre syndrome[12], sebaceous nevus[13], Grzybowski syndrome[14], and cutaneous papillomatosis[6]. KA may be related to multiple system syndromes, and appropriate systemic examinations should be performed on patients with KA.

Histopathologically, the typical manifestation of KA is through tumour nodular protrusions with crater-like, lamellar, or whirlpool-like keratinous material filling inside, and epithelial cells on both sides bulging upwards in a lip or neck ring shape, and horny cysts can be seen. Insufficiency or hyperker-



DOI: 10.12998/wjcc.v10.i20.6960 Copyright ©The Author(s) 2022.

Figure 1 A rapid pathological photos, routine pathological photos during the first operation and routine pathological photos during the second operation. A: First operation HE 40×; B: First operation HE 40×; C: Second operation HE 40×.

atosis, the hyperplastic keratinocytes of the spinous layer and basal layer are pale and transparent, the cytoplasm is rich and lightly stained and has an eosinophilic ground glass-like appearance, cell proliferation is active at the bottom, and occasional cell abnormalities and pathological mitotic figures are seen at the base. There is also visible infiltration of inflammatory cells such as neutrophils, lymphocytes, and eosinophils[6,15].

Lower lip KA and SCC have very similar histopathology, making it difficult to distinguish between them. Therefore, immunohistochemistry is needed to distinguish between the two. More specifically, the expression of lectin, vascular cell adhesion molecules (CD-106), intercellular adhesion molecules (CD-54), angiotensin type 1 receptors, and syndecan-1 expression, as well as MIB-1 immunohistochemistry and ultrastructural characteristics are all helpful to distinguish KA from SCC[6].

KA is a benign tumour. Given its self-limiting biological behaviour, Ramos *et al*[7] suggest that no intervention is needed. However, since the potential size of the lesion is unpredictable, its development may affect the function of adjacent tissues and organs. If local large-scale damage is easy to continue infection, the scars remaining after the lesions subside may affect the local anatomical function and may even cause squamous cell carcinogenesis. It is clinically considered that it is not feasible to wait for KA to subside on its own. Surgical treatment is the first choice for KA[1,15]; however, surgical resection is destructive, especially when the lesion is located in an aesthetically or functionally important area. Other treatment methods such as laser treatment, radiotherapy, cryotherapy, oral tretinoin drugs, intralesional injection of methotrexate (bleomycin, Triamcinolone acetonide, 5-fluorouracil, interferon α -2a), photodynamic therapy, topical imiquimod cream, *etc.* can all be used according to the disease condition[1,8,16-18]. Laser and cryotherapy are effective for multiple KAs, especially when small, but they can cause functional and cosmetic defects and make histopathological examination impossible. Radiotherapy can be used as an adjuvant treatment to prevent recurrence after surgical treatment, but radiotherapy will increase the tendency of local tissue to become cancerous. Oral retinoic acid can be considered for patients with multiple KA or with a preventive intent after recurrent KA. Local injection of methotrexate, bleomycin, and triamcinolone acetonide can be used for lesions that cannot be surgically removed. Topical 5% imiquimod cream provides a new treatment method for patients who cannot tolerate surgical treatment and who are unwilling to receive injection treatment. Two thirds of patients can achieve good results after 4-6 wk of application, but the effects should be closely monitored

so that treatment is changed if needed[16].

In this case, the lower lip lesion tissue was surgically removed for the first time, and the lower lip KA recurred in situ 6 mo later. A second surgery was performed, and local tretinoin ointment was applied after the operation. At the 2-year follow-up visit, the lesion did not recur. Surgical resection should be the first choice for the treatment of KA, and local enlarged resection can effectively prevent recurrence. To ensure complete removal of the diseased tissue, intraoperative frozen section edge control is necessary[19]. The clinical application of Mohs microsurgery can locate the edge of the tumour, so as to more accurately remove the diseased tissue, obtain a clear edge with the smallest surgical defect, and reduce disease recurrence[20]. Hadley *et al*[21] Although KA usually subsides spontaneously, up to 20% of KA cases can show nerve, blood vessel, or intravascular invasion, which can easily lead to recurrence. Moss *et al*[17] reported that the recurrence rate of KA is about 8%. According to some studies, KA often tends to worsen each time it relapses, and it can easily transform into well-differentiated SCC[20]. In this case, the patient had the same pathological characteristics in the first and in the recurring lesion. In addition to the recurrence of KA after surgical resection, the trauma of the operation itself is also the cause of KA[21]. For recurrent KA, combined treatment measures are thus necessary, including surgical resection combined with radiotherapy and injection of triamcinolone acetonide, YAG laser combined with local injection of 5-fluorouracil, and local application of imiquimod after surgical treatment, which can achieve good results[18,22,23]. In this case, surgical resection and topical application of tretinoin cream were used for recurrent KA, which effectively prevented disease recurrence.

CONCLUSION

KA is a benign tumour with clinical and pathological features similar to those of SCC. Based on a case of recurrent lower lip KA combined with a literature review, this article summarized the clinical and pathological characteristics of lower lip KA and analysed the cause of the patient's recurrence, deepening the understanding of the disease and proving useful information for clinical diagnosis and treatment.

FOOTNOTES

Author contributions: Liu XianG, Liu XingG, Wang CJ, Wang HX designed the research study; Liu XianG, Wang CJ, Wang HX performed the research; Liu XingG, Wang XX contributed analytic tools; Liu XianG, Liu XingG, Wang CJ, Wang XX analyzed the data and wrote the manuscript; All authors have read and approve the final manuscript.

Informed consent statement: All study participants, or their legal guardian, provided informed written consent prior to study enrollment.

Conflict-of-interest statement: The authors declare that they have no conflict of interest.

CARE Checklist (2016) statement: The authors have read the CARE Checklist (2016), and the manuscript was prepared and revised according to the CARE Checklist (2016).

Open-Access: This article is an open-access article that was selected by an in-house editor and fully peer-reviewed by external reviewers. It is distributed in accordance with the Creative Commons Attribution NonCommercial (CC BY-NC 4.0) license, which permits others to distribute, remix, adapt, build upon this work non-commercially, and license their derivative works on different terms, provided the original work is properly cited and the use is non-commercial. See: <https://creativecommons.org/licenses/by-nc/4.0/>

Country/Territory of origin: China

ORCID number: Xian-Guang Liu 0000-0002-6459-0834; Xing-Guang Liu 0000-0002-0432-4147; Cai-Jiao Wang 0000-0002-6508-9291; Han-Xi Wang 0000-0002-5083-4922; Xu-Xia Wang 0000-0002-5735-6142.

S-Editor: Liu JH

L-Editor: A

P-Editor: Liu JH

REFERENCES

- 1 Liang X, Lin S, Yan J. Photodynamic therapy for keratoacanthoma on the upper lip. *Photodiagnosis Photodyn Ther* 2020; 30: 101798 [PMID: 32360853 DOI: 10.1016/j.pdpdt.2020.101798]
- 2 Savage JA, Maize JC Sr. Keratoacanthoma clinical behavior: a systematic review. *Am J Dermatopathol* 2014; 36: 422-429

- [PMID: 24366198 DOI: 10.1097/DAD.0000000000000031]
- 3 **Kamath P**, Pereira T, Chande M, Shetty S. Keratoacanthoma of the lip: A case report with emphasis on histogenesis. *J Oral Maxillofac Pathol* 2017; **21**: 115-118 [PMID: 28479697 DOI: 10.4103/jomfp.JOMFP_217_16]
 - 4 **Kulkarni RP**, Plaisier S, Ra SH, Li X, Lee DJ, Hillman JD, Binder SW. Genetic profiling of BRAF inhibitor-induced keratoacanthomas reveals no induction of MAP kinase pathway expression. *J Invest Dermatol* 2013; **133**: 830-833 [PMID: 23014342 DOI: 10.1038/jid.2012.353]
 - 5 **Pattee SF**, Silvis NG. Keratoacanthoma developing in sites of previous trauma: a report of two cases and review of the literature. *J Am Acad Dermatol* 2003; **48**: S35-S38 [PMID: 12582383 DOI: 10.1067/mjd.2003.114]
 - 6 **Schwartz RA**. Keratoacanthoma: a clinico-pathologic enigma. *Dermatol Surg* 2004; **30**: 326-33; discussion 333 [PMID: 14871228 DOI: 10.1111/j.1524-4725.2004.30080.x]
 - 7 **Ramos LM**, Cardoso SV, Loyola AM, Rocha MA, Durigetto-Júnior AF. Keratoacanthoma of the inferior lip: review and report of case with spontaneous regression. *J Appl Oral Sci* 2009; **17**: 262-265 [PMID: 19466263 DOI: 10.1590/s1678-77572009000300025]
 - 8 **Chauhan A**, Chaudhary S, Agnihotri PG, Aadithya B. A solitary crateriform ulcer of the lower lip: a case report with review of literature. *Indian J Dermatol* 2011; **56**: 435-438 [PMID: 21965859 DOI: 10.4103/0019-5154.84755]
 - 9 **Wagner VP**, Martins MD, Dillenburg CS, Meurer L, Castilho RM, Squarize CH. Histogenesis of keratoacanthoma: histochemical and immunohistochemical study. *Oral Surg Oral Med Oral Pathol Oral Radiol* 2015; **119**: 310-317 [PMID: 25488010 DOI: 10.1016/j.oooo.2014.10.006]
 - 10 **Dillenburg CS**, Martins MD, Meurer L, Castilho RM, Squarize CH. Keratoacanthoma of the Lip: Activation of the mTOR Pathway, Tumor Suppressor Proteins, and Tumor Senescence. *Medicine (Baltimore)* 2015; **94**: e1552 [PMID: 26402814 DOI: 10.1097/MD.0000000000001552]
 - 11 **Ra SH**, Su A, Li X, Zhou J, Cochran AJ, Kulkarni RP, Binder SW. Keratoacanthoma and squamous cell carcinoma are distinct from a molecular perspective. *Mod Pathol* 2015; **28**: 799-806 [PMID: 25676557 DOI: 10.1038/modpathol.2015.5]
 - 12 **Schwartz RA**, Torre DP. The Muir-Torre syndrome: a 25-year retrospect. *J Am Acad Dermatol* 1995; **33**: 90-104 [PMID: 7601953 DOI: 10.1016/0190-9622(95)90017-9]
 - 13 **Beer GM**, Widder W, Cierpka K, Kompatscher P, Meyer VE. Malignant tumors associated with nevus sebaceous: therapeutic consequences. *Aesthetic Plast Surg* 1999; **23**: 224-227 [PMID: 10384023 DOI: 10.1007/s002669900272]
 - 14 **Parry F**, Saunière D, Huertas Diaz DL, Dandurand M. [Generalized eruptive keratoacanthomas of Grzybowski: A case report followed over 11 years]. *Ann Chir Plast Esthet* 2017; **62**: 176-180 [PMID: 27427442 DOI: 10.1016/j.anplas.2016.06.006]
 - 15 **Zargarani M**, Baghaei F. A clinical, histopathological and immunohistochemical approach to the bewildering diagnosis of keratoacanthoma. *J Dent (Shiraz)* 2014; **15**: 91-97 [PMID: 25191656]
 - 16 **Pancevski G**, Pepic S, Idoska S, Tofoski G, Nikolovska S. Topical Imiquimod 5% as a Treatment Option in Solitary Facial Keratoacanthoma. *Open Access Maced J Med Sci* 2018; **6**: 531-535 [PMID: 29610614 DOI: 10.3889/oamjms.2018.133]
 - 17 **Moss M**, Weber E, Hoverson K, Montemarano AD. Management of Keratoacanthoma: 157 Tumors Treated With Surgery or Intralesional Methotrexate. *Dermatol Surg* 2019; **45**: 877-883 [PMID: 30608293 DOI: 10.1097/DSS.0000000000001739]
 - 18 **Feldmeyer L**, Szeverényi I, Mandallaz M, Lane EB, Hohl D. Late-Onset Multiple Self-Healing Squamous Epithelioma Ferguson-Smith Recurrence Induced by Radiotherapy. *Case Rep Dermatol* 2016; **8**: 344-349 [PMID: 28101021 DOI: 10.1159/000447481]
 - 19 **Donaldson MJ**, Sullivan TJ, Whitehead KJ, Williamson RM. Periocular keratoacanthoma: clinical features, pathology, and management. *Ophthalmology* 2003; **110**: 1403-1407 [PMID: 12867399 DOI: 10.1016/S0161-6420(03)00402-0]
 - 20 **Juhász MLW**, Marmur ES. A Multiple Recurrent Keratoacanthoma of the Lower Leg After Repeated Wide-Excision and Mohs Micrographic Surgery. *Dermatol Surg* 2018; **44**: 1028-1030 [PMID: 29953419 DOI: 10.1097/DSS.0000000000001422]
 - 21 **Hadley JC**, Tristani-Firouzi P, Florell SF, Bowen GM, Hadley ML. Case series of multiple recurrent reactive keratoacanthomas developing at surgical margins. *Dermatol Surg* 2009; **35**: 2019-2024 [PMID: 19758354 DOI: 10.1111/j.1524-4725.2009.01327.x]
 - 22 **Thiele JJ**, Ziemer M, Fuchs S, Elsner P. Combined 5-fluorouracil and Er:YAG laser treatment in a case of recurrent giant keratoacanthoma of the lower leg. *Dermatol Surg* 2004; **30**: 1556-1560 [PMID: 15606840 DOI: 10.1111/j.1524-4725.2004.30559.x]
 - 23 **Kurien A**, Henderson C, Lee S. Recurrent keratoacanthoma with vascular invasion: a diagnostic and management dilemma. *Australas J Dermatol* 2009; **50**: 194-197 [PMID: 19659982 DOI: 10.1111/j.1440-0960.2009.00537.x]



Published by **Baishideng Publishing Group Inc**
7041 Koll Center Parkway, Suite 160, Pleasanton, CA 94566, USA

Telephone: +1-925-3991568

E-mail: bpgoffice@wjgnet.com

Help Desk: <https://www.f6publishing.com/helpdesk>

<https://www.wjgnet.com>

