

# World Journal of *Clinical Cases*

*World J Clin Cases* 2022 April 26; 10(12): 3639-3968



## Contents

Thrice Monthly Volume 10 Number 12 April 26, 2022

## EVIDENCE REVIEW

- 3639 Tilt and decentration with various intraocular lenses: A narrative review  
*Chen XY, Wang YC, Zhao TY, Wang ZZ, Wang W*

## REVIEW

- 3647 Role of zonula occludens in gastrointestinal and liver cancers  
*Ram AK, Vairappan B*

## MINIREVIEWS

- 3662 Pathophysiological mechanisms of hepatic stellate cells activation in liver fibrosis  
*Garbuzenko DV*

## ORIGINAL ARTICLE

## Retrospective Cohort Study

- 3677 Predictors of unfavorable outcome at 90 days in basilar artery occlusion patients  
*Chiu YC, Yang JL, Wang WC, Huang HY, Chen WL, Yen PS, Tseng YL, Chen HH, Tsai ST*

## Retrospective Study

- 3686 Role of multidetector computed tomography in patients with acute infectious colitis  
*Yu SJ, Heo JH, Choi EJ, Kim JH, Lee HS, Kim SY, Lim JH*
- 3698 Efficacy and prognostic factors of neoadjuvant chemotherapy for triple-negative breast cancer  
*Ding F, Chen RY, Hou J, Guo J, Dong TY*
- 3709 Relationship between subgroups of central and lateral lymph node metastasis in clinically node-negative papillary thyroid carcinoma  
*Zhou J, Li DX, Gao H, Su XL*
- 3720 Nomogram to predict postoperative complications in elderly with total hip replacement  
*Tan XJ, Gu XX, Ge FM, Li ZY, Zhang LQ*
- 3729 Flap failure prediction in microvascular tissue reconstruction using machine learning algorithms  
*Shi YC, Li J, Li SJ, Li ZP, Zhang HJ, Wu ZY, Wu ZY*
- Observational Study**
- 3739 Surgery in platinum-resistant recurrent epithelial ovarian carcinoma  
*Zhao LQ, Gao W, Zhang P, Zhang YL, Fang CY, Shou HF*

- 3754** Anorectal dysfunction in patients with mid-low rectal cancer after surgery: A pilot study with three-dimensional high-resolution manometry

Pi YN, Xiao Y, Wang ZF, Lin GL, Qiu HZ, Fang XC

#### Randomized Controlled Trial

- 3764** Effect of wrist-ankle acupuncture on propofol dosage during painless colonoscopy: A randomized controlled prospective study

He T, Liu C, Lu ZX, Kong LL, Li Y, Xu Z, Dong YJ, Hao W

#### META-ANALYSIS

- 3773** Melatonin intervention to prevent delirium in hospitalized patients: A meta-analysis

You W, Fan XY, Lei C, Nie CC, Chen Y, Wang XL

- 3787** Risk factors for hospital readmissions in pneumonia patients: A systematic review and meta-analysis

Fang YY, Ni JC, Wang Y, Yu JH, Fu LL

#### CASE REPORT

- 3801** Anti-programmed death 1 antibody in the treatment of coexistent *Mycobacterium fortuitum* and lung cancer: A case report

Zhang CC, Chen P

- 3808** Acute pancreatitis-induced thrombotic thrombocytopenic purpura: A case report

Wang CH, Jin HF, Liu WG, Guo Y, Liu Z

- 3814** Successful management of life-threatening aortoesophageal fistula: A case report and review of the literature

Zhong XQ, Li GX

- 3822** Isolated coagulopathy without classic CRAB symptoms as the initial manifestation of multiple myeloma: A case report

Zhang Y, Xu F, Wen JJ, Shi L, Zhou QL

- 3828** Evaluation of intracoronary function after reduction of ventricular rate by esmolol in severe stenotic myocardial bridge: A case report

Sun LJ, Yan DG, Huang SW

- 3834** Pediatric living donor liver transplantation using liver allograft after *ex vivo* backtable resection of hemangioma: A case report

Li SX, Tang HN, Lv GY, Chen X

- 3842** Kimura's disease in soft palate with clinical and histopathological presentation: A case report

Li W

- 3849** Combined targeted therapy and immunotherapy in anaplastic thyroid carcinoma with distant metastasis: A case report

Ma DX, Ding XP, Zhang C, Shi P

- 3856** Successful multimodality treatment of metastatic gallbladder cancer: A case report and review of literature  
*Zhang B, Li S, Liu ZY, Peiris KGK, Song LF, Liu MC, Luo P, Shang D, Bi W*
- 3866** Ischemic colitis after receiving the second dose of a COVID-19 inactivated vaccine: A case report  
*Cui MH, Hou XL, Liu JY*
- 3872** Cryoballoon pulmonary vein isolation and left atrial appendage occlusion prior to atrial septal defect closure: A case report  
*Wu YC, Wang MX, Chen GC, Ruan ZB, Zhang QQ*
- 3879** Surgical treatment for a combined anterior cruciate ligament and posterior cruciate ligament avulsion fracture: A case report  
*Yoshida K, Hakoziaki M, Kobayashi H, Kimura M, Konno S*
- 3886** Successful robot-assisted partial nephrectomy for giant renal hilum angiomyolipoma through the retroperitoneal approach: A case report  
*Luo SH, Zeng QS, Chen JX, Huang B, Wang ZR, Li WJ, Yang Y, Chen LW*
- 3893** Cryptococcal antigen testing of lung tissue homogenate improves pulmonary cryptococcosis diagnosis: Two case reports  
*Wang WY, Zheng YL, Jiang LB*
- 3899** Combined use of extracorporeal membrane oxygenation with interventional surgery for acute pancreatitis with pulmonary embolism: A case report  
*Yan LL, Jin XX, Yan XD, Peng JB, Li ZY, He BL*
- 3907** Dynamic navigation system-guided trans-inferior alveolar nerve implant placement in the atrophic posterior mandible: A case report  
*Chen LW, Zhao XE, Yan Q, Xia HB, Sun Q*
- 3916** Anti-glomerular basement membrane disease with IgA nephropathy: A case report  
*Guo C, Ye M, Li S, Zhu TT, Rao XR*
- 3923** Amniotic membrane transplantation in a patient with impending perforated corneal ulcer caused by *Streptococcus mitis*: A case report and review of literature  
*Hsiao FC, Meir YJJ, Yeh LK, Tan HY, Hsiao CH, Ma DHK, Wu WC, Chen HC*
- 3930** Steriod for Autoimmune pancreatitis complicating by gastric varices: A case report  
*Hao NB, Li X, Hu WW, Zhang D, Xie J, Wang XL, Li CZ*
- 3936** Antithrombotic treatment strategy for patients with coronary artery ectasia and acute myocardial infarction: A case report  
*Liu RF, Gao XY, Liang SW, Zhao HQ*
- 3944** Mesh plug erosion into the small intestine after inguinal hernia repair: A case report  
*Xie TH, Wang Q, Ha SN, Cheng SJ, Niu Z, Ren XX, Sun Q, Jin XS*
- 3951** Recurrence of infectious mononucleosis in adults after remission for 3 years: A case report  
*Zhang XY, Teng QB*

- 3959** Vertical direction impaction of kissing molars: A case report

*Wen C, Jiang R, Zhang ZQ, Lei B, Yan YZ, Zhong YQ, Tang L*

### **LETTER TO THE EDITOR**

- 3966** Comment on “Outcomes of different minimally invasive surgical treatments for vertebral compression fractures: An observational study”

*Ma L, Luo ZW, Sun YY*

**ABOUT COVER**

Editorial Board Member of *World Journal of Clinical Cases*, Potluri Leela Ravishankar, MDS, Professor, Department of Periodontics, SRM Kattankulathur Dental College and Hospital, SRM University, Chennai 603203, Tamil Nadu, India. plrs6@yahoo.com

**AIMS AND SCOPE**

The primary aim of *World Journal of Clinical Cases* (WJCC, *World J Clin Cases*) is to provide scholars and readers from various fields of clinical medicine with a platform to publish high-quality clinical research articles and communicate their research findings online.

WJCC mainly publishes articles reporting research results and findings obtained in the field of clinical medicine and covering a wide range of topics, including case control studies, retrospective cohort studies, retrospective studies, clinical trials studies, observational studies, prospective studies, randomized controlled trials, randomized clinical trials, systematic reviews, meta-analysis, and case reports.

**INDEXING/ABSTRACTING**

The WJCC is now indexed in Science Citation Index Expanded (also known as SciSearch®), Journal Citation Reports/Science Edition, Scopus, PubMed, and PubMed Central. The 2021 Edition of Journal Citation Reports® cites the 2020 impact factor (IF) for WJCC as 1.337; IF without journal self cites: 1.301; 5-year IF: 1.742; Journal Citation Indicator: 0.33; Ranking: 119 among 169 journals in medicine, general and internal; and Quartile category: Q3. The WJCC's CiteScore for 2020 is 0.8 and Scopus CiteScore rank 2020: General Medicine is 493/793.

**RESPONSIBLE EDITORS FOR THIS ISSUE**

Production Editor: *Ying-Yi Yuan*, Production Department Director: *Xu Guo*, Editorial Office Director: *Jin-Lei Wang*.

**NAME OF JOURNAL**

*World Journal of Clinical Cases*

**ISSN**

ISSN 2307-8960 (online)

**LAUNCH DATE**

April 16, 2013

**FREQUENCY**

Thrice Monthly

**EDITORS-IN-CHIEF**

Bao-Gan Peng, Jerzy Tadeusz Chudek, George Kontogeorgos, Maurizio Serati, Ja Hyeon Ku

**EDITORIAL BOARD MEMBERS**

<https://www.wjgnet.com/2307-8960/editorialboard.htm>

**PUBLICATION DATE**

April 26, 2022

**COPYRIGHT**

© 2022 Baishideng Publishing Group Inc

**INSTRUCTIONS TO AUTHORS**

<https://www.wjgnet.com/bpg/gerinfo/204>

**GUIDELINES FOR ETHICS DOCUMENTS**

<https://www.wjgnet.com/bpg/GerInfo/287>

**GUIDELINES FOR NON-NATIVE SPEAKERS OF ENGLISH**

<https://www.wjgnet.com/bpg/gerinfo/240>

**PUBLICATION ETHICS**

<https://www.wjgnet.com/bpg/GerInfo/288>

**PUBLICATION MISCONDUCT**

<https://www.wjgnet.com/bpg/gerinfo/208>

**ARTICLE PROCESSING CHARGE**

<https://www.wjgnet.com/bpg/gerinfo/242>

**STEPS FOR SUBMITTING MANUSCRIPTS**

<https://www.wjgnet.com/bpg/GerInfo/239>

**ONLINE SUBMISSION**

<https://www.f6publishing.com>



## Steroid for Autoimmune pancreatitis complicating by gastric varices: A case report

Ning-Bo Hao, Xue Li, Wen-Wei Hu, Dan Zhang, Jing Xie, Xiao-Lin Wang, Chang-Zheng Li

**Specialty type:** Gastroenterology and hepatology

**Provenance and peer review:**

Unsolicited article; Externally peer reviewed.

**Peer-review model:** Single blind

**Peer-review report's scientific quality classification**

Grade A (Excellent): 0  
Grade B (Very good): 0  
Grade C (Good): C, C, C  
Grade D (Fair): 0  
Grade E (Poor): 0

**P-Reviewer:** Omiyale AO, United Kingdom; Pelaez-Luna M, Mexico; Poturoglu S, Turkey

**Received:** September 28, 2021

**Peer-review started:** September 28, 2021

**First decision:** November 11, 2021

**Revised:** November 22, 2021

**Accepted:** March 6, 2022

**Article in press:** March 6, 2022

**Published online:** April 26, 2022



**Ning-Bo Hao, Xue Li, Wen-Wei Hu, Dan Zhang, Jing Xie, Xiao-Lin Wang, Chang-Zheng Li,** Department of Gastroenterology, PLA Rocket Force Characteristics Medical Center, Beijing 100088, China

**Corresponding author:** Chang-Zheng Li, MD, Chief Doctor, Department of Gastroenterology, PLA Rocket Force Characteristics Medical Center, No. 16 Xijiekouwai Street, Xicheng District, Beijing 100088, China. [lichangzheng435@126.com](mailto:lichangzheng435@126.com)

### Abstract

#### BACKGROUND

Both autoimmune pancreatitis (AIP) and gastric varices are related to various diseases. However, AIP complicated by gastric varices is extremely rare, and has only been reported in a few studies. Here, we report a case of AIP complicated by gastric varices in a female Chinese patient.

#### CASE SUMMARY

A 59-year-old Chinese woman was admitted to our hospital with mild abdominal pain. Computed tomography and magnetic resonance cholangiopancreatography revealed a diffusely enlarged pancreas, an obstructed splenic vein and slight splenomegaly. Esophagogastroduodenoscopy showed gastric varices in the partial gastric fundus and the red-color sign was positive. Blood chemistry showed that IgG4 was notably elevated. The patient was diagnosed with AIP complicated by gastric varices. Steroid therapy was administered to this patient with the risk of gastrointestinal bleeding. After one year of therapy, the pancreas, spleen and splenic vein recovered to the normal states, and the gastric varices had disappeared.

#### CONCLUSION

We present this case together with evidence from the literature to demonstrate the effectiveness of steroid therapy in the treatment of AIP complicated by gastric varices.

**Key Words:** Autoimmune pancreatitis; Gastric varices; Steroid; Case report

©The Author(s) 2022. Published by Baishideng Publishing Group Inc. All rights reserved.

**Core Tip:** Autoimmune pancreatitis (AIP) complicated by gastric varices is extremely rare. We report a case of AIP complicated by gastric varices. With one year of steroid therapy, the enlarged pancreas, obstructed splenic vein and slight splenomegaly recovered to the normal states. At the same time, the gastric varices disappeared. After 3 years of follow-up, the patient did not have any of the symptoms as previously described.

**Citation:** Hao NB, Li X, Hu WW, Zhang D, Xie J, Wang XL, Li CZ. Steroid for Autoimmune pancreatitis complicating by gastric varices: A case report. *World J Clin Cases* 2022; 10(12): 3930-3935

**URL:** <https://www.wjgnet.com/2307-8960/full/v10/i12/3930.htm>

**DOI:** <https://dx.doi.org/10.12998/wjcc.v10.i12.3930>

## INTRODUCTION

Autoimmune pancreatitis (AIP) is accepted as a unique clinical entity worldwide. The prevalence rate of AIP in Japan was 2.2 per 100000 people[1]. Using this prevalence, it was estimated that the number of AIP patients in China would be approximately 29 thousand[2]. A large multicenter study from 10 different countries reported that therapy with steroid could significantly induce clinical remission in 99% of type 1 AIP and 92% of type 2 AIP patients[3]. However, few studies have reported the role of steroid therapy in AIP complicated by gastric varices. In this study, we summarize the effects of steroid therapy in a case of AIP complicated by gastric varices.

## CASE PRESENTATION

### Chief complaints

A 59-year-old Chinese woman was admitted to the hospital with the symptoms of mild abdominal discontinuous pain for approximately 4 mo.

### History of present illness

The patient suffered from symptoms of mild abdominal discontinuous pain for approximately four months, accompanied by abdominal distension and poor appetite. The patient's intake was decreased by almost 1/2 compared with normal, and induced a weight loss of 5 kg. In the last month, the symptoms of abdominal pain and distension were worse than before, accompanied by fatigue, but without nausea and vomiting.

### History of past illness

No special previous medical history was reported.

### Personal and family history

No special personal or family histories were found.

### Physical examination

Epigastric tenderness without rebound or guarding was found. No other positive signs were found.

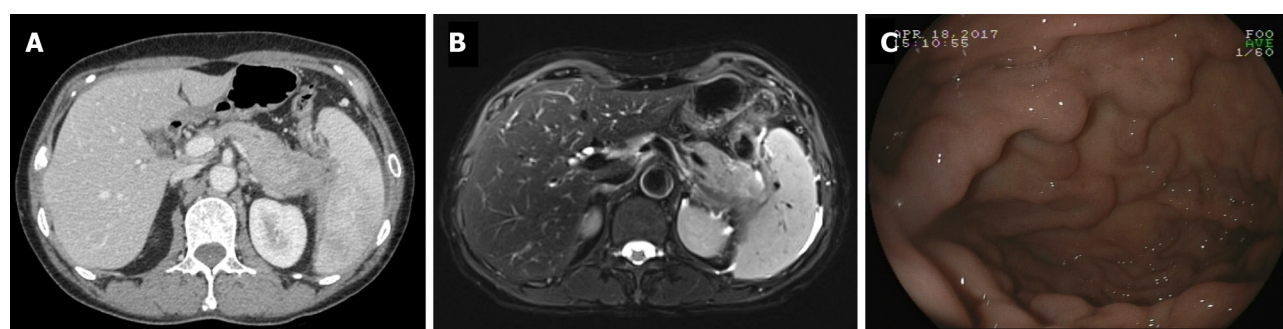
### Laboratory examinations

Routine blood tests showed a hemoglobin (Hb) of 81 g/L (N:113-151 g/L), red blood cell of  $2.88 \times 10^{12}/L$  (N:  $3.68-5.13 \times 10^{12}/L$ ). Other tests, such as white blood cell, platelet and neutrophil were all normal. Serum protein electrophoresis showed an increased incidence of polyclonal  $\alpha_1$ -globulinemia of 4.7% (N: 1.1-3.7%),  $\alpha_2$ -globulinemia of 15.2% (N: 8.5-14.5%) and  $\gamma$ -globulinemia of 26.1% (N: 9.2-18.2%). Other blood chemistry parameters such as tumor markers, liver and kidney function, coagulation tests and amylase levels were all within normal limits. Serology for hepatitis B and C and autoimmune serology, including anti-neutrophil cytoplasmic antibody and antinuclear antibody were all negative. The serum level of IgG4 was detected and was significantly elevated at 3670 mg/L (N: 80-1400 mg/L).

### Imaging examinations

Abdominal computed tomography (CT) revealed a diffusely enlarged pancreas with a capsule-like rim, an obstructed splenic vein, slight splenomegaly and collateral vessels from the gastric fundus (Figure 1A). Magnetic resonance cholangiopancreatography showed the irregular expansion of pancreatic duct in the neck and body of pancreas, and the swelling of pancreas (Figure 1B). Esophago-





DOI: 10.12998/wjcc.v10.i12.3930 Copyright ©The Author(s) 2022.

**Figure 1 Diffuse autoimmune pancreatitis complicating by gastric varices.** A: Computed tomography showed a diffusely enlarged pancreas with a capsule-like rim, obstructed splenic vein and slight splenomegaly; B: Magnetic resonance cholangiopancreatography showed the irregular expanding of pancreatic duct in the neck and body of pancreas, and the swelling of pancreas; C: Esophagogastroduodenoscopy showed the partial gastric varices in fundus with positive red-color sign.

gastroduodenoscopy (EGD) revealed that gastric varices in the partial gastric fundus and the red-color sign were positive (Figure 1C).

## FINAL DIAGNOSIS

Based on these findings, autoimmune pancreatitis complicating by gastric varices was identified.

## TREATMENT

Oral administration of 24 mg/d methylprednisolone was started for two weeks. Then the treatment was tapered by 4 mg every two weeks and until a maintenance dose of 8 mg/d was reached.

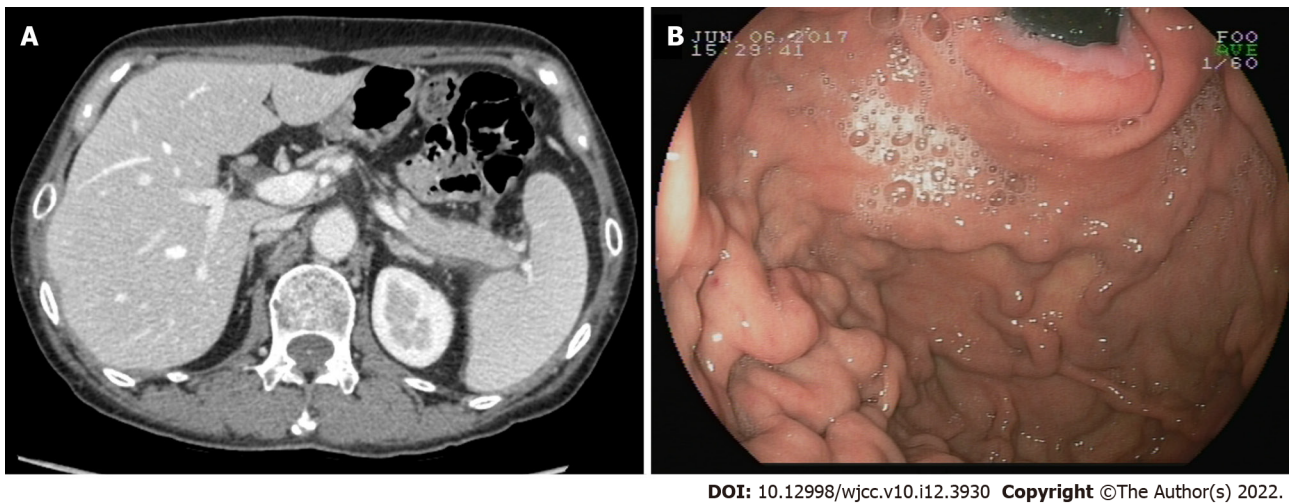
## OUTCOME AND FOLLOW-UP

Two months after the initial treatment, an abdominal CT showed that the swelling in the pancreas had improved (Figure 2A). The obstructed splenic vein, splenomegaly and gastric varices with positive red-color signs also showed a slight improvement (Figure 2B). The serum IgG4 had decreased to 1370 mg/L. Five months after the initial treatment, abdominal CT showed that the swelling of the pancreas, the obstructed splenic vein and splenomegaly had further improved (Figure 3A). EGD also showed that the gastric varices had improved, and the red-color signs were negative (Figure 3B). The serum IgG4 decreased to a normal level at 677mg/L. One year after the initial therapy, an abdominal CT showed that the pancreas, splenic vein and spleen were restored to the normal level (Figure 4A). EGD showed that the gastric vertices had disappeared (Figure 4B). The serum IgG4 had decreased to its normal level of 566 mg/L. Finally, the patient was asked to stop steroid therapy. After three years of follow-up, the patient did not experience a recurrent abdominal pain, and she did not have melena.

## DISCUSSION

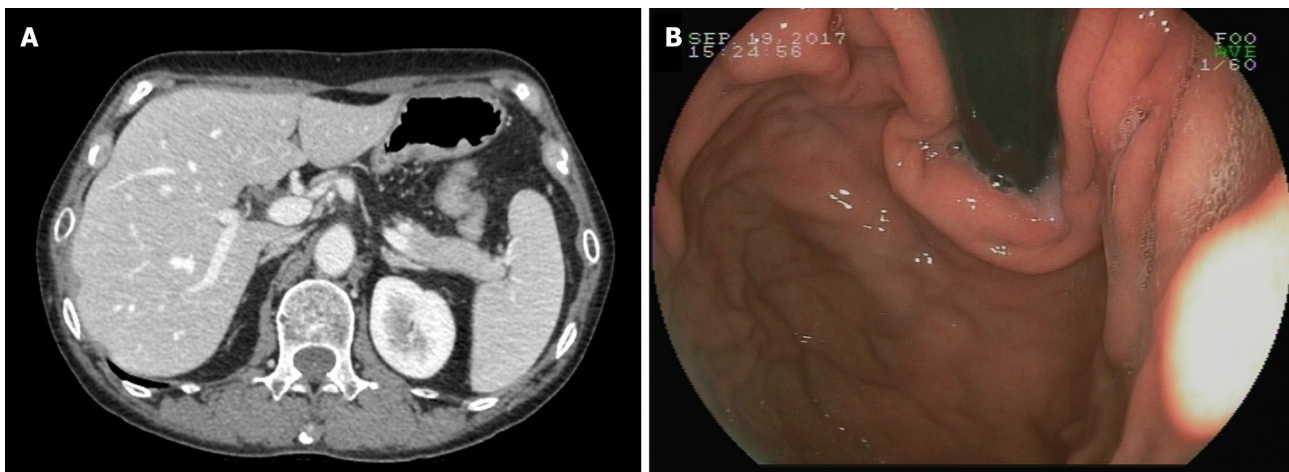
Type 1 AIP is considered a pancreatic manifestation of IgG4 related disease, which also includes a few extra-pancreatic organ diseases such as salivary sclerosingsialadenitis, interstitial nephritis, sclerosing cholangitis lung nodules, mediastinal fibrosis, adenopathy and chronic periaortitis[5,6]. The classical histopathological findings are dense lymphoplasmacytic infiltration, IgG4-positive plasma cell infiltration, storiform fibrosis, obliterative phlebitis and fibrosis without granulocytic infiltration[7]. A large multicenter study found that Type 1 AIP often presents at an older age and is more likely than type 2 AIP to manifest in men[3]. A systematic review in China found that the male to female ratio of type 1 AIP was 4.5:1. The main symptoms in type 1 AIP patients are jaundice (75%), abdominal pain (65%), and weight loss (42%)[2]. In this case report, the patient was a woman, and the main clinical presentation was up abdominal pain and weight loss.

Gastric varices are a relatively common complication in chronic pancreatitis[8]. Chronic pancreatitis leads to splenic vein obstruction and induces sinistral portal hypertension. Finally, gastric varices are



DOI: 10.12998/wjcc.v10.i12.3930 Copyright ©The Author(s) 2022.

**Figure 2 Autoimmune pancreatitis was significantly improved after two month steroid therapy.** A and B: Computed tomography and esophagogastroduodenoscopy showed the improvement of swelling pancreas, obstructed splenic vein, splenomegaly (A) and gastric varices with positive red-color sign (B).

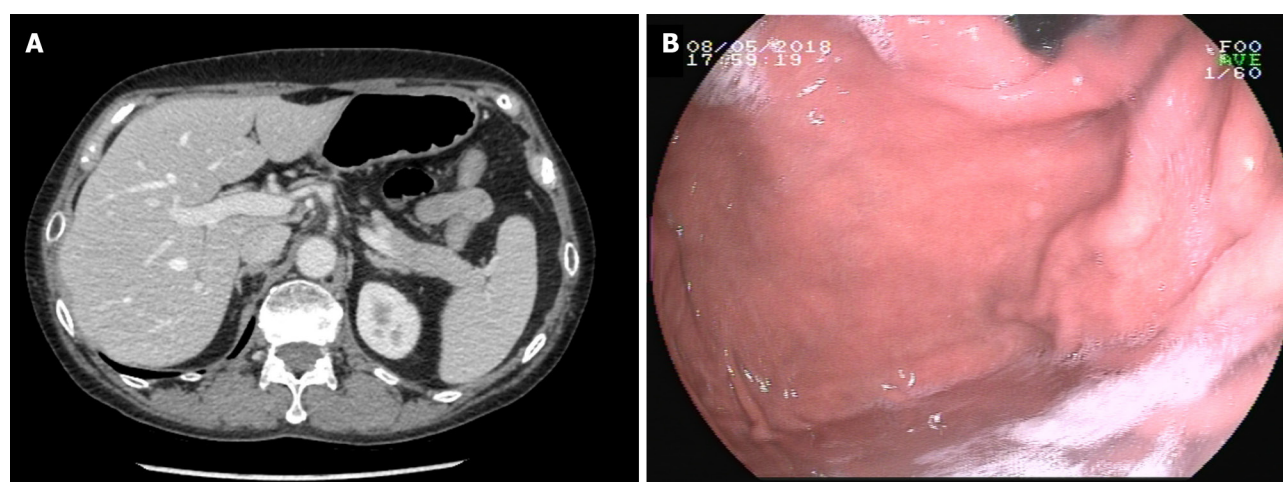


DOI: 10.12998/wjcc.v10.i12.3930 Copyright ©The Author(s) 2022.

**Figure 3 Autoimmune pancreatitis was further improved after five month steroid therapy.** A and B: Computed tomography and esophagogastroduodenoscopy showed the improvement of swelling pancreas, obstructed splenic vein, splenomegaly (A) and gastric varices with negative red-color sign (B).

formed along the fundus and the greater curvature of the stomach, since the blood flow in the short gastric veins or the gastroepiploic vein is significantly increased. However, AIP complicated by gastric varices has rarely been reported. Ishikawa *et al*[9] retrospectively reviewed 54 patients who met the international disease diagnostic criteria for AIP and found that 24 of the patients had AIP complicated by peripancreatic vascular involvement. Among these, only one patient (1/54, 1.9%) had gastric varices, 22 patients (22/54, 40.7%) had splenic vein occlusion or stenosis, and 13 patients (13/54, 24.1%) had superior mesenteric-portal vein occlusion or stenosis. In this case, the patient was diagnosed with AIP complicated by splenic vein obstruction and gastric varices.

Steroids are considered a risk factor for gastrointestinal bleeding. More studies are needed to evaluate the merits and disadvantages of using steroid therapy for AIP complicated by peripancreatic vascular involvement, especially gastric varices[10]. Ishikawa and colleagues reported that vascular lesions were significantly improved in 14 of 16 patients who received steroid therapy for AIP complicated by peripancreatic vascular involvement[9]. In contrast, the vascular lesions were exacerbated in 2 of 4 patients who were not treated with steroid therapy after two years. These results indicated that steroid therapy was meaningful. Furthermore, Goto and colleagues reported 3 cases of AIP complicated by gastric varices[11]. In case 1 without splenomegaly, steroid therapy significantly improved the enlarged pancreas and the splenic vein was reperfed. Finally, the gastric varices disappeared after six months of therapy. However, in cases 2 and 3 with splenomegaly, steroid therapy was not very effective. One case showed that steroid therapy only improved AIP but had no influence on gastric varices. In another



DOI: 10.12998/wjcc.v10.i12.3930 Copyright ©The Author(s) 2022.

**Figure 4 Gastric varices disappeared after 1 year steroid therapy.** A: Computed tomography showed the pancreas, spleen vein and spleen restore to the normal level; B: Esophagogastroduodenoscopy showed the gastric varices disappeared.

case, it was found that steroid therapy had no role in either AIP or gastric varices after five months of therapy. These cases revealed that the reason for these patients' congestive splenomegaly might have been the long duration for which they were affected by sinistral portal hypertension, and the splenomegaly finally led to irreversible spleen vein obstruction[11,12]. In this case, at the time of diagnosis, the patient had a diffusely enlarged pancreas with a capsule-like rim, an obstructed splenic vein, slight splenomegaly and gastric varices. After 1 year of steroid therapy, the capsule-like rim and gastric varices had disappeared, the spleen vein was reperfused, and the spleen was reduced.

## CONCLUSION

In summary, we reported a case of AIP complicated by gastric varices in this study. After 1 year of steroid therapy, the patient did not have any symptoms. The pancreas was significantly improved, and the gastric varices disappeared.

## FOOTNOTES

**Author contributions:** Hao NB and Li CZ designed the research study; Hao NB, Li X, Hu WW and Zhang D performed the research; Li X, Xie J and Wang XL contributed new reagents and analytic tools; Hao NB and Li CZ analyzed the data and wrote the manuscript; all authors have read and approve the final manuscript.

**Informed consent statement:** All study participants, or their legal guardian, provided informed written consent prior to study enrollment.

**Conflict-of-interest statement:** The authors declare that they have no conflict of interest.

**CARE Checklist (2016) statement:** The authors have read the CARE Checklist (2016), and the manuscript was prepared and revised according to the CARE Checklist (2016).

**Open-Access:** This article is an open-access article that was selected by an in-house editor and fully peer-reviewed by external reviewers. It is distributed in accordance with the Creative Commons Attribution NonCommercial (CC BY-NC 4.0) license, which permits others to distribute, remix, adapt, build upon this work non-commercially, and license their derivative works on different terms, provided the original work is properly cited and the use is non-commercial. See: <https://creativecommons.org/licenses/by-nc/4.0/>

**Country/Territory of origin:** China

**ORCID number:** Ning-Bo Hao 0000-0002-9315-8813; Xue Li 0000-0002-3298-7036; Wen-Wei Hu 0000-0001-8368-6199; Dan Zhang 0000-0001-9248-6195; Jing Xie 0000-0001-5650-8901; Xiao-Lin Wang 0000-0002-8074-3175; Chang-Zheng Li 0000-0001-6994-573X.

**S-Editor:** Xing YX



L-Editor: A

P-Editor: Xing YX

## REFERENCES

- 1 **Kanno A**, Nishimori I, Masamune A, Kikuta K, Hirota M, Kuriyama S, Tsuji I, Shimosegawa T; Research Committee on Intractable Diseases of Pancreas. Nationwide epidemiological survey of autoimmune pancreatitis in Japan. *Pancreas* 2012; **41**: 835-839 [PMID: [22466167](#) DOI: [10.1097/MPA.0b013e3182480c99](#)]
- 2 **Meng Q**, Xin L, Liu W, Lin H, Tian B, Wang L, Li Z. Diagnosis and Treatment of Autoimmune Pancreatitis in China: A Systematic Review. *PLoS One* 2015; **10**: e0130466 [PMID: [26110658](#) DOI: [10.1371/journal.pone.0130466](#)]
- 3 **Hart PA**, Kamisawa T, Brugge WR, Chung JB, Culver EL, Czako L, Frulloni L, Go VL, Gress TM, Kim MH, Kawa S, Lee KT, Lerch MM, Liao WC, Löhr M, Okazaki K, Ryu JK, Schleinitz N, Shimizu K, Shimosegawa T, Soetikno R, Webster G, Yadav D, Zen Y, Chari ST. Long-term outcomes of autoimmune pancreatitis: a multicentre, international analysis. *Gut* 2013; **62**: 1771-1776 [PMID: [23232048](#) DOI: [10.1136/gutjnl-2012-303617](#)]
- 4 **Shimosegawa T**, Chari ST, Frulloni L, Kamisawa T, Kawa S, Mino-Kenudson M, Kim MH, Klöppel G, Lerch MM, Löhr M, Notohara K, Okazaki K, Schneider A, Zhang L; International Association of Pancreatology. International consensus diagnostic criteria for autoimmune pancreatitis: guidelines of the International Association of Pancreatology. *Pancreas* 2011; **40**: 352-358 [PMID: [21412117](#) DOI: [10.1097/MPA.0b013e3182142fd2](#)]
- 5 **Omiyale AO**. Autoimmune pancreatitis. *Gland Surg* 2016; **5**: 318-326 [PMID: [27294040](#) DOI: [10.21037/gs.2015.11.02](#)]
- 6 **Sureka B**, Rastogi A. Autoimmune Pancreatitis. *Pol J Radiol* 2017; **82**: 233-239 [PMID: [28507644](#) DOI: [10.12659/PJR.900899](#)]
- 7 **Shiokawa M**, Kodama Y, Kuriyama K, Yoshimura K, Tomono T, Morita T, Kakiuchi N, Matsumori T, Mima A, Nishikawa Y, Ueda T, Tsuda M, Yamauchi Y, Minami R, Sakuma Y, Ota Y, Maruno T, Kurita A, Sawai Y, Tsuji Y, Uza N, Matsumura K, Watanabe T, Notohara K, Tsuruyama T, Seno H, Chiba T. Pathogenicity of IgG in patients with IgG4-related disease. *Gut* 2016; **65**: 1322-1332 [PMID: [26964842](#) DOI: [10.1136/gutjnl-2015-310336](#)]
- 8 **Ramesh H**, Jacob G, Venugopal A, Lekha V, Jacob M. Surgical management of chronic pancreatitis with portal hypertension--a 19-year experience. *Surgery* 2008; **143**: 252-258 [PMID: [18242342](#) DOI: [10.1016/j.surg.2007.08.014](#)]
- 9 **Ishikawa T**, Itoh A, Kawashima H, Ohno E, Itoh Y, Nakamura Y, Hiramatsu T, Miyahara R, Ohmiya N, Haruta J, Goto H, Hirooka Y. Peripancreatic vascular involvements of autoimmune pancreatitis. *J Gastroenterol Hepatol* 2012; **27**: 1790-1795 [PMID: [22849535](#) DOI: [10.1111/j.1440-1746.2012.07248.x](#)]
- 10 **Kamisawa T**, Yoshiike M, Egawa N, Nakajima H, Tsuruta K, Okamoto A: Treating patients with autoimmune pancreatitis: Results from a long-term follow-up study. *Pancreatol* : official journal of the International Association of Pancreatology 2005; **5**: 234-238; discussion 238-240 [DOI: [10.1159/000085277](#)]
- 11 **Goto N**, Mimura J, Itani T, Hayashi M, Shimada Y, Matsumori T. Autoimmune pancreatitis complicated by gastric varices: a report of 3 cases. *World J Gastroenterol* 2012; **18**: 4228-4232 [PMID: [22919259](#) DOI: [10.3748/wjg.v18.i31.4228](#)]
- 12 **Sakorafas GH**, Tsiotou AG. Splenic-vein thrombosis complicating chronic pancreatitis. *Scand J Gastroenterol* 1999; **34**: 1171-1177 [PMID: [10636062](#) DOI: [10.1080/003655299750024661](#)]



Published by **Baishideng Publishing Group Inc**  
7041 Koll Center Parkway, Suite 160, Pleasanton, CA 94566, USA

**Telephone:** +1-925-3991568

**E-mail:** [bpgoffice@wjgnet.com](mailto:bpgoffice@wjgnet.com)

**Help Desk:** <https://www.f6publishing.com/helpdesk>

<https://www.wjgnet.com>

