

World Journal of *Clinical Cases*

World J Clin Cases 2022 July 26; 10(21): 7187-7619



Contents

Thrice Monthly Volume 10 Number 21 July 26, 2022

OPINION REVIEW

- 7187 Effects of glucocorticoids on leukocytes: Genomic and non-genomic mechanisms
Jia WY, Zhang JJ

MINIREVIEWS

- 7195 Apheresis: A cell-based therapeutic tool for the inflammatory bowel disease
Yasmin F, Najeeb H, Naeem U, Moeed A, Koritala T, Surani S
- 7209 *Helicobacter pylori* infection and small intestinal bacterial overgrowth—more than what meets the eye
Dharan M, Wozny D
- 7215 Anatomy of the anterolateral ligament of the knee joint
Park JG, Han SB, Rhim HC, Jeon OH, Jang KM

ORIGINAL ARTICLE

Clinical and Translational Research

- 7224 Molecular mechanisms of Biyu decoction as treatment for psoriasis: A network pharmacology and molecular docking study
Wang Z, Zhang HM, Guo YR, Li LL
- 7242 Expression of hepatocyte nuclear factor 4 alpha, wingless-related integration site, and β -catenin in clinical gastric cancer
Hu Q, Li LL, Peng Z, Yi P

Case Control Study

- 7256 Improved Pittsburgh Sleep Quality Index scores on first postoperative night achieved by propofol anesthesia in patients undergoing ambulatory gynecologic surgery
Hu CH, Chou WY
- 7265 Efficacy of Guhong injection *versus* Butylphthalide injection for mild ischemic stroke: A multicenter controlled study
Zhang WW, Xin J, Zhang GY, Zhai QJ, Zhang HM, Wu CS

Retrospective Study

- 7275 Clinical values of Barcelona Clinic Liver Cancer subgroup and up-to-7 criteria in intermediate stage hepatocellular carcinoma with transcatheter arterial chemoembolization
Lee SW, Peng YC, Lien HC, Ko CW, Tung CF, Chang CS
- 7285 Intervention effect of encouraging mental and programmed nursing of patients in interventional operating room on their compliance and bad moods
Chi RB, Cai YY, Mao HP

- 7293** Preoperative neoadjuvant chemotherapy in patients with breast cancer evaluated using strain ultrasonic elastography
Pan HY, Zhang Q, Wu WJ, Li X
- 7302** Risk factors for delayed intracranial hemorrhage secondary to ventriculoperitoneal shunt: A retrospective study
Chen JC, Duan SX, Xue ZB, Yang SY, Li Y, Lai RL, Tan DH
- 7314** Sequential treatment of severe pneumonia with respiratory failure and its influence on respiratory mechanical parameters and hemodynamics
Niu BY, Wang G, Li B, Zhen GS, Weng YB
- 7324** Effects of alendronate sodium combined with InterTan on osteoporotic femoral intertrochanteric fractures and fracture recurrence
Wang KM, Wei SP, Yin XY, Meng QJ, Kong YM
- 7333** Correlation of magnetic resonance imaging quantitative parameters and apparent diffusion coefficient value with pathological breast cancer
Wang Z, Ren GY, Yin Q, Wang Q
- 7341** Risk factors for delirium after surgery for craniocerebral injury in the neurosurgical intensive care unit
Chen RY, Zhong CH, Chen W, Lin M, Feng CF, Chen CN

Observational Study

- 7348** Effect of osteoarthritic knee flexion deformity correction by total knee arthroplasty on sagittal spinopelvic alignment in Indian population
Puthiyapura LK, Jain M, Tripathy SK, Puliappadamb HM
- 7356** Imaging characteristics of orbital peripheral nerve sheath tumors: Analysis of 34 cases
Dai M, Wang T, Wang JM, Fang LP, Zhao Y, Thakur A, Wang D

Randomized Controlled Trial

- 7365** Comparison of involved-field intensity-modulated radiotherapy combined with S-1 *vs* radiotherapy alone for elderly patients with esophageal cancer
Liu LH, Yan MH, Di YP, Fu ZG, Zhang XD, Li HQ

Randomized Clinical Trial

- 7376** Dexmedetomidine in pediatric unilateral internal inguinal ring ligation
Liu G, Zhang L, Wang HS, Lin Y, Jin HQ, Wang XD, Qiao WN, Zhang YT, Sun JQ, Liu ZN

META-ANALYSIS

- 7386** Impact of cancer on mortality rates in patients with sepsis: A meta-analysis and meta-regression of current studies
Xiang MJ, Chen GL

CASE REPORT

- 7397 Updated clinical and glycomic features of mannosyl-oligosaccharide glucosidase deficiency: Two case reports
Abuduxikuer K, Wang L, Zou L, Cao CY, Yu L, Guo HM, Liang XM, Wang JS, Chen L
- 7409 Solitary necrotic nodules of the liver with "ring"-like calcification: A case report
Bao JP, Tian H, Wang HC, Wang CC, Li B
- 7415 Corticosteroid-induced bradycardia in multiple sclerosis and maturity-onset diabetes of the young due to hepatocyte nuclear factor 4-alpha mutation: A case report
Sohn SY, Kim SY, Joo IS
- 7422 Essential thrombocythemia with non-ST-segment elevation myocardial infarction as the first manifestation: A case report
Wang ZM, Chen WH, Wu YM, Wang LQ, Ye FL, Yin RL
- 7429 Extranasopharyngeal angiofibroma in children: A case report
Yan YY, Lai C, Wu L, Fu Y
- 7438 Deep Sylvian fissure meningiomas: A case report
Wang A, Zhang X, Sun KK, Li C, Song ZM, Sun T, Wang F
- 7445 Acute pulmonary embolism originating from upper limb venous thrombosis following breast cancer surgery: Two case reports
Duan Y, Wang GL, Guo X, Yang LL, Tian FG
- 7451 Managing spondylitis tuberculosis in a patient with underlying diabetes and hypothyroidism: A case report
Novita BD, Muliono AC, Wijaya S, Theodora I, Tjahjono Y, Supit VD, Willianto VM
- 7459 Ovarian mucinous tumor with mural nodules of anaplastic carcinoma: Three case reports
Wang XJ, Wang CY, Xi YF, Bu P, Wang P
- 7467 Transcatheter arterial infusion chemotherapy and embolization for primary lacrimal sac squamous cell carcinoma: A case report
Sun MH, Yi WD, Shen L, Zhou L, Lu JX
- 7474 Programmed cell death-1 inhibitor combination treatment for recurrent proficient mismatch repair/microsatellite-stable type endometrial cancer: A case report
Zhai CY, Yin LX, Han WD
- 7483 Novel compound heterozygous mutation of *SLC12A3* in Gitelman syndrome co-existent with hyperthyroidism: A case report and literature review
Qin YZ, Liu YM, Wang Y, You C, Li LN, Zhou XY, Lv WM, Hong SH, Xiao LX
- 7495 Successful treatment of hyperglycemia with liraglutide in a hospitalized 27-year-old patient with schizophrenia: A case report
Zhang L, Yu WJ, Zhu H, Li HF, Qiao J

- 7502** Refractory lymphoma treated with chimeric antigen receptor T cells combined with programmed cell death-1 inhibitor: A case report
Zhang CJ, Zhang JY, Li LJ, Xu NW
- 7509** Median arcuate ligament syndrome with retroperitoneal haemorrhage: A case report
Lu XC, Pei JG, Xie GH, Li YY, Han HM
- 7517** Novel frameshift mutation in the *AHDC1* gene in a Chinese global developmental delay patient: A case report
Lin SZ, Xie HY, Qu YL, Gao W, Wang WQ, Li JY, Feng XC, Jin CQ
- 7523** Selective nerve block for the treatment of neuralgia in Kummell's disease: A case report
Zhang X, Li ZX, Yin LJ, Chen H
- 7531** Traditional Chinese medicine manipulative reduction combined with percutaneous vertebroplasty for treating type III Kummell's disease: A case report
Hao SS, Zhang RJ, Dong SL, Li HK, Liu S, Li RF, Ren HH, Zhang LY
- 7539** Differential diagnosis and treatment of foot drop caused by an extraneural ganglion cyst above the knee: A case report
Won KH, Kang EY
- 7545** Effect of hydrogen intervention on refractory wounds after radiotherapy: A case report
Zhao PX, Luo RL, Dang Z, Wang YB, Zhang XJ, Liu ZY, Wen XH, Liu MY, Zhang MZ, Adzavon YM, Ma XM
- 7553** Chronic urticaria associated with lung adenocarcinoma — a paraneoplastic manifestation: A case report and literature review
Jiménez LF, Castellón EA, Marengo JD, Mejía JM, Rojas CA, Jiménez FT, Coronell L, Osorio-Llanes E, Mendoza-Torres E
- 7565** Spinal giant cell-rich osteosarcoma-diagnostic dilemma and treatment strategy: A case report
Tseng CS, Wong CE, Huang CC, Hsu HH, Lee JS, Lee PH
- 7571** Primary clear cell sarcoma of soft tissue in the posterior cervical spine invading the medulla oblongata: A case report
Liu CC, Huang WP, Gao JB
- 7577** *Pseudomonas aeruginosa*-related effusive-constrictive pericarditis diagnosed with echocardiography: A case report
Chen JL, Mei DE, Yu CG, Zhao ZY
- 7585** Maternal peripartum bacteremia caused by intrauterine infection with *Comamonas kerstersii*: A case report
Qu H, Zhao YH, Zhu WM, Liu L, Zhu M
- 7592** Considerations of single-lung ventilation in neonatal thoracoscopic surgery with cardiac arrest caused by bilateral pneumothorax: A case report
Zhang X, Song HC, Wang KL, Ren YY

- 7599** Rare primary rectal mucosa-associated lymphoid tissue lymphoma with curative resection by endoscopic submucosal dissection: A case report and review of literature

Tao Y, Nan Q, Lei Z, Miao YL, Niu JK

- 7609** Differences in examination results of small anastomotic fistula after radical gastrectomy with afterward treatments: A case report

Lu CY, Liu YL, Liu KJ, Xu S, Yao HL, Li L, Guo ZS

LETTER TO THE EDITOR

- 7617** Baseline differences may impact on relationship between dietary tryptophan and risk of obesity and type 2 diabetes

Ren XH, Ye YW, He LP

ABOUT COVER

Editorial Board Member of *World Journal of Clinical Cases*, Rajesh Kumar Rajnish, MBBS, MS, Assistant Professor, Department of Orthopaedics, All India Institute of Medical Sciences, Bilaspur, Bilaspur 174001, Himachal Pradesh, India. duktiraj@gmail.com

AIMS AND SCOPE

The primary aim of *World Journal of Clinical Cases* (WJCC, *World J Clin Cases*) is to provide scholars and readers from various fields of clinical medicine with a platform to publish high-quality clinical research articles and communicate their research findings online.

WJCC mainly publishes articles reporting research results and findings obtained in the field of clinical medicine and covering a wide range of topics, including case control studies, retrospective cohort studies, retrospective studies, clinical trials studies, observational studies, prospective studies, randomized controlled trials, randomized clinical trials, systematic reviews, meta-analysis, and case reports.

INDEXING/ABSTRACTING

The WJCC is now abstracted and indexed in Science Citation Index Expanded (SCIE, also known as SciSearch®), Journal Citation Reports/Science Edition, Current Contents®/Clinical Medicine, PubMed, PubMed Central, Scopus, Reference Citation Analysis, China National Knowledge Infrastructure, China Science and Technology Journal Database, and Superstar Journals Database. The 2022 Edition of Journal Citation Reports® cites the 2021 impact factor (IF) for WJCC as 1.534; IF without journal self cites: 1.491; 5-year IF: 1.599; Journal Citation Indicator: 0.28; Ranking: 135 among 172 journals in medicine, general and internal; and Quartile category: Q4. The WJCC's CiteScore for 2021 is 1.2 and Scopus CiteScore rank 2021: General Medicine is 443/826.

RESPONSIBLE EDITORS FOR THIS ISSUE

Production Editor: *Ying-Yi Yuan*; Production Department Director: *Xiang Li*; Editorial Office Director: *Jin-Lei Wang*.

NAME OF JOURNAL

World Journal of Clinical Cases

ISSN

ISSN 2307-8960 (online)

LAUNCH DATE

April 16, 2013

FREQUENCY

Thrice Monthly

EDITORS-IN-CHIEF

Bao-Gan Peng, Jerzy Tadeusz Chudek, George Kontogeorgos, Maurizio Serati, Ja Hyeon Ku

EDITORIAL BOARD MEMBERS

<https://www.wjnet.com/2307-8960/editorialboard.htm>

PUBLICATION DATE

July 26, 2022

COPYRIGHT

© 2022 Baishideng Publishing Group Inc

INSTRUCTIONS TO AUTHORS

<https://www.wjnet.com/bpg/gerinfo/204>

GUIDELINES FOR ETHICS DOCUMENTS

<https://www.wjnet.com/bpg/GerInfo/287>

GUIDELINES FOR NON-NATIVE SPEAKERS OF ENGLISH

<https://www.wjnet.com/bpg/gerinfo/240>

PUBLICATION ETHICS

<https://www.wjnet.com/bpg/GerInfo/288>

PUBLICATION MISCONDUCT

<https://www.wjnet.com/bpg/gerinfo/208>

ARTICLE PROCESSING CHARGE

<https://www.wjnet.com/bpg/gerinfo/242>

STEPS FOR SUBMITTING MANUSCRIPTS

<https://www.wjnet.com/bpg/GerInfo/239>

ONLINE SUBMISSION

<https://www.f6publishing.com>



Extranasopharyngeal angiofibroma in children: A case report

Yang-Yan Yan, Can Lai, Lei Wu, Yong Fu

Specialty type: Surgery

Provenance and peer review:

Unsolicited article; Externally peer reviewed.

Peer-review model: Single blind

Peer-review report's scientific quality classification

Grade A (Excellent): 0

Grade B (Very good): B

Grade C (Good): C

Grade D (Fair): 0

Grade E (Poor): 0

P-Reviewer: Noh CK, South Korea;

Saad K, Egypt

A-Editor: Valencia GA

Received: September 24, 2021

Peer-review started: September 24, 2021

First decision: December 2, 2021

Revised: December 11, 2021

Accepted: June 3, 2022

Article in press: June 3, 2022

Published online: July 26, 2022



Yang-Yan Yan, Yong Fu, Department of Otorhinolaryngology, Head and Neck Surgery, the Children's Hospital, Zhejiang University School of Medicine, National Clinical Research Center for Child Health, Hangzhou 310052, Zhejiang Province, China

Can Lai, Department of Radiology, the Children's Hospital, Zhejiang University School of Medicine, National Clinical Research Center for Child Health, Hangzhou 310052, Zhejiang Province, China

Lei Wu, Department of Endoscopy Center, the Children's Hospital, Zhejiang University School of Medicine, National Clinical Research Center for Child Health, Hangzhou 310052, Zhejiang Province, China

Corresponding author: Yong Fu, Doctor, PhD, Chief Doctor, Professor, Surgeon, Department of Otorhinolaryngology, Head and Neck Surgery, the Children's Hospital, Zhejiang University School of Medicine, National Clinical Research Center for Child Health, No. Binsheng Road 3333, Hangzhou 310052, Zhejiang Province, China. 1307022@zju.edu.cn

Abstract

BACKGROUND

Sporadic cases of extranasopharyngeal angiofibroma in children, especially preschool children, have been reported in the literature.

CASE SUMMARY

We present a case of extranasopharyngeal angiofibroma in a 4-year-old boy. The presenting symptoms, imaging findings, treatment, histological appearance, and follow-up data are described in detail. For this patient, we performed embolization on two occasions, and then, resected the tumor completely. During the treatment, the patient developed a soft-palate perforation due to aseptic necrosis. However, the healing ability was good, and the perforation healed spontaneously. We additionally reviewed all pediatric cases of extranasopharyngeal angiofibroma published up to 30 June 2020 in the PubMed, Baidu Scholar, Scopus, and Web of Science databases. We identified 45 pediatric patients [average (10.98 ± 4.86), boys 39 (86.7%)]. The highest proportion of cases occurred in adolescence [22 (48.9%)]. The top three sites of occurrence of extranasopharyngeal angiofibroma in children were the maxillary sinus, nasal septum, and inferior turbinate.

CONCLUSION

Extranasopharyngeal angiofibromas can occur throughout childhood, and predominantly present with nasal obstruction and spontaneous rhinorrhea.

Key Words: Extranasopharyngeal angiofibroma; Inferior turbinate; Children; Embolization; Perforation; Case report

©The Author(s) 2022. Published by Baishideng Publishing Group Inc. All rights reserved.

Core Tip: Extranasopharyngeal angiofibromas can occur throughout childhood, but predominantly occur during adolescence. They present with similar symptoms. In our case, the clinical presentation was unusual due to the patient's young age, the large tumor size, and the requirement of two embolization treatments. Soft palate perforation developed as a complication, but healed spontaneously during follow-up. Additionally, we performed a literature review to summarize the clinical characteristics of this rare tumor.

Citation: Yan YY, Lai C, Wu L, Fu Y. Extranasopharyngeal angiofibroma in children: A case report. *World J Clin Cases* 2022; 10(21): 7429-7437

URL: <https://www.wjgnet.com/2307-8960/full/v10/i21/7429.htm>

DOI: <https://dx.doi.org/10.12998/wjcc.v10.i21.7429>

INTRODUCTION

Angiofibromas are nasopharyngeal tumors that predominantly occur in adolescent boys. These tumors almost always originate in the region of the sphenopalatine foramen and enlarge to fill the postnasal space[1,2]. Angiofibromas that do not originate in this region are rare, and referred to as extranasopharyngeal angiofibromas[3]. Sporadic cases of extranasopharyngeal angiofibromas have been reported in the literature[2]. These types of angiofibromas most commonly originate from the maxillary sinus. Here, we describe a rare case of an extranasopharyngeal angiofibroma arising from the inferior turbinate and lateral wall of the nasopharynx in a child. The clinical presentation was unusual due to the patient's young age, the large tumor size, and the requirement of two embolization treatments. Soft palate perforation developed as a complication, but healed spontaneously during follow-up. Additionally, we performed a literature review to summarize the clinical characteristics of this rare tumor.

CASE PRESENTATION

Chief complaints

A 10-d history of epistaxis and nasal obstruction in the left nasal cavity.

History of present illness

A 4-year-old male reported to the ENT outpatient department of our institution with the chief complaints of epistaxis and nasal obstruction in the left nasal cavity for 10 d. The child had a sudden left nasal hemorrhage during sleep 10 days before, which was too large to stop by itself. He went to a local hospital for emergency treatment and stopped bleeding after filling the left nasal cavity with an inflated sponge. The next day, the child removed the expansive sponge by himself without obvious bleeding. Since then, the left nasal obstruction was persistent, accompanied by white purulent nasal discharge, which was difficult to blow out due to a large amount. Blood was sometimes seen in the nose, along with sleep snoring, accompanied by open mouth breathing and suffocation during sleep. Therefore, the patient was admitted to our hospital.

History of past illness

The child was previously healthy.

Physical examination

A pinkish lesion was seen in the total nasal passages of Bilateral nasal cavity

Imaging examinations

A Computed Tomography Scan of the paranasal sinuses was done which showed bilateral posterior nasal passage obstruction, a 2.5 cm × 2.7 cm size Soft tissue density shadow in the nasopharyngeal, and there was no bony erosion. Enhanced Magnetic Resonance Imaging (MRI) of paranasal sinus presented abnormal signal of nasopharynx with obvious enhancement, consideration of adolescent

nasopharyngeal fibroangioma (Figure 1).

FINAL DIAGNOSIS

Nasopharyngeal angiofibroma.

TREATMENT

After two embolization treatments, we use a plasma knife to remove the tumor (Figure 2).

OUTCOME AND FOLLOW-UP

The tumor tissues were completely removed. A follow-up nasal endoscopy at 3 mo after the endoscopic excision showed smooth mucosa at the posterior end of the left inferior turbinate and on the lateral wall of the nasopharynx, with no obvious new lesions.

DISCUSSION

Nasopharyngeal angiofibroma is a benign tumor of the nasopharynx. These tumors mostly occur in adolescent boys, and appear to be more common in the Middle East and Indian subcontinent[4]. Although the etiology and pathogenesis of nasopharyngeal angiofibroma are not yet clear, juvenile nasopharyngeal angiofibroma is believed to be caused by insufficient estrogen or relatively excessive androgen, which leads to hyperplasia of the vascular and fibrous tissues[5].

Due to the locally invasive nature of this tumor, it can widely involve the nasopharynx, paranasal sinuses, the orbital, pterygopalatine, and inferior temporal fossae, and even invade the skull base and cavernous sinus. Angiofibroma of extranasopharyngeal origin is rare. Extranasopharyngeal tumors most commonly originate in the maxillary sinus, but have also been reported to originate in the ethmoid sinus, sphenoid sinus, frontal sinus[7], middle turbinate[8], inferior turbinate[9], septum[10], cheek[11], and conjunctiva[6]. We searched the PubMed, Baidu Scholar, Scopus, and Web of Science databases for the search term “extranasopharyngeal angiofibroma.” A review of the retrieved literature revealed that a total of 45 cases, including ours, of this tumor have been reported in children[1,2,12,13]. We have also formulated a table that was first compiled by Ali and Jones in 1982 and updated it with recent cases of extranasopharyngeal angiofibroma in children (age < 18 years), including the present case (Table 1)[1]. The main features of these cases have been summarized in Table 2.

Of the 45 patients with extranasopharyngeal angiofibroma, 39 (86.7%) were boys, and 6 (13.3%) were girls, yielding a male-to-female ratio of 13:2. The highest proportion of cases occurred in adolescence (48.9%), which is consistent with the reported prevalence of the disease in adolescents[2]. The second most affected age group was children aged 7-12 years, who accounted for 35.6% of cases. Infants accounted for the smallest proportion of cases (15.5%). Thus, we found that extranasopharyngeal angiofibromas can occur throughout childhood, with non-adolescent children accounting for half of the total number of cases. The top three sites of occurrence of extranasopharyngeal angiofibroma in children were the maxillary sinus, nasal septum, and inferior turbinate, which accounted for 31.1%, 20%, and 13.3% of cases, respectively. Other sites were less frequently involved, and included the ethmoid sinus (6.7%), sphenoid sinus (4.4%), and middle turbinate (4.4%).

The main clinical manifestations of extranasopharyngeal angiofibroma were nasal obstruction (80%) and spontaneous rhinorrhea (60%). Other manifestations included secondary headache; sinusitis symptoms; tumor invasion of the pharyngeal opening of the eustachian tube, leading to conductive hearing loss; and tumor enlargement causing cheek swelling[14]. In our patient, the main symptoms were nasal obstruction and nosebleed, which is consistent with the reported findings.

Preoperative examinations for extranasopharyngeal angiofibroma include nasal endoscopy, CT, MRI, and angiography, which are required to fully evaluate the tumor extent, blood supply, and main blood vessels. Prior to the clinical diagnosis, intraoperative hemorrhage can be avoided by performing preoperative angiography and feeding-vessel embolization[15]. However, none of the children in the previous cases underwent preoperative embolization. This shows that extranasopharyngeal angiofibroma is less vascular, and thus, the chances of massive hemorrhage are low. For our patient, we chose to perform a second embolization 28 d after the first embolization, and then, remove the tumor. This is because the tumor had an abundant blood supply, was large, and its boundaries could not be clearly determined. Moreover, angiography showed early arteriovenous enhancement and abundant arteriovenous malformation, so we could not rule out the possibility of arteriovenous fistula

Table 1 Characteristics of extranasopharyngeal angiofibromas in children

No	Ref.	Site of origin	Age	Sex
1	Munson[21], 1941	Maxillary sinus	15 years	M
2	Radcliffe[22], 1951	Ethmoid sinus	16 years	M
3	Alajmo and Fini-Storchi[26], 1962	Maxillary sinus	9 years	M
4	Whitlock <i>et al</i> [23], 1961	Cheek	16 years	M
5	Alajmo and Fini-Storchi[26], 1962	Maxillary sinus	6 years	M
6	Hora and Brown[26], 1962	Maxillary sinus	13 years	M
7	Furstenborg and Boles[26], 1963	Ethmoid sinus	1 months	M
8	Minicone[26], 1964	Conjunctiva	17 years	M
9	Ogura[26], 1965	Maxillary sinus	16 years	M
10	Chaikovskii[26], 1967	External nose	14 years	F
11	Szczepanski <i>et al</i> [24], 1967	Ethmoid sinus	13 years	F
12	Manigla[26], 1969	Maxillary sinus	15 years	M
13	Pathak[26], 1970	Maxillary sinus	18 years	M
14	Beeden and Alexander[26], 1971	Oropharynx and hypopharynx	1 years	M
15	Charkabti[26], 1973	Maxillary sinus	17 years	M
16	Rye[26], 1973	Maxillary sinus	17 years	M
17	Stewart and O'Brien[26], 1973	Molar and retromolar	10 years	M
18	Ramajaneyulu[26], 1974	Maxillary sinus	17 years	M
19	Yamagiwa[26], 1974	Sphenoid sinus	14 years	M
20	Isherwood <i>et al</i> [25], 1975	Pterygomaxillary fissure, infratemporal region	13 years	M
21	Krutchkoff[30], 1977	Maxillary sinus	12 years	M
22	Reddy[26], 1979	Molar and retromolar area	14 years	F
23	Obiako <i>et al</i> [31], 1983	Roof of nasal cavity	12 years	M
24	Hiraide and Matsubara[27], 1984	Nasal septum	13 years	M
25	Sarpa and Novelly[28], 1989	Nasal septum	9 years	M
26	Kitano <i>et al</i> [32], 1992	Maxillary sinus	13 years	M
27	Manjalay <i>et al</i> [33], 1992	Maxillary sinus	Newborn	M
28	Gaffney <i>et al</i> [18], 1997	Inferior turbinate	9 years	M
29	Schick <i>et al</i> [6], 1997	Lacrimal sac	15 months	M
30	Schick <i>et al</i> [6], 1997	Paranasal sinus	9 years	M
31	Schick <i>et al</i> [6], 1997	Sphenoid sinus	6 years	M
32	Huang <i>et al</i> [8], 2000	Middle turbinate	14 years	M
33	Handa <i>et al</i> [12], 2001	Nasal septum	8 years	M
34	Panesar <i>et al</i> [2], 2003	Maxillary sinus	1 years	M
35	Gupta <i>et al</i> [34], 2006	Infratemporal region	13 years	M
36	Castillo <i>et al</i> [29], 2006	Nasal septum	9 years	M
37	Ifeacho and Caulfield[35], 2011	Middle turbinate	14 years	M
38	Singhal <i>et al</i> [17], 2014	Nasal septum	12 years	M
39	Ganguly <i>et al</i> [16], 2017	Nasal septum	7 years	M
40	Singh <i>et al</i> [17], 2018	Nasal septum	9 years	F
41	Kim <i>et al</i> [20], 2019	Inferior turbinate	9 years	M

42	Kim <i>et al</i> [20], 2019	Inferior turbinate	16 years	M
43	Kim <i>et al</i> [20], 2019	Inferior turbinate	8 years	F
44	Kim <i>et al</i> [20], 2019	Inferior turbinate	12 years	F
45	Our case	Inferior turbinate and lateral wall of nasopharynx	4 years	M

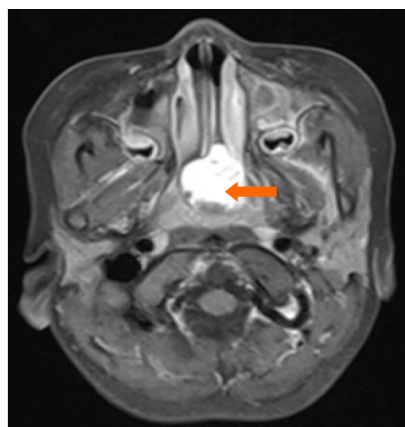
Table 2 Reported cases of extranasopharyngeal angiofibroma in children (n = 45)

Variable	N (%)
Gender	
Male	39 (86.7%)
Female	6 (13.3%)
Age at the time of surgery	
≤ 6 years	8 (17.8%)
7-12 years	15 (33.3%)
13-18 years	22 (48.9%)
Site	
Maxillary sinus	15 (33.3%)
Ethmoid sinus	3 (6.7%)
Sphenoid sinus	2 (4.4%)
Nasal septum	7 (15.6%)
Inferior turbinate	6 (13.3%)
Middle turbinate	2 (4.4%)
Roof of nasal cavity	1 (2.2%)
Lacrimal sac	1 (2.2%)
Cheek	1 (2.2%)
Conjunctiva	1 (2.2%)
External nose	1 (2.2%)
Molar and retromolar area	2 (4.4%)
Oropharynx and hypopharynx	1 (2.2%)
Infratemporal region	2 (4.4%)

(Figure 3A). Therefore, considering the high risk of intraoperative bleeding and the difficulty in achieving complete tumor resection, we planned to perform a second embolization after tumor necrosis and shrinkage had set in (Figure 3B).

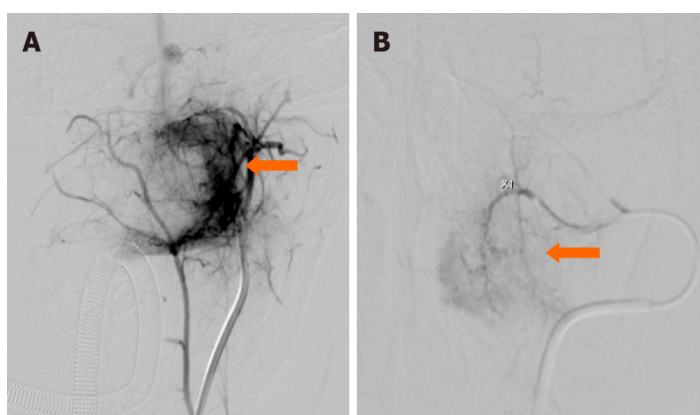
After the first embolization, the patient developed soft palate necrosis as a complication, which has not been previously reported (Figure 4A). The patient experienced reflux of food through the perforation in the soft palate and into the nasal cavity. As the perforation gradually narrowed, this symptom lessened and then disappeared. It is possible that the arteries supplying the soft palate were simultaneously embolized during the first embolization of the pterygoid segment of the internal maxillary artery, resulting in ischemic necrosis of the soft palate. However, because the perforation was caused by aseptic necrosis, it healed well, and had completely closed by the time of the reexamination 3 mo after the operation (Figure 4B).

The main treatment for extranasopharyngeal angiofibroma is surgical resection, which is usually performed *via* the transnasal endoscopic, lateral rhinotomy incision, or transoral approaches, depending on the site and size of the tumor. We reviewed the surgical procedures performed for extrapharyngeal angiofibromas in children over the last 30 years, and found that tumors in the septum, inferior turbinate, and middle turbinate were mostly commonly removed using nasal endoscopic resection (*e.g.*, Ganguly *et al*[16] and Singh *et al*[17]). Gaffney *et al*[18] and Huang *et al*[8] performed lateral rhinotomy to remove tumors originating from the inferior and middle turbinates, respectively. Handa *et al*[12] used an external approach incision in the left alar crease to resect a nasal septum tumor, which was found to be



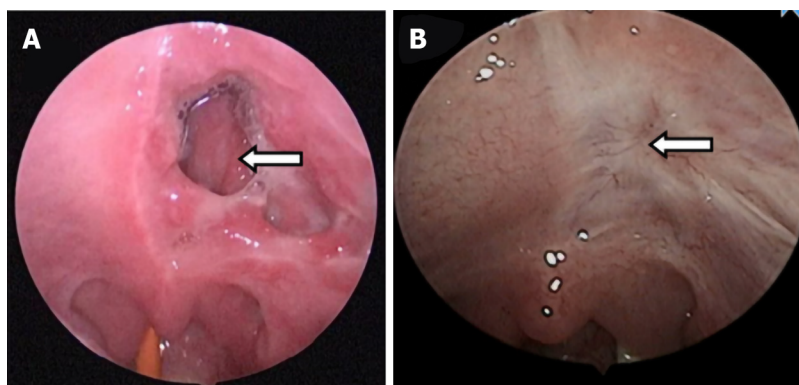
DOI: 10.12998/wjcc.v10.i21.7429 Copyright ©The Author(s) 2022.

Figure 1 Enhanced magnetic resonance imaging showing an abnormal signal in the nasopharynx with obvious enhancement.



DOI: 10.12998/wjcc.v10.i21.7429 Copyright ©The Author(s) 2022.

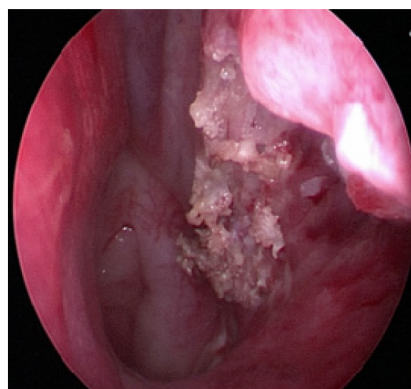
Figure 2 Before and after embolization. A: Pre-embolization angiography reveals that the tumor (arrow) is supplied by the left internal maxillary artery; B: After the second embolization, the arteriovenous fistula in the tumor in the nasopharynx has almost disappeared.



DOI: 10.12998/wjcc.v10.i21.7429 Copyright ©The Author(s) 2022.

Figure 3 Transformation of soft palate perforation. A: After the first embolization, an irregular perforation is seen in the left soft palate; B: At 3 mo after the endoscopic excision, the necrotic area in the left soft palate has completely healed.

firmly adhered to the nasal septum at the junction of the quadrangular cartilage and the bony septum. Endoscopic and KTP laser-assisted surgery has also been used[19]. Panesar *et al*[2] used the endoscopic approach for the first time to resect a tumor located in the maxillary sinus; however, their patient developed tumor recurrence after the operation, and another midfacial degloving procedure was used for the complete removal of the recurrent tumor. In the present study, we used a nasal endoscopic approach. During the surgery, the tumor was completely excised along with the tissues in a 0.5-cm



DOI: 10.12998/wjcc.v10.i21.7429 Copyright ©The Author(s) 2022.

Figure 4 The posterior end of the inferior turbinate and lateral wall of the nasopharynx after resection of the tumor mass.

margin around the tumor to minimize intraoperative hemorrhage. We used a plasma knife to remove the tumor, which helped to clear the operative field and reduced the probability of intraoperative bleeding and complications. There was little intraoperative bleeding in our patient, and nasal packing was not performed after tumor removal, which helped to minimize postoperative pain.

CONCLUSION

Extranasopharyngeal angiofibromas can occur throughout childhood, but predominantly occur during adolescence. They present with similar symptoms such as nasal obstruction and spontaneous rhinorrhea. When post-embolization complications occur, like in our case, they can be a challenge to manage and treat. However, aseptic necrosis due to embolism is associated with good healing ability and spontaneous repair.

ACKNOWLEDGEMENTS

The authors express their appreciation for Dr. Liu Yang's assistance with the pathology micrographs.

FOOTNOTES

Author contributions: Yan YY and Fu Y contributed equally to this work; Yan YY, Lai C, Wu L and Fu Y participated the treatment of disease. Yan YY and Fu Y analyzed the case and wrote the manuscript; all authors have read and approve the final manuscript.

Informed consent statement: Written informed consent was obtained from individual participants.

Conflict-of-interest statement: This paper has not been published elsewhere in whole or in part. All authors have read and approved the content, and agree to submit it for consideration for publication in your journal. There are no conflict of interest related to the manuscript.

CARE Checklist (2016) statement: The authors have read the CARE Checklist (2016), and the manuscript was prepared and revised according to the CARE Checklist (2016).

Open-Access: This article is an open-access article that was selected by an in-house editor and fully peer-reviewed by external reviewers. It is distributed in accordance with the Creative Commons Attribution NonCommercial (CC BY-NC 4.0) license, which permits others to distribute, remix, adapt, build upon this work non-commercially, and license their derivative works on different terms, provided the original work is properly cited and the use is non-commercial. See: <https://creativecommons.org/licenses/by-nc/4.0/>

Country/Territory of origin: China

ORCID number: Yang Yan Yan 0000-0002-0349-3491; Can Lai 0000-0002-4474-3087; Lei Wu 0000-0003-1329-010X; Yong Fu 0000-0003-4570-2973.

S-Editor: Ma YJ

L-Editor: A

P-Editor: Ma YJ

REFERENCES

- 1 Pathak PN. Extranasopharyngeal juvenile angiofibroma--a case report. *J Laryngol Otol* 1970; **84**: 449-451 [PMID: 4314888 DOI: 10.1017/s0022215100072066]
- 2 Panesar J, Vadgama B, Rogers G, Ramsay AD, Hartley BJ. Juvenile angiofibroma of the maxillary sinus. *Rhinology* 2004; **42**: 171-174 [DOI: 10.1177/000348944105000222]
- 3 Sarpa JR, Novelty NJ. Extranasopharyngeal angiofibroma. *Otolaryngol Head Neck Surg* 1989; **101**: 693-697 [PMID: 2556678 DOI: 10.1177/019459988910100613]
- 4 Gullane PJ, Davidson J, O'Dwyer T, Forte V. Juvenile angiofibroma: a review of the literature and a case series report. *Laryngoscope* 1992; **102**: 928-933 [PMID: 1323003 DOI: 10.1288/00005537-199208000-00014]
- 5 Dwight AL, Ramanath Rao, John Smeyer. Hormonal receptor determination in juvenile nasopharyngeal angiofibromas. *Cancer* 1980; **46**: 547-551
- 6 Schick V, Kind M, Draf W, Weber R, Lackmann GM. Extranasopharyngeal angiofibroma in a 15-month-old child. *Int J Pediatr Otorhinolaryngol* 1997; **42**: 135-140 [DOI: 10.1016/s0165-5876(97)00127-4]
- 7 Kim JS, Kwon SH, Kim JS, Jung JY, Heo SJ. Extranasopharyngeal Angiofibroma of the Frontal Sinus. *J Craniofac Surg* 2019; **30**: e432-e433 [PMID: 31299804 DOI: 10.1097/SCS.00000000000005464]
- 8 Huang RY, Damrose EJ, Blackwell KE, Cohen AN, Calcaterra TC. Extranasopharyngeal angiofibroma. *Int J Pediatr Otorhinolaryngol* 2000; **56**: 59-64 [PMID: 11074117 DOI: 10.1016/s0165-5876(00)00404-3]
- 9 Singh GB, Agarwal S, Arora R, Doloi P, Kumar D. A Rare Case of Angiofibroma Arising from Inferior Turbinate in a Female. *J Clin Diagn Res* 2016; **10**: MD07-MD08 [PMID: 27190846 DOI: 10.7860/JCDR/2016/18548.7621]
- 10 Hamdan AL, Moukarbel RV, Kattan M, Natout M. Angiofibroma of the nasal septum. *Middle East J Anaesthesiol* 2012; **21**: 653-655 [PMID: 23327044]
- 11 Dere H, Ozcan KM, Ergul G, Bahar S, Ozcan I, Kulacoglu S. Extranasopharyngeal angiofibroma of the cheek. *J Laryngol Otol* 2006; **120**: 141-144 [PMID: 16359575 DOI: 10.1017/s0022215105004573]
- 12 Handa KK, Kumar A, Singh MK, Chhabra AH. Extranasopharyngeal angiofibroma arising from the nasal septum. *International Journal of Pediatric Otorhinolaryngology* 2001; **58**: 163-166 [DOI: 10.1016/s0165-5876(00)00460-2]
- 13 Kim HD, Choi IS. Extranasopharyngeal angiofibroma mimicking choanal polyp in patients with chronic paranasal sinusitis. *Auris Nasus Larynx* 2019; **46**: 302-305 [PMID: 29954635 DOI: 10.1016/j.anl.2018.05.015]
- 14 López F, Triantafyllou A, Snyderman CH, Hunt JL, Suárez C, Lund VJ, Strojman P, Saba NF, Nixon IJ, Devaney KO, Alobid I, Bernal-Sprekelsen M, Hanna EY, Rinaldo A, Ferlito A. Nasal juvenile angiofibroma: Current perspectives with emphasis on management. *Head Neck* 2017; **39**: 1033-1045 [PMID: 28199045 DOI: 10.1002/hed.24696]
- 15 Katsiotis P, Tzortzis G, Karaminis C. Transcatheter arterial embolisation in nasopharyngeal angiofibroma. *Acta Radiol* 1979; **20**: 433-438
- 16 Ganguly S, Gawarle SH, Keche PN. Extra-Nasopharyngeal Angiofibroma in a Pre-Pubertal Child. *Journal of Clinical and Diagnostic Research* 2017; **11**: XD01-XD02 [DOI: 10.7860/jcdr/2017/27897.10771]
- 17 Singh GB, Shukla S, Kumari P, Shukla I. A rare case of extra-nasopharyngeal angiofibroma of the septum in a female child. *J Laryngol Otol* 2018; **132**: 184-187 [PMID: 29143693 DOI: 10.1017/S0022215117002122]
- 18 Gaffney R, Hui Yau, Vojvodich S, Forte V. Extranasopharyngeal angiofibromas of the inferior turbinate. *Intl J Pediatr Otorhinolaryngol* 1997; **40**: 177-180 [DOI: 10.1016/s0165-5876(97)00030-x]
- 19 Hazarika P, Nayak DR, Balakrishnan R, Raj G, Pillai S. Endoscopic and KTP laser-assisted surgery for juvenile nasopharyngeal angiofibroma. *Am J Otolaryngol* 2002; **23**: 282-286 [PMID: 12239693 DOI: 10.1053/ajot.2002.126324]
- 20 Kim HD, Choi IS. Extranasopharyngeal angiofibroma mimicking choanal polyp in patients with chronic paranasal sinusitis. *Auris Nasus Larynx* 2019; **46**: 302-305
- 21 Munson FT. Angiofibroma of the maxillary sinus. *Annals of otology, Rhinology and Laryngology* 1941; **50**: 561-569
- 22 Radcliffe A. Ethmoidal Fibroangioma. *Journal of Laryngology and Otolaryngology* 1951; **65**: 786-787
- 23 Whitlock RIH. Angiofibroma of Cheek. *British Dental Journal* 1961; **111**: 372-374
- 24 Szczepanski J, Perlowski H. Vascular tumours of the ethmoid sinus. *Polski Tygodnik Lekarski* 1967; **22**: 1503-1504
- 25 Isherwood I, Dogra TS, Farrington WT. Extranasopharyngeal juvenile angiofibroma. *Journal of Laryngology and Otolaryngology* 1975; **89**: 535-544
- 26 Ali S, Jones WI. Extranasopharyngeal Angiofibromas. *Journal of Laryngology and Otolaryngology* 1982; **96**: 559-565
- 27 Hiraide F, Matsubara H. Juvenile nasal angiofibroma: a case report. *Arch Otorhinolaryngol* 1984; **239**: 235-41
- 28 Sarpa JR, Novelty NJ. Extranasopharyngeal angiofibroma. *Otolaryngol Head Neck Surg* 1989; **101**: 693-697
- 29 Castillo MP, Timmons CF, McClay JE. Autoamputation of an extranasopharyngeal angiofibroma of the nasal septum. *Int J Pediatr Otorhinolaryngol Extra* 2006; **1**: 267-70
- 30 Krutchkoff DJ, Matteson SR, Mark H, Hasson J. Juvenile nasopharyngeal angiofibroma: an unusual p source arch otolaryngol. *Arch Otolaryngol* 1977; **103**: 553-556
- 31 Obiako MN, Jacobs A. An isolated case of juvenile angiofibroma in the nasal cavity. *Ear nose & throat journal* 1983; **62**: 70
- 32 Kitano M, Landini G, Mimura T. Juvenile angiofibroma of the maxillary sinus-A case report. *International journal of oral and maxillofacial surgery* 1992; **21**: 230-232
- 33 Manjalay G, Hoare TJ, Pearman K, Green NJ. A case of congenital angiofibroma. *Intl J Pediatr Otorhinolaryngol* 1992; **24**: 275-278

- 34 **Gupta M**, Motwani G, Gupta P. Extranasopharyngeal angiofibroma arising from the infratemporal region. *Indian J Otolaryngol Head Neck Surg* 2006; **58**: 312-315 [PMID: [23120330](#) DOI: [10.1007/BF03050857](#)]
- 35 **Ifeacho SN**, Caulfield HM. A rare cause of paediatric epistaxis: lobular capillary haemangioma of the nasal cavity. *BMJ Case Rep* 2011; 2011 [PMID: [22707545](#) DOI: [10.1136/bcr.07.2010.3199](#)]



Published by **Baishideng Publishing Group Inc**
7041 Koll Center Parkway, Suite 160, Pleasanton, CA 94566, USA

Telephone: +1-925-3991568

E-mail: bpgoffice@wjgnet.com

Help Desk: <https://www.f6publishing.com/helpdesk>

<https://www.wjgnet.com>

