

World Journal of *Clinical Cases*

World J Clin Cases 2022 April 6; 10(10): 2976-3320



Contents

Thrice Monthly Volume 10 Number 10 April 6, 2022

REVIEW

- 2976** Gut microbiota in gastrointestinal diseases during pregnancy
Liu ZZ, Sun JH, Wang WJ
- 2990** Targeting metabolism: A potential strategy for hematological cancer therapy
Tang X, Chen F, Xie LC, Liu SX, Mai HR

MINIREVIEWS

- 3005** Elevated intra-abdominal pressure: A review of current knowledge
Łagosz P, Sokolski M, Biegus J, Tycinska A, Zymlinski R

ORIGINAL ARTICLE

Case Control Study

- 3014** Changes in corneal nerve morphology and function in patients with dry eyes having type 2 diabetes
Fang W, Lin ZX, Yang HQ, Zhao L, Liu DC, Pan ZQ
- 3027** Combined sevoflurane-dexmedetomidine and nerve blockade on post-surgical serum oxidative stress biomarker levels in thyroid cancer patients
Du D, Qiao Q, Guan Z, Gao YF, Wang Q

Retrospective Cohort Study

- 3035** Early warning prevention and control strategies to reduce perioperative venous thromboembolism in patients with gastrointestinal cancer
Lu Y, Chen FY, Cai L, Huang CX, Shen XF, Cai LQ, Li XT, Fu YY, Wei J
- 3047** Dose-response relationship between risk factors and incidence of COVID-19 in 325 hospitalized patients: A multicenter retrospective cohort study
Zhao SC, Yu XQ, Lai XF, Duan R, Guo DL, Zhu Q

Retrospective Study

- 3060** Preventive online and offline health management intervention in polycystic ovary syndrome
Liu R, Li M, Wang P, Yu M, Wang Z, Zhang GZ
- 3069** Evidence-based intervention on postoperative fear, compliance, and self-efficacy in elderly patients with hip fracture
Fu Y, Zhu LJ, Li DC, Yan JL, Zhang HT, Xuan YH, Meng CL, Sun YH
- 3078** Significance of dysplasia in bile duct resection margin in patients with extrahepatic cholangiocarcinoma: A retrospective analysis
Choe JW, Kim HJ, Kim JS

- 3088** Diagnostic value and safety of medical thoracoscopy for pleural effusion of different causes

Liu XT, Dong XL, Zhang Y, Fang P, Shi HY, Ming ZJ

Observational Study

- 3101** Oxaliplatin-induced neuropathy and colo-rectal cancer patient's quality of life: Practical lessons from a prospective cross-sectional, real-world study

Prutianu I, Alexa-Stratulat T, Cristea EO, Nicolau A, Moisuc DC, Covrig AA, Ivanov K, Croitoru AE, Miron MI, Dinu MI, Ivanov AV, Marinca MV, Radu I, Gafton B

- 3113** Breast-conserving surgery and sentinel lymph node biopsy for breast cancer and their correlation with the expression of polyligand proteoglycan-1

Li FM, Xu DY, Xu Q, Yuan Y

SYSTEMATIC REVIEWS

- 3121** Clinical significance of aberrant left hepatic artery during gastrectomy: A systematic review

Tao W, Peng D, Cheng YX, Zhang W

META-ANALYSIS

- 3131** Betel quid chewing and oral potential malignant disorders and the impact of smoking and drinking: A meta-analysis

Lin HJ, Wang XL, Tian MY, Li XL, Tan HZ

- 3143** Effects of physical exercise on the quality-of-life of patients with haematological malignancies and thrombocytopenia: A systematic review and meta-analysis

Yang YP, Pan SJ, Qiu SL, Tung TH

CASE REPORT

- 3156** Primary malignant peritoneal mesothelioma mimicking tuberculous peritonitis: A case report

Lin LC, Kuan WY, Shiu BH, Wang YT, Chao WR, Wang CC

- 3164** Endoscopic submucosal dissection combined with adjuvant chemotherapy for early-stage neuroendocrine carcinoma of the esophagus: A case report

Tang N, Feng Z

- 3170** Lymph-node-first presentation of Kawasaki disease in a 12-year-old girl with cervical lymphadenitis caused by *Mycoplasma pneumoniae*: A case report

Kim N, Choi YJ, Na JY, Oh JW

- 3178** Tuberculosis-associated hemophagocytic lymphohistiocytosis misdiagnosed as systemic lupus erythematosus: A case report

Chen WT, Liu ZC, Li MS, Zhou Y, Liang SJ, Yang Y

- 3188** Migration of a Hem-o-Lok clip to the renal pelvis after laparoscopic partial nephrectomy: A case report

Sun J, Zhao LW, Wang XL, Huang JG, Fan Y

- 3194** Ectopic intrauterine device in the bladder causing cystolithiasis: A case report
Yu HT, Chen Y, Xie YP, Gan TB, Gou X
- 3200** Giant tumor resection under ultrasound-guided nerve block in a patient with severe asthma: A case report
Liu Q, Zhong Q, Zhou NN, Ye L
- 3206** Myomatous erythrocytosis syndrome: A case report
Shu XY, Chen N, Chen BY, Yang HX, Bi H
- 3213** Middle thyroid vein tumor thrombus in metastatic papillary thyroid microcarcinoma: A case report and review of literature
Gui Y, Wang JY, Wei XD
- 3222** Severe pneumonia and acute myocardial infarction complicated with pericarditis after percutaneous coronary intervention: A case report
Liu WC, Li SB, Zhang CF, Cui XH
- 3232** IgA nephropathy treatment with traditional Chinese medicine: A case report
Zhang YY, Chen YL, Yi L, Gao K
- 3241** Appendico-vesicocolonic fistula: A case report and review of literature
Yan H, Wu YC, Wang X, Liu YC, Zuo S, Wang PY
- 3251** *Scedosporium apiospermum* infection of the lumbar vertebrae: A case report
Shi XW, Li ST, Lou JP, Xu B, Wang J, Wang X, Liu H, Li SK, Zhen P, Zhang T
- 3261** Woman diagnosed with obsessive-compulsive disorder became delusional after childbirth: A case report
Lin SS, Gao JF
- 3268** Emphysematous pyelonephritis: Six case reports and review of literature
Ma LP, Zhou N, Fu Y, Liu Y, Wang C, Zhao B
- 3278** Atypical infantile-onset Pompe disease with good prognosis from mainland China: A case report
Zhang Y, Zhang C, Shu JB, Zhang F
- 3284** *Mycobacterium tuberculosis* bacteremia in a human immunodeficiency virus-negative patient with liver cirrhosis: A case report
Lin ZZ, Chen D, Liu S, Yu JH, Liu SR, Zhu ML
- 3291** Cervical aortic arch with aneurysm formation and an anomalous right subclavian artery and left vertebral artery: A case report
Wu YK, Mao Q, Zhou MT, Liu N, Yu X, Peng JC, Tao YY, Gong XQ, Yang L, Zhang XM
- 3297** Dedifferentiated chondrosarcoma of the middle finger arising from a solitary enchondroma: A case report
Yonezawa H, Yamamoto N, Hayashi K, Takeuchi A, Miwa S, Igarashi K, Morinaga S, Asano Y, Saito S, Tome Y, Ikeda H, Nojima T, Tsuchiya H

- 3306** Endoscopic-catheter-directed infusion of diluted (-)-noradrenaline for atypical hemobilia caused by liver abscess: A case report

Zou H, Wen Y, Pang Y, Zhang H, Zhang L, Tang LJ, Wu H

- 3313** *Pneumocystis jiroveci* pneumonia after total hip arthroplasty in a dermatomyositis patient: A case report

Hong M, Zhang ZY, Sun XW, Wang WG, Zhang QD, Guo WS

ABOUT COVER

Editorial Board Member of *World Journal of Clinical Cases*, Hui-Jeong Hwang, MD, PhD, Associate Professor, Department of Cardiology, Kyung Hee University Hospital at Gangdong, Kyung Hee University College of Medicine, Seoul 05278, South Korea. neonic7749@hanmail.net

AIMS AND SCOPE

The primary aim of *World Journal of Clinical Cases* (WJCC, *World J Clin Cases*) is to provide scholars and readers from various fields of clinical medicine with a platform to publish high-quality clinical research articles and communicate their research findings online.

WJCC mainly publishes articles reporting research results and findings obtained in the field of clinical medicine and covering a wide range of topics, including case control studies, retrospective cohort studies, retrospective studies, clinical trials studies, observational studies, prospective studies, randomized controlled trials, randomized clinical trials, systematic reviews, meta-analysis, and case reports.

INDEXING/ABSTRACTING

The WJCC is now indexed in Science Citation Index Expanded (also known as SciSearch®), Journal Citation Reports/Science Edition, Scopus, PubMed, and PubMed Central. The 2021 Edition of Journal Citation Reports® cites the 2020 impact factor (IF) for WJCC as 1.337; IF without journal self cites: 1.301; 5-year IF: 1.742; Journal Citation Indicator: 0.33; Ranking: 119 among 169 journals in medicine, general and internal; and Quartile category: Q3. The WJCC's CiteScore for 2020 is 0.8 and Scopus CiteScore rank 2020: General Medicine is 493/793.

RESPONSIBLE EDITORS FOR THIS ISSUE

Production Editor: *Xu Guo*; Production Department Director: *Xiang Li*; Editorial Office Director: *Jin-Lai Wang*.

NAME OF JOURNAL

World Journal of Clinical Cases

ISSN

ISSN 2307-8960 (online)

LAUNCH DATE

April 16, 2013

FREQUENCY

Thrice Monthly

EDITORS-IN-CHIEF

Bao-Gan Peng, Jerzy Tadeusz Chudek, George Kontogeorgos, Maurizio Serati, Ja Hyeon Ku

EDITORIAL BOARD MEMBERS

<https://www.wjgnet.com/2307-8960/editorialboard.htm>

PUBLICATION DATE

April 6, 2022

COPYRIGHT

© 2022 Baishideng Publishing Group Inc

INSTRUCTIONS TO AUTHORS

<https://www.wjgnet.com/bpg/gerinfo/204>

GUIDELINES FOR ETHICS DOCUMENTS

<https://www.wjgnet.com/bpg/gerinfo/287>

GUIDELINES FOR NON-NATIVE SPEAKERS OF ENGLISH

<https://www.wjgnet.com/bpg/gerinfo/240>

PUBLICATION ETHICS

<https://www.wjgnet.com/bpg/gerinfo/288>

PUBLICATION MISCONDUCT

<https://www.wjgnet.com/bpg/gerinfo/208>

ARTICLE PROCESSING CHARGE

<https://www.wjgnet.com/bpg/gerinfo/242>

STEPS FOR SUBMITTING MANUSCRIPTS

<https://www.wjgnet.com/bpg/gerinfo/239>

ONLINE SUBMISSION

<https://www.f6publishing.com>



Clinical significance of aberrant left hepatic artery during gastrectomy: A systematic review

Wei Tao, Dong Peng, Yu-Xi Cheng, Wei Zhang

Specialty type: Nuclear science and technology

Provenance and peer review: Invited article; Externally peer reviewed.

Peer-review model: Single blind

Peer-review report's scientific quality classification

Grade A (Excellent): 0
Grade B (Very good): B, B
Grade C (Good): C
Grade D (Fair): 0
Grade E (Poor): 0

P-Reviewer: Garbarino GM, Mishra TS, Nur Azlina M

Received: September 27, 2021

Peer-review started: September 27, 2021

First decision: December 2, 2021

Revised: December 12, 2021

Accepted: February 20, 2022

Article in press: February 20, 2022

Published online: April 6, 2022



Wei Tao, Dong Peng, Yu-Xi Cheng, Wei Zhang, Department of Gastrointestinal Surgery, the First Affiliated Hospital of Chongqing Medical University, Chongqing 400016, China

Corresponding author: Wei Zhang, PhD, Surgeon, Department of Gastrointestinal Surgery, the First Affiliated Hospital of Chongqing Medical University, No. 1 Youyi Road, Yuanjiagang, Yuzhong Distric, Chongqing 400016, China. cyzhangwei@hotmail.com

Abstract

BACKGROUND

Vascular variations are frequently encountered during surgery. Approximately thirty percent of these variations are aberrant left hepatic arteries originating from the left gastric artery.

AIM

To summarize the safety and feasibility of aberrant left hepatic arteries (ALHA) ligation in gastric cancer patients who underwent laparoscopic-assisted gastrectomy (LAG).

METHODS

The literature search was systematically performed on databases including PubMed, Embase, and Cochrane Library. The publishing date of eligible studies was from inception to June 2021.

RESULTS

A total of nine studies were included according to the inclusion and exclusion criteria in this review. The variation rate of ALHA ranged from 7.00% to 20.70%, and four studies compared the differences between the ALHA ligation group and the preservation group. Only one study showed worse postoperative outcomes in the ALHA ligation group. In all the included studies, a significant difference was found between the ALHA ligation group and the preservation group in terms of postoperative liver enzymes after LAG. However, there was no significant difference in the number of retrieved lymph nodes between the two groups.

CONCLUSION

In conclusion, it is not always safe and feasible for surgeons to ligate the ALHA during LAG surgery, and it is necessary for gastric cancer patients to undergo preoperative examination to clarify the ALHA subtypes, measure the diameter of the ALHA, and determine whether the patients have chronic liver disease.

Key Words: Gastric cancer; Aberrant left hepatic artery; Laparoscopic-assisted gastrectomy; Vascular variation; Ligation

©The Author(s) 2022. Published by Baishideng Publishing Group Inc. All rights reserved.

Core Tip: Vascular variations are frequently encountered during surgery. Approximately thirty percent of these variations are aberrant left hepatic arteries (ALHAs) originating from the left gastric artery. And liver dysfunction occurs more frequently after laparoscopic-assisted gastrectomy (LAG). The purpose of this systematic review is to summarize the safety and feasibility of ALHA ligation in gastric cancer patients who underwent LAG.

Citation: Tao W, Peng D, Cheng YX, Zhang W. Clinical significance of aberrant left hepatic artery during gastrectomy: A systematic review. *World J Clin Cases* 2022; 10(10): 3121-3130

URL: <https://www.wjgnet.com/2307-8960/full/v10/i10/3121.htm>

DOI: <https://dx.doi.org/10.12998/wjcc.v10.i10.3121>

INTRODUCTION

Gastric cancer (GC) is the second leading cause of cancer-related death worldwide, with 78000 patients dying every year[1-2]. Although multidisciplinary treatment, including chemotherapy, targeted therapy, and immunotherapy, has been recommended in many countries, radical gastrectomy remains the main or even the only curative therapy for GC. Radical gastrectomy is also beneficial to long-term survival[3-4].

Laparoscopic-assisted gastrectomy (LAG) has become the main surgical method for early-stage gastric cancer[5]. Although LAG has more advantages than open gastrectomy (OG), including less estimated blood loss, shorter hospital stays and fewer complications[6-7], liver dysfunction occurs more frequently after LAG. Several studies have reported that a long carbon dioxide (CO₂) exposure time caused by a difficult LAG could result in liver function alterations[8]. However, a previous study, comparing LAG with laparoscopy-assisted colectomy, found that liver dysfunction might not be caused by CO₂ pneumoperitoneum[9]. Vascular variations are frequently encountered during surgery. Variations in the anatomy of the hepatic artery are most frequently found, and approximately thirty percent of these variations are aberrant left hepatic arteries (ALHAs) originating from the left gastric artery (LGA)[10-12]. There are two main subtypes of ALHA variations: accessory LHA (acLHA) and replaced LHA type (RLHA)[10]. Radical LAG for GC is required to sever the LGA at the root level to ensure lymph node dissection, and the existing ALHA will inevitably be severed[13]. However, the ligation of ALHA may cause liver ischemia and severe postoperative complications, such as left hepatic lobe necrosis and liver dysfunction, because parts of the liver may be supplied by this artery[14-15]. There was no significant difference in surgical outcomes between the ALHA ligation group and the ALHA preservation group according to a previous study[16].

According to existing studies, there is still controversy regarding whether ALHA should be ligated during LAG surgery, and whether liver dysfunction occurs when ALHA is ligated. Therefore, the purpose of this systematic review is to summarize and assess the safety and feasibility of ALHA ligation in GC patients who underwent LAG surgery.

MATERIALS AND METHODS

Search strategy

This systematic review was designed and performed based on the Preferred Reporting Items for Systematic Review and Meta-Analysis Protocols (PRISMA-P) Statement[17]. This study is a systematic review of literature related to the change in postoperative liver function after gastrectomy with ligation of the ALHA. The literature search was systematically performed on databases including PubMed, Embase, and Cochrane Library. The publishing date of eligible studies was from inception to June 2021. We searched databases using the following keywords: “left hepatic artery”, “LHA”, “stomach tumor”, “stomach neoplasm”, “stomach cancer”, “cancer of stomach”, “gastric cancer” and “gastrectomy” (Table 1).

Table 1 The search strategy of the review

Search strategy
Search Databases: PubMed, Embase, Cochrane Library
Date: Up to June 3, 2021
Strategy: #1 AND #2
#1 Left hepatic artery [Title/ Abstract] or LHA[Title/ Abstract]
#2 (((stomach tumor [Title/ Abstract]) OR (stomach neoplasm [Title/ Abstract])) OR (stomach cancer [Title/ Abstract])) OR (cancer of the stomach [Title/ Abstract])) OR (gastric neoplasm [Title/ Abstract])) OR (gastric cancer [Title/ Abstract]) AND gastrectomy [Title/ Abstract]

Inclusion criteria and exclusion criteria

The title and abstract of all searched articles were independently screened by two authors. All articles conforming to the inclusion and exclusion criteria were eventually included in the study. The Inclusion criteria were as follows: (1) Study type: cohort studies, case-control studies, and retrospective studies on humans; (2) English language articles published in scientific journals; (3) Full-text articles available; and (4) Articles related to this research. The exclusion criteria were as follows: review, case reports, commentaries, randomized clinical trials and conference abstracts.

Data extraction

The full text of all included articles was independently screened by two researchers. Perioperative information, including the first author, publication year, country, study date, surgical procedure, sample size, vascular variation rate and main outcome, was extracted.

The anatomy variation of aberrant left hepatic artery

The ALHA has two primary subtypes. The first originates from the LGA in the extrahepatic area and communicates with the LHA *via* the accessory LHA (acLHA). In the second subtype, there is no LHA in the extrahepatic area, and an artery that emanates from the LGA communicates with the hepatic vasculature to replace the function of the LHA. This artery is referred to as the replaced LHA (RLHA). [Figure 1](#) shows the two subtypes of ALHA in detail.

Quality assessment

The quality of the nine included studies was assessed by the Newcastle-Ottawa Scale[18], and the results are reported in [Table 2](#).

RESULTS

A total of 549 studies were screened from the databases using the keywords. Then, duplicate studies, animal related studies and unrelated studies were excluded, and according to the inclusion criteria, 58 studies were left for further review. Next, the title and abstract from all selected studies were examined for final decisions, and 40 studies were excluded. Finally, eighteen full-text were thoroughly assessed for eligibility, and nine studies remained. According to the PRISMA statement, a flowchart was made for the detailed screening process of the study ([Figure 2](#)).

The characteristics of included studies

The nine included studies all originated in Asian countries, including 4 studies in Japan, 4 studies in Korea and 1 study in China. The year of publication ranged from 1993 to 2021. The sample size for these studies ranged from 28 to 215, with an average sample size of 135. Six studies were conducted to evaluate the safety of severing ALHA during LAG, and OG and LAG were discussed in the other three studies. According to the population characteristics of the included studies, 8 studies calculated the vascular variation rate of the simple set, and the rate ranged from 7.00% to 20.70%.

We summarized the main results of nine studies and divided their conclusions on the preservation of ALHA into two degrees of suggestions, of which the “possible preserve” was weak one, and the “preserve” was strong. Five studies suggested that it is of great necessity to preserve the ALHA to prevent postoperative liver dysfunction. However, the conclusions of other studies were that the ALHA could be ligated in appropriate situations, such as patients without chronic liver disease, an ALHA diameter less than 1.5 mm, and when more precise examinations are needed ([Table 2](#)).

The perioperative outcomes

We extracted operative outcome data from four studies that compared the surgical outcomes of the

Table 2 Characteristics of the studies included in the review

Ref.	Country	Study design	Study date	Surgical procedure	Simple size	Vascular variation rate	Main results	NOS
Waki <i>et al</i> [25], 2020	Japan	RS	2012-2018	LDG	106	20.70%	Preserve. Surgeons should confirm the RLHA preoperatively and preserve it, because the preservation of RLHA could reduce postoperative transaminase elevation and hepatic infraction	8
Okano <i>et al</i> [26], 1993	Japan	RS	1985-1991	LG	28	19.90%	Possible preserve. For patients with preoperative liver dysfunction or a large LHLG, the LHLG diameter should be estimated, as it can help with the decision of whether to preserve it	7
Ang <i>et al</i> [29], 2020	Korea	RS	2012-2016	LG	204	8.20%	Possible preserve. When ligating ALHA > 1.5 mm in diameter regardless of subtype, a transient rise would be seen in postoperative SGOT and SGPT levels, and liver enzymes should be monitored postoperatively	8
Shinohara <i>et al</i> [17], 2007	Japan	RS	1997-2001	Gastrectomy	50	7.00%	Preserve. Routine division of the ALHA does not be required as long as it is not directly involved by the tumour	7
Huang <i>et al</i> [24], 2013	China	RS	2007-2012	LG	135	11.50%	Possible preserve. ALHA is a common anomaly that was found in 11.5% of patients. It can be safely severed during radical gastrectomy in patients without CLD, but should be left intact in patients with CLD to prevent liver dysfunction	7
Jeong <i>et al</i> [10], 2011	Korea	RS	2006-2007	Gastrectomy	215	N/A	Preserve. Patients who underwent a gastrectomy showed significantly increased hepatic enzyme levels on POD1, regardless of the surgical technique, which returned to normal on POD5. This study concludes that the liver function alteration after LAG may have been caused by direct liver manipulation or aberrant hepatic artery ligation rather than the CO ₂ pneumoperitoneum	8
Kim <i>et al</i> [30], 2016	Korea	RS	2009-2014	LDG	150	12.50%	Preserve. Preservation of an ALHA during laparoscopic gastrectomy is feasible. This study suggests preserving ALHA which arises from a large LGA, diameter larger than 5 mm, during laparoscopic gastrectomy to prevent immediate postoperative hepatic dysfunction	8
Sano <i>et al</i> [27], 2021	Japan	RS	2013-2019	LG	54	35.30%	Preserve. Liver retraction using the NLR and ligation of an ALHA were recognized as independent risk factors for PLEE after LG for gastric cancer. ALHA preservation may contribute to avoiding postoperative liver dysfunction	7
Lee <i>et al</i> [28], 2021	Korea	RS	2015-2019	Gastrectomy	160	17.60%	Possible preserve. 8.6% patients with a ligated ALHA presented with MS liver enzyme elevation. These patients showed poorer short-term postoperative outcomes, in terms of the length of hospital stay and the incidence and severity of postoperative complications, than patients with NM liver enzyme elevation	8

LDG: Laparoscopic distal gastrectomy; LG: Laparoscopic gastrectomy; RS: Retrospective study; ALHA: Aberrant left hepatic arteries; NOS: Newcastle-Ottawa Scale. CLD: Chronic liver disease.

ALHA ligation group and the ALHA preservation group. The surgical outcome reported by Shinohara *et al* [16] indicated that the operation time was significantly longer, and the estimated blood loss and the number of retrieved lymph nodes were significantly higher in the ALHA-divided group than in the ALHA-preserved group ($P = 0.014$, $P = 0.005$ and $P = 0.018$, respectively). However, the surgical outcomes were not significantly different between the two groups in the other three studies. Furthermore, the surgical complications between the two groups were not significantly different in the four studies. According to these four studies, the postoperative variation of liver enzymes was used to reflect the changes in liver function, of which the variation of alanine aminotransferase (ALT) and aspartate aminotransferase (AST) were used as the main postoperative indicators. There were statistically significant differences in postoperative changes in liver enzymes between the ALHA-ligated group and the ALHA-preserved group on postoperative day (POD) 1, POD2, POD3, and POD5 (Table 3).

Table 3 The characteristic of four studies compared ALHA ligation and ALHA preservation group

	ALHA Waki <i>et al</i> [25], ALHA			Ang <i>et al</i> [29], RLHA			AcLHA			Shinohara <i>et al</i> [17], ALHA			Kim <i>et al</i> [30], ALHA		
	Divided (n = 18)	Preserved (n = 37)	P value	Divided (n = 17)	Preserved (n = 114)	P value	Divided (n = 52)	Preserved (n = 21)	P value	Divided (n = 23)	Preserved (n = 27)	P value	Divided (n = 116)	Preserved (n = 34)	P value
Operation time (min)	285 (171-490)	301 (173-476)	0.36	222 ± 55	243 ± 73	0.158	216 ± 49	221 ± 59	0.727	293 ± 19	223 ± 18	0.0141	151.5 (84-315)	177.5 (118-329)	0.084
EBL (mL)	10 (0-155)	18 (0-308)	0.427	102 ± 93	134 ± 126	0.316	108 ± 93	129 ± 126	0.429	450 ± 44	269 ± 43	0.0051	100 (20-1000)	100 (30-200)	0.791
RLS (n)	59 (34-64)	36.5 (21-53)	0.152							54 ± 5.7	38 ± 3.5	0.0181	37 (16-87)	33 (16-66)	0.207
PHS (d)	10 (7-38)	9 (7-21)	0.113	11.8 ± 8.0	9.7 ± 7.5	0.295	10.9 ± 16.7	11.9 ± 9.2	0.804	-	-	-	-	-	-
Complications, n (%)	6 (33.3%)	6 (16.2%)	0.177	3 (17.6%)	16 (14%)	0.713	8 (15.4%)	6 (28.6%)	0.207	-	-	-	-	-	-
PLECT	POD1, POD3		< 0.001 ¹	AST POD2, ALT (POD2, POD5)		< 0.001 ¹ , (< 0.001 ¹ , 0.046 ¹)	-		-	POD1, POD3		< 0.01 ¹	AST POD1; ALT (POD1, POD5)		0.009 ¹ ; (0.003 ¹ , 0.007 ¹)

¹P < 0.05. Values are presented as mean ± SE or median (range).

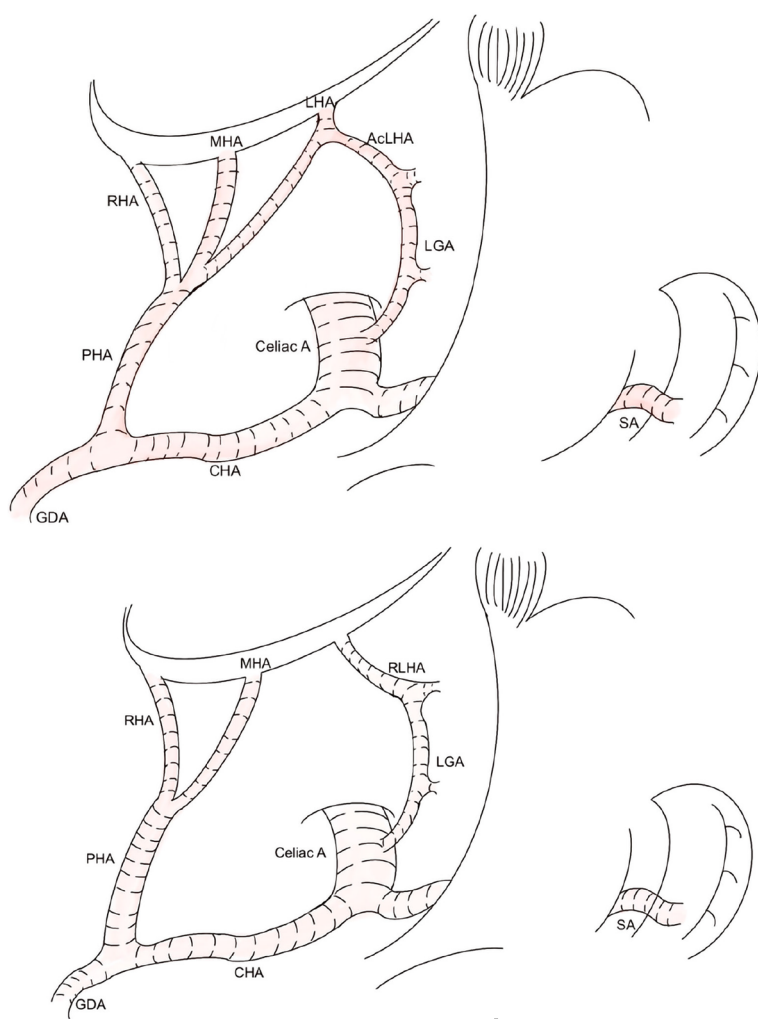
EBL: Estimated blood loss; RLS: Retrieved lymph nodes; PHS: Postoperative hospital stay; PLECT: Postoperative liver enzyme changed time; ALT: alanine aminotransferase; AST: aspartate aminotransferase; POD: postoperative day.

DISCUSSION

In this study, we systematically reviewed nine published scientific studies that focused on the safety and clinical significance of ligating the ALHA during LAG.

To our knowledge, this is the first systematic review to summarize the clinical significance of preserving the ALHA during LAG in GC patients. This is the first systematic review only on GC patients to summarize the clinical significance of ligating the ALHA during LAG by comparing the postoperative complications and the number of retrieved lymph nodes in the ALHA preserved group and ALHA ligated group. In this systematic review, we found that in five studies, the researchers strongly recommended that preserving ALHA could reduce postoperative complications. In the other four studies, the researchers reported that there was no significant difference in the changes in liver function between the ALHA ligation group and the preservation group. Only in special situations should postoperative liver function be monitored, such as in patients with chronic liver disease or those with an ALHA diameter > 1.5 mm.

ALHA variations were first reported in 1764. According to a previous study that had 57 studies related to ALHA variation, the ALHA prevalence rate reached 13.52%[19]. For a clear understanding of vascular anatomic variation, patients were asked to undergo preoperative examination before surgery. The difference in preoperative examination led to various results, with prevalence of 11.16%, 15.63%, and 13.1% for abdomen computed tomography (CT), angio-CT and visceral angiography respectively



DOI: 10.12998/wjcc.v10.i10.3121 Copyright ©The Author(s) 2022.

Figure 1 This artery is referred to as the replaced aberrant left hepatic arteries. Shows the two subtypes of aberrant left hepatic arteries in detail. ALHA: Aberrant left hepatic arterie; RLHA: Replaced LHA; LGA: Laparoscopic-assisted gastrectomy; CHA: Common hepatic artery; PHA: Proper hepatic artery; MHA: Middle hepatic artery; GDA: Gastroduodenal artery; SA: Splenic artery; RHA: Right hepatic artery.

[20]. Previous studies suggested that using three-dimensional CT angiography before surgery was more beneficial than using multidetector-row CT to recognize ALHA[21]. The ALHA has been categorized into ten types based on Michel's classification according to Cirocchi *et al*[20]. The ALHA is primarily composed of aCLHA and RLHA. It is necessary to recognize the existence of ALHA by preoperative examination before LAG surgery, because it is difficult to determine whether the anatomic structure of ALHA is normal during LGA surgery. Also, the intraoperative ligation of ALHA may lead to increased postoperative complications and prolonged hospitalization.

Based on the five types of vascular variations reported by Cirocchi *et al*[20], the ALHA originates from the left gastric artery to supply the left hepatic lobe directly or indirectly. For GC patients, lymph node metastasis is commonly diagnosed, and LAG is recommended as a curative treatment, according to the Japanese Classification of Gastric Carcinoma[13]. Thus, it is necessary to dissect the metastasizing lymph nodes around the tumor completely during LAG, including lymph node Stations 1, 3, and 7[22]. However, the LGA should be severed at its root level to achieve radical cure, and the ALHA, including aCLHA and RLHA, should also be ligated.

When the ALHA was ligated during surgery, severe complications, such as liver ischemia and liver failure, were reported by previous studies[16,23]. In contrast, other studies indicated that preserving ALHA could increase the operation time and estimated blood loss; however, it could not increase complications[24]. In this systematic review, four studies[16,24,28-29] that compared the ALHA preservation group with the ALHA ligation group were assessed to investigate the outcomes of GC patients with ALHA during LAG. In one of the four studies, Shinohara *et al*[16] reported that the ALHA ligation group had a longer operation time, higher estimated blood loss, more retrieved lymph nodes and a longer postoperative hospital stay. However, the other three studies reported negative outcomes. Furthermore, the rest five studies[9,23,25-27] used different methods to determine whether to ligate ALHA. Okano *et al*[25] reported that ligation of ALHA would cause transient liver enzyme changes on

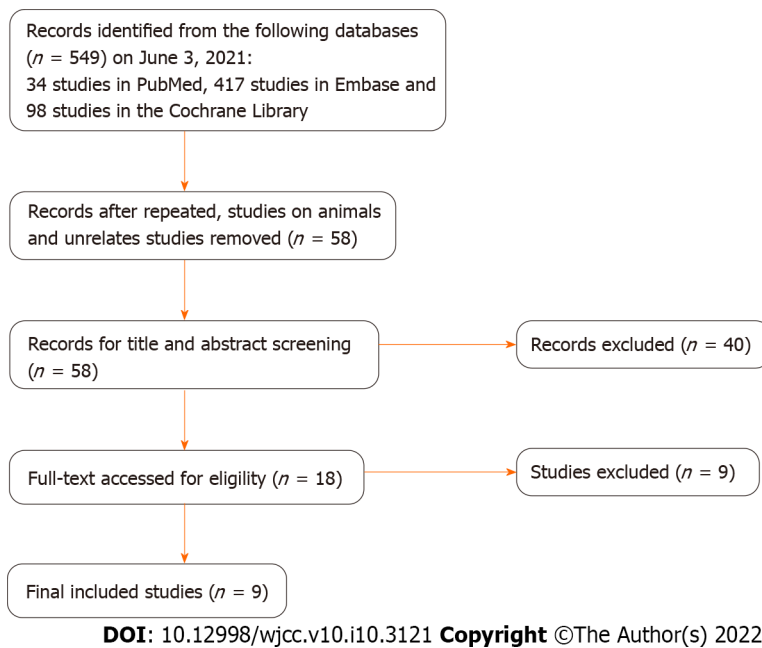


Figure 2 The flowchart of study selection.

POD1, and the surgical outcome might be related to the ALHA-fed area and the diameter of the ALHA. Huang *et al*[23] showed that patients with chronic liver disease (CLD) were more susceptible to tissue damage when they encountered ischemia and hypoxia than patients without CLD. Jeong GA *et al*[10] indicated that liver tissue primarily produces ALT, and the ALT level should be considered the gold standard for reflecting liver function changes. It was found that the ALT level increased when the ALHA was severed, but the clinical consequences of this were not significantly different. Sano *et al*[26] reported that ALHA ligation was an independent risk factor ($P = 0.042$) for increased postoperative liver enzyme in multivariate analysis, and it was feasible to preserve ALHA when dissected the lymph nodes as standard requested. Lee *et al*[27], in their analysis, demonstrated that 8.6% of their included patients with ALHA ligated have longer hospital stay and higher incidence of postoperative complications.

Postoperative liver enzyme variations were reported by all nine included studies. A significant transient elevation in ALT and AST enzymes was observed within POD5. In accordance with anatomic differences in the ALHA[19], the two types of ALHA can induce various degrees of liver dysfunction. The RLHA can directly provide a larger blood supply for part of the liver tissue than acLHA, which means that ischemia and hypoxia of liver tissue may be more serious in RLHA ligation than acLHA ligation. Therefore, Waki *et al*[24] and Ang *et al*[28] recommended that liver function variations should be monitored in patients, especially those with the RLHA type. Furthermore, three studies showed that regardless of the ALHA anatomic subtypes, when the ALHA has been severed in surgery, the diameter of the ALHA was related to postoperative liver enzymes elevation. Among these studies, two studies believed that when the diameter of ALHA was greater than 1.5 mm, postoperative liver damage should be monitored carefully[24,28]. The third study believed that an ALHA diameter larger than 0.5 mm should be preserved[29]. However, the nine included studies only reported that liver enzymes were elevated in the short-term after LAG, and long-term liver function changes were not reported, because liver dysfunction gradually recovered to normal levels after POD5. Although a few studies have shown that serious complications, such as liver failure, may occur after ALHA ligation[30], most studies reported transient postoperative liver enzyme elevation, which has no obvious influence on the recovery of most patients after surgery. Surgeons should pay more attention to patients with CLD because preserving ALHA in these patients could prevent postoperative liver function deterioration.

In this systematic review, although the ALHA may influence the decision of surgeons to complete a full lymph node dissection, there was no significant difference in the number of retrieved lymph nodes between the ALHA preservation and ALHA ligation groups. Therefore, it is not necessary for the surgeon to divide ALHA for the purpose of lymph node dissection in LAG unless there are obvious signs of tumor metastasis.

This current review had some limitations. First, this systematic review included nine retrospective studies with languages limited to English, and only 4 of these studies compared the ALHA-divided group with the ALHA-preserved group to analyze the relationship between ALHA variations and liver function changes in GC patients. Second, the sample size of the included studies was relatively small. Third, these nine studies lacked pliable data to implement a meta-analysis to support this research. Forth, between the initiations of this study, the included studies lacked western studies because of none of western studies could be searched based on this search strategy. Therefore, more large-scale studies

and randomized controlled trials clarifying the relationship between ALHA ligation and LAG surgery in postoperative liver function variations in GC patients are needed in the future.

CONCLUSION

In conclusion, it is not always safe and feasible for surgeons to ligate the ALHA during LAG surgery. Also, it is necessary for gastric cancer patients to undergo preoperative examination, to clarify the ALHA subtypes, measure the diameter of ALHA, and determine whether the patients have CLD.

ARTICLE HIGHLIGHTS

Research background

Vascular variations are frequently encountered during surgery. Approximately thirty percent of these variations are aberrant left hepatic arteries (ALHAs) originating from the left gastric artery (LGA).

Research motivation

A previous study, comparing LAG with laparoscopy-assisted colectomy, found that liver dysfunction might not be caused by carbon dioxide pneumoperitoneum. According to existing studies, there is still controversy regarding whether ALHA should be ligated during LAG surgery, and whether liver dysfunction occurs when ALHA is ligated.

Research objectives

The purpose of this systematic review is to summarize and assess the safety and feasibility of ALHA ligation in GC patients who underwent LAG surgery.

Research methods

The literature search was systematically performed on databases including PubMed, Embase, and Cochrane Library. The publishing date of eligible studies was from inception to June 2021.

Research results

A total of nine studies were included in this review. In all the included studies, a significant difference was found between the ALHA ligation group and the preservation group in terms of postoperative liver enzymes after LAG. However, there was no significant difference in the number of retrieved lymph nodes between the two groups.

Research conclusions

It is not always safe and feasible for surgeons to ligate the ALHA during LAG surgery, and it is necessary for gastric cancer patients to undergo preoperative examination to clarify the ALHA subtypes, measure the diameter of the ALHA, and determine whether the patients have chronic liver disease.

Research perspectives

More large-scale studies and randomized controlled trials clarifying the relationship between ALHA ligation and LAG surgery in postoperative liver function variations in GC patients are needed in the future.

FOOTNOTES

Author contributions: Tao W and Peng D contributed equally to this work; Zhang W designed the research study; Tao W wrote the manuscript; Peng D and Cheng YX conducted data extraction; Tao W conducted figure painting; Tao W, Peng D, Cheng YX and Zhang W conducted writing review and editing; all authors read and approved the final manuscript.

Conflict-of-interest statement: Authors declare no conflict of interests for this article.

PRISMA 2009 Checklist statement: This systematic review was designed and performed based on the Preferred Reporting Items for Systematic Review and Meta-Analysis Protocols (PRISMA-P) Statement.

Open-Access: This article is an open-access article that was selected by an in-house editor and fully peer-reviewed by external reviewers. It is distributed in accordance with the Creative Commons Attribution NonCommercial (CC BY-

NC 4.0) license, which permits others to distribute, remix, adapt, build upon this work non-commercially, and license their derivative works on different terms, provided the original work is properly cited and the use is non-commercial. See: <https://creativecommons.org/licenses/by-nc/4.0/>

Country/Territory of origin: China

ORCID number: Wei Tao 0000-0002-3149-0642; Dong Peng 0000-0003-4050-4337; Yu-Xi Cheng 0000-0002-9220-7855; Wei Zhang 0000-0002-5822-9970.

S-Editor: Ma YJ

L-Editor: A

P-Editor: Ma YJ

REFERENCES

- 1 **Bray F**, Ferlay J, Soerjomataram I, Siegel RL, Torre LA, Jemal A. Global cancer statistics 2018: GLOBOCAN estimates of incidence and mortality worldwide for 36 cancers in 185 countries. *CA Cancer J Clin* 2018; **68**: 394-424 [PMID: 30207593 DOI: 10.3322/caac.21492]
- 2 **Rawla P**, Barsouk A. Epidemiology of gastric cancer: global trends, risk factors and prevention. *Prz Gastroenterol* 2019; **14**: 26-38 [PMID: 30944675 DOI: 10.5114/pg.2018.80001]
- 3 **Japanese Gastric Cancer Association**. Japanese gastric cancer treatment guidelines 2014 (ver. 4). *Gastric Cancer* 2017; **20**: 1-19 [PMID: 27342689 DOI: 10.1007/s10120-016-0622-4]
- 4 **Peng D**, Cheng YX, Liao G. Effect of endoscopic resection on short-term surgical outcomes of subsequent laparoscopic gastrectomy: a meta-analysis. *World J Surg Oncol* 2021; **19**: 119 [PMID: 33853622 DOI: 10.1186/s12957-021-02230-5]
- 5 **Jiao J**, Liu S, Chen C, Maimaiti A, He Q, Hu S, Yu W. Comparative study of laparoscopic radical gastrectomy and open radical gastrectomy. *J Minim Access Surg* 2020; **16**: 41-46 [PMID: 30106026 DOI: 10.4103/jmas.JMAS_155_18]
- 6 **Kitano S**, Shiraishi N, Uyama I, Sugihara K, Tanigawa N; Japanese Laparoscopic Surgery Study Group. A multicenter study on oncologic outcome of laparoscopic gastrectomy for early cancer in Japan. *Ann Surg* 2007; **245**: 68-72 [PMID: 17197967 DOI: 10.1097/01.sla.0000225364.03133.f8]
- 7 **Huang X**, Du H, Aihemaiti M, Liu T, Chen N, Yu W, Hu S, Liu S. Laparoscopic-assisted Versus Open D2 Gastrectomy for Advanced Gastric Cancer in Highly Selective Patients: Short-term Surgical and Chemotherapy Outcomes of a Prospective Cohort Study. *Am J Clin Oncol* 2019; **42**: 459-465 [PMID: 30883390 DOI: 10.1097/COC.0000000000000534]
- 8 **Etoh T**, Shiraishi N, Tajima M, Shiromizu A, Yasuda K, Inomata M, Kitano S. Transient liver dysfunction after laparoscopic gastrectomy for gastric cancer patients. *World J Surg* 2007; **31**: 1115-1120 [PMID: 17426897 DOI: 10.1007/s00268-007-0237-3]
- 9 **Jeong GA**, Cho GS, Shin EJ, Lee MS, Kim HC, Song OP. Liver function alterations after laparoscopy-assisted gastrectomy for gastric cancer and its clinical significance. *World J Gastroenterol* 2011; **17**: 372-378 [PMID: 21253398 DOI: 10.3748/wjg.v17.i3.372]
- 10 **Michels NA**. Newer anatomy of the liver and its variant blood supply and collateral circulation. *Am J Surg* 1966; **112**: 337-347 [PMID: 5917302 DOI: 10.1016/0002-9610(66)90201-7]
- 11 **Hiatt JR**, Gabbay J, Busuttil RW. Surgical anatomy of the hepatic arteries in 1000 cases. *Ann Surg* 1994; **220**: 50-52 [PMID: 8024358 DOI: 10.1097/0000658-199407000-00008]
- 12 **Tiwari S**, Roopashree R, Padmavathi G, Varalakshmi KL, Sangeeta M. Study of aberrant left hepatic artery from left gastric artery and its clinical importance. *IJCRR* 2014; **6**: 25-28 [DOI: 10.9790/0853-13428388]
- 13 **Japanese Gastric Cancer Association**. Japanese classification of gastric carcinoma: 3rd English edition. *Gastric Cancer* 2011; **14**: 101-112 [PMID: 21573743 DOI: 10.1007/s10120-011-0041-5]
- 14 **Yamamoto M**, Zaima M, Yamamoto H, Harada H, Kawamura J, Yamada M, Yazawa T, Kawasoe J. Liver necrosis shortly after pancreaticoduodenectomy with resection of the replaced left hepatic artery. *World J Surg Oncol* 2017; **15**: 77 [PMID: 28399882 DOI: 10.1186/s12957-017-1151-2]
- 15 **FRIESEN SR**. The significance of the anomalous origin of the left hepatic artery from the left gastric artery in operations upon the stomach and esophagus. *Am Surg* 1957; **23**: 1103-1108 [PMID: 13488026]
- 16 **Shinohara T**, Ohyama S, Muto T, Yanaga K, Yamaguchi T. The significance of the aberrant left hepatic artery arising from the left gastric artery at curative gastrectomy for gastric cancer. *Eur J Surg Oncol* 2007; **33**: 967-971 [PMID: 17418995 DOI: 10.1016/j.ejso.2007.02.030]
- 17 **Shamseer L**, Moher D, Clarke M, Gherzi D, Liberati A, Petticrew M, Shekelle P, Stewart LA; PRISMA-P Group. Preferred reporting items for systematic review and meta-analysis protocols (PRISMA-P) 2015: elaboration and explanation. *BMJ* 2015; **350**: g7647 [PMID: 25555855 DOI: 10.1136/bmj.g7647]
- 18 **Stang A**. Critical evaluation of the Newcastle-Ottawa scale for the assessment of the quality of nonrandomized studies in meta-analyses. *Eur J Epidemiol* 2010; **25**: 603-605 [PMID: 20652370 DOI: 10.1007/s10654-010-9491-z]
- 19 **Haller AV**. Elementa phynologiae corporis humani. Neapoli, Apud Vincentium Ursinum, Bern. 1764 VIeVII [DOI: 10.5962/bhl.title.39950]
- 20 **Cirotchi R**, D'Andrea V, Amato B, Renzi C, Henry BM, Tomaszewski KA, Gioia S, Lancia M, Artico M, Randolph J. Aberrant left hepatic arteries arising from left gastric arteries and their clinical importance. *Surgeon* 2020; **18**: 100-112 [PMID: 31337536 DOI: 10.1016/j.surge.2019.06.002]
- 21 **Yamashita K**, Sakuramoto S, Mieno H, Shibata T, Nemoto M, Katada N, Kikuchi S, Watanabe M. Preoperative dual-phase 3D CT angiography assessment of the right hepatic artery before gastrectomy. *Surg Today* 2014; **44**: 1912-1919 [PMID: 24811111 DOI: 10.1007/s00570-014-0388-8]

- 24522892 DOI: [10.1007/s00595-014-0858-8](https://doi.org/10.1007/s00595-014-0858-8)
- 22 **Maruyama K**, Gunvén P, Okabayashi K, Sasako M, Kinoshita T. Lymph node metastases of gastric cancer. General pattern in 1931 patients. *Ann Surg* 1989; **210**: 596-602 [PMID: [2818028](https://pubmed.ncbi.nlm.nih.gov/2818028/) DOI: [10.1097/00000658-198911000-00005](https://doi.org/10.1097/00000658-198911000-00005)]
- 23 **Huang CM**, Chen QY, Lin JX, Zheng CH, Li P, Xie JW, Wang JB, Lu J. Short-term clinical implications of the accessory left hepatic artery in patients undergoing radical gastrectomy for gastric cancer. *PLoS One* 2013; **8**: e64300 [PMID: [23717589](https://pubmed.ncbi.nlm.nih.gov/23717589/) DOI: [10.1371/journal.pone.0064300](https://doi.org/10.1371/journal.pone.0064300)]
- 24 **Waki Y**, Kamiya S, Li Y, Hikage M, Tanizawa Y, Bando E, Terashima M. Preserving a Replaced Left Hepatic Artery Arising from the Left Gastric Artery During Laparoscopic Distal Gastrectomy for Gastric Cancer. *World J Surg* 2021; **45**: 543-553 [PMID: [33108491](https://pubmed.ncbi.nlm.nih.gov/33108491/) DOI: [10.1007/s00268-020-05832-4](https://doi.org/10.1007/s00268-020-05832-4)]
- 25 **Okano S**, Sawai K, Taniguchi H, Takahashi T. Aberrant left hepatic artery arising from the left gastric artery and liver function after radical gastrectomy for gastric cancer. *World J Surg* 1993; **17**: 70-3; discussion 74 [PMID: [8447143](https://pubmed.ncbi.nlm.nih.gov/8447143/) DOI: [10.1007/BF01655708](https://doi.org/10.1007/BF01655708)]
- 26 **Sano A**, Saito K, Kuriyama K, Nakazawa N, Ubukata Y, Hara K, Sakai M, Ogata K, Fukasawa T, Sohda M, Fukuchi M, Naitoh H, Shirabe K, Saeki H. Risk Factors for Postoperative Liver Enzyme Elevation After Laparoscopic Gastrectomy for Gastric Cancer. *In Vivo* 2021; **35**: 1227-1234 [PMID: [33622925](https://pubmed.ncbi.nlm.nih.gov/33622925/) DOI: [10.21873/invivo.12373](https://doi.org/10.21873/invivo.12373)]
- 27 **Lee S**, Son T, Song JH, Choi S, Cho M, Kim YM, Kim HI, Hyung WJ. Adverse Effects of Ligation of an Aberrant Left Hepatic Artery Arising from the Left Gastric Artery during Radical Gastrectomy for Gastric Cancer: a Propensity Score Matching Analysis. *J Gastric Cancer* 2021; **21**: 74-83 [PMID: [33854815](https://pubmed.ncbi.nlm.nih.gov/33854815/) DOI: [10.5230/jgc.2021.21.e6](https://doi.org/10.5230/jgc.2021.21.e6)]
- 28 **Ang RRG**, Lee HJ, Bae JS, Zhu CC, Berlth F, Kim TH, Park SH, Suh YS, Kong SH, Kim SH, Yang HK. Safety of Ligation of Aberrant Left Hepatic Artery Originating from Left Gastric Artery in Laparoscopic Gastrectomy for Gastric Cancer. *Sci Rep* 2020; **10**: 5856 [PMID: [32246010](https://pubmed.ncbi.nlm.nih.gov/32246010/) DOI: [10.1038/s41598-020-62587-7](https://doi.org/10.1038/s41598-020-62587-7)]
- 29 **Kim J**, Kim SM, Seo JE, Ha MH, An JY, Choi MG, Lee JH, Bae JM, Kim S, Jeong WK, Sohn TS. Should an Aberrant Left Hepatic Artery Arising from the Left Gastric Artery Be Preserved during Laparoscopic Gastrectomy for Early Gastric Cancer Treatment? *J Gastric Cancer* 2016; **16**: 72-77 [PMID: [27433391](https://pubmed.ncbi.nlm.nih.gov/27433391/) DOI: [10.5230/jgc.2016.16.2.72](https://doi.org/10.5230/jgc.2016.16.2.72)]
- 30 **Mays ET**, Wheeler CS. Demonstration of collateral arterial flow after interruption of hepatic arteries in man. *N Engl J Med* 1974; **290**: 993-996 [PMID: [4594527](https://pubmed.ncbi.nlm.nih.gov/4594527/) DOI: [10.1056/NEJM197405022901804](https://doi.org/10.1056/NEJM197405022901804)]



Published by **Baishideng Publishing Group Inc**
7041 Koll Center Parkway, Suite 160, Pleasanton, CA 94566, USA

Telephone: +1-925-3991568

E-mail: bpgoffice@wjgnet.com

Help Desk: <https://www.f6publishing.com/helpdesk>

<https://www.wjgnet.com>

