

World Journal of *Clinical Cases*

World J Clin Cases 2022 July 16; 10(20): 6759-7186



Contents

Thrice Monthly Volume 10 Number 20 July 16, 2022

OPINION REVIEW

- 6759 Semaglutide might be a key for breaking the vicious cycle of metabolically associated fatty liver disease spectrum?

Cigrovski Berkovic M, Rezić T, Bilic-Curcic I, Mrzljak A

MINIREVIEWS

- 6769 Drainage of pancreatic fluid collections in acute pancreatitis: A comprehensive overview
Bansal A, Gupta P, Singh AK, Shah J, Samanta J, Mandavdhare HS, Sharma V, Sinha SK, Dutta U, Sandhu MS, Kochhar R

- 6784 Frontiers of COVID-19-related myocarditis as assessed by cardiovascular magnetic resonance

Luo Y, Liu BT, Yuan WF, Zhao CX

ORIGINAL ARTICLE

Case Control Study

- 6794 Urinary and sexual function changes in benign prostatic hyperplasia patients before and after transurethral columnar balloon dilatation of the prostate

Zhang DP, Pan ZB, Zhang HT

- 6803 Effects of the information-knowledge-attitude-practice nursing model combined with predictability intervention on patients with cerebrovascular disease

Huo HL, Gui YY, Xu CM, Zhang Y, Li Q

Retrospective Cohort Study

- 6811 Effects of Kampo medicine hangebyakujutsutemmato on persistent postural-perceptual dizziness: A retrospective pilot study

Miwa T, Kanemaru SI

Retrospective Study

- 6825 Longitudinal changes in personalized platelet count metrics are good indicators of initial 3-year outcome in colorectal cancer

Herold Z, Herold M, Lohinszky J, Szasz AM, Dank M, Somogyi A

- 6845 Efficacy of Kegel exercises in preventing incontinence after partial division of internal anal sphincter during anal fistula surgery

Garg P, Yagnik VD, Kaur B, Menon GR, Dawka S

Observational Study

- 6855 Influence of the water jet system vs cavitron ultrasonic surgical aspirator for liver resection on the remnant liver

Hanaki T, Tsuda A, Sunaguchi T, Goto K, Morimoto M, Murakami Y, Kihara K, Matsunaga T, Yamamoto M, Tokuyasu N, Sakamoto T, Hasegawa T, Fujiwara Y

- 6865** Critical values of monitoring indexes for perioperative major adverse cardiac events in elderly patients with biliary diseases

Zhang ZM, Xie XY, Zhao Y, Zhang C, Liu Z, Liu LM, Zhu MW, Wan BJ, Deng H, Tian K, Guo ZT, Zhao XZ

- 6876** Comparative study of surface electromyography of masticatory muscles in patients with different types of bruxism

Lan KW, Jiang LL, Yan Y

Randomized Controlled Trial

- 6890** Dural puncture epidural technique provides better anesthesia quality in repeat cesarean delivery than epidural technique: Randomized controlled study

Wang SY, He Y, Zhu HJ, Han B

SYSTEMATIC REVIEWS

- 6900** Network pharmacology-based strategy for predicting therapy targets of Sanqi and Huangjing in diabetes mellitus

Cui XY, Wu X, Lu D, Wang D

META-ANALYSIS

- 6915** Endoscopic submucosal dissection for early signet ring cell gastric cancer: A systematic review and meta-analysis

Weng CY, Sun SP, Cai C, Xu JL, Lv B

- 6927** Prognostic value of computed tomography derived skeletal muscle mass index in lung cancer: A meta-analysis

Pan XL, Li HJ, Li Z, Li ZL

CASE REPORT

- 6936** Autosomal dominant osteopetrosis type II resulting from a *de novo* mutation in the *CLCN7* gene: A case report

Song XL, Peng LY, Wang DW, Wang H

- 6944** Clinical expression and mitochondrial deoxyribonucleic acid study in twins with 14484 Leber's hereditary optic neuropathy: A case report

Chuenkongkaew WL, Chinkulkitnivat B, Lertrit P, Chirapapaisan N, Kaewsutthi S, Suktitipat B, Mitrpant C

- 6954** Management of the enteroatmospheric fistula: A case report

Cho J, Sung K, Lee D

- 6960** Lower lip recurrent keratoacanthoma: A case report

Liu XG, Liu XG, Wang CJ, Wang HX, Wang XX

- 6966** Optic disc coloboma associated with macular retinoschisis: A case report

Zhang W, Peng XY

- 6974** A 7-year-old boy with recurrent cyanosis and tachypnea: A case report
Li S, Chen LN, Zhong L
- 6981** Schwannomatosis patient who was followed up for fifteen years: A case report
Li K, Liu SJ, Wang HB, Yin CY, Huang YS, Guo WT
- 6991** Intentional replantation combined root resection therapy for the treatment of type III radicular groove with two roots: A case report
Tan D, Li ST, Feng H, Wang ZC, Wen C, Nie MH
- 6999** Clinical features and genetic variations of severe neonatal hyperbilirubinemia: Five case reports
Lin F, Xu JX, Wu YH, Ma YB, Yang LY
- 7006** Percutaneous transhepatic access for catheter ablation of a patient with heterotaxy syndrome complicated with atrial fibrillation: A case report
Wang HX, Li N, An J, Han XB
- 7013** Secondary positioning of rotationally asymmetric refractive multifocal intraocular lens in a patient with glaucoma: A case report
Fan C, Zhou Y, Jiang J
- 7020** Laparoscopic repair of diaphragmatic hernia associating with radiofrequency ablation for hepatocellular carcinoma: A case report
Tsunoda J, Nishi T, Ito T, Inaguma G, Matsuzaki T, Seki H, Yasui N, Sakata M, Shimada A, Matsumoto H
- 7029** Hypopituitary syndrome with pituitary crisis in a patient with traumatic shock: A case report
Zhang XC, Sun Y
- 7037** Solitary plasmacytoma of the left rib misdiagnosed as angina pectoris: A case report
Yao J, He X, Wang CY, Hao L, Tan LL, Shen CJ, Hou MX
- 7045** Secondary coronary artery ostial lesions: Three case reports
Liu XP, Wang HJ, Gao JL, Ma GL, Xu XY, Ji LN, He RX, Qi BYE, Wang LC, Li CQ, Zhang YJ, Feng YB
- 7054** Bladder perforation injury after percutaneous peritoneal dialysis catheterization: A case report
Shi CX, Li ZX, Sun HT, Sun WQ, Ji Y, Jia SJ
- 7060** Myotonic dystrophy type 1 presenting with dyspnea: A case report
Jia YX, Dong CL, Xue JW, Duan XQ, Xu MY, Su XM, Li P
- 7068** Novel mutation in the *SALL1* gene in a four-generation Chinese family with uraemia: A case report
Fang JX, Zhang JS, Wang MM, Liu L
- 7076** Malignant transformation of primary mature teratoma of colon: A case report
Liu J

- 7082** Treatment of pyogenic liver abscess by surgical incision and drainage combined with platelet-rich plasma: A case report
Wang JH, Gao ZH, Qian HL, Li JS, Ji HM, Da MX
- 7090** Left bundle branch pacing in a ventricular pacing dependent patient with heart failure: A case report
Song BX, Wang XX, An Y, Zhang YY
- 7097** Solitary fibrous tumor of the liver: A case report and review of the literature
Xie GY, Zhu HB, Jin Y, Li BZ, Yu YQ, Li JT
- 7105** MutL homolog 1 germline mutation c.(453+1_454-1)_(545+1_546-1)del identified in lynch syndrome: A case report and review of literature
Zhang XW, Jia ZH, Zhao LP, Wu YS, Cui MH, Jia Y, Xu TM
- 7116** Malignant histiocytosis associated with mediastinal germ cell tumor: A case report
Yang PY, Ma XL, Zhao W, Fu LB, Zhang R, Zeng Q, Qin H, Yu T, Su Y
- 7124** Immunoglobulin G4 associated autoimmune cholangitis and pancreatitis following the administration of nivolumab: A case report
Agrawal R, Guzman G, Karimi S, Giulianotti PC, Lora AJM, Jain S, Khan M, Boulay BR, Chen Y
- 7130** Portal vein thrombosis in a noncirrhotic patient after hemihepatectomy: A case report and review of literature
Zhang SB, Hu ZX, Xing ZQ, Li A, Zhou XB, Liu JH
- 7138** Microvascular decompression for a patient with oculomotor palsy caused by posterior cerebral artery compression: A case report and literature review
Zhang J, Wei ZJ, Wang H, Yu YB, Sun HT
- 7147** Topical halometasone cream combined with fire needle pre-treatment for treatment of primary cutaneous amyloidosis: Two case reports
Su YQ, Liu ZY, Wei G, Zhang CM
- 7153** Simultaneous robot-assisted approach in a super-elderly patient with urothelial carcinoma and synchronous contralateral renal cell carcinoma: A case report
Yun JK, Kim SH, Kim WB, Kim HK, Lee SW
- 7163** Nursing a patient with latent autoimmune diabetes in adults with insulin-related lipodystrophy, allergy, and exogenous insulin autoimmune syndrome: A case report
He F, Xu LL, Li YX, Dong YX
- 7171** Incidental diagnosis of medullary thyroid carcinoma due to persistently elevated procalcitonin in a patient with COVID-19 pneumonia: A case report
Saha A, Mukhopadhyay M, Paul S, Bera A, Bandyopadhyay T
- 7178** Macular hole following phakic intraocular lens implantation: A case report
Li XJ, Duan JL, Ma JX, Shang QL

LETTER TO THE EDITOR

- 7184** Is every microorganism detected in the intensive care unit a nosocomial infection? Isn't prevention more important than detection?

Yildirim F, Karaman I, Yildirim M

ABOUT COVER

Editorial Board Member of *World Journal of Clinical Cases*, Jie-Feng Huang, PhD, Associate Chief Physician, Associate Professor, Department of Orthopaedics and Traumatology, The First Affiliated Hospital of Zhejiang Chinese Medical University, Hangzhou 310006, Zhejiang Province, China. 40983285@qq.com

AIMS AND SCOPE

The primary aim of *World Journal of Clinical Cases* (WJCC, *World J Clin Cases*) is to provide scholars and readers from various fields of clinical medicine with a platform to publish high-quality clinical research articles and communicate their research findings online.

WJCC mainly publishes articles reporting research results and findings obtained in the field of clinical medicine and covering a wide range of topics, including case control studies, retrospective cohort studies, retrospective studies, clinical trials studies, observational studies, prospective studies, randomized controlled trials, randomized clinical trials, systematic reviews, meta-analysis, and case reports.

INDEXING/ABSTRACTING

The WJCC is now indexed in Science Citation Index Expanded (also known as SciSearch®), Journal Citation Reports/Science Edition, Scopus, PubMed, and PubMed Central. The 2021 Edition of Journal Citation Reports® cites the 2020 impact factor (IF) for WJCC as 1.337; IF without journal self cites: 1.301; 5-year IF: 1.742; Journal Citation Indicator: 0.33; Ranking: 119 among 169 journals in medicine, general and internal; and Quartile category: Q3. The WJCC's CiteScore for 2020 is 0.8 and Scopus CiteScore rank 2020: General Medicine is 493/793.

RESPONSIBLE EDITORS FOR THIS ISSUE

Production Editor: Hua-Ge Yin, Production Department Director: Xu Guo, Editorial Office Director: Jin-Lei Wang.

NAME OF JOURNAL

World Journal of Clinical Cases

ISSN

ISSN 2307-8960 (online)

LAUNCH DATE

April 16, 2013

FREQUENCY

Thrice Monthly

EDITORS-IN-CHIEF

Bao-Gan Peng, Jerzy Tadeusz Chudek, George Kontogeorgos, Maurizio Serati, Ja Hyeon Ku

EDITORIAL BOARD MEMBERS

<https://www.wjgnet.com/2307-8960/editorialboard.htm>

PUBLICATION DATE

July 16, 2022

COPYRIGHT

© 2022 Baishideng Publishing Group Inc

INSTRUCTIONS TO AUTHORS

<https://www.wjgnet.com/bpg/gerinfo/204>

GUIDELINES FOR ETHICS DOCUMENTS

<https://www.wjgnet.com/bpg/GerInfo/287>

GUIDELINES FOR NON-NATIVE SPEAKERS OF ENGLISH

<https://www.wjgnet.com/bpg/gerinfo/240>

PUBLICATION ETHICS

<https://www.wjgnet.com/bpg/GerInfo/288>

PUBLICATION MISCONDUCT

<https://www.wjgnet.com/bpg/gerinfo/208>

ARTICLE PROCESSING CHARGE

<https://www.wjgnet.com/bpg/gerinfo/242>

STEPS FOR SUBMITTING MANUSCRIPTS

<https://www.wjgnet.com/bpg/GerInfo/239>

ONLINE SUBMISSION

<https://www.f6publishing.com>



Optic disc coloboma associated with macular retinoschisis: A case report

Wei Zhang, Xiao-Yan Peng

Specialty type: Ophthalmology

Provenance and peer review:

Unsolicited article; Externally peer reviewed.

Peer-review model: Single blind

Peer-review report's scientific quality classification

Grade A (Excellent): 0

Grade B (Very good): 0

Grade C (Good): 0

Grade D (Fair): 0

Grade E (Poor): 0

P-Reviewer: Mohapatra SSD, India

A-Editor: A

Received: September 27, 2021

Peer-review started: September 27, 2021

First decision: March 7, 2022

Revised: April 9, 2022

Accepted: May 22, 2022

Article in press: May 22, 2022

Published online: July 16, 2022



Wei Zhang, Xiao-Yan Peng, Beijing Ophthalmology and Visual Science Key Laboratory, Beijing Institute of Ophthalmology, Beijing Tongren Eye Center, Beijing Tongren Hospital, Capital Medical University, Beijing 100005, China

Corresponding author: Xiao-Yan Peng, PhD, Doctor, Professor, Beijing Ophthalmology and Visual Science Key Laboratory, Beijing Institute of Ophthalmology, Beijing Tongren Eye Center, Beijing Tongren Hospital, Capital Medical University, No. 17 Hougou Lane, Chongnei Street, Beijing 100005, China. drzhangwei2014@163.com

Abstract

BACKGROUND

To report an unusual case of bilateral optic disc coloboma associated with macular retinoschisis in the left eye.

CASE SUMMARY

A 37-year-old woman presented with complaints of blurred and distorted vision in her left eye for more than 1 year. Fundus examination demonstrated choroidal atrophy around the optic disc in both eyes, with a cup-to-disc ratio of 0.9. Serous retinal detachment in the macular area of the left eye. Left eye macular blood flow imaging optical coherence tomography (Angio-OCT) showed macular retinal serous cleavage. En-face OCT showed that the canal gully-like structure formed by the defect of the optic disc nerve fiber layer between the optic disc and macula, serous detachment area was connected with the enlarged optic disc coloboma through the canal gully-like structure, and the fluid leaked from the enlarged and thinned optic disc coloboma into the retinal layer of the macular area. Patients with optic disc abnormalities and macular degeneration must be monitored appropriately. During the follow-up period, the use of optic disc stereography and 3D-OCT, en-face, and Angio-OCT imaging can clarify the correlation between macular retinoschisis and optic disc coloboma.

CONCLUSION

Macular retinoschisis may be owing to the combined force of disc edge loss, enlarged optic disc coloboma, the canal gully-like structure formed by the defect of the nerve fiber layer around the optic disc, and the traction of the posterior vitreous cortex.

Key Words: Optic disc coloboma; Macular retinoschisis; Optical coherence tomography; Case report

Core Tip: We reported an unusual case of bilateral optic disc coloboma associated with macular retinoschisis in the left eye. Macular retinoschisis may be owing to the combined force of disc edge loss, enlarged optic disc coloboma, the canal gully-like structure formed by the defect of the nerve fiber layer around the optic disc, and the traction of the posterior vitreous cortex.

Citation: Zhang W, Peng XY. Optic disc coloboma associated with macular retinoschisis: A case report. *World J Clin Cases* 2022; 10(20): 6966-6973

URL: <https://www.wjgnet.com/2307-8960/full/v10/i20/6966.htm>

DOI: <https://dx.doi.org/10.12998/wjcc.v10.i20.6966>

INTRODUCTION

Clinically, optic disc coloboma is considered a bowl-shaped depression. The frequency of unilateral and bilateral occurrence is similar, and it is mostly owing to congenital optic disc abnormalities, physiological large optic cups, glaucoma optic disc cupping, and optic nerve atrophic coloboma[1-3]. Optic disc coloboma can cause abnormal visual fields[4-6]. The author found that optic disc coloboma is related to serous macular retinoschisis, which is similar to optic disc pit-related macular serous retinoschisis[7-9]. The literature regarding optic disc coloboma associated with macular retinoschisis is limited.

CASE PRESENTATION

Chief complaints

A 37-year-old woman presented with complaints of blurred and distorted vision in her left eye for more than 1 year.

History of present illness

There was no family history of ocular diseases. One month ago, she was diagnosed with left eye macular retinoschisis, and optic disc pit and underwent a left eye vitrectomy in another hospital.

History of past illness

The patient had no systemic diseases.

Personal and family history

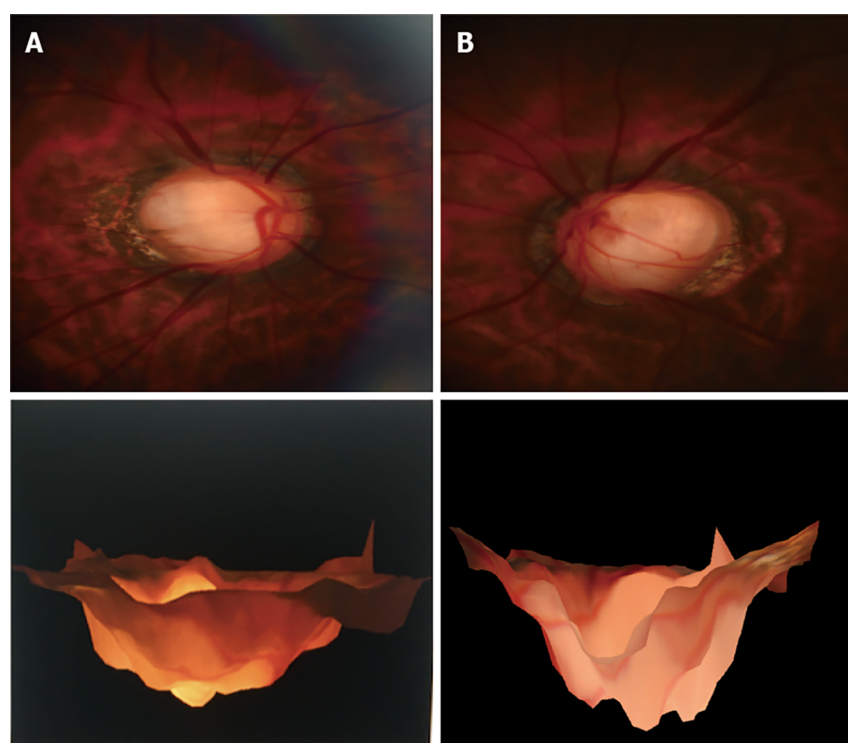
There was no family history of ocular diseases.

Physical examination

Ophthalmic examination showed the unaided visual acuity was 20/1000 in the right eye which was improving up to 20/20 (with -10.25 D) and 20/1000 in the left eye, improving up to 20/200 (with -10.75 D). Intraocular pressure (IOP) measured with Goldmann applanation tonometry was 10 mmHg and 12 mmHg in the right and left eye respectively. Examination of the anterior segment of both eyes showed no abnormality. Gonioscopy examination showed the normal width of the anterior chamber angle of both eyes. Fundus examination demonstrated choroidal atrophy around the optic disc in both eyes, with a cup-to-disc ratio of 0.9. Serous retinal detachment in the macular area of the left eye.

Imaging examinations

Magnetic head imaging revealed no brain abnormalities. Optic disc stereography (Kowa nonmyd WX 3D, Japan) demonstrated choroidal atrophy around the optic disc in both eyes, with optic disc coloboma is illustrated in Figure 1. Visual field examination for both eyes were performed with Humphrey Field Analyzer II (Zeiss) using 24-2 Swedish Interactive Threshold Algorithm (SITA) standard strategy. Binocular visual field examination revealed that the physiological blind spots of both eyes enlarged. Using IOL Master 700 (Zeiss), the axial length was measured as 27.72 mm and 27.42 mm for the right and left eyes, respectively. Blood flow imaging optical coherence tomography (United States Optovue, Angio-OCT) three-dimensional (3D) mode showed local defects in the temporal disc edge of the binocular optic disc. Moreover, the optic disc circular scan mode indicated that the thickness of the nerve fiber layer around the optic disc in the left eye was thinned. OCT B-scan of the left eye revealed



DOI: 10.12998/wjcc.v10.i20.6966 Copyright ©The Author(s) 2022.

Figure 1 Stereoscopic color photography of the optic disc of the right (A) and left (B) eyes.

macular serous neurosensory retinal detachment, discontinuity of the ellipsoid zone, and fracture of the outer nuclear layer of the retina. En-face OCT showed that the canal and gully-like structure formed by the defect of the optic disc nerve fiber layer between the optic disc and macula, serous detachment area, and the enlarged optic disc coloboma inferior to the temporal area were connected *via* the canal and gully-like structure. The fluid was considered to leak from the enlarged partial defect of the optic disc, gully-like thinning of the optic disc nerve fiber layer, and gully-like structure into the retinal layer of the macular area (Figures 2-4).

FINAL DIAGNOSIS

The final clinical diagnosis was optic disc coloboma in both eyes and optic disc coloboma associated with macular retinoschisis in the left eye.

TREATMENT

On November 27, 2019, posterior scleral macular buckling of the left eye was performed under general anesthesia.

OUTCOME AND FOLLOW-UP

Re-examination was performed at 3 mo, 6 mo, 12 mo, and 24 mo after operation. OCT showed complete recovery of the left eye serous macular retinoschisis until 24 mo after the operation (Figure 5). The visual acuity of the left eye was gradually improved to 20/33.

DISCUSSION

Congenital optic disc coloboma includes optic disc pit, optic nerve dysplasia, and morning glory syndrome. Congenital pits of the optic disc may be present alone or occasionally combined with optic disc defects[10]. Previous case reports have described the presence of optic disc defects in the same eye

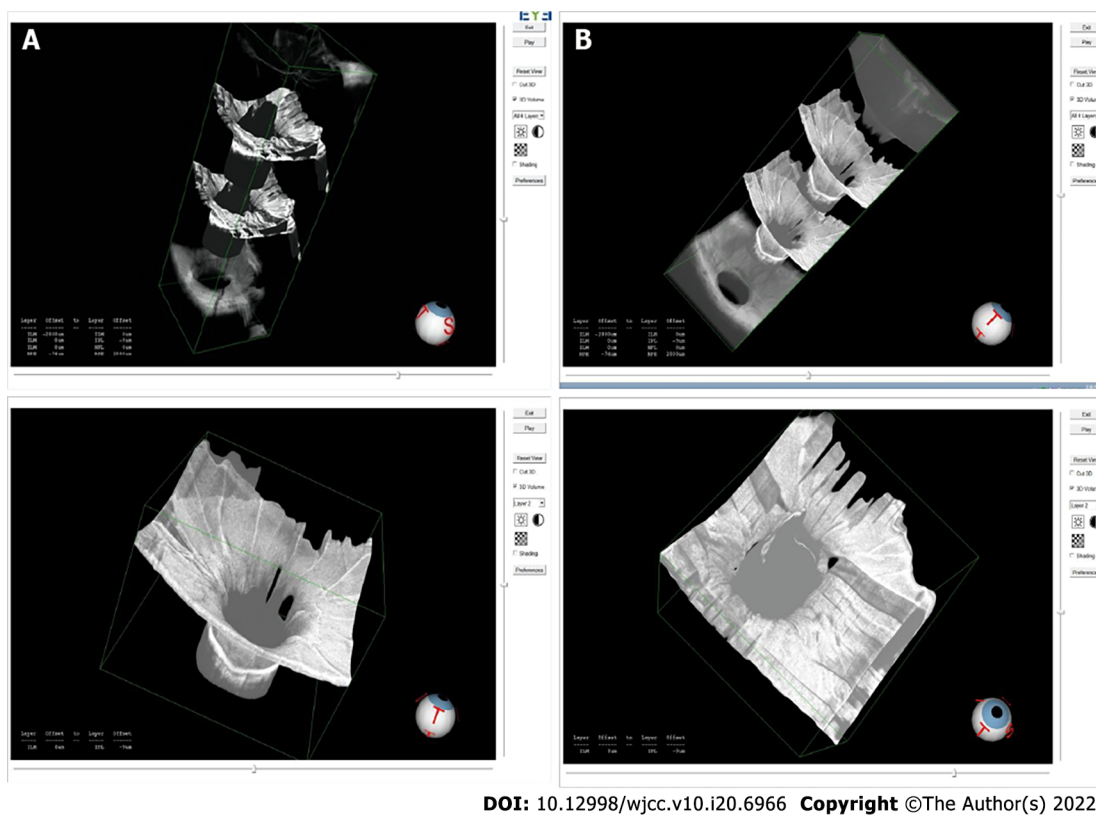


Figure 2 Three-dimensional optical coherence tomography optic disc mode of the optic disc of the right (A) and left (B) eyes.

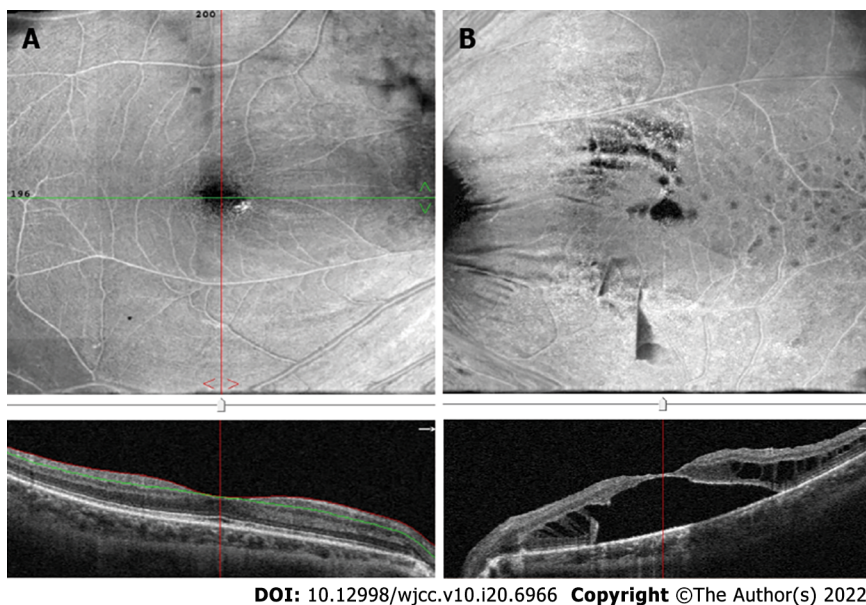


Figure 3 En-face-optical coherence tomography and B-scan macular pattern of the macula of right (A) and left (B) eyes.

combined with optic disc pit[11,12]. Optic nerve defects can occasionally be misdiagnosed as morning glory syndrome[13]. The pathophysiology of morning glory syndrome caused by abnormal fetal fissure closure is similar to that of optic disc defect[14]. However, tiny pigments can be detected with no glial hyperplasia around the optic disc in the optic disc defect, while a large amount of glial hyperplasia and pigment can be observed around papilla in the morning glory syndrome[15]. Additionally, Hotta *et al* [16] reported a case of choroidal and optic disc defect with a rare type of macular detachment and retinoschisis.

Serous macular retinoschisis related to optic disc coloboma is similar to that related to optic disc pit. The pathogenesis may be the result of multiple factors such as age, traction of the posterior vitreous

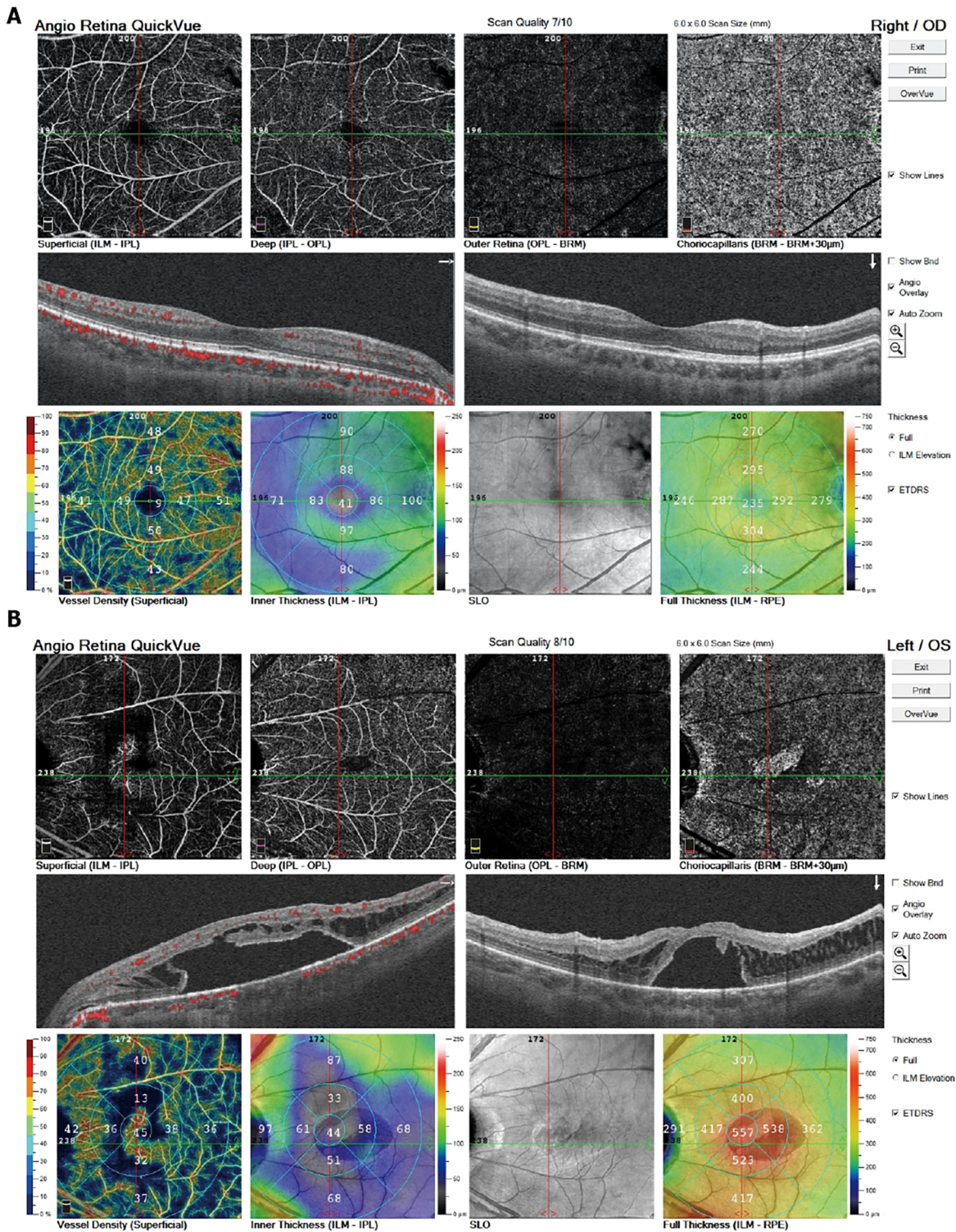
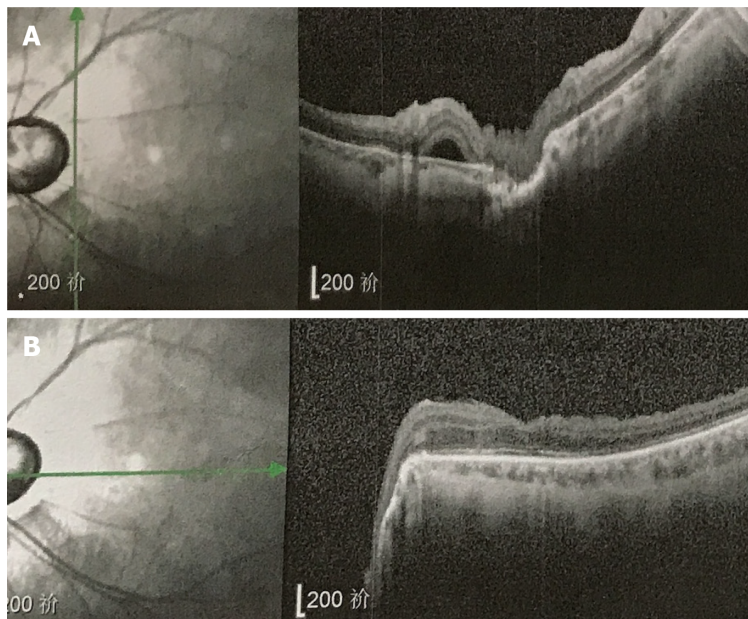


Figure 4 Angio-optical coherence tomography macular 6 mm × 6 mm pattern of the right (A) and left (B) eyes.

cortex, local defects of the optic disc coloboma, and peripheral nerves of the optic disc. The drainage channel formed by the local defect of the nerve fiber layer, fluctuation of IOP, direct natural potential gap between the neuroepithelium and the pigment epithelium, and high perfusion of the choroidal capillaries (similar to the pathogenesis of the central serous chorioretinopathy) are related to the peripheral nerves of the optic disc. The secondary related factors are the canal-like channel structure formed by the local defect of the nerve fiber layer and traction of the posterior vitreous cortex and other factors. There is evidence that retinal neuroepithelial detachment in the macula becomes obvious after the age of 20 years. Liconff described that the communication between the optic disc fovea and retina resulted in a split-like separation of the inner layer of the retina[17]. Cleavage formation is the first step in the progression of serous retinal detachment related to optic disc coloboma. Krivoy *et al*[18] believe

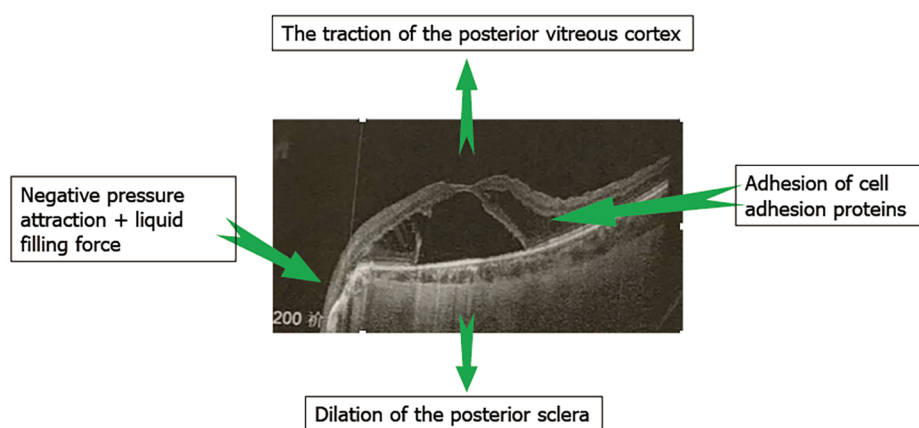


DOI: 10.12998/wjcc.v10.i20.6966 Copyright ©The Author(s) 2022.

Figure 5 Optical coherence tomography B-scan macular pattern of right (A) and left (B) eye for 2 years after surgery.

that the optic disc coloboma is the fluid passage between the subretinal fluid and cleavage cavity or subretinal space. SS-OCT draws a thin line in the optic disc, presumably related to the subretinal space. In an eye with an optic disc pit, the subretinal space has a direct connection with the vitreous cavity. Ohno-Matsui *et al*[19] reported that in 93.2% of highly myopic eyes, the subretinal space can be detected using SS-OCT. They believe that the subretinal space around the optic nerve is low reflex. In a patient with myopia, the subretinal space has a direct connection with the vitreous cavity. Previous reports have only inferred that in the optic disc pit, there is direct communication between the optic disc pit, vitreous cavity, and subretinal space. Kuhn *et al*[20] reported a case of an optic disc pit with silicone oil injected into the vitreous cavity. The echo of silicone oil was detected in the subretinal space, showing the communication between the subretinal space and the vitreous cavity. Additionally, the complete separation of the outer layer of the retina (full-thickness detachment of the macula) may be secondary and related to the hole in the outer layer of the macula. Some authors speculate that vitreous traction in the macula may be the cause of retinal detachment and cleavage in the macula. Therefore, vitrectomy with or without peeling the inner limiting membrane, laser photocoagulation, and intraocular gas packing can reduce or eliminate vitreous traction. A recent report found that simple vitrectomy without gas tamponade and intraocular laser can completely cure macular retinoschisis. Yokoi *et al*[21] used fundus photography and swept OCT images to evaluate six eyes of seven macular retinopathy patients with optic disc pit. They detected abnormal traction of the vitreous by reconstructing 3D swept OCT images and observing the vitreous at the vitreous retinal interface. This may be one of the causes of this disease. Visual acuity and OCT should be monitored through proper follow-up to observe retinal changes[22]. In our case, the most likely cause of visual impairment was the damage to the macular retinal ellipsoid zone of the left eye.

The 37-year-old patient, in this case, had no posterior detachment of the posterior vitreous cortex and had optic disc coloboma in both eyes. Further, 3D-OCT revealed more evident optic disc defects in the right eye than that in the left eye. Consequently, a serous macular retinoschisis occurred in the left eye. En-face OCT demonstrated that the canal and gully-like structure formed by local atrophy and loss of nerve fibers around the optic disc communicated with the macular retinoschisis, which might be the most fundamental cause of the disease. The pathogenesis of optic disc coloboma-related macular serous retinoschisis may be similar to optic disc pit-related macular serous retinal retinoschisis[23]. The age of onset is 30–40 years (the third decade)[24]. Posterior vitreous detachment appears gradually during this period. Another important factor may be the traction of the posterior cortex. Vitrectomy is considered the preferred and effective treatment. Even if vitrectomy is combined with optic disc edge laser, internal limiting membrane peeling and covering, gas filling, and posterior scleral macular buckling, this type of serous macular retinoschisis often results in complete recovery in 1–2 years. The success rate of different treatment methods reported in different studies is variable[25–27]. For fluids derived from the cerebrospinal fluid or vitreous liquids, which is still debatable. Both the liquids may enter the macular retinal layer. The cerebrospinal fluid enters through the defect of the lamina edge, and the vitreous humor enters through the deep coloboma of the large optic disc. The optic disc is composed of a scleral defect (the cup of the optic disc) and optic nerve fibers (the disc edge of the optic disc). Nerve fibers are tightly covered and horizontally distributed in the retinal hierarchy to prevent fluid from directly



DOI: 10.12998/wjcc.v10.i20.6966 Copyright ©The Author(s) 2022.

Figure 6 Macular retinoschisis associated with optic disc coloboma may be the result of the combined force.

entering the retinal layers and maintain the transparent state of the retina. Local nerve fiber defects may lose this covering and protection function, allowing fluid to easily enter between the retinal layers, causing serous macular cleavage. The fovea is the lowest point of fluid outflow, similar to an hourglass or a pool floor drain. Therefore, the liquid flows from the top to the bottom. Thus, the subretinal fluid flows from the coloboma of the optic disc to the center of the macula.

CONCLUSION

Macular retinoschisis may be owing to the combined force of disc edge loss, enlarged optic disc coloboma, the canal gully-like structure formed by the defect of the nerve fiber layer around the optic disc, and the traction of the posterior vitreous cortex (Figure 6). Vitrectomy may be the preferred and effective treatment for the macular retinoschisis associated with optic disc coloboma. Proper monitoring of patients with optic disc coloboma and macular degeneration is critical. The use of optic disc stereography, and 3D, En-face, and Angio-OCT imaging during the follow-up period can clarify the correlation between macular retinoschisis and optic disc coloboma.

FOOTNOTES

Author contributions: Zhang W data collection, data analysis and literature search; Peng XY conceived of the study, data collection and revision supervision; all authors participate the manuscript preparation and manuscript editing, read and approved the final manuscript.

Informed consent statement: Written informed consent was obtained from the patient.

Conflict-of-interest statement: The authors declare that they have no competing interests.

CARE Checklist (2016) statement: The authors have read the CARE Checklist (2016), and the manuscript was prepared and revised according to the CARE Checklist (2016).

Open-Access: This article is an open-access article that was selected by an in-house editor and fully peer-reviewed by external reviewers. It is distributed in accordance with the Creative Commons Attribution Non Commercial (CC BY-NC 4.0) license, which permits others to distribute, remix, adapt, build upon this work non-commercially, and license their derivative works on different terms, provided the original work is properly cited and the use is non-commercial. See: <https://creativecommons.org/licenses/by-nc/4.0/>

Country/Territory of origin: China

ORCID number: Xiao-Yan Peng 0000-0002-1422-6938.

S-Editor: Wu YXJ

L-Editor: A

P-Editor: Wu YXJ

REFERENCES

- 1 **Duvall J**, Miller SL, Cheattle E, Tso MO. Histopathologic study of ocular changes in a syndrome of multiple congenital anomalies. *Am J Ophthalmol* 1987; **103**: 701-705 [PMID: [3578469](#) DOI: [10.1016/s0002-9394\(14\)74333-8](#)]
- 2 **Dutton GN**. Congenital disorders of the optic nerve: excavations and hypoplasia. *Eye (Lond)* 2004; **18**: 1038-1048 [PMID: [15534588](#) DOI: [10.1038/sj.eye.6701545](#)]
- 3 **Georgalas I**, Ladas I, Georgopoulos G, Petrou P. Optic disc pit: a review. *Graefes Arch Clin Exp Ophthalmol* 2011; **249**: 1113-1122 [PMID: [21638030](#) DOI: [10.1007/s00417-011-1698-5](#)]
- 4 **Brown GC**, Shields JA, Goldberg RE. Congenital pits of the optic nerve head. II. Clinical studies in humans. *Ophthalmology* 1980; **87**: 51-65 [PMID: [7375086](#) DOI: [10.1016/s0161-6420\(80\)35278-0](#)]
- 5 **Brodsky MC**. Congenital optic disk anomalies. *Surv Ophthalmol* 1994; **39**: 89-112 [PMID: [7801227](#) DOI: [10.1016/0039-6257\(94\)90155-4](#)]
- 6 **Meirelles RL**, Aggio FB, Costa RA, Farah ME. STRATUS optical coherence tomography in unilateral colobomatous excavation of the optic disc and secondary retinoschisis. *Graefes Arch Clin Exp Ophthalmol* 2005; **243**: 76-81 [PMID: [15660280](#) DOI: [10.1007/s00417-004-0956-1](#)]
- 7 **Ohno-Matsui K**, Hirakata A, Inoue M, Akiba M, Ishibashi T. Evaluation of congenital optic disc pits and optic disc colobomas by swept-source optical coherence tomography. *Invest Ophthalmol Vis Sci* 2013; **54**: 7769-7778 [PMID: [24168988](#) DOI: [10.1167/iops.13-12901](#)]
- 8 **Vedantham V**. Double optic discs, optic disc coloboma, and pit: spectrum of hybrid disc anomalies in a single eye. *Arch Ophthalmol* 2005; **123**: 1450-1452 [PMID: [16219745](#) DOI: [10.1001/archophth.123.10.1450](#)]
- 9 **Özelece R**, Gürlü V, Güçlü H, Özal SA. Coexistence of optic pit and coloboma of iris, lens, and choroid: a case report. *Arq Bras Oftalmol* 2016; **79**: 328-329 [PMID: [27982214](#) DOI: [10.5935/0004-2749.20160093](#)]
- 10 **Denis D**, Girard N, Levy-Mozziconacci A, Berbis J, Matonti F. [Ocular coloboma and results of brain MRI: preliminary results]. *J Fr Ophtalmol* 2013; **36**: 210-220 [PMID: [23177150](#) DOI: [10.1016/j.jfo.2012.02.014](#)]
- 11 **Steinkuller PG**. The morning glory disk anomaly: case report and literature review. *J Pediatr Ophthalmol Strabismus* 1980; **17**: 81-87 [PMID: [7391902](#) DOI: [10.3928/0191-3913-19800301-06](#)]
- 12 **Kindler P**. Morning glory syndrome: unusual congenital optic disk anomaly. *Am J Ophthalmol* 1970; **69**: 376-384 [PMID: [5418855](#) DOI: [10.1016/0002-9394\(70\)92269-5](#)]
- 13 **Lee BJ**, Traboulsi EI. Update on the morning glory disc anomaly. *Ophthalmic Genet* 2008; **29**: 47-52 [PMID: [18484308](#) DOI: [10.1080/13816810801901876](#)]
- 14 **Takkar B**, Venkatesh P, Agarwal D, Kumar A. Optic disc coloboma with pit treated as glaucoma: diagnostic utility of ultrasound and swept source optical coherence tomography. *BMJ Case Rep* 2017; **2017** [PMID: [28830904](#) DOI: [10.1136/bcr-2017-221967](#)]
- 15 **Savell J**, Cook JR. Optic nerve colobomas of autosomal-dominant heredity. *Arch Ophthalmol* 1976; **94**: 395-400 [PMID: [945057](#) DOI: [10.1001/archophth.1976.03910030183002](#)]
- 16 **Hotta K**, Hirakata A, Hida T. Retinoschisis associated with disc coloboma. *Br J Ophthalmol* 1999; **83**: 124 [PMID: [10209452](#) DOI: [10.1136/bjo.83.1.123b](#)]
- 17 **Lincoff H**, Lopez R, Kreissig I, Yannuzzi L, Cox M, Burton T. Retinoschisis associated with optic nerve pits. *Arch Ophthalmol* 1988; **106**: 61-67 [PMID: [3337708](#) DOI: [10.1097/iae.0b013e31823f9abb](#)]
- 18 **Krivoy D**, Gentile R, Liebmman JM, Stegman Z, Rosen R, Walsh JB, Ritch R. Imaging congenital optic disc pits and associated maculopathy using optical coherence tomography. *Arch Ophthalmol* 1996; **114**: 165-170 [PMID: [8573019](#) DOI: [10.1001/archophth.1996.01100130159008](#)]
- 19 **Ohno-Matsui K**, Akiba M, Moriyama M, Ishibashi T, Tokoro T, Spaide RF. Imaging retrobulbar subarachnoid space around optic nerve by swept-source optical coherence tomography in eyes with pathologic myopia. *Invest Ophthalmol Vis Sci* 2011; **52**: 9644-9650 [PMID: [22076987](#) DOI: [10.1167/iops.11-8597](#)]
- 20 **Kuhn F**, Kover F, Szabo I, Mester V. Intracranial migration of silicone oil from an eye with optic pit. *Graefes Arch Clin Exp Ophthalmol* 2006; **244**: 1360-1362 [PMID: [16523301](#) DOI: [10.1007/s00417-006-0267-9](#)]
- 21 **Yokoi T**, Nakayama Y, Nishina S, Azuma N. Abnormal traction of the vitreous detected by swept-source optical coherence tomography is related to the maculopathy associated with optic disc pits. *Graefes Arch Clin Exp Ophthalmol* 2016; **254**: 675-682 [PMID: [26245337](#) DOI: [10.1007/s00417-015-3114-z](#)]
- 22 **Snead MP**, James N, Jacobs PM. Vitrectomy, argon laser, and gas tamponade for serous retinal detachment associated with an optic disc pit: a case report. *Br J Ophthalmol* 1991; **75**: 381-382 [PMID: [2043587](#) DOI: [10.1136/bjo.75.6.381](#)]
- 23 **Hirakata A**, Inoue M, Hiraoka T, McCuen BW 2nd. Vitrectomy without laser treatment or gas tamponade for macular detachment associated with an optic disc pit. *Ophthalmology* 2012; **119**: 810-818 [PMID: [22218142](#) DOI: [10.1016/j.ophtha.2011.09.026](#)]
- 24 **Ferry AP**. Macular detachment associated with congenital pit of the optic nerve head. pathologic findings in two cases simulating malignant melanoma of the choroid. *Arch Ophthalmol* 1963; **70**: 346-357 [PMID: [14048795](#) DOI: [10.1001/archophth.1963.00960050348014](#)]
- 25 **Besada E**, Barr R, Schatz S, Brewer C. Vitreal pathogenic role in optic pit foveolar retinoschisis and central serous retinopathy. *Clin Exp Optom* 2003; **86**: 390-398 [PMID: [14632616](#) DOI: [10.1111/j.1444-0938.2003.tb03084.x](#)]
- 26 **Irvine AR**, Crawford JB, Sullivan JH. The pathogenesis of retinal detachment with morning glory disc and optic pit. *Trans Am Ophthalmol Soc* 1986; **84**: 280-292 [PMID: [3590472](#) DOI: [10.1097/00006982-198600630-00002](#)]
- 27 **Schatz H**, McDonald HR. Treatment of sensory retinal detachment associated with optic nerve pit or coloboma. *Ophthalmology* 1988; **95**: 178-186 [DOI: [10.1016/S0161-6420\(88\)33197-0](#)]



Published by **Baishideng Publishing Group Inc**
7041 Koll Center Parkway, Suite 160, Pleasanton, CA 94566, USA

Telephone: +1-925-3991568

E-mail: bpgoffice@wjgnet.com

Help Desk: <https://www.f6publishing.com/helpdesk>

<https://www.wjgnet.com>

