

# World Journal of *Clinical Cases*

*World J Clin Cases* 2022 March 26; 10(9): 2660-2975



## Contents

Thrice Monthly Volume 10 Number 9 March 26, 2022

## REVIEW

- 2660 Role of metabolites derived from gut microbiota in inflammatory bowel disease  
*Zheng L, Wen XL, Duan SL*

## MINIREVIEWS

- 2678 Roles of Wnt/ $\beta$ -catenin signaling pathway related microRNAs in esophageal cancer  
*Chu CY, Wang R, Liu XL*
- 2687 Animal models applied to acute-on-chronic liver failure: Are new models required to understand the human condition?  
*Gama JFG, Cardoso LMDF, Lagrota-Candido JM, Alves LA*

## ORIGINAL ARTICLE

## Case Control Study

- 2700 Associations between coagulation factor XII, coagulation factor XI, and stability of venous thromboembolism: A case-control study  
*Meng Y, Li Y, Ye YJ, Ma Q, Zhang JB, Qin H, Deng YY, Tian HY*

## Retrospective Cohort Study

- 2710 Nomogram to predict the risk of endoscopic removal failure with forceps/baskets for treating submandibular stones  
*Huang Y, Liang PS, Yang YC, Cai WX, Tao Q*
- 2721 Association between anesthesia technique and complications after hip surgery in the elderly population  
*Guo LS, Wang LN, Xiao JB, Zhong M, Zhao GF*

## Retrospective Study

- 2733 Perforating and nonperforating indications in repeated surgeries for Crohn's disease  
*Shen WS, Huang XH, Liu RQ, Li CY, Li Y, Zhu WM*
- 2743 Treatment of *Pneumocystis jirovecii* pneumonia in non-human immunodeficiency virus-infected patients using a combination of trimethoprim-sulfamethoxazole and caspofungin  
*Wu HH, Fang SY, Chen YX, Feng LF*
- 2751 Acute kidney injury in traumatic brain injury intensive care unit patients  
*Huang ZY, Liu Y, Huang HF, Huang SH, Wang JX, Tian JF, Zeng WX, Lv RG, Jiang S, Gao JL, Gao Y, Yu XX*
- 2764 Enucleation combined with guided bone regeneration in small and medium-sized odontogenic jaw cysts  
*Cao YT, Gu QH, Wang YW, Jiang Q*

**Clinical Trials Study**

- 2773 Determination of the ED<sub>95</sub> of intranasal sufentanil combined with intranasal dexmedetomidine for moderate sedation during endoscopic ultrasonography

Zou Y, Li N, Shao LJZ, Liu FK, Xue FS, Tao X

**Observational Study**

- 2783 Overexpression of Ubiquilin4 is associated with poor prognosis in patients with cervical cancer

Wang LN, Huang KJ, Wang L, Cheng HY

**Randomized Clinical Trial**

- 2792 Peplau's interpersonal relationship theory combined with bladder function training on patients with prostate cancer

Yang XH, Wu LF, Yan XY, Zhou Y, Liu X

**SYSTEMATIC REVIEWS**

- 2801 Efficacy of bone grafts in jaw cystic lesions: A systematic review

Wang J, Yao QY, Zhu HY

**CASE REPORT**

- 2811 Short stature associated with a novel mutation in the aggrecan gene: A case report and literature review

Yin LP, Zheng HX, Zhu H

- 2818 Treatment with sorafenib plus camrelizumab after splenectomy for primary splenic angiosarcoma with liver metastasis: A case report and literature review

Pan D, Li TP, Xiong JH, Wang SB, Chen YX, Li JF, Xiao Q

- 2829 Sarcomatoid intrahepatic cholangiocarcinoma with good patient prognosis after treatment with Huaier granules following hepatectomy: A case report

Feng JY, Li XP, Wu ZY, Ying LP, Xin C, Dai ZZ, Shen Y, Wu YF

- 2836 Sequential occurrence of T790M mutation and small cell lung cancer transformation in EGFR-positive lung adenocarcinoma: A case report

Hong E, Chen XE, Mao J, Zhou JJ, Chen L, Xu JY, Tao W

- 2844 Early diagnosis of Gitelman syndrome in a young child: A case report

Wu CY, Tsai MH, Chen CC, Kao CH

- 2851 Congenital intestinal malrotation with gastric wall defects causing extensive gut necrosis and short gut syndrome: A case report

Wang Y, Gu Y, Ma D, Guo WX, Zhang YF

- 2858 Delusional parasitosis as premotor symptom of parkinson's disease: A case report

Oh M, Kim JW, Lee SM

- 2864** Laninamivir-induced ischemic enterocolitis: A case report  
*Suzuki C, Kenzaka T*
- 2871** Intramural pregnancy after *in vitro* fertilization and embryo transfer: A case report  
*Xie QJ, Li X, Ni DY, Ji H, Zhao C, Ling XF*
- 2878** Bilateral ureteral reimplantation in a patient with an intraperitoneal ectopic bipenis: A case report  
*Jia YT, Shi BL, Zhang J, Li YY, Zhu J*
- 2883** Lumbar disc sequestration mimicking a tumor: Report of four cases and a literature review  
*Li ST, Zhang T, Shi XW, Liu H, Yang CW, Zhen P, Li SK*
- 2895** Parasitic leiomyoma in the trocar site after laparoscopic myomectomy: A case report  
*Roh CK, Kwon HJ, Jung MJ*
- 2901** Giant nontraumatic myositis ossificans in a child: A case report  
*Xia AN, Wang JS*
- 2908** Paradoxical carbon dioxide embolism during laparoscopic hepatectomy without intracardiac shunt: A case report  
*Jeon S, Hong JM, Lee HJ, Kim Y, Kang H, Hwang BY, Lee D, Jung YH*
- 2916** Local hyperthermia combined with chemotherapy for the treatment of multiple recurrences of *undifferentiated pleomorphic sarcoma*: A case report  
*Zhou YT, Wang RY, Zhang Y, Li DY, Yu J*
- 2923** Acute coronary artery stent thrombosis caused by a spasm: A case report  
*Meng LP, Wang P, Peng F*
- 2931** Turner syndrome with primary myelofibrosis, cirrhosis and ovarian cystic mass: A case report  
*Xu LW, Su YZ, Tao HF*
- 2938** Esophageal myoepithelial carcinoma: Four case reports  
*Lu H, Zhao HP, Liu YY, Yu J, Wang R, Gao JB*
- 2948** Ipsilateral hemifacial microsomia with dextrocardia and pulmonary hypoplasia: A case report  
*Guo R, Chang SH, Wang BQ, Zhang QG*
- 2954** Upper gastrointestinal bleeding from a Mallory-Weiss tear associated with transesophageal echocardiography during successful cardiopulmonary resuscitation: A case report  
*Tang MM, Fang DF, Liu B*
- 2961** Malignant struma ovarii with papillary carcinoma combined with retroperitoneal lymph node metastasis: A case report  
*Xiao W, Zhou JR, Chen D*

- 2969** Occult colon cancer with sepsis as the primary manifestation identified by bone marrow puncture: A case report

*Wang HJ, Zhou CJ*

**ABOUT COVER**

Editorial Board Member of *World Journal of Clinical Cases*, Arunchai Chang, MD, Assistant Professor, Lecturer, Staff Physician, Division of Gastroenterology, Department of Internal Medicine, Hatyai Hospital, Hatyai 90110, Songkhla, Thailand. busmdcu58@gmail.com

**AIMS AND SCOPE**

The primary aim of *World Journal of Clinical Cases* (WJCC, *World J Clin Cases*) is to provide scholars and readers from various fields of clinical medicine with a platform to publish high-quality clinical research articles and communicate their research findings online.

WJCC mainly publishes articles reporting research results and findings obtained in the field of clinical medicine and covering a wide range of topics, including case control studies, retrospective cohort studies, retrospective studies, clinical trials studies, observational studies, prospective studies, randomized controlled trials, randomized clinical trials, systematic reviews, meta-analysis, and case reports.

**INDEXING/ABSTRACTING**

The WJCC is now indexed in Science Citation Index Expanded (also known as SciSearch®), Journal Citation Reports/Science Edition, Scopus, PubMed, and PubMed Central. The 2021 Edition of Journal Citation Reports® cites the 2020 impact factor (IF) for WJCC as 1.337; IF without journal self cites: 1.301; 5-year IF: 1.742; Journal Citation Indicator: 0.33; Ranking: 119 among 169 journals in medicine, general and internal; and Quartile category: Q3. The WJCC's CiteScore for 2020 is 0.8 and Scopus CiteScore rank 2020: General Medicine is 493/793.

**RESPONSIBLE EDITORS FOR THIS ISSUE**

Production Editor: *Ying-Yi Yuan*, Production Department Director: *Xiang Li*, Editorial Office Director: *Jin-Lei Wang*.

**NAME OF JOURNAL**

*World Journal of Clinical Cases*

**ISSN**

ISSN 2307-8960 (online)

**LAUNCH DATE**

April 16, 2013

**FREQUENCY**

Thrice Monthly

**EDITORS-IN-CHIEF**

Bao-Gan Peng, Jerzy Tadeusz Chudek, George Kontogeorgos, Maurizio Serati, Ja Hyeon Ku

**EDITORIAL BOARD MEMBERS**

<https://www.wjgnet.com/2307-8960/editorialboard.htm>

**PUBLICATION DATE**

March 26, 2022

**COPYRIGHT**

© 2022 Baishideng Publishing Group Inc

**INSTRUCTIONS TO AUTHORS**

<https://www.wjgnet.com/bpg/gerinfo/204>

**GUIDELINES FOR ETHICS DOCUMENTS**

<https://www.wjgnet.com/bpg/GerInfo/287>

**GUIDELINES FOR NON-NATIVE SPEAKERS OF ENGLISH**

<https://www.wjgnet.com/bpg/gerinfo/240>

**PUBLICATION ETHICS**

<https://www.wjgnet.com/bpg/GerInfo/288>

**PUBLICATION MISCONDUCT**

<https://www.wjgnet.com/bpg/gerinfo/208>

**ARTICLE PROCESSING CHARGE**

<https://www.wjgnet.com/bpg/gerinfo/242>

**STEPS FOR SUBMITTING MANUSCRIPTS**

<https://www.wjgnet.com/bpg/GerInfo/239>

**ONLINE SUBMISSION**

<https://www.f6publishing.com>



## Acute coronary artery stent thrombosis caused by a spasm: A case report

Li-Ping Meng, Ping Wang, Fang Peng

**Specialty type:** Cardiac and cardiovascular systems

**Provenance and peer review:** Unsolicited article; externally peer-reviewed.

**Peer-review model:** Single-blind

**Peer-review report's scientific quality classification**

Grade A (Excellent): 0  
Grade B (Very good): 0  
Grade C (Good): C, C  
Grade D (Fair): D  
Grade E (Poor): 0

**P-Reviewer:** TERAGAWA H, Wang P

**Received:** October 7, 2021

**Peer-review started:** October 7, 2021

**First decision:** December 17, 2021

**Revised:** December 25, 2021

**Accepted:** February 20, 2022

**Article in press:** February 20, 2022

**Published online:** March 26, 2022



**Li-Ping Meng, Ping Wang, Fang Peng**, Department of Cardiology, Shaoxing People's Hospital, Shaoxing 312000, Zhejiang Province, China

**Corresponding author:** Fang Peng, MD, Chief Doctor, Department of Cardiology, Shaoxing People's Hospital, No. 568 Zhongxing North Road, Shaoxing 312000, Zhejiang Province, China. [sxrmyypf@126.com](mailto:sxrmyypf@126.com)

### Abstract

#### BACKGROUND

Acute stent thrombosis (AST) is a serious complication of percutaneous coronary intervention (PCI). The causes of AST include the use of stents of inappropriate diameters, multiple overlapping stents, or excessively long stents; incomplete stent expansion; poor stent adhesion; incomplete coverage of dissection; formation of thrombosis or intramural hematomas; vascular injury secondary to intraoperative mechanical manipulation; insufficient dose administration of postoperative antiplatelet medications; and resistance to antiplatelet drugs. Cases of AST secondary to coronary artery spasms are rare, with only a few reports in the literature.

#### CASE SUMMARY

A 55-year-old man was admitted to the hospital with a chief complaint of back pain for 2 d. He was diagnosed with coronary heart disease and acute myocardial infarction (AMI) based on electrocardiography results and creatinine kinase myocardial band, troponin I, and troponin T levels. A 2.5 mm × 33.0 mm drug-eluting stent was inserted into the occluded portion of the right coronary artery. Aspirin, clopidogrel, and atorvastatin were started. Six days later, the patient developed AST after taking a bath in the morning. Repeat coronary angiography showed occlusion of the proximal stent, and intravascular ultrasound showed severe coronary artery spasms. The patient's AST was thought to be caused by coronary artery spasms and treated with percutaneous transluminal coronary angioplasty. Postoperatively, he was administered diltiazem to inhibit coronary artery spasms and prevent future episodes of AST. He survived and reported no discomfort at the 2-mo follow-up after the operation and initiation of drug treatment.

#### CONCLUSION

Coronary spasms can cause both AMI and AST. For patients who exhibit coronary spasms during PCI, diltiazem administration could reduce spasms and prevent

future AST.

**Key Words:** Acute stent thrombosis; Coronary spasm; Kounis syndrome; Case report

©The Author(s) 2022. Published by Baishideng Publishing Group Inc. All rights reserved.

**Core Tip:** Acute stent thrombosis (AST) is a serious complication of percutaneous coronary intervention (PCI). The causes of AST include the use of stents of inappropriate diameters, multiple overlapping stents, or excessively long stents; incomplete stent expansion; poor stent adhesion; incomplete coverage of dissection; formation of thrombosis or intramural hematomas; vascular injury secondary to intraoperative mechanical manipulation; insufficient dose administration of postoperative antiplatelet medications; and resistance to antiplatelet drugs. Cases of AST secondary to coronary artery spasms are rare. We report a case of AST in a 52-year-old man possibly caused by a coronary artery spasm. Coronary spasms can cause both AMI and AST. For patients with coronary spasms during PCI, diltiazem administration could reduce spasms and prevent future AST.

**Citation:** Meng LP, Wang P, Peng F. Acute coronary artery stent thrombosis caused by a spasm: A case report. *World J Clin Cases* 2022; 10(9): 2923-2930

**URL:** <https://www.wjgnet.com/2307-8960/full/v10/i9/2923.htm>

**DOI:** <https://dx.doi.org/10.12998/wjcc.v10.i9.2923>

## INTRODUCTION

Acute stent thrombosis (AST) is a serious complication of percutaneous coronary intervention (PCI). When bare metal stents were often used, the incidence rate of AST was approximately 1.2% [1]. However, in recent years, because of the widespread use of drug-eluting stents and continuous advancements in the treatment of complex lesions, the incidence rate of AST has been increasing [2]. Currently, the known causes of AST include the use of stents of inappropriate diameters, multiple overlapping stents, or excessively long stents; incomplete coverage of dissection; incomplete stent expansion; poor stent adhesion; formation of thrombosis or intramural hematomas; vascular injury secondary to intraoperative mechanical manipulation; insufficient dose administration of postoperative antiplatelet medications; and resistance to antiplatelet drugs [3,4]. However, the occurrence of AST secondary to coronary artery spasms is rare, with only a few cases reported in the literature [5]. Here, we report a case of AST possibly caused by a coronary artery spasm.

## CASE PRESENTATION

### Chief complaints

A 55-year-old man was admitted to the hospital with a chief complaint of back pain for 2 d.

### History of present illness

Two days before admission, the patient developed non-radiating back pain, nausea, discomfort, fatigue, and an impending sense of doom. He reported no shortness of breath or vomiting. His symptoms lasted for 6-7 h and improved afterwards. He did not seek medical consultation until the day of admission.

### History of past illness

The patient had hypertension for 3 years and was on irbesartan 80 mg qd.

### Personal and family history

The patient reported no history of smoking, diabetes, or malignancy.

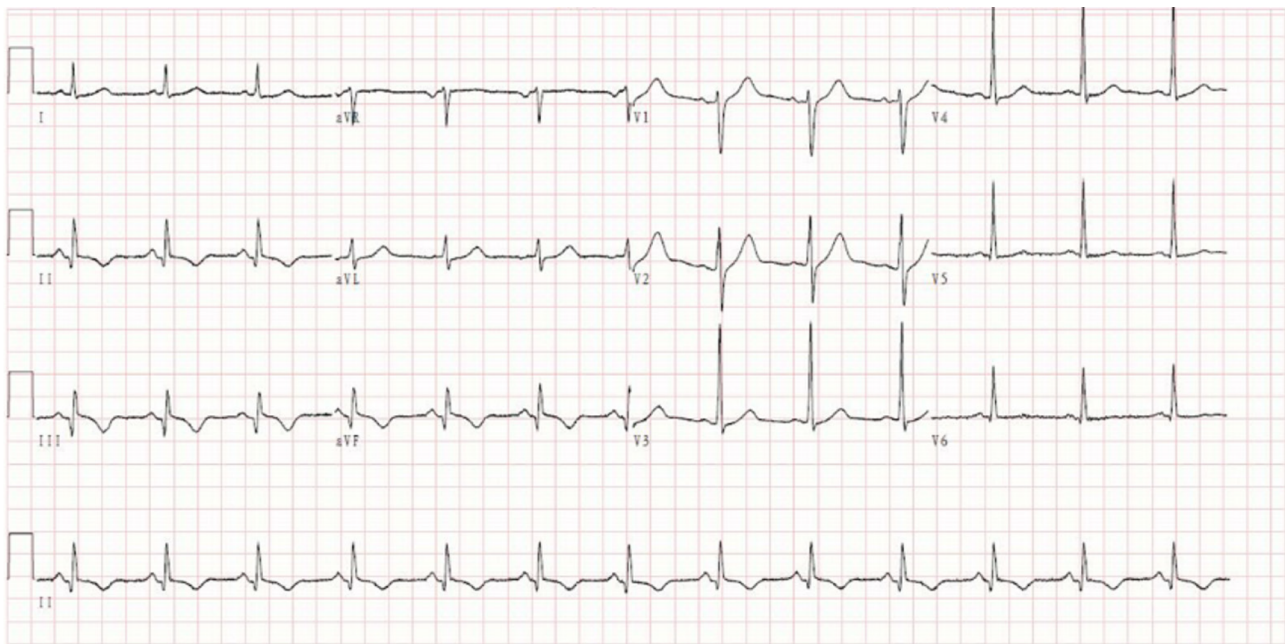
### Physical examination

Physical examination revealed no abnormalities.

### Laboratory examinations

At the hospital, the electrocardiogram showed a sinus rhythm; possible inferior myocardial infarction in leads II, III, and aVF; and mild ST-segment depression. The patient was administered with ticagrelor 180





DOI: 10.12998/wjcc.v10.i9.2923 Copyright ©The Author(s) 2022.

**Figure 1** The first electrocardiogram of the patient at the emergency department shows inferior myocardial infarction.

mg, aspirin 300 mg, and atorvastatin 20 mg before emergency department transfer. The repeat electrocardiogram showed an abnormal sinus rhythm; Q wave; and II, III, aVF T-wave changes (Figure 1). Blood examination revealed a troponin level of 23.85 ng/mL and a creatine kinase myocardial band isoenzyme level of 90.2 U/L. The patient was admitted to the critical care unit for acute inferior myocardial infarction.

### Imaging examinations

Six days later, the patient's troponin levels returned to normal. Coronary angiography showed no left main coronary or left circumflex artery stenosis, 60% stenosis in the proximal left anterior descending artery, 60%-70% stenosis in the proximal right coronary artery (RCA), and complete occlusion of the middle parts of the RCA (Figure 2A).

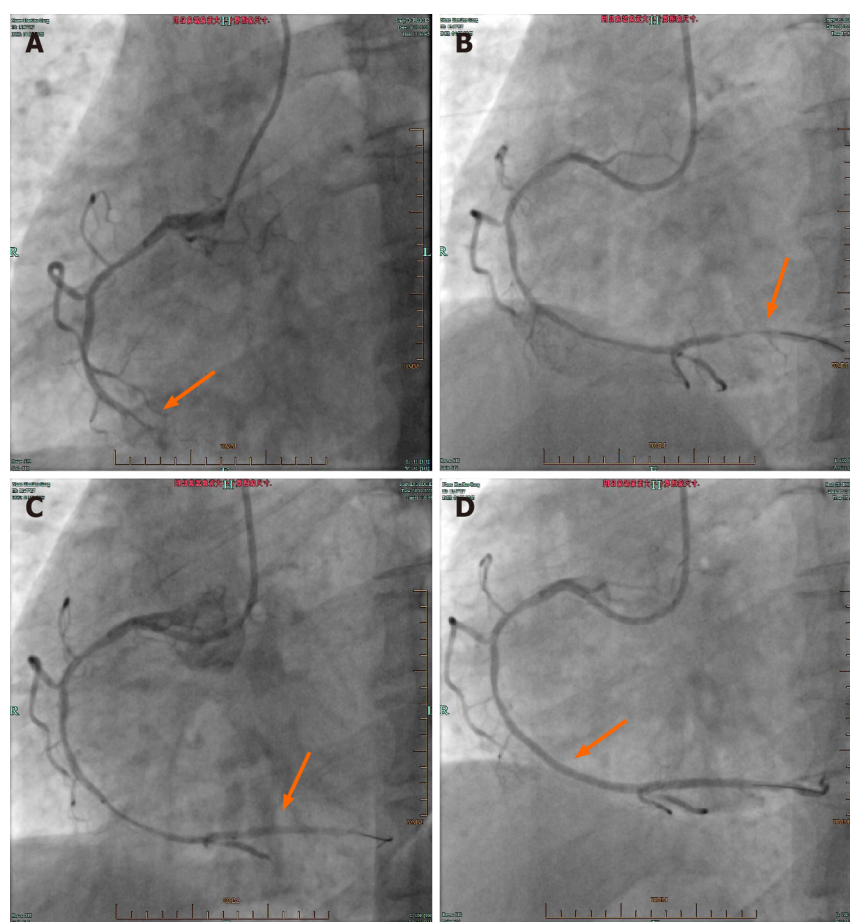
Balloon angioplasty was performed with a 2.0 mm × 15.0 mm balloon in the middle part of the RCA. Repeat angiography showed 90% stenosis in both the middle and distal parts of the RCA (Figure 2B). Distal RCA stenosis resolved after injecting 2 mL of nitroglycerin (Figure 2C). A 2.5 mm × 33.0 mm drug-eluting stent was then inserted into the middle part of the RCA. A Thrombolysis in Myocardial Infarction (TIMI) flow grade of 3 was documented postoperatively (Figure 2D).

## FINAL DIAGNOSIS

Final diagnoses of coronary heart disease, acute myocardial infarction (AMI), and AST were made.

## TREATMENT

The patient was started on aspirin, clopidogrel, and atorvastatin. He recovered well from the operation and was scheduled to leave the hospital on June 15, 2020. However, on the day of the supposed discharge, he suddenly developed pain and discomfort in his back lasting over 10 min. The electrocardiogram showed a sinus rhythm with abnormal Q waves and ST elevations of 0.05-0.10 mv in leads II, III, and aVF (Figure 3). His symptoms improved slightly after sublingual nitroglycerin administration. AST was suspected, and he was transferred to the digital subtraction tomography room. Coronary angiography showed occlusion in the proximal stent (Figure 4A, Video 1). After performing percutaneous transluminal coronary angioplasty using a 2.5 mm × 20.0 mm balloon, the distal end of the RCA showed 90% stenosis. After expanding the stent sequentially from the distal to proximal segments using 15 atm pressure, RCA showed 90% stenosis (Figure 4B). The balloon was withdrawn, and intracoronary nitroglycerin was administered. Repeat angiography then revealed a patent distal coronary artery with TIMI flow grade 3 (Figure 4C). An intravascular ultrasound catheter inserted



DOI: 10.12998/wjcc.v10.i9.2923 Copyright ©The Author(s) 2022.

**Figure 2 Photographs of the patient's first emergency percutaneous coronary intervention.** A: 60%-70% diffuse stenosis in the proximal part of the right coronary artery, approximately 50% stenosis in the middle part, and total occlusion beyond the middle and distal parts; B: After balloon dilation, digital subtraction angiography shows 90% stenosis in the middle and distal parts of the right coronary and 90% stenosis in the distal part; C: Stenosis of the distal right coronary artery has disappeared after injecting 2 mL of nitroglycerin; D: No stenosis in the middle or distal part of the right coronary artery after stent implantation, with Thrombolysis in Myocardial Infarction flow grade 3.

in the distal end of the right coronary artery showed no obvious plaque (Figure 5A) and good adherence of the stent (Figure 5B). Postoperatively, the etiology of AST was suspected to be coronary artery spasms. Diltiazem administration was started to reduce coronary artery spasms. Postoperatively, back discomfort disappeared, and ST segments in leads II, III, and aVF dropped.

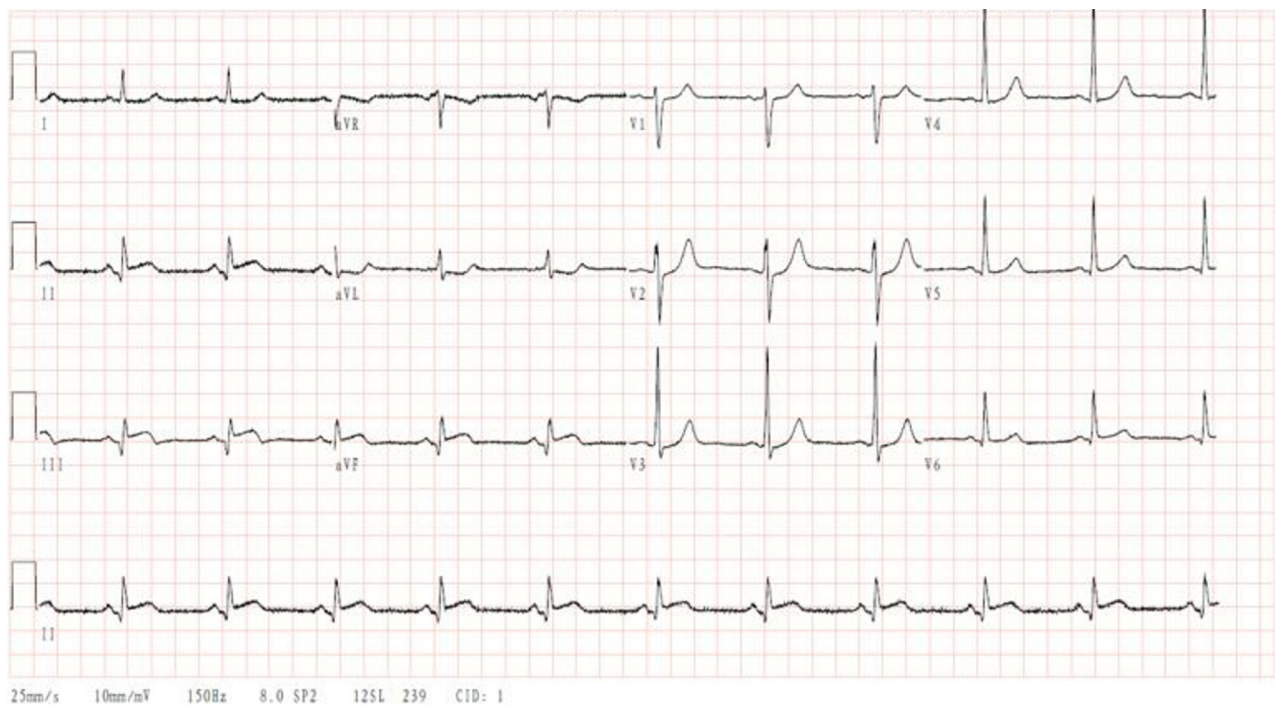
## OUTCOME AND FOLLOW-UP

On hospitalization day 4, the patient reported no discomfort. He was discharged and started on antiplatelet therapy with aspirin and clopidogrel, diltiazem to reduce coronary spasms, and atorvastatin to stabilize atherosclerotic plaques. He reported no discomfort at the 2-mo follow-up.

## DISCUSSION

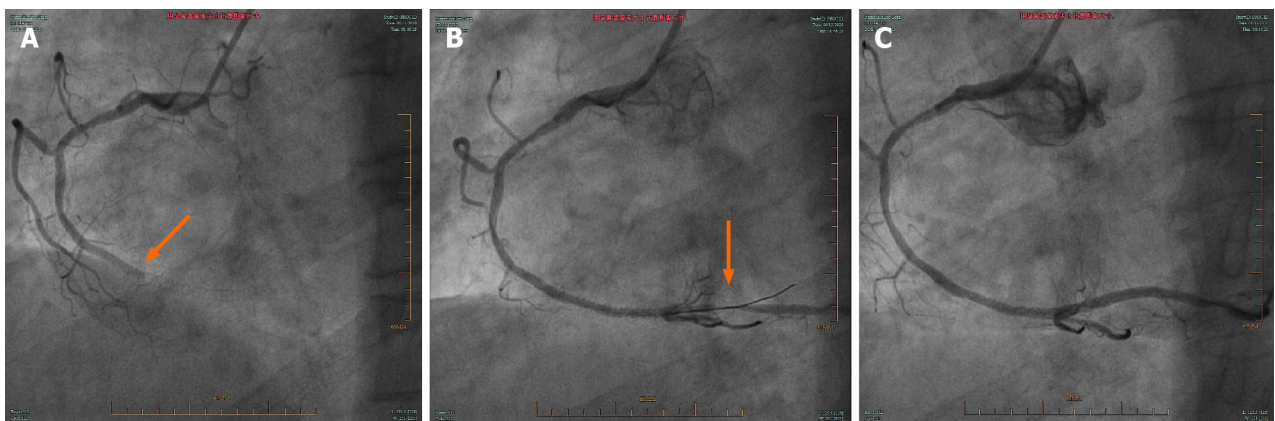
AST is a serious complication of PCI. A recent meta-analysis of 30 clinical studies involving a total 221066 patients showed that the incidences of confirmed, highly probable, and possible AST were 0.4%, 0.2%, and 0.6%, respectively[6]. Despite the low incidence, AST leads to acute coronary syndrome and has a mortality rate of 20%-40%[7]. Understanding the risk factors for AST and pathophysiology of its occurrence and development may provide insights to aid the development of preventive and active treatments.

Iakovou *et al*[8] showed that decreased left ventricular ejection fraction is associated with the occurrence of AST. The ACUTY trial showed that insulin-treated diabetes and ST-segment elevations  $\geq 0.1$  mv are independent risk factors for AST within 1 year after PCI[9]. Kuchulakanti *et al*[7] showed that diabetes and acute and chronic renal failure are risk factors for AST in patients with drug-coated stent



DOI: 10.12998/wjcc.v10.i9.2923 Copyright ©The Author(s) 2022.

**Figure 3** The electrocardiogram shows inferior myocardial infarction after the patient has taken a bath.



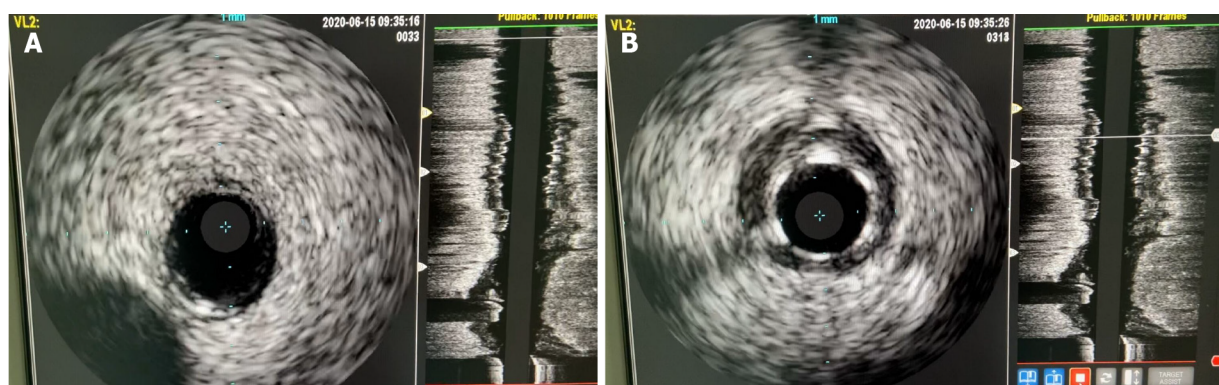
DOI: 10.12998/wjcc.v10.i9.2923 Copyright ©The Author(s) 2022.

**Figure 4** Acute thrombosis in a stent undergoing emergency percutaneous coronary intervention. A: The proximal part of the right coronary artery stent is occluded; B: After thrombus formation in the balloon-expanded stent, 90% stenosis of the distal right coronary artery is seen on the radiograph; C: The distal part of the right coronary artery is patent after the second nitroglycerin administration into the coronary artery, with Thrombolysis in Myocardial Infarction flow grade 3.

implants. A study on platelet hyperresponsiveness to adenosine diphosphate involving over 10000 patients proposed platelet hyperresponsiveness as a major risk factor for AST after PCI[10]. Insufficient use or premature discontinuation of antiplatelet drugs and clopidogrel resistance are also major causes of thrombosis after PCI. In recent years, cases of AST secondary to heparin-induced thrombocytopenia have been reported frequently[11,12].

Clinical risk factors for AST include current or past acute coronary syndrome, diabetes, and smoking. Coronary artery disease-related risk factors for AST include restenosis, bridging vessel disease, opening, coronary artery bifurcation, chronic occlusive arterial disease, and small vessel disease. Intraoperative technical risk factors for AST include the use of stents of inappropriate diameters, multiple overlapping stents, or excessively long stents; incomplete coverage of dissection; incomplete stent expansion; poor stent adherence; formation of thrombosis or intramural hematomas, and vascular damage secondary to mechanical manipulation. Drug-related risk factors for AST include poor response to aspirin or clopidogrel and premature discontinuation of antiplatelet drugs.





DOI: 10.12998/wjcc.v10.i9.2923 Copyright ©The Author(s) 2022.

**Figure 5 Intravascular ultrasound shows coronary stenosis.** A: The distal end of the right coronary artery shows no stenosis; B: The stent adheres well and shows no stenosis.

Coronary artery spasms can lead to acute coronary syndrome and myocardial infarction[13,14]; however, the occurrence of AST secondary to coronary spasms is rare and often only reported in the context of Kounis syndrome[15,16]. Kounis syndrome refers to the occurrence of acute coronary syndrome secondary to an allergic reaction. Exposure to allergens induces derangements in the neuroendocrine system and mast cell degranulation. This releases abundant inflammatory transmitters, which lead to coronary artery spasms or atherosclerotic plaque rupture. These events ultimately lead to stent thrombosis and AMI. Greif *et al*[5] reported a case of AST caused by a wasp bite after PCI. Tzanis *et al*[17] reported a case of early stent thrombosis secondary to an allergic reaction caused by rice intake. In our case, spasms were observed at the distal end of the coronary artery during PCI and resolved with nitroglycerin administration. At first, the spasms were not adequately appreciable and simply thought to be an effect of the surgical procedure, eluding the possibility of myocardial infarction resulting from a coronary artery spasm. During the second operation, the distal end of the stent showed severe stenosis after passing the balloon; however, the stenosis disappeared after intracoronary nitroglycerin administration, and subsequent intravascular ultrasound confirmed coronary artery spasms as the cause. The cold bath before the occurrence of AST was the patient's first bath after 12 d of bed rest. It acted as an acute stimulus to the body and possibly caused neuroendocrine derangements that ultimately led to coronary artery spasms at the distal end of the stent. After adjusting the patient's medications, subsequent follow-up consultations documented no cardiac events for 2 mo; this indicated the effectiveness of the medications used after PTCA and a good patient prognosis. However, for our patient, it is still difficult to ascertain the distal coronary spasm as the sole cause of AST.

## CONCLUSION

Coronary artery spasms can cause both AMI and AST. For patients who exhibit coronary spasms during PCI, diltiazem administration is advised to reduce these spasms and prevent AST.

## FOOTNOTES

**Author contributions:** Meng LP, Wang P, and Peng F performed the operation and attended the patient together; Meng LP wrote the paper.

**Supported by** the National Natural Science Foundation of China, No. 82000252.

**Informed consent statement:** The patient provided informed consent for publication of the case.

**Conflict-of-interest statement:** The authors declare that they have no conflict of interest.

**CARE Checklist (2016) statement:** The authors have read the CARE Checklist (2016), and the manuscript was prepared and revised according to the CARE Checklist (2016).

**Open-Access:** This is an open-access article that was selected by an in-house editor and fully peer-reviewed by external reviewers. It is distributed in accordance with the Creative Commons Attribution NonCommercial (CC BY-NC 4.0) license, which permits others to distribute, remix, adapt, and build upon this work non-commercially as well as license their derivative works on different terms, provided the original work is properly cited and the use is non-

commercial. See: <https://creativecommons.org/licenses/by-nc/4.0/>

Country/Territory of origin: China

ORCID number: Li-Ping Meng 0000-0002-6139-2031; Ping Wang 0000-0002-6139-2034; Fang Peng 0000-0002-3826-5632.

S-Editor: Liu JH

L-Editor: A

P-Editor: Liu JH

## REFERENCES

- 1 Verhaegen C, Kautbally S, Zapareto DC, Brusa D, Courtoy G, Aydin S, Bouzin C, Oury C, Bertrand L, Jacques PJ, Beauloye C, Horman S, Kefer J. Early thrombogenicity of coronary stents: comparison of bioresorbable polymer sirolimus-eluting and bare metal stents in an aortic rat model. *Am J Cardiovasc Dis* 2020; **10**: 72-83 [PMID: 32685265]
- 2 Lupi A, Ugo F, De Martino L, Infantino V, Iannaccone M, Iorio S, Di Leo A, Colangelo S, Zanera M, Schaffer A, Persampieri S, Garbo R, Senatore G. Real-World Experience With a Tapered Biodegradable Polymer-Coated Sirolimus-Eluting Stent in Patients With Long Coronary Artery Stenoses. *Cardiol Res* 2020; **11**: 219-225 [PMID: 32595806 DOI: 10.14740/cr1055]
- 3 Natsuaki M, Morimoto T, Watanabe H, Abe M, Kawai K, Nakao K, Ando K, Tanabe K, Ikari Y, Igarashi Hanaoka K, Morino Y, Kozuma K, Kadota K, Kimura T; STOPDAPT-1 and STOPDAPT-2 Trial Investigators. Clopidogrel Monotherapy vs. Aspirin Monotherapy Following Short-Term Dual Antiplatelet Therapy in Patients Receiving Everolimus-Eluting Coronary Stent Implantation. *Circ J* 2020; **84**: 1483-1492 [PMID: 32684537 DOI: 10.1253/circj.CJ-20-0298]
- 4 Byrne RA, Joner M, Kastrati A. Stent thrombosis and restenosis: what have we learned and where are we going? *Eur Heart J* 2015; **36**: 3320-3331 [PMID: 26417060 DOI: 10.1093/eurheartj/ehv511]
- 5 Greif M, Pohl T, Oversohl N, Reithmann C, Steinbeck G, Becker A. Acute stent thrombosis in a sirolimus eluting stent after wasp sting causing acute myocardial infarction: a case report. *Cases J* 2009; **2**: 7800 [PMID: 19918484 DOI: 10.4076/1757-1626-2-7800]
- 6 Lipinski MJ, Escarcega RO, Baker NC, Benn HA, Gaglia MA Jr, Torguson R, Waksman R. Scaffold Thrombosis After Percutaneous Coronary Intervention With ABSORB Bioresorbable Vascular Scaffold: A Systematic Review and Meta-Analysis. *JACC Cardiovasc Interv* 2016; **9**: 12-24 [PMID: 26762906 DOI: 10.1016/j.jcin.2015.09.024]
- 7 Kuchulakanti PK, Chu WW, Torguson R, Ohlmann P, Rha SW, Clavijo LC, Kim SW, Bui A, Gevorkian N, Xue Z, Smith K, Fournadjieva J, Suddath WO, Satler LF, Pichard AD, Kent KM, Waksman R. Correlates and long-term outcomes of angiographically proven stent thrombosis with sirolimus- and paclitaxel-eluting stents. *Circulation* 2006; **113**: 1108-1113 [PMID: 16490815 DOI: 10.1161/CIRCULATIONAHA.105.600155]
- 8 Iakovou I, Schmidt T, Bonizzoni E, Ge L, Sangiorgi GM, Stankovic G, Airolidi F, Chieffo A, Montorfano M, Carlino M, Michev I, Corvaja N, Briguori C, Gerckens U, Grube E, Colombo A. Incidence, predictors, and outcome of thrombosis after successful implantation of drug-eluting stents. *JAMA* 2005; **293**: 2126-2130 [PMID: 15870416 DOI: 10.1001/jama.293.17.2126]
- 9 Généreux P, Madhavan MV, Mintz GS, Maehara A, Palmerini T, Lasalle L, Xu K, McAndrew T, Kirtane A, Lansky AJ, Brener SJ, Mehran R, Stone GW. Ischemic outcomes after coronary intervention of calcified vessels in acute coronary syndromes. Pooled analysis from the HORIZONS-AMI (Harmonizing Outcomes With Revascularization and Stents in Acute Myocardial Infarction) and ACUITY (Acute Catheterization and Urgent Intervention Triage Strategy) TRIALS. *J Am Coll Cardiol* 2014; **63**: 1845-1854 [PMID: 24561145 DOI: 10.1016/j.jacc.2014.01.034]
- 10 Stone GW, Witzenbichler B, Weisz G, Rinaldi MJ, Neumann FJ, Metzger DC, Henry TD, Cox DA, Duffy PL, Mazzaferri E, Gurbel PA, Xu K, Parise H, Kirtane AJ, Brodie BR, Mehran R, Stuckey TD; ADAPT-DES Investigators. Platelet reactivity and clinical outcomes after coronary artery implantation of drug-eluting stents (ADAPT-DES): a prospective multicentre registry study. *Lancet* 2013; **382**: 614-623 [PMID: 23890998 DOI: 10.1016/S0140-6736(13)61170-8]
- 11 Voudris V, Georgiadou P, Kalogris P, Kostelidou T, Karabinis A, Gerotziakas G. Missed Heparin-Induced Thrombocytopenia (HIT) Diagnosis in a Patient with Acute Stent Thrombosis. *Am J Case Rep* 2019; **20**: 753-757 [PMID: 31133634 DOI: 10.12659/AJCR.914988]
- 12 Ben Messaoud M, Maatouk M, Boussaada MM, Mahjoub M, Mnari W, Gamra H. Case Report: Concomitant coronary stent and femoral artery thrombosis in the setting of heparin-induced thrombocytopenia. *F1000Res* 2019; **8**: 667 [PMID: 31316756 DOI: 10.12688/f1000research.19041.1]
- 13 Om SY, Yoo SY, Cho GY, Kim M, Woo Y, Lee S, Kim DH, Song JM, Kang DH, Cheong SS, Park SW, Park SJ, Song JK. Diagnostic and Prognostic Value of Ergonovine Echocardiography for Noninvasive Diagnosis of Coronary Vasospasm. *JACC Cardiovasc Imaging* 2020; **13**: 1875-1887 [PMID: 32417336 DOI: 10.1016/j.jcmg.2020.03.008]
- 14 Niccoli G, Camici PG. Myocardial infarction with non-obstructive coronary arteries: what is the prognosis? *Eur Heart J Suppl* 2020; **22**: E40-E45 [PMID: 32523437 DOI: 10.1093/eurheartj/suaa057]
- 15 Sciatti E, Vizzardi E, Cani DS, Castiello A, Bonadei I, Savoldi D, Metra M, D'Aloia A. Kounis syndrome, a disease to know: Case report and review of the literature. *Monaldi Arch Chest Dis* 2018; **88**: 898 [PMID: 29557575 DOI: 10.4081/monaldi.2018.898]
- 16 Chen JP, Hou D, Pendyala L, Goudevanos JA, Kounis NG. Drug-eluting stent thrombosis: the Kounis hypersensitivity-associated acute coronary syndrome revisited. *JACC Cardiovasc Interv* 2009; **2**: 583-593 [PMID: 19628178 DOI: 10.1016/j.jcin.2009.04.017]
- 17 Tzanis G, Bonou M, Mikos N, Biliou S, Koniari I, Kounis NG, Barbetseas J. Early stent thrombosis secondary to food

allergic reaction: Kounis syndrome following rice pudding ingestion. *World J Cardiol* 2017; **9**: 283-288 [PMID: [28400926](#)  
DOI: [10.4330/wjc.v9.i3.283](#)]



Published by **Baishideng Publishing Group Inc**  
7041 Koll Center Parkway, Suite 160, Pleasanton, CA 94566, USA

**Telephone:** +1-925-3991568

**E-mail:** [bpgoffice@wjgnet.com](mailto:bpgoffice@wjgnet.com)

**Help Desk:** <https://www.f6publishing.com/helpdesk>

<https://www.wjgnet.com>

