

# World Journal of *Clinical Cases*

*World J Clin Cases* 2022 April 16; 10(11): 3321-3638



### REVIEW

- 3321** Encouraging specific biomarkers-based therapeutic strategies for hepatocellular carcinoma  
*Yao M, Yang JL, Wang DF, Wang L, Chen Y, Yao DF*

### ORIGINAL ARTICLE

#### Clinical and Translational Research

- 3334** Autophagy-related long non-coding RNA prognostic model predicts prognosis and survival of melanoma patients  
*Qiu Y, Wang HT, Zheng XF, Huang X, Meng JZ, Huang JP, Wen ZP, Yao J*
- 3352** Identification of circ\_0000375 and circ\_0011536 as novel diagnostic biomarkers of colorectal cancer  
*Yin TF, Du SY, Zhao DY, Sun XZ, Zhou YC, Wang QQ, Zhou GYJ, Yao SK*

#### Retrospective Study

- 3369** Echocardiography in the diagnosis of Shone's complex and analysis of the causes for missed diagnosis and misdiagnosis  
*Li YD, Meng H, Pang KJ, Li MZ, Xu N, Wang H, Li SJ, Yan J*
- 3379** Predictors and prognostic impact of post-operative atrial fibrillation in patients with hip fracture surgery  
*Bae SJ, Kwon CH, Kim TY, Chang H, Kim BS, Kim SH, Kim HJ*
- 3389** Added value of systemic inflammation markers for monitoring response to neoadjuvant chemotherapy in breast cancer patients  
*Ke ZR, Chen W, Li MX, Wu S, Jin LT, Wang TJ*
- 3401** Washed microbiota transplantation reduces serum uric acid levels in patients with hyperuricaemia  
*Cai JR, Chen XW, He YJ, Wu B, Zhang M, Wu LH*

#### Clinical Trials Study

- 3414** Concurrent chemoradiotherapy using gemcitabine and nedaplatin in recurrent or locally advanced head and neck squamous cell carcinoma  
*Huo RX, Jin YY, Zhuo YX, Ji XT, Cui Y, Wu XJ, Wang YJ, Zhang L, Zhang WH, Cai YM, Zheng CC, Cui RX, Wang QY, Sun Z, Wang FW*

### META-ANALYSIS

- 3426** Effect of enhanced recovery after surgery on inflammatory bowel disease surgery: A meta-analysis  
*Peng D, Cheng YX, Tao W, Tang H, Ji GY*
- 3436** Accuracy of ultrasound elastography for predicting breast cancer response to neoadjuvant chemotherapy: A systematic review and meta-analysis  
*Chen W, Fang LX, Chen HL, Zheng JH*

- 3449** Association of chronic obstructive pulmonary disease with mild cognitive impairment and dementia risk: A systematic review and meta-analysis

Zhao LY, Zhou XL

### CASE REPORT

- 3461** Circulating tumor DNA genomic profiling reveals the complicated olaparib-resistance mechanism in prostate cancer salvage therapy: A case report

Yuan F, Liu N, Yang MZ, Zhang XT, Luo H, Zhou H

- 3472** Difference and similarity between type A interrupted aortic arch and aortic coarctation in adults: Two case reports

Ren SX, Zhang Q, Li PP, Wang XD

- 3478** Combination therapy (toripalimab and lenvatinib)-associated toxic epidermal necrolysis in a patient with metastatic liver cancer: A case report

Huang KK, Han SS, He LY, Yang LL, Liang BY, Zhen QY, Zhu ZB, Zhang CY, Li HY, Lin Y

- 3485** Unusual glomus tumor of the lower leg: A case report

Wang HY, Duan P, Chen H, Pan ZY

- 3490** Pulmonary *Cladosporium* infection coexisting with subcutaneous *Corynespora cassiicola* infection in a patient: A case report

Wang WY, Luo HB, Hu JQ, Hong HH

- 3496** Preoperational diagnosis and management of breast ductal carcinoma *in situ* arising within fibroadenoma: Two case reports

Wu J, Sun KW, Mo QP, Yang ZR, Chen Y, Zhong MC

- 3505** Reconstruction of complex chest wall defects: A case report

Huang SC, Chen CY, Qiu P, Yan ZM, Chen WZ, Liang ZZ, Luo KW, Li JW, Zhang YQ, Huang BY

- 3511** Young children with multidrug-resistant epilepsy and vagus nerve stimulation responding to perampanel: A case report

Yang H, Yu D

- 3518** Intramedullary nailing for pathological fractures of the proximal humerus caused by multiple myeloma: A case report and review of literature

Xu GQ, Wang G, Bai XD, Wang XJ

- 3527** Double tracheal stents reduce side effects of progression of malignant tracheoesophageal fistula treated with immunotherapy: A case report

Li CA, Yu WX, Wang LY, Zou H, Ban CJ, Wang HW

- 3533** Ankylosing spondylitis complicated with andersson lesion in the lower cervical spine: A case report

Peng YJ, Zhou Z, Wang QL, Liu XF, Yan J

- 3541** Severe gastric insufflation and consequent atelectasis caused by gas leakage using AIR-Q laryngeal mask airway: A case report

Zhao Y, Li P, Li DW, Zhao GF, Li XY

- 3547** Hypereosinophilic syndrome presenting as acute ischemic stroke, myocardial infarction, and arterial involvement: A case report  
*Sun RR, Chen TZ, Meng M*
- 3553** Cytochrome P450 family 17 subfamily A member 1 mutation causes severe pseudohermaphroditism: A case report  
*Gong Y, Qin F, Li WJ, Li LY, He P, Zhou XJ*
- 3561** Patellar dislocation following distal femoral replacement after extra-articular knee resection for bone sarcoma: A case report  
*Kubota Y, Tanaka K, Hirakawa M, Iwasaki T, Kawano M, Itonaga I, Tsumura H*
- 3573** Qingchang decoction retention enema may induce clinical and mucosal remission in left-sided ulcerative colitis: A case report  
*Li PH, Tang Y, Wen HZ*
- 3579** Anti-nuclear matrix protein 2+ juvenile dermatomyositis with severe skin ulcer and infection: A case report and literature review  
*Wang YT, Zhang Y, Tang T, Luo C, Liu MY, Xu L, Wang L, Tang XM*
- 3587** Ultrasound-guided local ethanol injection for fertility-preserving cervical pregnancy accompanied by fetal heartbeat: Two case reports  
*Kakinuma T, Kakinuma K, Matsuda Y, Ohwada M, Yanagida K, Kaijima H*
- 3593** Successful apatinib treatment for advanced clear cell renal carcinoma as a first-line palliative treatment: A case report  
*Wei HP, Mao J, Hu ZL*
- 3601** Del(5q) and inv(3) in myelodysplastic syndrome: A rare case report  
*Liang HP, Luo XC, Zhang YL, Liu B*
- 3609** Papillary thyroid microcarcinoma with contralateral lymphatic skip metastasis and breast cancer: A case report  
*Ding M, Kong YH, Gu JH, Xie RL, Fei J*
- 3615** Contrast-enhanced ultrasound manifestations of synchronous combined hepatocellular-cholangiocarcinoma and hepatocellular carcinoma: A case report  
*Gao L, Huang JY, Lu ZJ, Lu Q*
- 3624** Thyrotoxicosis after a massive levothyroxine ingestion: A case report  
*Du F, Liu SW, Yang H, Duan RX, Ren WX*
- 3630** Pleomorphic adenoma of the left lacrimal gland recurred and transformed into myoepithelial carcinoma after multiple operations: A case report  
*Huang WP, Li LM, Gao JB*

**ABOUT COVER**

Editorial Board Member of *World Journal of Clinical Cases*, Chi-Yuan Yeh, MD, PhD, Assistant Professor, Chief Doctor, radiation oncology, Tungs' Taichung MetroHarbor Hospital, Taichung 43503, Taiwan.  
peteryeh46@gmail.com

**AIMS AND SCOPE**

The primary aim of *World Journal of Clinical Cases* (WJCC, *World J Clin Cases*) is to provide scholars and readers from various fields of clinical medicine with a platform to publish high-quality clinical research articles and communicate their research findings online.

WJCC mainly publishes articles reporting research results and findings obtained in the field of clinical medicine and covering a wide range of topics, including case control studies, retrospective cohort studies, retrospective studies, clinical trials studies, observational studies, prospective studies, randomized controlled trials, randomized clinical trials, systematic reviews, meta-analysis, and case reports.

**INDEXING/ABSTRACTING**

The WJCC is now indexed in Science Citation Index Expanded (also known as SciSearch®), Journal Citation Reports/Science Edition, Scopus, PubMed, and PubMed Central. The 2021 Edition of Journal Citation Reports® cites the 2020 impact factor (IF) for WJCC as 1.337; IF without journal self cites: 1.301; 5-year IF: 1.742; Journal Citation Indicator: 0.33; Ranking: 119 among 169 journals in medicine, general and internal; and Quartile category: Q3. The WJCC's CiteScore for 2020 is 0.8 and Scopus CiteScore rank 2020: General Medicine is 493/793.

**RESPONSIBLE EDITORS FOR THIS ISSUE**

Production Editor: Hua-Ge Yin; Production Department Director: Xiang Li; Editorial Office Director: Jin-Lai Wang.

**NAME OF JOURNAL**

*World Journal of Clinical Cases*

**ISSN**

ISSN 2307-8960 (online)

**LAUNCH DATE**

April 16, 2013

**FREQUENCY**

Thrice Monthly

**EDITORS-IN-CHIEF**

Bao-Gan Peng, Jerzy Tadeusz Chudek, George Kontogeorgos, Maurizio Serati, Ja Hyeon Ku

**EDITORIAL BOARD MEMBERS**

<https://www.wjgnet.com/2307-8960/editorialboard.htm>

**PUBLICATION DATE**

April 16, 2022

**COPYRIGHT**

© 2022 Baishideng Publishing Group Inc

**INSTRUCTIONS TO AUTHORS**

<https://www.wjgnet.com/bpg/gerinfo/204>

**GUIDELINES FOR ETHICS DOCUMENTS**

<https://www.wjgnet.com/bpg/GerInfo/287>

**GUIDELINES FOR NON-NATIVE SPEAKERS OF ENGLISH**

<https://www.wjgnet.com/bpg/gerinfo/240>

**PUBLICATION ETHICS**

<https://www.wjgnet.com/bpg/GerInfo/288>

**PUBLICATION MISCONDUCT**

<https://www.wjgnet.com/bpg/gerinfo/208>

**ARTICLE PROCESSING CHARGE**

<https://www.wjgnet.com/bpg/gerinfo/242>

**STEPS FOR SUBMITTING MANUSCRIPTS**

<https://www.wjgnet.com/bpg/GerInfo/239>

**ONLINE SUBMISSION**

<https://www.f6publishing.com>





## Hypereosinophilic syndrome presenting as acute ischemic stroke, myocardial infarction, and arterial involvement: A case report

Ran-Ran Sun, Tuan-Zhi Chen, Min Meng

**Specialty type:** Cardiac and cardiovascular systems

**Provenance and peer review:** Unsolicited article; Externally peer reviewed.

**Peer-review model:** Single blind

**Peer-review report's scientific quality classification**

Grade A (Excellent): 0  
Grade B (Very good): B  
Grade C (Good): C  
Grade D (Fair): 0  
Grade E (Poor): 0

**P-Reviewer:** Lakusic N, Croatia; Shariati MBH, Iran

**Received:** October 30, 2021

**Peer-review started:** October 30, 2021

**First decision:** December 27, 2021

**Revised:** January 6, 2022

**Accepted:** February 27, 2022

**Article in press:** February 27, 2022

**Published online:** April 16, 2022



**Ran-Ran Sun, Tuan-Zhi Chen,** Department of Neurology, Liaocheng People's Hospital, Liaocheng 252000, Shandong Province, China

**Min Meng,** Department of Central Laboratory, Liaocheng People's Hospital, Liaocheng 252000, Shandong Province, China

**Corresponding author:** Min Meng, MS, Doctor, Department of Central Laboratory, Liaocheng People's Hospital, No. 67 Dongchang West Road, Liaocheng 252000, Shandong Province, China. [mengmin2011@126.com](mailto:mengmin2011@126.com)

### Abstract

#### BACKGROUND

Simultaneous cerebral and myocardial infarction with arterial involvement has not been reported in hypereosinophilic syndrome (HES). Here, we report a patient with HES that was also associated with acute ischemic stroke, myocardial infarction, and arterial involvement of the left common carotid artery, vertebral arteries, posterior cerebral artery, and coronary artery.

#### CASE SUMMARY

A 64-year-old male patient was admitted with headache and right lower extremity weakness. Laboratory tests indicated eosinophilia. Brain magnetic resonance imaging (MRI) showed bilateral and multiple acute infarcts in the border zones. Electrocardiography revealed that T wave was inverted and that the concentration of troponin I was significantly elevated above normal levels. Cardiac echocardiography showed an ejection fraction of 69% with mitral and tricuspid mild regurgitation. Computed tomography angiography detected multiple and localized instances of mild stenosis in the left common carotid artery bifurcation, bilateral vertebral arteries (V5 segment), and the posterior cerebral artery (P2 segment). These were observed together with multiple non-calcified and mixed plaques as well as luminal stenosis in the left circumflex artery, left anterior descending artery, and right coronary artery. The patient was treated with oral methylprednisolone and clopidogrel, after which the absolute eosinophil count fell rapidly to a normal level. After one month, a second brain MRI showed a partial reduction in the size and number of the lesions.

#### CONCLUSION

HES can masquerade as ischemic stroke, myocardial infarction, and arterial vascular involvement. The patient reported here recovered very quickly when his eosinophil blood count returned to normal. Early diagnosis and rapid reduction of

eosinophils may lead to a good prognosis.

**Key Words:** Hypereosinophilic syndrome; Ischemic stroke; Myocardial infarction; Arterial involvement; Case report

©The Author(s) 2022. Published by Baishideng Publishing Group Inc. All rights reserved.

**Core Tip:** Hypereosinophilic syndrome (HES) is characterized by unexplained eosinophilia in the blood and tissues. Neurologic and cardiac involvement in patients with HES is common and variable. Eosinophil-mediated arterial vascular involvement is a rare manifestation of HES. This rare case of HES was accompanied by acute ischemic stroke, myocardial infarction and arterial vascular involvement. Early diagnosis and rapid reduction of eosinophils may lead to a good prognosis.

**Citation:** Sun RR, Chen TZ, Meng M. Hypereosinophilic syndrome presenting as acute ischemic stroke, myocardial infarction, and arterial involvement: A case report. *World J Clin Cases* 2022; 10(11): 3547-3552

**URL:** <https://www.wjgnet.com/2307-8960/full/v10/i11/3547.htm>

**DOI:** <https://dx.doi.org/10.12998/wjcc.v10.i11.3547>

## INTRODUCTION

Hypereosinophilic syndrome (HES) is characterized by unexplained eosinophilia in the blood and tissues, and is associated with a variety of clinical manifestations[1]. It has long been thought that HES is associated with multiple organ dysfunctions, ranging from minor skin involvement to serious and even life-threatening cardiovascular, hematologic, and neurologic manifestations[2]. Neurologic involvement in patients with HES is common and highly variable, and includes the occurrence of peripheral neuropathy, encephalopathy, and stroke[3]. Cardiac involvement may lead to the development of thrombi, resulting a transient ischemic attack or embolic stroke with associated sequelae[4]. However, eosinophil-mediated arterial vascular involvement is a rare manifestation of HES. Most HES patients present with organ involvement showed normal cranial computed tomography angiogram (CTA) or magnetic resonance angiography[3,5,6]. Here, we report a rare case of HES accompanied by the simultaneous occurrence of acute ischemic stroke and myocardial infarction (MI), as well as arterial vascular involvement of the left common carotid artery, vertebral arteries, posterior cerebral artery, and coronary artery.

## CASE PRESENTATION

### Chief complaints

A 64-year-old male patient without any cerebrovascular risk factors was admitted to our hospital with a headache and right lower extremity weakness that lasted for two days.

### History of present illness

The patient had a history of toothache, smoking, and alcohol consumption.

### History of past illness

Until hospitalization, the patient was not burdened with any significant cardiovascular comorbidity.

### Personal and family history

The patient had no pertinent family history of heart disease or other illnesses.

### Physical examination

The results of a physical examination showed right lower extremity weakness (4-/5 strength) and dystaxia.

### Laboratory examinations

Routine laboratory tests revealed significant leucocytosis ( $12.36 \times 10^9/L$ ) and an elevated eosinophil count ( $6.89 \times 10^9/L$ , 55.7% of leukocytes) in the peripheral blood. The results of a blood clotting test, urine and stool routine examination, virus screening, liver and renal function examination, and

immunological function examination were normal. The antinuclear antibodies, anti-neutrophil cytoplasmic antibodies, and tumor markers were also negative. Molecular genetic analysis of fusion gene mutation (Fip1-like 1-platelet-derived growth factor receptor alpha) was also negative. Bone marrow aspirate results were compatible with HES, showing no sign of myelodysplasia, hemoparasite, or atypical cells. Cerebrospinal fluid analysis revealed that the levels of white blood cells, proteins, and glucose were normal. Acid-fast staining and India ink staining of cerebrospinal fluid were negative. Electrocardiography (ECG) revealed that the T wave was inverted and the concentration of troponin I (0.644 ng/mL) was significantly elevated. The clinical history and examination results of this patient showed no sign of parasitic infection, neoplasm, vasculitis, or allergy.

### Imaging examinations

A CT scan of the chest was normal. Abdominal ultrasound revealed multiple hepatic cysts. Brain magnetic resonance imaging (MRI) detected bilateral and multiple acute infarcts in the border zones, which were located in the cortical and subcortical areas (Figure 1A-C). CTA of the head and neck revealed multiple and localized mild instances of stenosis in the left common carotid artery bifurcation, bilateral vertebral arteries (V5 segment), and posterior cerebral artery (P2 segment) (Figure 1D-F). Cardiac echocardiography showed an ejection fraction of 69% with mitral and tricuspid mild regurgitation. Coronary CTA showed multiple non-calcified, mixed plaques and luminal stenoses in the left circumflex artery, left anterior descending artery, and right coronary artery (Figure 1G-I). The results of cardiac examination supported the diagnosis of non-ST-elevated MI.

## FINAL DIAGNOSIS

The patient was diagnosed with HES, accompanied with multiple cerebral infarctions and acute MI.

## TREATMENT

The patient was treated with oral methylprednisolone (1 mg/kg/d) and clopidogrel (75 mg/d) for 7 d, and responded well to the treatment. The absolute eosinophil count ( $0.18 \times 10^9/L$ , 1.8% of leukocytes) fell to a normal level within 7 d.

## OUTCOME AND FOLLOW-UP

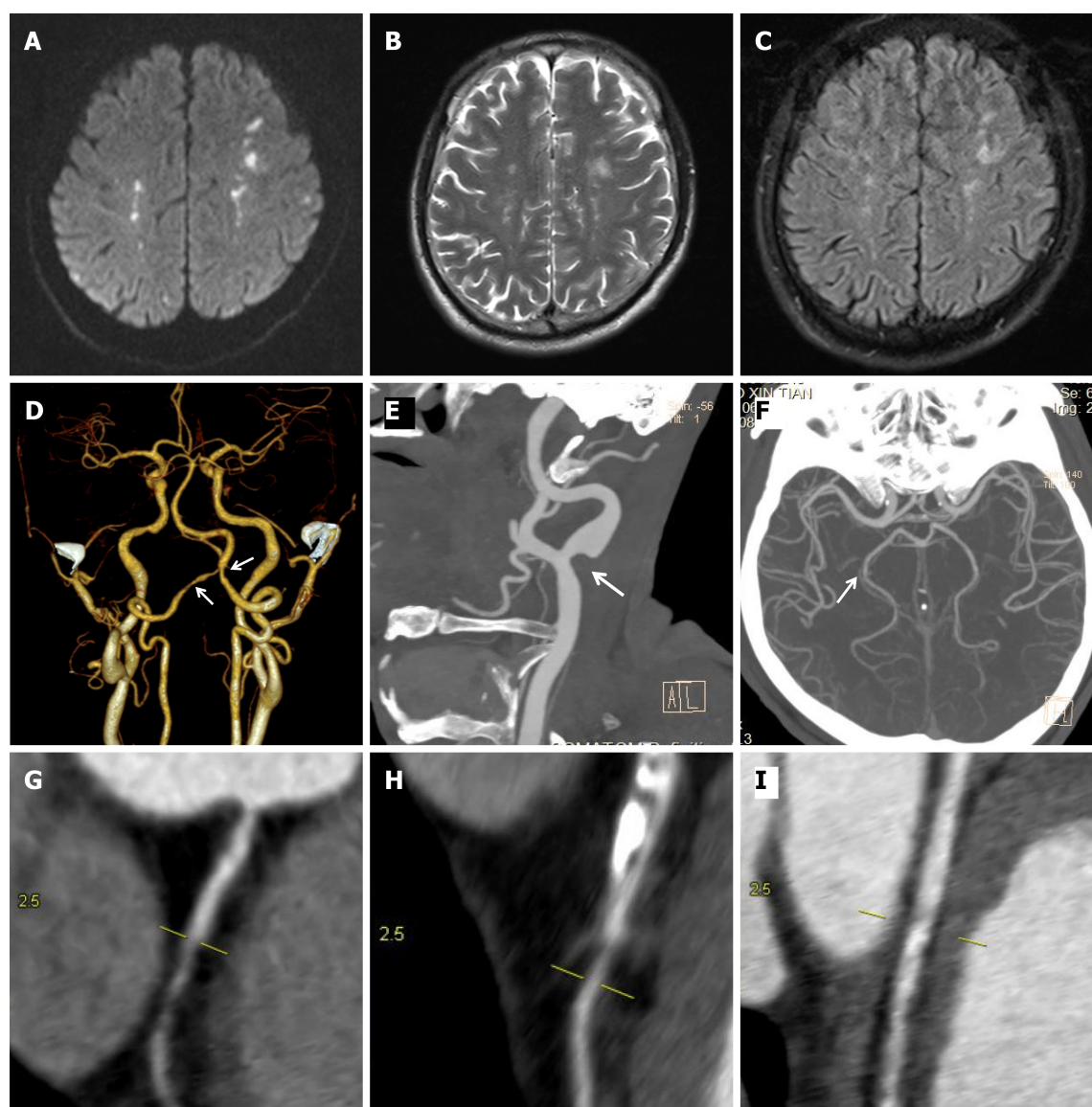
The patient was discharged after two weeks and continued taking low-dose prednisone. The ECG at discharge showed a normal T wave. The troponin I was 0.455 ng/mL during hospitalization and 0.012 ng/mL at discharge. After one month, a second brain MRI showed a partial reduction in the size and number of the lesions (Figure 2A-C). After one year, another brain MRI showed cerebromalacia in multiple areas of the lesions (Figure 2D-F). The follow-up of this patient was satisfactory in that he remained asymptomatic while on low-dose prednisone.

## DISCUSSION

HES comprises a group of disorders characterized by the abnormal accumulation of eosinophils in the peripheral tissues or blood, independent of known secondary causes of eosinophilia (*e.g.*, parasitic infection)[4]. In 2010, new diagnostic criteria of HES were proposed: An absolute eosinophil count of more than  $1500/mm^3$  on at least two occasions or marked blood eosinophilia and prominent tissue eosinophilia associated with symptoms; exclusion of secondary causes of eosinophilia, such as neoplasms, hypoadrenalism, chemical- or drug-induced eosinophilia, allergic diseases, and viral or parasitic infection. Advances in diagnostic and therapeutic approaches have prompted a re-evaluation of the definition and classification of HES[7]. More than half of the patients with HES in one study (27 of 52) had neurologic dysfunction[8]. Stroke represents the most devastating neurological consequence of HES, which is characterized by a distinct pattern of both internal and external border zone infarcts[2].

In the patient reported here, eosinophilic involvement resulted in multiple cerebral infarctions and acute MI. Acute cerebral infarctions in the border zones were the first presenting symptom in this case. Meanwhile, the patient suffered from ischemic ECG changes, troponin I elevation, and mild valve regurgitation in echocardiography, which supported the diagnosis of MI. As a rare complication of HES, MI occurs as the result of endomyocardial fibrosis[9]. CTA of the head and neck, as well as the coronary artery showed multiple arterial stenoses in this case. Single arterial stenosis or occlusion has been only occasionally reported in patients with HES. Chang *et al*[10] reported a 43-year-old male patient with



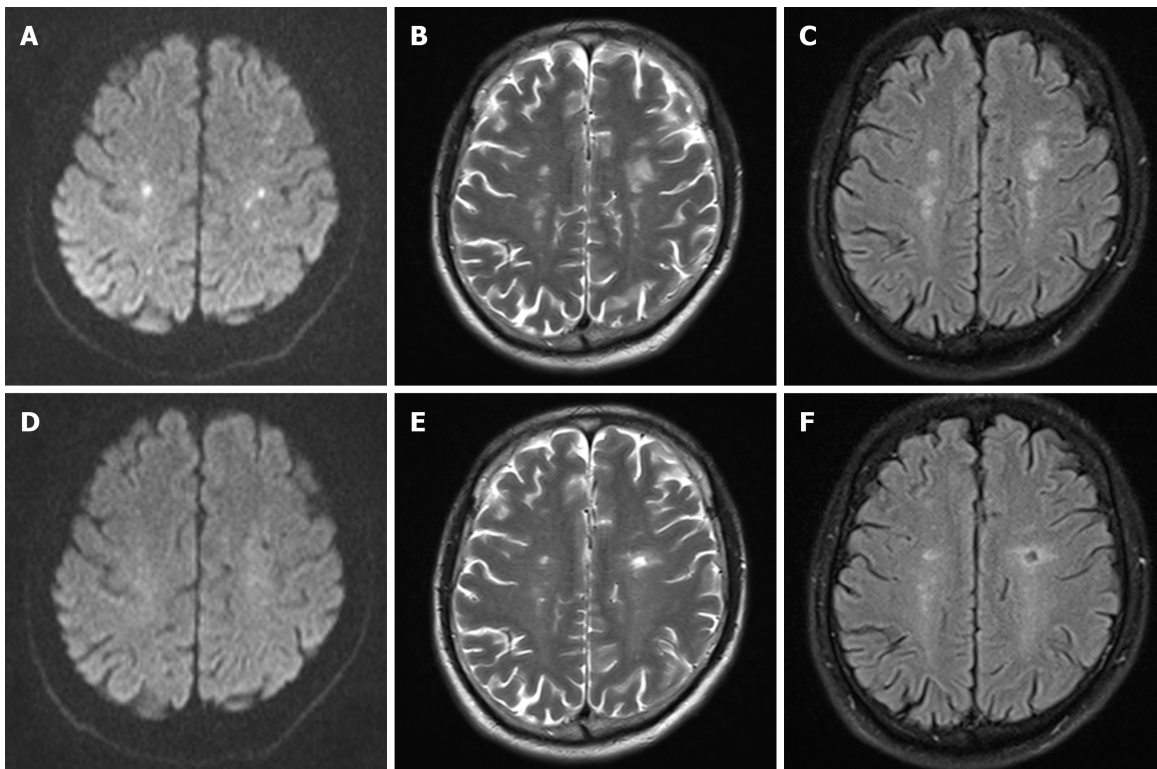


DOI: 10.12998/wjcc.v10.i11.3547 Copyright © The Author(s) 2022.

**Figure 1** Brain magnetic resonance imaging and computed tomography angiography at admission. A: Diffusion-weighted magnetic resonance imaging (MRI); B: T2-weighted MRI; C: Fluid-attenuated inversion recovery revealed multiple acute infarcts in the bilateral border zones; D-I: Computed tomography angiogram (CTA) of the head and neck revealed mild stenosis in the (D) bilateral vertebral arteries, (E) left common carotid artery bifurcation, and (F) the posterior cerebral artery. Coronary CTA showed mild stenosis in the (G) right coronary artery, (H) left anterior descending artery, and (I) the left circumflex artery.

HES presenting with ischemic stroke and segmental stenosis of the right posterior cerebral artery resulting from direct eosinophilic toxicity. Li *et al*[11] described a middle-aged woman with idiopathic HES presenting with bilateral middle cerebral artery occlusion and progressive multiple cerebral infarction. Our patient suffered from multiple arterial vascular damage involving the left common carotid artery, vertebral arteries, posterior cerebral artery, and coronary artery. Eosinophilic toxicity to the vascular wall, *via* either arterial or venous vessels, was considered the pathological consequence of eosinophil accumulation[10]. Eosinophils have direct cytotoxic activity through the local release of toxic substances, including pro-inflammatory cytokines, reactive oxygen species, enzymes, arachidonic acid-derived factors, and cationic proteins[10,12].

The mechanism of eosinophilia-associated stroke remains unknown. The major etiology is cardiac embolism. More than half of cases with HES show a sign of cardiac involvement in echocardiography, which is a common source of thromboembolism with thrombi formation in damaged endocardium[13, 14]. With the development of thromboembolism, patients with HES may experience a transient ischemic attack or embolic stroke as the initial presenting symptom[15]. Eosinophilia may damage the myocardium and endocardium, and therefore contribute to cardiac embolism by releasing eosinophilic granule contents, such as eosinophilic cationic protein and major basic protein[14]. Generally, eosinophilic myocarditis can be divided into three stages, which may occur simultaneously: (1) Acute necrosis/myocarditis stage-eosinophilic infiltration of the myocardium associated with myocardial necrosis due to the release of toxic cationic proteins from degranulated eosinophils; (2) thrombosis



DOI: 10.12998/wjcc.v10.i11.3547 Copyright © The Author(s) 2022.

**Figure 2 Brain magnetic resonance imaging during follow-up.** A-C: Brain magnetic resonance imaging (MRI) at one month of follow-up showed a reduced size and number of lesions compared with the results at admission; D-F: Brain MRI at one year of follow-up showed cerebromalacia in multiple areas of the lesions.

stage-thrombosis at both ventricles where the ventricular outflow tract and subvalvular regions are associated with a significant risk of embolic complications; and (3) fibrotic stage-fibrosis replaces the thrombus formed on denuded myocardium and often requires surgical intervention[9,16]. The clinical records and laboratory tests of this case indicated that eosinophilia-induced cardioembolism and vascular wall damage may have been the main cause of cerebral infarction. Unfortunately, cardiac MRI and endocardial biopsy were not performed. Despite advances in noninvasive imaging methods (*e.g.*, echocardiography and cardiac MRI), endomyocardial biopsy remains the gold standard for the diagnosis of HES, especially in patients at the early stages of myocardial infiltration.

Corticosteroids are the most widely used medication to reduce eosinophil levels in patients with HES. If the patient presents with significant end-organ damage, corticosteroid treatment should be initiated immediately. An antiplatelet agent was used to reduce the risk of embolization in this case, however, the use of antiplatelet agents or anticoagulants alone is not recommended. The rapid reduction of eosinophil count is essential for preventing thromboembolic events and end-organ damage in patients at risk.

## CONCLUSION

In conclusion, neurologic and cardiac complications occurred almost simultaneously in this case. Thus, the early diagnosis and treatment of HES are crucial for the prevention of widespread cardioembolism and subsequent irreversible, life-threatening cerebrovascular complications. Long-term follow-up and ongoing surveillance are important for monitoring the progression of the disease. Clinicians should be cognizant of HES patients presenting with cerebral infarction in the border zone. Early diagnosis and prompt treatment with corticosteroids are required.

## FOOTNOTES

**Author contributions:** Sun RR and Chen TZ evaluated and managed the patient; Sun RR and Meng M prepared the figures; Meng M wrote and edited the manuscript; all authors read and approved the final manuscript.

**Informed consent statement:** Informed written consent was obtained from the patients for the publication of this

report and any accompanying images.

**Conflict-of-interest statement:** The authors declare that they have no conflict of interest.

**CARE Checklist (2016) statement:** The authors have read the CARE Checklist (2016), and the manuscript was prepared and revised according to the CARE Checklist (2016).

**Open-Access:** This article is an open-access article that was selected by an in-house editor and fully peer-reviewed by external reviewers. It is distributed in accordance with the Creative Commons Attribution NonCommercial (CC BY-NC 4.0) license, which permits others to distribute, remix, adapt, build upon this work non-commercially, and license their derivative works on different terms, provided the original work is properly cited and the use is non-commercial. See: <https://creativecommons.org/licenses/by-nc/4.0/>

**Country/Territory of origin:** China

**ORCID number:** Ran-Ran Sun 0000-0002-1678-4917; Tuan-Zhi Chen 0000-0001-9866-9885; Min Meng 0000-0002-3055-7948.

**S-Editor:** Chen YL

**L-Editor:** A

**P-Editor:** Chen YL

## REFERENCES

- 1 Kahn JE, Groh M, Lefèvre G. (A Critical Appraisal of) Classification of Hypereosinophilic Disorders. *Front Med (Lausanne)* 2017; **4**: 216 [PMID: 29259972 DOI: 10.3389/fmed.2017.00216]
- 2 Rosenberg J, Aamodt W, Takvorian S, Mullen M. Clinical Reasoning: A young woman with symmetric weakness and behavioral disturbance. *Neurology* 2018; **90**: e1442-e1447 [PMID: 29661906 DOI: 10.1212/WNL.0000000000005335]
- 3 Chen H, Raza HK, Jing J, Shen D, Xu P, Zhou S, Zu J, Yang X, Zhang W, Zhang S, Hua F, Cui G. Hypereosinophilic syndrome with central nervous system involvement: Two case reports and literature review. *Brain Inj* 2017; **31**: 1695-1700 [PMID: 28945486 DOI: 10.1080/02699052.2017.1357835]
- 4 Curtis C, Ogbogu P. Hypereosinophilic Syndrome. *Clin Rev Allergy Immunol* 2016; **50**: 240-251 [PMID: 26475367 DOI: 10.1007/s12016-015-8506-7]
- 5 Psychogios K, Evmorfiadis I, Dragomanovits S, Stavridis A, Takis K, Kaklamanis L, Stathis P. ANCA-Negative Churg-Strauss Syndrome Presenting as Acute Multiple Cerebral Infarcts: A Case Report. *J Stroke Cerebrovasc Dis* 2017; **26**: e47-e49 [PMID: 28065613 DOI: 10.1016/j.jstrokecerebrovasdis.2016.12.009]
- 6 Rohmer J, Groh M, Samson M, London J, Jachiet M, Rouzaud D, Paule R, Suarez F, Lefèvre G, Cohen F, Lambotte O, Perlat A, Bielefeld P, Guillemin L, Kahn JE, Terrier B; French Vasculitis Study Group (FVSG). Distal ischemia as the initial presentation of hypereosinophilic syndrome-related arterial involvement: A case study and literature review. *Autoimmun Rev* 2019; **18**: 828-830 [PMID: 31176876 DOI: 10.1016/j.autrev.2019.06.004]
- 7 Simon HU, Rothenberg ME, Bochner BS, Weller PF, Wardlaw AJ, Wechsler ME, Rosenwasser LJ, Roufosse F, Gleich GJ, Klion AD. Refining the definition of hypereosinophilic syndrome. *J Allergy Clin Immunol* 2010; **126**: 45-49 [PMID: 20639008 DOI: 10.1016/j.jaci.2010.03.042]
- 8 Moore PM, Harley JB, Fauci AS. Neurologic dysfunction in the idiopathic hypereosinophilic syndrome. *Ann Intern Med* 1985; **102**: 109-114 [PMID: 2981493 DOI: 10.7326/0003-4819-102-1-109]
- 9 Ogbogu PU, Rosing DR, Hone MK 3rd. Cardiovascular manifestations of hypereosinophilic syndromes. *Immunol Allergy Clin North Am* 2007; **27**: 457-475 [PMID: 17868859 DOI: 10.1016/j.iac.2007.07.001]
- 10 Chang WL, Lin HJ, Cheng HH. Hypereosinophilic syndrome with recurrent strokes: a case report. *Acta Neurol Taiwan* 2008; **17**: 184-188 [PMID: 18975525]
- 11 Li QF, Zhang Q, Huang YF, Zhang ZX. Acute progressive stroke with middle cerebral artery occlusion caused by idiopathic hypereosinophilic syndrome: a case report. *BMC Neurol* 2020; **20**: 361 [PMID: 33003998 DOI: 10.1186/s12883-020-01941-8]
- 12 Roufosse F, Cogan E, Goldman M. The hypereosinophilic syndrome revisited. *Annu Rev Med* 2003; **54**: 169-184 [PMID: 12525672 DOI: 10.1146/annurev.med.54.101601.152431]
- 13 Ommen SR, Seward JB, Tajik AJ. Clinical and echocardiographic features of hypereosinophilic syndromes. *Am J Cardiol* 2000; **86**: 110-113 [PMID: 10867107 DOI: 10.1016/s0002-9149(00)00841-9]
- 14 Rezaizadeh H, Sanchez-Ross M, Kaluski E, Klapholz M, Haider B, Gerula C. Acute eosinophilic myocarditis: diagnosis and treatment. *Acute Card Care* 2010; **12**: 31-36 [PMID: 20201659 DOI: 10.3109/17482940903578998]
- 15 Spry CJ, Davies J, Tai PC, Olsen EG, Oakley CM, Goodwin JF. Clinical features of fifteen patients with the hypereosinophilic syndrome. *Q J Med* 1983; **52**: 1-22 [PMID: 6878618]
- 16 Cheung CC, Constantine M, Ahmadi A, Shiao C, Chen LYC. Eosinophilic Myocarditis. *Am J Med Sci* 2017; **354**: 486-492 [PMID: 29173361 DOI: 10.1016/j.amjms.2017.04.002]



Published by **Baishideng Publishing Group Inc**  
7041 Koll Center Parkway, Suite 160, Pleasanton, CA 94566, USA

**Telephone:** +1-925-3991568

**E-mail:** [bpgoffice@wjgnet.com](mailto:bpgoffice@wjgnet.com)

**Help Desk:** <https://www.f6publishing.com/helpdesk>

<https://www.wjgnet.com>

