

World Journal of *Gastrointestinal Surgery*

World J Gastrointest Surg 2022 March 27; 14(3): 211-270



ORIGINAL ARTICLE

Case Control Study

- 211 Fast-track protocols in laparoscopic liver surgery: Applicability and correlation with difficulty scoring systems

Ciria R, Padial A, Ayllón MD, García-Gaitan C, Briceño J

- 221 Does cranial-medial mixed dominant approach have a unique advantage for laparoscopic right hemicolectomy with complete mesocolic excision?

Lin L, Yuan SB, Guo H

Retrospective Study

- 236 New common bile duct morphological subtypes: Risk predictors of common bile duct stone recurrence

Ji X, Yang Z, Ma SR, Jia W, Zhao Q, Xu L, Kan Y, Cao Y, Wang Y, Fan BJ

META-ANALYSIS

- 247 Peroral endoscopic longer vs shorter esophageal myotomy for achalasia treatment: A systematic review and meta-analysis

Weng CY, He CH, Zhuang MY, Xu JL, Lyu B

CASE REPORT

- 260 Successful treatment with laparoscopic surgery and sequential multikinase inhibitor therapy for hepatocellular carcinoma: A case report

Endo Y, Shimazu M, Sakuragawa T, Uchi Y, Edanami M, Sunamura K, Ozawa S, Chiba N, Kawachi S

LETTER TO THE EDITOR

- 268 Is it sufficient to evaluate only preoperative systemic inflammatory biomarkers to predict postoperative complications after pancreaticoduodenectomy?

Demirli Atici S, Kamer E

ABOUT COVER

Editorial Board Member of *World Journal of Gastrointestinal Surgery*, Vishal Gupta, FACS, MBBS, MCh, MS, Additional Professor, Surgeon, Department of Surgical Gastroenterology, All India Institute of Medical Sciences, Bhopal 462020, India. vggis@yahoo.co.in

AIMS AND SCOPE

The primary aim of *World Journal of Gastrointestinal Surgery* (WJGS, *World J Gastrointest Surg*) is to provide scholars and readers from various fields of gastrointestinal surgery with a platform to publish high-quality basic and clinical research articles and communicate their research findings online.

WJGS mainly publishes articles reporting research results and findings obtained in the field of gastrointestinal surgery and covering a wide range of topics including biliary tract surgical procedures, biliopancreatic diversion, colectomy, esophagectomy, esophagostomy, pancreas transplantation, and pancreatectomy, etc.

INDEXING/ABSTRACTING

The WJGS is now abstracted and indexed in Science Citation Index Expanded (SCIE, also known as SciSearch®), Current Contents/Clinical Medicine, Journal Citation Reports/Science Edition, PubMed, and PubMed Central. The 2021 edition of Journal Citation Reports® cites the 2020 impact factor (IF) for WJGS as 2.582; IF without journal self cites: 2.564; 5-year IF: 3.378; Journal Citation Indicator: 0.53; Ranking: 97 among 212 journals in surgery; Quartile category: Q2; Ranking: 73 among 92 journals in gastroenterology and hepatology; and Quartile category: Q4.

RESPONSIBLE EDITORS FOR THIS ISSUE

Production Editor: Rui-Rui Wu, Production Department Director: Xiang Li, Editorial Office Director: Ya-Juan Ma.

NAME OF JOURNAL

World Journal of Gastrointestinal Surgery

ISSN

ISSN 1948-9366 (online)

LAUNCH DATE

November 30, 2009

FREQUENCY

Monthly

EDITORS-IN-CHIEF

Peter Schemmer

EDITORIAL BOARD MEMBERS

<https://www.wjgnet.com/1948-9366/editorialboard.htm>

PUBLICATION DATE

March 27, 2022

COPYRIGHT

© 2022 Baishideng Publishing Group Inc

INSTRUCTIONS TO AUTHORS

<https://www.wjgnet.com/bpg/gerinfo/204>

GUIDELINES FOR ETHICS DOCUMENTS

<https://www.wjgnet.com/bpg/gerinfo/287>

GUIDELINES FOR NON-NATIVE SPEAKERS OF ENGLISH

<https://www.wjgnet.com/bpg/gerinfo/240>

PUBLICATION ETHICS

<https://www.wjgnet.com/bpg/gerinfo/288>

PUBLICATION MISCONDUCT

<https://www.wjgnet.com/bpg/gerinfo/208>

ARTICLE PROCESSING CHARGE

<https://www.wjgnet.com/bpg/gerinfo/242>

STEPS FOR SUBMITTING MANUSCRIPTS

<https://www.wjgnet.com/bpg/gerinfo/239>

ONLINE SUBMISSION

<https://www.f6publishing.com>



Successful treatment with laparoscopic surgery and sequential multikinase inhibitor therapy for hepatocellular carcinoma: A case report

Yutaka Endo, Motohide Shimazu, Tadayuki Sakuragawa, Yusuke Uchi, Motonori Edanami, Ken Sunamura, Soji Ozawa, Naokazu Chiba, Shigeyuki Kawachi

Specialty type: Surgery

Provenance and peer review:

Unsolicited article; Externally peer reviewed.

Peer-review model: Single blind

Peer-review report's scientific quality classification

Grade A (Excellent): 0

Grade B (Very good): B, B

Grade C (Good): C

Grade D (Fair): 0

Grade E (Poor): 0

P-Reviewer: Luo XZ, China; Mukthinuthalapati VVPK, United States; Nenu I, Romania

Received: November 30, 2021

Peer-review started: November 30, 2021

First decision: December 26, 2021

Revised: January 8, 2022

Accepted: March 16, 2022

Article in press: March 16, 2022

Published online: March 27, 2022



Yutaka Endo, Motohide Shimazu, Tadayuki Sakuragawa, Yusuke Uchi, Motonori Edanami, Ken Sunamura, Soji Ozawa, Department of Surgery, Tama Kyuryo Hospital, Tokyo 1940297, Japan

Naokazu Chiba, Shigeyuki Kawachi, Department of Digestive and Transplantation Surgery, Tokyo Medical University Hachioji Medical Center, Tokyo 1930998, Japan

Corresponding author: Motohide Shimazu, MD, PhD, Chief Doctor, Department of Surgery, Tama Kyuryo Hospital, 1491 Shimo-oyamadacho, Machida, Tokyo 1940297, Japan. shimazu@tokyo-med.ac.jp

Abstract

BACKGROUND

Hepatocellular carcinoma (HCC) with massive portal vein tumor thrombosis (PVTT) and distant metastasis is considered unresectable. However, due to recent developments in systemic chemotherapy, successful cases of conversion therapy for unresectable diseases have been reported. Herein, we report a successful multidisciplinary approach for treatment of multi-visceral recurrence with sequential multikinase inhibitor and laparoscopic surgery.

CASE SUMMARY

A 63-year-old woman with chronic hepatitis B virus infection was diagnosed with HCC. Subsequently, she underwent two rounds of laparoscopic partial hepatectomy, laparoscopic left adrenalectomy, and transcatheter arterial chemoembolization plus sorafenib for recurrence. Four years after initial hepatectomy, she presented with a 43-mm mass in the spleen and tumor thrombus involving the main portal vein trunk with ascites. Her liver function was Child-Pugh B (8), and protein induced by vitamin K absence or antagonist II (PIVKA II) levels were elevated up to 46.291 mAU/mL. Since initial treatment with regorafenib for three months was unsuccessful, the patient was administered lenvatinib. Ten months post-treatment, there was no contrast enhancement of PVTT or splenic metastasis. Chemotherapy was discontinued due to severe diarrhea. Afterward, splenic metastasis became viable, and PIVKA II increased. Therefore, hand-assisted laparoscopic splenectomy was performed. She experienced no clinical recurrence 14 mo after resection.

CONCLUSION

Conversion surgery after successful multikinase inhibitor treatment might be considered an effective treatment option for advanced HCC.

Key Words: Hepatocellular carcinoma; Lenvatinib; Portal vein; Venous thrombosis; Splenic neoplasms; Case report

©The Author(s) 2022. Published by Baishideng Publishing Group Inc. All rights reserved.

Core Tip: A 63-year-old woman had chronic hepatitis B virus infection and previous treatment history of hepatocellular carcinoma. She developed a 43-mm splenic mass and tumor thrombus involving the right portal branch and an umbilical portion extending down to the main trunk with severe ascites. She was initially treated with regorafenib and then lenvatinib. Ten months post-treatment, there was no contrast enhancement of portal vein tumor thrombosis or splenic metastases. However, after lenvatinib discontinuation due to severe diarrhea, splenic metastases showed partial contrast enhancement. Subsequently, hand-assisted laparoscopic splenectomy was performed with no remarkable postoperative complications. She experienced no recurrence for 14 mo.

Citation: Endo Y, Shimazu M, Sakuragawa T, Uchi Y, Edanami M, Sunamura K, Ozawa S, Chiba N, Kawachi S. Successful treatment with laparoscopic surgery and sequential multikinase inhibitor therapy for hepatocellular carcinoma: A case report. *World J Gastrointest Surg* 2022; 14(3): 260-267

URL: <https://www.wjgnet.com/1948-9366/full/v14/i3/260.htm>

DOI: <https://dx.doi.org/10.4240/wjgs.v14.i3.260>

INTRODUCTION

Treatment strategy recommendations for hepatocellular carcinoma (HCC) have been introduced in various guidelines. These guidelines include the Clinical Practice Guidelines for Hepatocellular Carcinoma in Japan[1], Barcelona Clinic Liver Cancer (BCLC) Guidelines[2], and American Association for the Study of the Liver Diseases Guidelines[3]. According to these guidelines, indications for liver resection are limited by tumor progression. Moreover, many cases with distant metastasis or local major vessel invasion are not eligible for resection. Recently, development of effective molecular-targeted agents, including sorafenib[4], regorafenib[5], ramucirumab[6], and lenvatinib (LEN)[7] has prolonged patient survival and occasionally enabled multidisciplinary treatments combined with chemotherapy and liver resection for HCC. Among these agents, LEN, which is an oral multikinase inhibitor targeting kinases, is known to achieve a higher rate of objective response rate (ORR)[7]. These kinases include vascular endothelial growth factor receptor 1-3, fibroblast growth factor receptor (FGFR) 1-4, platelet-derived growth factor receptor- α (PDGFR), RET, and KIT. Therefore, there have been a limited number of reports on conversion surgery after LEN treatment[8-17]. However, to the best of our knowledge, there are only a few reports on long-term remission with portal vein tumor thrombus[8,16].

Herein, we report a successful multidisciplinary approach for treatment of unresectable HCC recurrence with sequential multikinase inhibitor therapy and laparoscopic surgery.

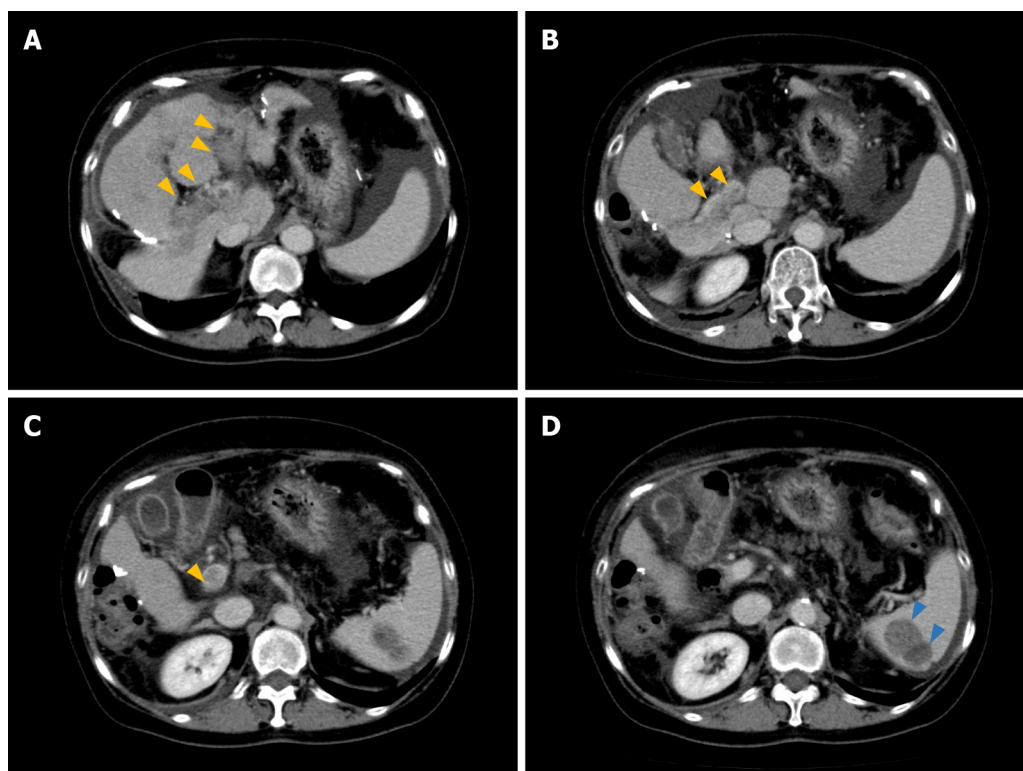
CASE PRESENTATION

Chief complaints

A 63-year-old woman with chronic hepatitis B virus infection was referred to our clinic due to incidental detection of a hepatic mass. Alpha-fetoprotein and protein induced by vitamin K absence or antagonist II (PIVKA II) levels were 25.24 ng/mL and 3021 mAU/mL, respectively. The patient was diagnosed with HCC in December 2014. Thereafter, she underwent hand-assisted laparoscopic partial hepatectomy for a solitary tumor with 5 cm in diameter in the right posterior sector. Pathological findings showed that the lesion was 40 mm in size, moderately differentiated, solitary HCC without any macroscopic vascular invasion (T1bN0M0 and stage IB, based on the 8th Union for International Cancer Control staging of HCC). Liver fibrosis was evident during initial surgery (METVIR F2-3).

History of present illness

Six months after initial surgery, multiple recurrent lesions in the liver were observed. Consequently, the



DOI: 10.4240/wjgs.v14.i3.260 Copyright The Author(s) 2022.

Figure 1 Radiological findings of hepatocellular carcinoma with portal vein tumor thrombosis and splenic metastasis. A: Hypervascular lesion in the left and right anterior portal branches (yellow arrows) suggesting portal vein tumor thrombosis. Ascites are located around the spleen. Dynamic computed tomography (CT), portal phase; B and C: Hypervascular lesions in the main portal branch (yellow arrows). Dynamic CT, portal phase; D: Heterogenic, largely a hypodense lesion with high contrast enhancement in the lower pole of the spleen (blue arrows). Dynamic CT, portal phase.

patient was treated with lipiodol-transcatheter arterial chemoembolization (TACE). After this successful TACE, sorafenib (400 mg per day) was administered. Six months later, she underwent laparoscopic left adrenalectomy for adrenal metastasis (pathology revealed metastatic, moderately differentiated HCC). Eight months after the adrenalectomy, the patient underwent laparoscopic partial hepatectomy for a solitary recurrence in the lateral sector (pathology revealed moderately differentiated HCC, background liver condition; METAVIR F3). Eight months after the second hepatectomy, the patient was treated with sorafenib (400 mg per day, followed by 600 mg per day) for increased PIVKA II levels. Despite 9-mo treatment with sorafenib, she was found to have a 43-mm mass in the spleen and portal vein tumor thrombosis (PVTT) that involved both the right and left portal branches down to the main trunk (Vp4) on computed tomography (CT) (Figure 1).

History of past illness

Hepatitis B infection.

Personal and family history

Her personal and family history was unremarkable.

Physical examination

Her vital signs were normal. There were no remarkable findings other than abdominal distention.

Laboratory examinations

PIVKA II levels increased tremendously up to 46.291 mAU/mL. The BCLC staging system classified the patient into stage C. Aspartate aminotransferase, alanine aminotransferase, and platelet count were 49 IU/L, 40 IU/L, and $14.7 \times 10^4/\mu\text{L}$, respectively. The FIB-4 index was calculated as 3.71, suggesting that she was likely to be cirrhotic. Her cirrhosis was classified into Child-Pugh B (8) and modified albumin-bilirubin grade 1.

Imaging examinations

CT findings revealed moderate ascites, which indicated portal hypertension due to tumor thrombosis. This also demonstrated irregularity of the external contour of the left lobe of the liver, suggesting cirrhosis.

MULTIDISCIPLINARY EXPERT CONSULTATION

Seishi Nakatsuka, MD, PhD, Assistant Professor, Department of Radiology, Keio University

On contrast enhanced CT scan, a hypodense mass with a size of 43 mm in the spleen and PVTT that involved the right anterior, posterior, and left portal branches down to main trunk (Vp4) were seen. Moreover, moderate ascites was observed. No obvious liver masses were recognized.

FINAL DIAGNOSIS

HCC with PVTT and splenic metastases, which led to massive ascites, possibly due to portal hypertension, was observed.

TREATMENT

Initially, she was treated with regorafenib (400 mg/d) and tolvaptan for ascites.

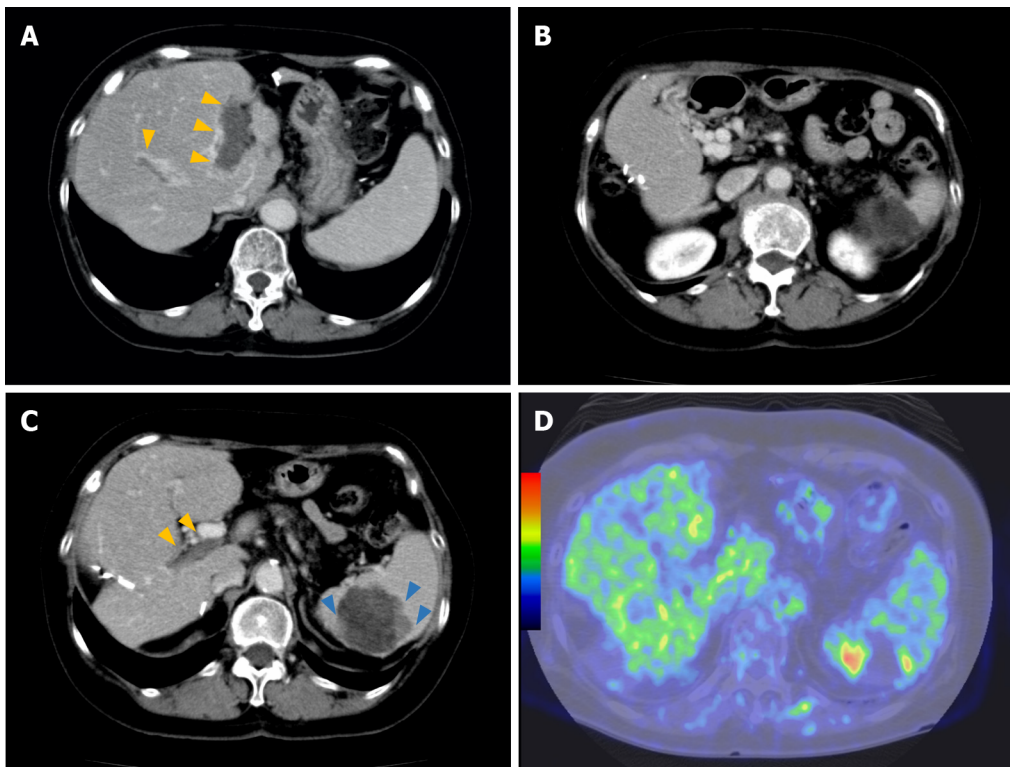
OUTCOME AND FOLLOW-UP

Three months after initiation of regorafenib treatment, the tumor thrombus and spleen metastasis continued to increase in size with elevated PIVKA II levels (129.815 mAU/mL). However, improvement of liver function by resolution of portal hypertension due to cavernous transformation occurred. Her ascites and liver function improved [Child-Pugh A (5)]. Therefore, LEN was orally administered at a dose of 8 mg/d. No severe side effects were observed, except for grade 2 hypertension and anorexia. Ten months after initiation of LEN therapy, the patient had a clinically complete response, according to radiological findings (Figure 2A and B). Additionally, PIVKA II level markedly decreased from 1.637 to 4 mAU/mL and was sustained within the normal range with continued therapy. After 18 mo, LEN treatment was ceased because the patient developed severe diarrhea. At that time, a follow-up CT examination revealed that the tumor burden had significantly decreased. However, after 7 mo, PIVKA II levels increased again, with contrast-enhancement of the splenic lesion on CT and positron emission tomography (PET) findings (Figure 2C and D). Splenectomy was required to control the disease. Therefore, a hand-assisted laparoscopic splenectomy was performed for solitary spleen metastasis. The patient's postoperative course was uneventful. Macroscopic and microscopic histopathological examinations showed necrosis of HCC with slightly viable tumor cells. Surgical margins were negative (Figure 3). There was no clinical evidence of recurrence 14 mo after splenectomy and 81 mo after initial hepatectomy. Levels of PIVKA II remained within the normal range.

DISCUSSION

Based on our experience, LEN therapy could successfully lead to a hypovascular status of PVTT 10 mo after its initiation. In addition, conversion surgery was performed effectively for progression of solitary splenic metastasis after LEN discontinuation. To the best of our knowledge, there have been few reports regarding successful conversion surgery after multikinase inhibitor treatment for HCC with massive tumor thrombus[8,16].

We experienced good control of PVTT with LEN administration. In our case, PVTT became hypovascular 10 mo after LEN administration, along with a necrosis of the splenic lesion. After LEN discontinuation, PVTT continued to be hypovascular, whereas the splenic lesion progressed. There have been two case reports showing disappearance of PVTT[8,16]. Takeda *et al*[8] reported a female patient with advanced HCC and PVTT who was treated with LEN monotherapy and experienced a long-term antitumor effect. Rapidly, LEN caused hypovascularity in the main hypervascular target lesion, and PVTT became undetectable 11 mo after LEN initiation. Takahashi *et al*[16] also reported a 59-year-old male patient with a recurrent liver mass diffusely located at the lateral segment with a massive Vp4 PVTT extending from the umbilical portion to the main and contralateral third-order portal branches. Three months after starting LEN, PVTT critically regressed and retreated to the contralateral first-order portal branch. After LEN cessation for 7 d, radical left lobectomy and PVTT thrombectomy were performed. The majority of PVTT cases showed necrosis. They argued that LEN may have a relatively strong antitumor effect not only on main tumor, but also on PVTT, which is attributed to an antiangiogenic effect. According to two previous reports, LEN exerts both immediate antiangiogenic and long-term antitumor effects on PVTT. According to previous basic studies[18-20], FGFR plays an important role in this antitumor effect *via* inhibition of FGF19-FGFR autocrine loop and antiangiogenic effects



DOI: 10.4240/wjgs.v14.i3.260 Copyright The Author(s) 2022.

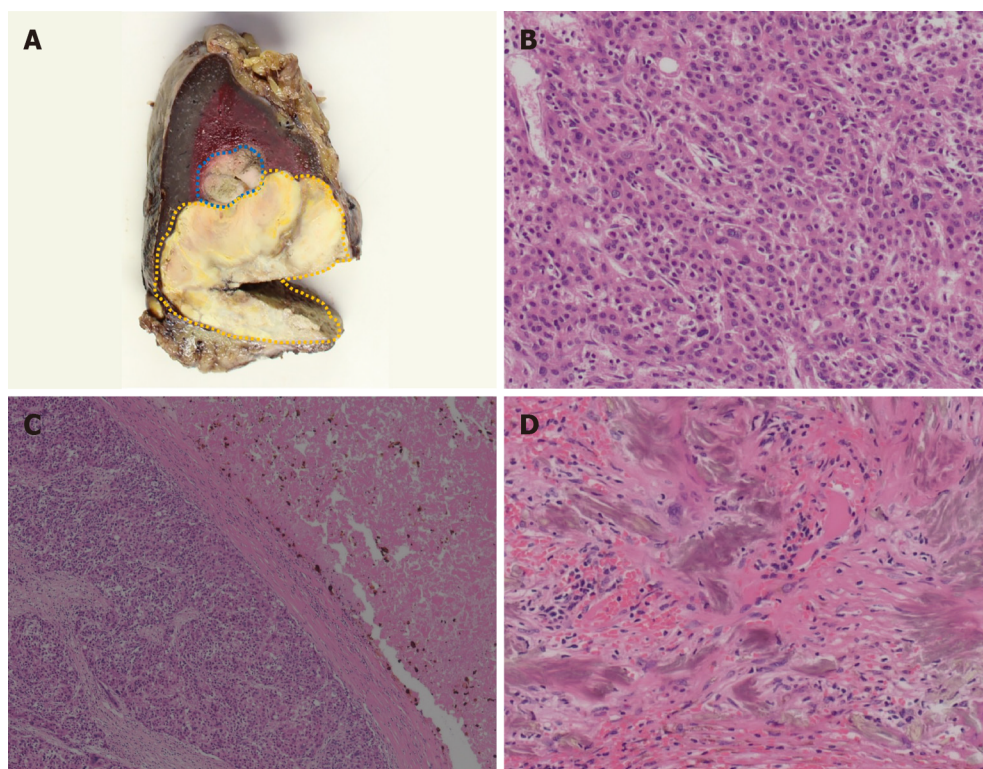
Figure 2 Radiological findings after the lenvatinib treatment. A: Portal vein tumor thrombus (PVTT) becomes hypovascular (yellow arrows) 10 mo after the administration of lenvatinib. Dynamic computed tomography (CT), portal phase; B: The main portal vein is hypovascular, suggesting the organization of PVTT 10 mo after the administration of lenvatinib. Numerous collateral veins are seen around the portal vein. Dynamic CT, portal phase; C: PVTT remains hypovascular (yellow arrows), whereas hypervascular lesions increase the peripheral lesions of the spleen metastases (blue arrows) 8 mo after the cessation of lenvatinib. Dynamic CT, portal phase; D: Fluorodeoxyglucose (FDG) uptakes in the lower pole of the spleen (blue arrows) corresponding to hypervascular lesions on CT. FDG-positron emission tomography.

through inhibition of FGFR/PDGFR. This explains why PVTT and hepatic lesions became hypovascular in 10 mo and continued to be in a hypovascular status approximately 2 years after LEN cessation in our patient.

Importantly, the safety of LEN administration for main PVTT (Vp4) has not been established. Kuzuya *et al*[21] compared the outcomes of advanced HCC with Vp3/4 between sorafenib and LEN as the first-line systemic therapy. The ORR was significantly higher in the LEN group than in the sorafenib group (53.8% *vs* 14.3%, $P = 0.0193$), and the median overall survival (OS) and time to progression were significantly longer in the LEN group than in the sorafenib group. None of these patients discontinued LEN treatment due to treatment-related adverse events in their series. Chuma *et al*[22] recently have reported the safety and efficacy of LEN treatment in highly advanced HCC. In this report, 20 patients with Vp4 HCC were included, and 12 patients (60%) experienced grade ≥ 3 adverse effects. The ORRs were 26.7% in patients with Child-Pugh A and 0% in those with Child-Pugh B. These findings suggest that LEN administration with close monitoring of patients' live conditions would be acceptable.

It was notable that regorafenib, which has also anti-angiogenic properties did not have any impact on cavernous transformation of the portal vein and portal vein thrombosis. Although they have not been fully elucidated, the various reactions of regorafenib and LEN may originate from the different mechanisms of action between the two agents. The genes downregulated by regorafenib might be different from those manipulated by LEN. That would lead to their different effects. There have been few cases regarding regorafenib and conversion therapy for HCC with PVTT, despite REFLECT trial included patients with macrovascular invasion[5].

Since metastatic splenic lesions became viable after LEN cessation, splenectomy was necessary to control the disease. There have been a few cases of spleen metastases resection[23-26]. The spleen is an important organ in the immune system, and metastases to this organ usually involve multiple lesions, and solitary splenic metastasis seems rare. According to previous reports[23-25], splenectomy for spleen metastases led to favorable outcomes, despite some patients having dismal outcomes (OS, 2-84 mo). Kim *et al*[26] have reported lesions detected by fluorodeoxyglucose-PET, which was similar to those in our patient. It has been assumed that splenic metastasis could be transformed into poor differentiation through multiple treatments.



DOI: 10.4240/wjgs.v14.i3.260 Copyright The Author(s) 2022.

Figure 3 Pathological findings of metastatic splenic lesions. A: Macroscopic finding shows that splenic lesions surrounded by fibrous capsule, and a border part (blue area) is distinguished from other parts (yellow area) with its color, suggesting viable lesions; B: Microscopic finding of viable tumor lesion shows moderately to poorly differentiated hepatocellular carcinoma. Hematoxylin-eosin stain, high-power field ($\times 200$); C: Microscopic findings of mixed component of viable cells and necrotic tissue demonstrated that coagulative and partially liquefactive necrosis (right-side) is surrounded by fibrous capsule, and viable cells (left-side). Hematoxylin-eosin stain, low-power field ($\times 50$); D: Gamma-Gandy bodies shown in the splenic lesions, suggesting previous history of portal hypertension due to portal vein tumor thrombosis. Hematoxylin-eosin stain, high-power field ($\times 200$).

CONCLUSION

We report the rare case of a patient with advanced HCC in whom LEN monotherapy showed long-term antitumor activity. Clinicians should be aware of radiological changes suggestive of intratumoral vascularity during treatment with the novel antiangiogenic agent LEN in patients with advanced HCC. Further studies are needed to elucidate the background of patients' favorable outcomes.

ACKNOWLEDGEMENTS

We would like to thank Dr. Hiromi Serizawa from the Department of Pathology, Hachioji Medical Center Tokyo Medical University for their insightful comment on pathological findings; Dr. Seishi Nakatsuka from the Department of Radiology, Keio University for his precise comment on radiological findings.

FOOTNOTES

Author contributions: Endo Y participated in the patient care, conceptualization, data curation, visualization and wrote the original article; Shimazu M participated in the patient care, reviewed the article, and supervised this report; Ozawa S, Kawachi S, Chiba N, Sakuragawa T, Uchi Y, Sunamura K reviewed the article; Edanami M participated in the patient care.

Informed consent statement: Written informed consent was obtained from this patient.

Conflict-of-interest statement: The authors have no conflict of interest to disclose.

CARE Checklist (2016) statement: The authors have read the CARE Checklist (2016), and the manuscript was prepared and revised according to the CARE Checklist (2016).

Open-Access: This article is an open-access article that was selected by an in-house editor and fully peer-reviewed by external reviewers. It is distributed in accordance with the Creative Commons Attribution NonCommercial (CC BY-NC 4.0) license, which permits others to distribute, remix, adapt, build upon this work non-commercially, and license their derivative works on different terms, provided the original work is properly cited and the use is non-commercial. See: <https://creativecommons.org/licenses/by-nc/4.0/>

Country/Territory of origin: Japan

ORCID number: Yutaka Endo 0000-0001-7187-0124; Motohide Shimazu 0000-0001-5369-2256; Tadayuki Sakuragawa 0000-0002-4410-4923; Yusuke Uchi 0000-0002-0373-2659; Motonori Edanami 0000-0002-7169-1860; Ken Sunamura 0000-0001-7014-4550; Soji Ozawa 0000-0001-6130-1753; Naokazu Chiba 0000-0002-1846-5987; Shigeyuki Kawachi 0000-0001-7870-9149.

S-Editor: Yan JP

L-Editor: A

P-Editor: Yan JP

REFERENCES

- Kokudo N**, Takemura N, Hasegawa K, Takayama T, Kubo S, Shimada M, Nagano H, Hatano E, Izumi N, Kaneko S, Kudo M, Iijima H, Genda T, Tateishi R, Torimura T, Igaki H, Kobayashi S, Sakurai H, Murakami T, Watadani T, Matsuyama Y. Clinical practice guidelines for hepatocellular carcinoma: The Japan Society of Hepatology 2017 (4th JSH-HCC guidelines) 2019 update. *Hepatol Res* 2019; **49**: 1109-1113 [PMID: [31336394](#) DOI: [10.1111/hepr.13411](#)]
- Llovet JM**, Brú C, Bruix J. Prognosis of hepatocellular carcinoma: the BCLC staging classification. *Semin Liver Dis* 1999; **19**: 329-338 [PMID: [10518312](#) DOI: [10.1055/s-2007-1007122](#)]
- Heimbach JK**, Kulik LM, Finn RS, Sirlin CB, Abecassis MM, Roberts LR, Zhu AX, Murad MH, Marrero JA. AASLD guidelines for the treatment of hepatocellular carcinoma. *Hepatology* 2018; **67**: 358-380 [PMID: [28130846](#) DOI: [10.1002/hep.29086](#)]
- Llovet JM**, Ricci S, Mazzaferro V, Hilgard P, Gane E, Blanc JF, de Oliveira AC, Santoro A, Raoul JL, Forner A, Schwartz M, Porta C, Zeuzem S, Bolondi L, Gretter TF, Galle PR, Seitz JF, Borbath I, Häussinger D, Giannaris T, Shan M, Moscovici M, Voliotis D, Bruix J; SHARP Investigators Study Group. Sorafenib in advanced hepatocellular carcinoma. *N Engl J Med* 2008; **359**: 378-390 [PMID: [18650514](#) DOI: [10.1056/NEJMoa0708857](#)]
- Bruix J**, Qin S, Merle P, Granito A, Huang YH, Bodoky G, Pracht M, Yokosuka O, Rosmorduc O, Breder V, Gerolami R, Masi G, Ross PJ, Song T, Bronowicki JP, Ollivier-Hourmand I, Kudo M, Cheng AL, Llovet JM, Finn RS, LeBerre MA, Baumhauer A, Meinhardt G, Han G; RESORCE Investigators. Regorafenib for patients with hepatocellular carcinoma who progressed on sorafenib treatment (RESORCE): a randomised, double-blind, placebo-controlled, phase 3 trial. *Lancet* 2017; **389**: 56-66 [PMID: [27932229](#) DOI: [10.1016/S0140-6736\(16\)32453-9](#)]
- Zhu AX**, Kang YK, Yen CJ, Finn RS, Galle PR, Llovet JM, Assenat E, Brandi G, Pracht M, Lim HY, Rau KM, Motomura K, Ohno I, Merle P, Daniele B, Shin DB, Gerken G, Borg C, Hiriart JB, Okusaka T, Morimoto M, Hsu Y, Abada PB, Kudo M; REACH-2 study investigators. Ramucirumab after sorafenib in patients with advanced hepatocellular carcinoma and increased α -fetoprotein concentrations (REACH-2): a randomised, double-blind, placebo-controlled, phase 3 trial. *Lancet Oncol* 2019; **20**: 282-296 [PMID: [30665869](#) DOI: [10.1016/S1470-2045\(18\)30937-9](#)]
- Kudo M**, Finn RS, Qin S, Han KH, Ikeda K, Piscaglia F, Baron A, Park JW, Han G, Jasse J, Blanc JF, Vogel A, Komov D, Evans TRJ, Lopez C, Dutcus C, Guo M, Saito K, Kraljevic S, Tamai T, Ren M, Cheng AL. Lenvatinib versus sorafenib in first-line treatment of patients with unresectable hepatocellular carcinoma: a randomised phase 3 non-inferiority trial. *Lancet* 2018; **391**: 1163-1173 [PMID: [29433850](#) DOI: [10.1016/S0140-6736\(18\)30207-1](#)]
- Takeda H**, Nishijima N, Nasu A, Komekado H, Kita R, Kimura T, Kudo M, Osaki Y. Long-term antitumor effect of lenvatinib on unresectable hepatocellular carcinoma with portal vein invasion. *Hepatol Res* 2019; **49**: 594-599 [PMID: [30499247](#) DOI: [10.1111/hepr.13294](#)]
- Sato N**, Beppu T, Kinoshita K, Yuki H, Suyama K, Chiyonaga S, Motohara T, Komohara Y, Hara A, Akahoshi S. Conversion Hepatectomy for Huge Hepatocellular Carcinoma With Arteriportal Shunt After Chemoembolization and Lenvatinib Therapy. *Anticancer Res* 2019; **39**: 5695-5701 [PMID: [31570469](#) DOI: [10.21873/anticancer.13768](#)]
- Liu Z**, Fu Z, Li G, Lin D. Downstaging of Recurrent Advanced Hepatocellular Carcinoma After Lenvatinib Treatment: Opportunities or Pitfalls? *Onco Targets Ther* 2020; **13**: 10267-10273 [PMID: [33116607](#) DOI: [10.2147/OTT.S261521](#)]
- Matsuki R**, Kawai K, Suzuki Y, Kogure M, Nakazato T, Naruge D, Okano N, Seki S, Ohmori Y, Kawamura N, Kamma H, Hisamatsu T, Shibahara J, Mori T, Furuse J, Sakamoto Y. Pathological Complete Response in Conversion Hepatectomy Induced by Lenvatinib for Advanced Hepatocellular Carcinoma. *Liver Cancer* 2020; **9**: 358-360 [PMID: [32647636](#) DOI: [10.1159/000506202](#)]
- Ohya Y**, Hayashida S, Tsuji A, Kuramoto K, Shibata H, Setoyama H, Hayashi H, Kuriwaki K, Sasaki M, Iizaka M, Nakahara O, Inomata Y. Conversion hepatectomy for advanced hepatocellular carcinoma after right portal vein transection and lenvatinib therapy. *Surg Case Rep* 2020; **6**: 318 [PMID: [33301055](#) DOI: [10.1186/s40792-020-01078-3](#)]
- Tomonari T**, Sato Y, Tanaka H, Tanaka T, Taniguchi T, Sogabe M, Okamoto K, Miyamoto H, Murguruma N, Saito Y, Imura S, Bando Y, Shimada M, Takayama T. Conversion therapy for unresectable hepatocellular carcinoma after lenvatinib: Three case reports. *Medicine (Baltimore)* 2020; **99**: e22782 [PMID: [33080748](#) DOI: [10.1097/MD.00000000000022782](#)]
- Yokoo H**, Takahashi H, Hagiwara M, Iwata H, Imai K, Saito Y, Matsuno N, Furukawa H. Successful hepatic resection for

- recurrent hepatocellular carcinoma after lenvatinib treatment: A case report. *World J Hepatol* 2020; **12**: 1349-1357 [PMID: 33442460 DOI: 10.4254/wjh.v12.i12.1349]
- 15 **Chen S**, Wu Z, Shi F, Mai Q, Wang L, Wang F, Zhuang W, Chen X, Chen H, Xu B, Lai J, Guo W. Lenvatinib plus TACE with or without pembrolizumab for the treatment of initially unresectable hepatocellular carcinoma harbouring PD-L1 expression: a retrospective study. *J Cancer Res Clin Oncol* 2021 [PMID: 34453221 DOI: 10.1007/s00432-021-03767-4]
 - 16 **Takahashi K**, Kim J, Takahashi A, Hashimoto S, Doi M, Furuya K, Hashimoto R, Owada Y, Ogawa K, Ohara Y, Akashi Y, Hisakura K, Enomoto T, Shimomura O, Noguchi M, Oda T. Conversion hepatectomy for hepatocellular carcinoma with main portal vein tumour thrombus after lenvatinib treatment: A case report. *World J Hepatol* 2021; **13**: 384-392 [PMID: 33815680 DOI: 10.4254/wjh.v13.i3.384]
 - 17 **Yang X**, Xu H, Zuo B, Yang X, Bian J, Long J, Wang D, Zhang J, Ning C, Wang Y, Xun Z, Lu X, Mao Y, Sang X, Zhao H. Downstaging and resection of hepatocellular carcinoma in patients with extrahepatic metastases after stereotactic therapy. *Hepatobiliary Surg Nutr* 2021; **10**: 434-442 [PMID: 34430522 DOI: 10.21037/hbsn-21-188]
 - 18 **Okamoto K**, Ikemori-Kawada M, Jestel A, von König K, Funahashi Y, Matsushima T, Tsuruoka A, Inoue A, Matsui J. Distinct binding mode of multikinase inhibitor lenvatinib revealed by biochemical characterization. *ACS Med Chem Lett* 2015; **6**: 89-94 [PMID: 25589937 DOI: 10.1021/ml500394m]
 - 19 **Matsuki M**, Hoshi T, Yamamoto Y, Ikemori-Kawada M, Minoshima Y, Funahashi Y, Matsui J. Lenvatinib inhibits angiogenesis and tumor fibroblast growth factor signaling pathways in human hepatocellular carcinoma models. *Cancer Med* 2018; **7**: 2641-2653 [PMID: 29733511 DOI: 10.1002/cam4.1517]
 - 20 **Kanzaki H**, Chiba T, Ao J, Koroki K, Kanayama K, Maruta S, Maeda T, Kusakabe Y, Kobayashi K, Kanogawa N, Kiyono S, Nakamura M, Kondo T, Saito T, Nakagawa R, Ogasawara S, Suzuki E, Ooka Y, Muroyama R, Nakamoto S, Yasui S, Tawada A, Arai M, Kanda T, Maruyama H, Mimura N, Kato J, Zen Y, Ohtsuka M, Iwama A, Kato N. The impact of FGF19/FGFR4 signaling inhibition in antitumor activity of multi-kinase inhibitors in hepatocellular carcinoma. *Sci Rep* 2021; **11**: 5303 [PMID: 33674622 DOI: 10.1038/s41598-021-84117-9]
 - 21 **Kuzuya T**, Ishigami M, Ito T, Ishizu Y, Honda T, Ishikawa T, Fujishiro M. Sorafenib vs. Lenvatinib as First-line Therapy for Advanced Hepatocellular Carcinoma With Portal Vein Tumor Thrombosis. *Anticancer Res* 2020; **40**: 2283-2290 [PMID: 32234927 DOI: 10.21873/anticancer.14193]
 - 22 **Chuma M**, Uojima H, Hiraoka A, Kobayashi S, Toyoda H, Tada T, Hidaka H, Iwabuchi S, Numata K, Itobayashi E, Itokawa N, Kariyama K, Ohama H, Hattori N, Hirose S, Shibata H, Tani J, Imai M, Tajiri K, Moriya S, Wada N, Iwasaki S, Fukushima T, Ueno M, Yasuda S, Atsukawa M, Nouse K, Fukunishi S, Watanabe T, Ishikawa T, Nakamura S, Morimoto M, Kagawa T, Sakamoto M, Kumada T, Maeda S. Analysis of efficacy of lenvatinib treatment in highly advanced hepatocellular carcinoma with tumor thrombus in the main trunk of the portal vein or tumor with more than 50% liver occupation: A multicenter analysis. *Hepatol Res* 2021; **51**: 201-215 [PMID: 33270323 DOI: 10.1111/hepr.13592]
 - 23 **Hanada K**, Saito A, Nozawa H, Haruyama K, Hayashi N, Yamada M, Katagiri S, Katsuragawa H, Otsubo T, Takasaki K. Histopathologically-diagnosed splenic metastasis in a hepatocellular carcinoma case with adrenal metastasis. *Intern Med* 2004; **43**: 484-489 [PMID: 15283184 DOI: 10.2169/internalmedicine.43.484]
 - 24 **Iwaki K**, Ohta M, Ishio T, Kai S, Iwashita Y, Shibata K, Himeno K, Seike M, Fujioka T, Kitano S. Metastasis of hepatocellular carcinoma to spleen and small intestine. *J Hepatobiliary Pancreat Surg* 2008; **15**: 213-219 [PMID: 18392718 DOI: 10.1007/s00534-007-1230-9]
 - 25 **Sanefuji K**, Fukuzawa K, Okamoto M, Kai S, Takaki H, Hirotohi Y, Motohiro A, Wakasugi K. Long-term surviving patient with inferior vena cava tumor thrombus and extrahepatic metastasis after spontaneous ruptured hepatocellular carcinoma. *Clin J Gastroenterol* 2011; **4**: 123-128 [PMID: 26190719 DOI: 10.1007/s12328-011-0205-1]
 - 26 **Kim DH**, Jeong SY, Lee SW, Lee J, Ahn BC. Solitary splenic metastasis from hepatocellular carcinoma detected on (18)F-FDG PET/CT. *Clin Nucl Med* 2015; **40**: e325-e327 [PMID: 25546205 DOI: 10.1097/RLU.0000000000000659]



Published by **Baishideng Publishing Group Inc**
7041 Koll Center Parkway, Suite 160, Pleasanton, CA 94566, USA

Telephone: +1-925-3991568

E-mail: bpgoffice@wjgnet.com

Help Desk: <https://www.f6publishing.com/helpdesk>

<https://www.wjgnet.com>

