

# World Journal of *Clinical Cases*

*World J Clin Cases* 2022 July 16; 10(20): 6759-7186



### OPINION REVIEW

- 6759 Semaglutide might be a key for breaking the vicious cycle of metabolically associated fatty liver disease spectrum?

*Cigrovski Berkovic M, Rezig T, Bilic-Curcic I, Mrzljak A*

### MINIREVIEWS

- 6769 Drainage of pancreatic fluid collections in acute pancreatitis: A comprehensive overview

*Bansal A, Gupta P, Singh AK, Shah J, Samanta J, Mandavdhare HS, Sharma V, Sinha SK, Dutta U, Sandhu MS, Kochhar R*

- 6784 Frontiers of COVID-19-related myocarditis as assessed by cardiovascular magnetic resonance

*Luo Y, Liu BT, Yuan WF, Zhao CX*

### ORIGINAL ARTICLE

#### Case Control Study

- 6794 Urinary and sexual function changes in benign prostatic hyperplasia patients before and after transurethral columnar balloon dilatation of the prostate

*Zhang DP, Pan ZB, Zhang HT*

- 6803 Effects of the information-knowledge-attitude-practice nursing model combined with predictability intervention on patients with cerebrovascular disease

*Huo HL, Gui YY, Xu CM, Zhang Y, Li Q*

#### Retrospective Cohort Study

- 6811 Effects of Kampo medicine hangebyakujutsutemmato on persistent postural-perceptual dizziness: A retrospective pilot study

*Miwa T, Kanemaru SI*

#### Retrospective Study

- 6825 Longitudinal changes in personalized platelet count metrics are good indicators of initial 3-year outcome in colorectal cancer

*Herold Z, Herold M, Lohinszky J, Szasz AM, Dank M, Somogyi A*

- 6845 Efficacy of Kegel exercises in preventing incontinence after partial division of internal anal sphincter during anal fistula surgery

*Garg P, Yagnik VD, Kaur B, Menon GR, Dawka S*

#### Observational Study

- 6855 Influence of the water jet system vs cavitron ultrasonic surgical aspirator for liver resection on the remnant liver

*Hanaki T, Tsuda A, Sunaguchi T, Goto K, Morimoto M, Murakami Y, Kihara K, Matsunaga T, Yamamoto M, Tokuyasu N, Sakamoto T, Hasegawa T, Fujiwara Y*

- 6865** Critical values of monitoring indexes for perioperative major adverse cardiac events in elderly patients with biliary diseases

*Zhang ZM, Xie XY, Zhao Y, Zhang C, Liu Z, Liu LM, Zhu MW, Wan BJ, Deng H, Tian K, Guo ZT, Zhao XZ*

- 6876** Comparative study of surface electromyography of masticatory muscles in patients with different types of bruxism

*Lan KW, Jiang LL, Yan Y*

### Randomized Controlled Trial

- 6890** Dural puncture epidural technique provides better anesthesia quality in repeat cesarean delivery than epidural technique: Randomized controlled study

*Wang SY, He Y, Zhu HJ, Han B*

### SYSTEMATIC REVIEWS

- 6900** Network pharmacology-based strategy for predicting therapy targets of Sanqi and Huangjing in diabetes mellitus

*Cui XY, Wu X, Lu D, Wang D*

### META-ANALYSIS

- 6915** Endoscopic submucosal dissection for early signet ring cell gastric cancer: A systematic review and meta-analysis

*Weng CY, Sun SP, Cai C, Xu JL, Lv B*

- 6927** Prognostic value of computed tomography derived skeletal muscle mass index in lung cancer: A meta-analysis

*Pan XL, Li HJ, Li Z, Li ZL*

### CASE REPORT

- 6936** Autosomal dominant osteopetrosis type II resulting from a *de novo* mutation in the *CLCN7* gene: A case report

*Song XL, Peng LY, Wang DW, Wang H*

- 6944** Clinical expression and mitochondrial deoxyribonucleic acid study in twins with 14484 Leber's hereditary optic neuropathy: A case report

*Chuenkongkaew WL, Chinkulkitnivat B, Lertrit P, Chirapapaisan N, Kaewsutthi S, Suktitipat B, Mitrpant C*

- 6954** Management of the enteroatmospheric fistula: A case report

*Cho J, Sung K, Lee D*

- 6960** Lower lip recurrent keratoacanthoma: A case report

*Liu XG, Liu XG, Wang CJ, Wang HX, Wang XX*

- 6966** Optic disc coloboma associated with macular retinoschisis: A case report

*Zhang W, Peng XY*

- 6974** A 7-year-old boy with recurrent cyanosis and tachypnea: A case report  
*Li S, Chen LN, Zhong L*
- 6981** Schwannomatosis patient who was followed up for fifteen years: A case report  
*Li K, Liu SJ, Wang HB, Yin CY, Huang YS, Guo WT*
- 6991** Intentional replantation combined root resection therapy for the treatment of type III radicular groove with two roots: A case report  
*Tan D, Li ST, Feng H, Wang ZC, Wen C, Nie MH*
- 6999** Clinical features and genetic variations of severe neonatal hyperbilirubinemia: Five case reports  
*Lin F, Xu JX, Wu YH, Ma YB, Yang LY*
- 7006** Percutaneous transhepatic access for catheter ablation of a patient with heterotaxy syndrome complicated with atrial fibrillation: A case report  
*Wang HX, Li N, An J, Han XB*
- 7013** Secondary positioning of rotationally asymmetric refractive multifocal intraocular lens in a patient with glaucoma: A case report  
*Fan C, Zhou Y, Jiang J*
- 7020** Laparoscopic repair of diaphragmatic hernia associating with radiofrequency ablation for hepatocellular carcinoma: A case report  
*Tsunoda J, Nishi T, Ito T, Inaguma G, Matsuzaki T, Seki H, Yasui N, Sakata M, Shimada A, Matsumoto H*
- 7029** Hypopituitary syndrome with pituitary crisis in a patient with traumatic shock: A case report  
*Zhang XC, Sun Y*
- 7037** Solitary plasmacytoma of the left rib misdiagnosed as angina pectoris: A case report  
*Yao J, He X, Wang CY, Hao L, Tan LL, Shen CJ, Hou MX*
- 7045** Secondary coronary artery ostial lesions: Three case reports  
*Liu XP, Wang HJ, Gao JL, Ma GL, Xu XY, Ji LN, He RX, Qi BYE, Wang LC, Li CQ, Zhang YJ, Feng YB*
- 7054** Bladder perforation injury after percutaneous peritoneal dialysis catheterization: A case report  
*Shi CX, Li ZX, Sun HT, Sun WQ, Ji Y, Jia SJ*
- 7060** Myotonic dystrophy type 1 presenting with dyspnea: A case report  
*Jia YX, Dong CL, Xue JW, Duan XQ, Xu MY, Su XM, Li P*
- 7068** Novel mutation in the *SALL1* gene in a four-generation Chinese family with uraemia: A case report  
*Fang JX, Zhang JS, Wang MM, Liu L*
- 7076** Malignant transformation of primary mature teratoma of colon: A case report  
*Liu J*

- 7082** Treatment of pyogenic liver abscess by surgical incision and drainage combined with platelet-rich plasma: A case report  
*Wang JH, Gao ZH, Qian HL, Li JS, Ji HM, Da MX*
- 7090** Left bundle branch pacing in a ventricular pacing dependent patient with heart failure: A case report  
*Song BX, Wang XX, An Y, Zhang YY*
- 7097** Solitary fibrous tumor of the liver: A case report and review of the literature  
*Xie GY, Zhu HB, Jin Y, Li BZ, Yu YQ, Li JT*
- 7105** MutL homolog 1 germline mutation c.(453+1\_454-1)\_(545+1\_546-1)del identified in lynch syndrome: A case report and review of literature  
*Zhang XW, Jia ZH, Zhao LP, Wu YS, Cui MH, Jia Y, Xu TM*
- 7116** Malignant histiocytosis associated with mediastinal germ cell tumor: A case report  
*Yang PY, Ma XL, Zhao W, Fu LB, Zhang R, Zeng Q, Qin H, Yu T, Su Y*
- 7124** Immunoglobulin G4 associated autoimmune cholangitis and pancreatitis following the administration of nivolumab: A case report  
*Agrawal R, Guzman G, Karimi S, Giulianotti PC, Lora AJM, Jain S, Khan M, Boulay BR, Chen Y*
- 7130** Portal vein thrombosis in a noncirrhotic patient after hemihepatectomy: A case report and review of literature  
*Zhang SB, Hu ZX, Xing ZQ, Li A, Zhou XB, Liu JH*
- 7138** Microvascular decompression for a patient with oculomotor palsy caused by posterior cerebral artery compression: A case report and literature review  
*Zhang J, Wei ZJ, Wang H, Yu YB, Sun HT*
- 7147** Topical halometasone cream combined with fire needle pre-treatment for treatment of primary cutaneous amyloidosis: Two case reports  
*Su YQ, Liu ZY, Wei G, Zhang CM*
- 7153** Simultaneous robot-assisted approach in a super-elderly patient with urothelial carcinoma and synchronous contralateral renal cell carcinoma: A case report  
*Yun JK, Kim SH, Kim WB, Kim HK, Lee SW*
- 7163** Nursing a patient with latent autoimmune diabetes in adults with insulin-related lipodystrophy, allergy, and exogenous insulin autoimmune syndrome: A case report  
*He F, Xu LL, Li YX, Dong YX*
- 7171** Incidental diagnosis of medullary thyroid carcinoma due to persistently elevated procalcitonin in a patient with COVID-19 pneumonia: A case report  
*Saha A, Mukhopadhyay M, Paul S, Bera A, Bandyopadhyay T*
- 7178** Macular hole following phakic intraocular lens implantation: A case report  
*Li XJ, Duan JL, Ma JX, Shang QL*

**LETTER TO THE EDITOR**

- 7184** Is every microorganism detected in the intensive care unit a nosocomial infection? Isn't prevention more important than detection?

*Yildirim F, Karaman I, Yildirim M*



**ABOUT COVER**

Editorial Board Member of *World Journal of Clinical Cases*, Jie-Feng Huang, PhD, Associate Chief Physician, Associate Professor, Department of Orthopaedics and Traumatology, The First Affiliated Hospital of Zhejiang Chinese Medical University, Hangzhou 310006, Zhejiang Province, China. 40983285@qq.com

**AIMS AND SCOPE**

The primary aim of *World Journal of Clinical Cases* (WJCC, *World J Clin Cases*) is to provide scholars and readers from various fields of clinical medicine with a platform to publish high-quality clinical research articles and communicate their research findings online.

WJCC mainly publishes articles reporting research results and findings obtained in the field of clinical medicine and covering a wide range of topics, including case control studies, retrospective cohort studies, retrospective studies, clinical trials studies, observational studies, prospective studies, randomized controlled trials, randomized clinical trials, systematic reviews, meta-analysis, and case reports.

**INDEXING/ABSTRACTING**

The WJCC is now indexed in Science Citation Index Expanded (also known as SciSearch®), Journal Citation Reports/Science Edition, Scopus, PubMed, and PubMed Central. The 2021 Edition of Journal Citation Reports® cites the 2020 impact factor (IF) for WJCC as 1.337; IF without journal self cites: 1.301; 5-year IF: 1.742; Journal Citation Indicator: 0.33; Ranking: 119 among 169 journals in medicine, general and internal; and Quartile category: Q3. The WJCC's CiteScore for 2020 is 0.8 and Scopus CiteScore rank 2020: General Medicine is 493/793.

**RESPONSIBLE EDITORS FOR THIS ISSUE**

Production Editor: Hua-Ge Yin, Production Department Director: Xu Guo, Editorial Office Director: Jin-Lei Wang.

**NAME OF JOURNAL**

*World Journal of Clinical Cases*

**ISSN**

ISSN 2307-8960 (online)

**LAUNCH DATE**

April 16, 2013

**FREQUENCY**

Thrice Monthly

**EDITORS-IN-CHIEF**

Bao-Gan Peng, Jerzy Tadeusz Chudek, George Kontogeorgos, Maurizio Serati, Ja Hyeon Ku

**EDITORIAL BOARD MEMBERS**

<https://www.wjgnet.com/2307-8960/editorialboard.htm>

**PUBLICATION DATE**

July 16, 2022

**COPYRIGHT**

© 2022 Baishideng Publishing Group Inc

**INSTRUCTIONS TO AUTHORS**

<https://www.wjgnet.com/bpg/gerinfo/204>

**GUIDELINES FOR ETHICS DOCUMENTS**

<https://www.wjgnet.com/bpg/GerInfo/287>

**GUIDELINES FOR NON-NATIVE SPEAKERS OF ENGLISH**

<https://www.wjgnet.com/bpg/gerinfo/240>

**PUBLICATION ETHICS**

<https://www.wjgnet.com/bpg/GerInfo/288>

**PUBLICATION MISCONDUCT**

<https://www.wjgnet.com/bpg/gerinfo/208>

**ARTICLE PROCESSING CHARGE**

<https://www.wjgnet.com/bpg/gerinfo/242>

**STEPS FOR SUBMITTING MANUSCRIPTS**

<https://www.wjgnet.com/bpg/GerInfo/239>

**ONLINE SUBMISSION**

<https://www.f6publishing.com>



## Secondary positioning of rotationally asymmetric refractive multifocal intraocular lens in a patient with glaucoma: A case report

Cong Fan, Yi Zhou, Jian Jiang

**Specialty type:** Medicine, research and experimental

**Provenance and peer review:** Unsolicited article; Externally peer reviewed.

**Peer-review model:** Single blind

**Peer-review report's scientific quality classification**

Grade A (Excellent): 0  
Grade B (Very good): 0  
Grade C (Good): C, C  
Grade D (Fair): 0  
Grade E (Poor): 0

**P-Reviewer:** Chrcanovic BR, Sweden; Chrcanovic BR, Sweden

**A-Editor:** Liu X, China

**Received:** November 17, 2021

**Peer-review started:** November 17, 2021

**First decision:** April 13, 2022

**Revised:** April 20, 2022

**Accepted:** May 27, 2022

**Article in press:** May 27, 2022

**Published online:** July 16, 2022



**Cong Fan, Yi Zhou, Jian Jiang**, Department of Ophthalmology, Xiangya Hospital Central South University, Changsha 410000, Hunan Province, China

**Corresponding author:** Jian Jiang, PhD, Associate Professor, Department of Ophthalmology, Xiangya Hospital Central South University, No. 87 Xiangya Road, Changsha 410000, Hunan Province, China. [jiangjianxy@126.com](mailto:jiangjianxy@126.com)

### Abstract

#### BACKGROUND

Asymmetric multifocal intraocular lenses (IOLs) are now widely used in the modern cataract surgery, providing a good level of visual performance over a range of distances and high postoperative patient satisfaction. We report a case of improved visual quality after shifting the near segment of an asymmetrical multifocal IOL to the superotemporal placement in the dominant eye of a glaucoma patient.

#### CASE SUMMARY

A 72-year-old woman with bilateral glaucoma underwent phacoemulsification in the dominant eye (left eye) with implantation of an asymmetrical multifocal IOL. Postoperative uncorrected distance visual acuity (UDVA) was 0.0 logMAR (20/20 Snellen) and uncorrected near visual acuity (UNVA) was 0.1 logMAR (20/25 Snellen). Two weeks later, the patient presented to our clinic with decreased vision due to migration of lens epithelial cells to IOL anterior surface and edema of corneal endothelial cells. Anterior capsule polishing and superotemporal placement of near segment [+3.00 diopter (D) addition (add)] of IOL were performed. As a result, UDVA at the first week and first year after reposition was 0.0 logMAR (20/20 Snellen), and compared with 0.3 logMAR (20/40 Snellen) in the first week, the UNVA was improved to 0.0 logMAR (20/20 Snellen) one year after surgery.

#### CONCLUSION

The postoperative inflammatory reaction and lens epithelial cells proliferation were obvious in this glaucoma patient. Capsule polishing and rotation of the lens were beneficial to the patient, which not only enhanced the patient's vision, but also improved the patient's satisfaction. Therefore, glaucoma patients need to be cautious of implanting multifocal IOLs. Placement of a near segment of an asymmetrical multifocal IOL in the dominant eye should be performed on an individual basis.



**Key Words:** Cataract surgery; Glaucoma; Rotationally asymmetric refractive multifocal intraocular lens; Visual quality; Patient satisfaction; Case report

©The Author(s) 2022. Published by Baishideng Publishing Group Inc. All rights reserved.

**Core Tip:** Based on the design concept of asymmetric region refraction, the placement of asymmetric multifocal intraocular lenses (IOLs) is particularly important. Here, we report the case of a glaucoma patient undergoing cataract surgery with an asymmetric multifocal IOL implanted in the dominant eye. After 2 wk, the lens epithelial cells proliferated rapidly and visual acuity decreased significantly, which was recovered after capsular polishing combined with IOL rotation. By reporting this case, we hope to provide new insights into the implantation of asymmetric multifocal IOLs in patients with glaucoma.

**Citation:** Fan C, Zhou Y, Jiang J. Secondary positioning of rotationally asymmetric refractive multifocal intraocular lens in a patient with glaucoma: A case report. *World J Clin Cases* 2022; 10(20): 7013-7019

**URL:** <https://www.wjgnet.com/2307-8960/full/v10/i20/7013.htm>

**DOI:** <https://dx.doi.org/10.12998/wjcc.v10.i20.7013>

## INTRODUCTION

Cataract is the leading cause of blindness in the world. The development of the intraocular lens (IOL) and phacoemulsification as a technique for cataract removal could be considered as the two most significant strides that have been made in this surgical field[1]. With the development of science and technology, the choice of IOL is becoming more and more diversified and personalized. Asymmetric multifocal IOLs are now widely used in the modern cataract surgery, which provide excellent levels of visual performance at a range of distances as well as high postoperative patient satisfaction[2-4]. Asymmetrical multifocal IOLs, such as the SBL-3 (Lenstec, Inc.) as we mentioned in this case, provide their multifocality through a refractive design by incorporating a near vision section in the IOL[5]. Therefore, the SBL-3 is an asymmetric multifocal IOL with a +3.0 D near portion and a seamless transition zone between distance section and near section, and the asymmetric nature means that the position of the near segment must be considered.

## CASE PRESENTATION

### Chief complaints

A 72-year-old woman was referred to our clinic with a complaint of decreased visual acuity for 1 wk following cataract surgery performed in the left eye 2 wk ago.

### History of present illness

The patient underwent an uneventful phacoemulsification cataract surgery for the left eye at our department 2 wk ago, and a rotationally asymmetric refractive multifocal IOL (SBL-3, Lenstec, Inc.) was chosen and implanted with the near segments placed inferonasally. The first day post-surgery, uncorrected distance visual acuity (UDVA) was 0.0 logMAR (20/20 Snellen) and uncorrected near visual acuity (UNVA) was 0.1 logMAR (20/25 Snellen). Preoperative biometric data are given in Table 1.

### History of past illness

The patient had bilateral primary angle closure glaucoma treated by laser peripheral iridectomy before at a local hospital, bilateral intraocular pressure was normal with no glaucoma medication before cataract surgery, and she had no history of allergies, trauma, surgery, or systemic disease.

### Personal and family history

The patient was married and had two sons. She had no family history of ocular disease.

### Physical examination

The patient presented to our clinic for reexamination with deterioration in the UDVA to 1.0 logMAR (20/200 Snellen) and in the corrected distant visual acuity of 1.0 logMAR (20/200 Snellen). Using a slit lamp, the swelling of the corneal endothelium and proliferation of lens epithelial cells crawling over the surface of the IOL could be clearly seen. Meanwhile, the IOL was in positive position, without any tilt or

Table 1 Preoperative biometric data

Parameter	Left eye
Axial length (mm)	22.46
K1 (D)	44.94 @ 55°
K2 (D)	45.18 @ 145°
ACD (mm)	2.23
Angle kappa (mm)	0.06 @ 56°
Angle alpha (mm)	0.32 @ 28°
Total corneal astigmatism (D)	1.0

K: Keratometry; D: Diopters; ACD: Anterior chamber depth.

decentration, and the near segment was located in inferonasal orientation (Figure 1).

## FINAL DIAGNOSIS

IOL (left), complicated cataract (right), primary angle closure glaucoma (both), and status after laser peripheral iridectomy (both).

## TREATMENT

We performed surgery for polishing the capsule and repositioning the IOL. During surgery, the anterior capsule was polished with a polisher to reduce the incidence of capsular contraction syndrome and posterior capsular opacification (PCO). Meanwhile, the near segment of IOL was shifted to the supero-temporal placement, and coinciding transition zone of IOL with angle Kappa was avoided. At the end of the operation, the central position of the IOL was checked to see whether the light projection of the microscope was on the central point of IOL (Figure 2). Postoperatively, the patient was treated with a schedule of levofloxacin 0.5%, prednisolone, and pranopfen eyedrops for 4 wk.

## OUTCOME AND FOLLOW-UP

The first day after rotation, UDVA and UNVA were 0.2 logMAR (20/32 Snellen) and 0.3 logMAR (20/40 Snellen), respectively. UDVA improved to 0.0 logMAR (20/20 Snellen) 1 wk later (Table 2), and the intraocular pressure was 16 mmHg, which have remained stable during follow-up. One year after rotation, when she checked again, we found that she had a cataract surgery on her right eye at another hospital half a year ago, and the type of the IOL was the same as that on the left. In addition, the near segment of the lens on the right was positioned inferiorly with slight nasal deviation. For the right eye, UDVA and UNVA were 0.0 logMAR (20/20 Snellen) and 0.10 logMAR (20/25 Snellen), respectively. While for the left eye, UDVA and UNVA were 0.0 logMAR (20/20 Snellen) and 0.0 logMAR (20/20 Snellen), respectively. After a series of examinations, the lens position of the left eye was still positive, which almost was unchanged from the previous. Visual quality was assessed using OPD Scan III (Nidek Inc., Tokyo, Japan), and the tilt was acceptable in both horizontal and vertical directions without adversely affecting visual quality. At the same time, the lens position was also positive with no obvious tilt when viewed using ultrasound biomicroscopy (Supplementary Figure 1). The patient was very satisfied with the distant and near visual acuity, and achieved excellent visual performance.

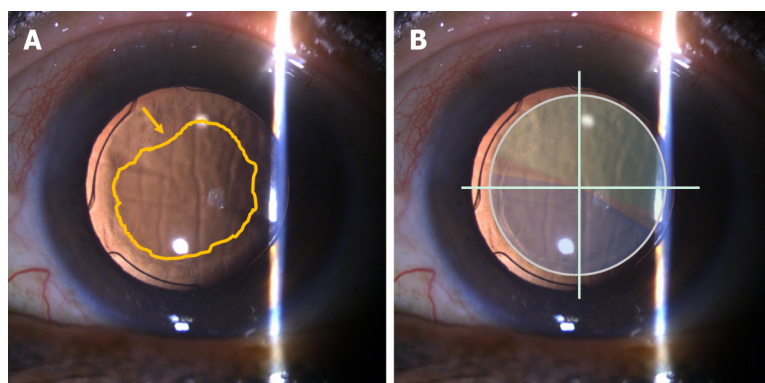
## DISCUSSION

We speculated the reasons for deterioration of postoperative visual quality, such as postoperative inflammation which could lead to proliferation of lens epithelial cells and migration to the anterior surface of IOL, and even corneal endothelial edema and opacity of refractive media. The unique functional and structural characteristics of glaucoma patients lead to an increased risk of PCO, inflammation, and anterior capsular opacification[6-8]. Above all, although the patient's eyesight reflected well

**Table 2 Preoperative and postoperative visual acuity (log MAR, left eye)**

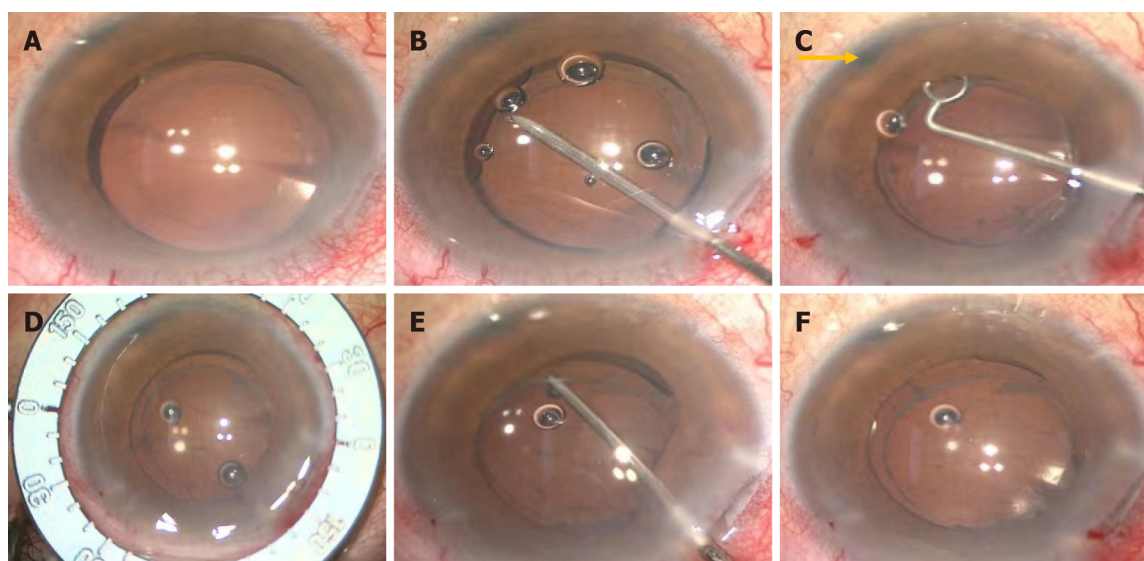
	Preoperative	Postoperative 1 d	Postoperative 2 wk	1 d after rotation	1 wk after rotation	1 yr after rotation
UDVA	0.2 (20/32 Snellen)	0.0 (20/20 Snellen)	1.0 (20/200 Snellen)	0.2 (20/32 Snellen)	0.0 (20/20 Snellen)	0.0 (20/20 Snellen)
CDVA	0.05 (20/25 Snellen)	0.0 (20/20 Snellen)	1.0 (20/200 Snellen)	0.1 (20/25 Snellen)	0.0 (20/20 Snellen)	0.0 (20/20 Snellen)
UNVA	1.0 (20/200 Snellen)	0.1 (20/25 Snellen)	0.5 (20/63 Snellen)	0.3 (20/40 Snellen)	0.3 (20/40 Snellen)	-0.10 (20/16 Snellen)

UDVA: Uncorrected distance visual acuity (5 m); CDVA: Corrected distance visual acuity (5 m); UNVA: Uncorrected near visual acuity (40 cm).



DOI: 10.12998/wjcc.v10.i20.7013 Copyright ©The Author(s) 2022.

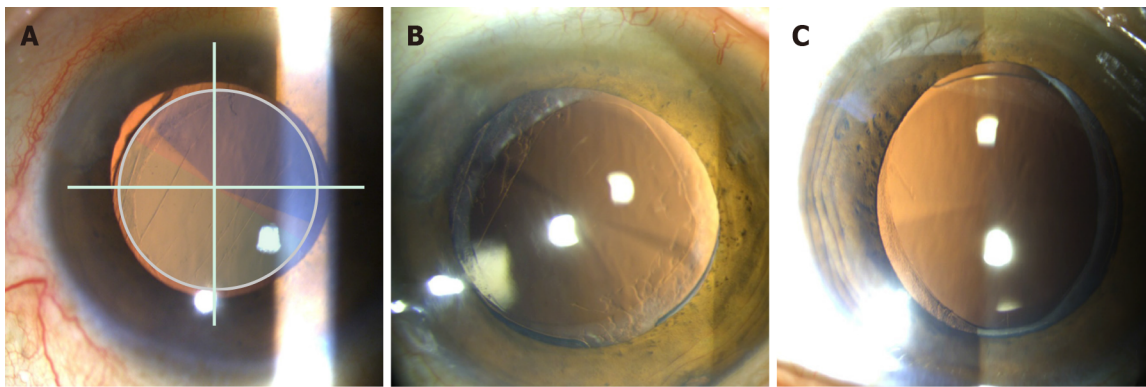
**Figure 1 Slit lamp examinations 2 wk after phacoemulsification in the left eye.** A: The swelling of the corneal endothelium and the proliferation of lens epithelial cells are most pronounced (yellow arrow) over the surface of the intraocular lens; B: The intraocular lens is centered with the near segment placed inferonasally (blue: near segment; green: distant segment).



DOI: 10.12998/wjcc.v10.i20.7013 Copyright ©The Author(s) 2022.

**Figure 2 Intraoperative images of the rotating lens.** A: Preoperatively, the light projection of the microscope coincides with the center of the intraocular lens (IOL); B: Separating capsulorhexis opening with a needle; C: Polishing anterior capsule. The laser hole (yellow arrow) after peripheral iridectomy is clearly visible; D: Locating the position of the IOL after rotation with a ring manually; E: Adjusting the position of the IOL with an IOL hook; F: The light projection of the microscope is on the central point of the IOL after rotation.

numerically, when we repeatedly confirmed her subjective experience on the first day postoperatively, there was no inflammatory reaction and no proliferation of lens epithelial cells, and the patient emphasized that she felt clearly in near vision while obscurely in distant vision. Consequently, we conjectured that lens position might play a key role. Given that the lens was a plate-haptic design for excellent stability, it will be more difficult to rotate it later. Meanwhile, anterior capsule polishing is a method to prevent the occurrence of PCO and enhance visual function[9]. Here, we decided to perform



DOI: 10.12998/wjcc.v10.i20.7013 Copyright ©The Author(s) 2022.

**Figure 3** Slit lamp examinations 1 yr after phacoemulsification in the left eye. A: The intraocular lens (IOL) with the near segment placed superotemporally the first day after rotation in the left eye (blue: near segment; green: distant segment); B: The IOL with the near segment placed superotemporally one year after rotation in the left eye; C: The IOL with the near segment placed inferiorly with slight nasal deviation half a year after phacomulsification in the right eye.

surgery for polishing capsule and repositioning the IOL in the same operation, trying to enhance the patient's visual quality and reduce the patient's complaints and pain.

Why did we choose to rotate the near segment to the superotemporal position rather than somewhere else? SBL-3, as mentioned in this case, is designed based on the concept of asymmetric regional refraction, and the choice of its placement position appears to be particularly important. A study by de Wit *et al*[10] found that the difference between inferonasal near add positioning and superotemporal near add positioning was not statistically significant. What's more, whether the near segment is positioned inferiorly, superiorly, or temporally, there was no significant effect on visual performance [11]. A study by McNeely *et al*[5] found that bilateral implantation of asymmetric multifocal IOLs with a combination of superotemporal placement of the near segment in the dominant eye and inferonasal placement of the near segment in the fellow eye enhanced quality of vision and reduced symptoms such as glare and halo compared with bilateral inferonasal placement. In our case, we chose to shift the near segment to the superotemporal position in the dominant eye (Figure 3); coincidentally, the near segment of the lens of the fellow eye was positioned inferonasally. The patient's satisfactory postoperative results confirmed the feasibility of the mix and match placement scheme.

Because of its asymmetrical design, tilt and decentration had a prominent effect on optical quality with the rotational asymmetric multifocal IOL *in vitro*. Liu *et al*[12] found that the decentration induced increased or decreased optical quality, but tilt yielded decreased optical quality at different orientations. Pazo *et al*[13] also demonstrated that rotation of the asymmetric IOL can be used to both recenter the IOL and increase the required surface area of either distance or near component within the physiological pupil, thereby optimizing visual outcomes. These are all important considerations when using this asymmetric multifocal IOL.

There has been considerable debate over whether multifocal IOL implantation is a suitable choice for glaucoma patients. Studies have shown that glaucoma patients can benefit from multifocal IOL technology and achieve spectacle independence with no significant adverse effects[14]. Use of these IOLs in the presence of concurrent eye diseases has not been extensively studied. Thus, decisions regarding the choice of a multifocal IOL in patients with glaucoma must be made on an individual basis, with patient motivation and expectation being a prime mover. The rate of progression of glaucoma in an individual patient is also an important consideration[15].

## CONCLUSION

The postoperative inflammatory reaction and lens epithelial cell proliferation were obvious in this glaucoma patient. Capsule polishing and rotation of the lens were beneficial to the patient, which not only enhanced the patient's vision, but also improved the patient's satisfaction. Glaucoma patients need to be cautious of implanting multifocal IOLs. Placement of a near segment of an asymmetrical multifocal IOL in the dominant eye should be performed on an individual basis. Although cataract surgery for glaucoma patients may be challenging, it affords an opportunity to dramatically improve the quality of life of patients.



## FOOTNOTES

**Author contributions:** Fan C was a major contributor in acquisition of the data, literature search, and manuscript draft; Zhou Y analyzed and interpreted the imaging findings, and contributed to manuscript drafting; Jiang J was the patient's surgeon, provided the concept and design, and was responsible for the revision of the manuscript for important intellectual content; all authors issued final approval for the version to be submitted.

**Supported by** National Natural Science Foundation of China, No. 81974130; and Natural Science Foundation of Hunan Province, China, No. 2020JJ4882.

**Informed consent statement:** Informed written consent was obtained from the patient for publication of this report and any accompanying images.

**Conflict-of-interest statement:** All the authors report no relevant conflicts of interest for this article.

**CARE Checklist (2016) statement:** The authors have read the CARE Checklist (2016), and the manuscript was prepared and revised according to the CARE Checklist (2016).

**Open-Access:** This article is an open-access article that was selected by an in-house editor and fully peer-reviewed by external reviewers. It is distributed in accordance with the Creative Commons Attribution NonCommercial (CC BY-NC 4.0) license, which permits others to distribute, remix, adapt, build upon this work non-commercially, and license their derivative works on different terms, provided the original work is properly cited and the use is non-commercial. See: <https://creativecommons.org/licenses/by-nc/4.0/>

**Country/Territory of origin:** China

**ORCID number:** Cong Fan 0000-0003-1930-7574; Yi Zhou 0000-0002-2493-7434; Jian Jiang 0000-0001-9395-3748.

**S-Editor:** Gao CC

**L-Editor:** Wang TQ

**P-Editor:** Gao CC

## REFERENCES

- 1 **Fraser IS.** Relationship between gonadotrophin-releasing hormone analogue therapy and bone loss; a review. *Reprod Fertil Dev* 1991; **3**: 61-69 [PMID: 1957015 DOI: 10.1071/rd9910061]
- 2 **Venter JA,** Barclay D, Pelouskova M, Bull CE. Initial experience with a new refractive rotationally asymmetric multifocal intraocular lens. *J Refract Surg* 2014; **30**: 770-776 [PMID: 25375850 DOI: 10.3928/1081597X-20141021-09]
- 3 **Wang X,** Tu H, Wang Y. Comparative Analysis of Visual Performance and Optical Quality with a Rotationally Asymmetric Multifocal Intraocular Lens and an Apodized Diffractive Multifocal Intraocular Lens. *J Ophthalmol* 2020; **2020**: 7923045 [PMID: 32377423 DOI: 10.1155/2020/7923045]
- 4 **Moore JE,** McNeely RN, Pazo EE, Moore TC. Rotationally asymmetric multifocal intraocular lenses: preoperative considerations and postoperative outcomes. *Curr Opin Ophthalmol* 2017; **28**: 9-15 [PMID: 27828894 DOI: 10.1097/ICU.0000000000000339]
- 5 **McNeely RN,** Pazo E, Spence A, Richoz O, Nesbit MA, Moore TC, Moore JE. Comparison of the visual performance and quality of vision with combined symmetrical inferonasal near addition vs inferonasal and superotemporal placement of rotationally asymmetric refractive multifocal intraocular lenses. *J Cataract Refract Surg* 2016; **42**: 1721-1729 [PMID: 28007103 DOI: 10.1016/j.jcrs.2016.10.016]
- 6 **Teichman JC,** Ahmed II. Intraocular lens choices for patients with glaucoma. *Curr Opin Ophthalmol* 2010; **21**: 135-143 [PMID: 20040877 DOI: 10.1097/ICU.0b013e3283365154]
- 7 **Quigley HA.** Long-term follow-up of laser iridotomy. *Ophthalmology* 1981; **88**: 218-224 [PMID: 7231918 DOI: 10.1016/s0161-6420(81)35038-6]
- 8 **Liebmann JM,** Ritch R. Laser surgery for angle closure glaucoma. *Semin Ophthalmol* 2002; **17**: 84-91 [PMID: 15513461 DOI: 10.1076/soph.17.2.84.14720]
- 9 **Han MY,** Yu AH, Yuan J, Cai XJ, Ren JB. Effect of anterior capsule polish on visual function: A meta-analysis. *PLoS One* 2019; **14**: e0210205 [PMID: 30620750 DOI: 10.1371/journal.pone.0210205]
- 10 **de Wit DW,** Diaz J, Moore TC, Moutari S, Moore JE. Effect of position of near addition in an asymmetric refractive multifocal intraocular lens on quality of vision. *J Cataract Refract Surg* 2015; **41**: 945-955 [PMID: 26049829 DOI: 10.1016/j.jcrs.2014.07.045]
- 11 **Song IS,** Yoon SY, Kim JY, Kim MJ, Tchah H. Influence of Near-Segment Positioning in a Rotationally Asymmetric Multifocal Intraocular Lens. *J Refract Surg* 2016; **32**: 238-243 [PMID: 27070230 DOI: 10.3928/1081597X-20160217-06]
- 12 **Liu X,** Xie L, Huang Y. Effects of decentration and tilt at different orientations on the optical performance of a rotationally asymmetric multifocal intraocular lens. *J Cataract Refract Surg* 2019; **45**: 507-514 [PMID: 30947854 DOI: 10.1016/j.jcrs.2018.10.045]
- 13 **Pazo EE,** Richoz O, McNeely R, Millar ZA, Moore TC, Moore JE. Optimized Visual Outcome After Asymmetrical Multifocal IOL Rotation. *J Refract Surg* 2016; **32**: 494-496 [PMID: 27400082 DOI: 10.3928/1081597X-20160503-01]

- 14 **Ouchi M**, Kinoshita S. Implantation of refractive multifocal intraocular lens with a surface-embedded near section for cataract eyes complicated with a coexisting ocular pathology. *Eye (Lond)* 2015; **29**: 649-655 [PMID: [25744442](#) DOI: [10.1038/eye.2015.12](#)]
- 15 **Kumar BV**, Phillips RP, Prasad S. Multifocal intraocular lenses in the setting of glaucoma. *Curr Opin Ophthalmol* 2007; **18**: 62-66 [PMID: [17159450](#) DOI: [10.1097/ICU.0b013e328011d108](#)]





Published by **Baishideng Publishing Group Inc**  
7041 Koll Center Parkway, Suite 160, Pleasanton, CA 94566, USA

**Telephone:** +1-925-3991568

**E-mail:** [bpgoffice@wjgnet.com](mailto:bpgoffice@wjgnet.com)

**Help Desk:** <https://www.f6publishing.com/helpdesk>

<https://www.wjgnet.com>

