

# World Journal of *Clinical Cases*

*World J Clin Cases* 2022 May 16; 10(14): 4327-4712



## Contents

Thrice Monthly Volume 10 Number 14 May 16, 2022

## OPINION REVIEW

- 4327 Emerging role of biosimilars in the clinical care of inflammatory bowel disease patients  
*Najeeb H, Yasmin F, Surani S*

## MINIREVIEWS

- 4334 Practical insights into chronic management of hepatic Wilson's disease  
*Lynch EN, Campani C, Innocenti T, Dragoni G, Forte P, Galli A*
- 4348 Adipose-derived stem cells in the treatment of hepatobiliary diseases and sepsis  
*Satilmis B, Cicek GS, Cicek E, Akbulut S, Sahin TT, Yilmaz S*

## ORIGINAL ARTICLE

## Clinical and Translational Research

- 4357 Learning curve for a surgeon in robotic pancreaticoduodenectomy through a "G"-shaped approach: A cumulative sum analysis  
*Wei ZG, Liang CJ, Du Y, Zhang YP, Liu Y*
- 4368 Clinical and prognostic significance of expression of phosphoglycerate mutase family member 5 and Parkin in advanced colorectal cancer  
*Wu C, Feng ML, Jiao TW, Sun MJ*

## Case Control Study

- 4380 Significance of preoperative peripheral blood neutrophil-lymphocyte ratio in predicting postoperative survival in patients with multiple myeloma bone disease  
*Xu ZY, Yao XC, Shi XJ, Du XR*

## Retrospective Study

- 4395 Association between depression and malnutrition in pulmonary tuberculosis patients: A cross-sectional study  
*Fang XE, Chen DP, Tang LL, Mao YJ*
- 4404 Pancreatic cancer incidence and mortality patterns in 2006-2015 and prediction of the epidemiological trend to 2025 in China  
*Yin MY, Xi LT, Liu L, Zhu JZ, Qian LJ, Xu CF*
- 4414 Evaluation of short- and medium-term efficacy and complications of ultrasound-guided ablation for small liver cancer  
*Zhong H, Hu R, Jiang YS*

- 4425** Hematopoiesis reconstitution and anti-tumor effectiveness of Pai-Neng-Da capsule in acute leukemia patients with haploidentical hematopoietic stem cell transplantation

*Yuan JJ, Lu Y, Cao JJ, Pei RZ, Gao RL*

- 4436** Oral and maxillofacial pain as the first sign of metastasis of an occult primary tumour: A fifteen-year retrospective study

*Shan S, Liu S, Yang ZY, Wang TM, Lin ZT, Feng YL, Pakezhati S, Huang XF, Zhang L, Sun GW*

- 4446** Reduced serum high-density lipoprotein cholesterol levels and aberrantly expressed cholesterol metabolism genes in colorectal cancer

*Tao JH, Wang XT, Yuan W, Chen JN, Wang ZJ, Ma YB, Zhao FQ, Zhang LY, Ma J, Liu Q*

### Observational Study

- 4460** Correlation of pressure gradient in three hepatic veins with portal pressure gradient

*Wang HY, Song QK, Yue ZD, Wang L, Fan ZH, Wu YF, Dong CB, Zhang Y, Meng MM, Zhang K, Jiang L, Ding HG, Zhang YN, Yang YP, Liu FQ*

- 4470** Multi-slice spiral computed tomography in diagnosing unstable pelvic fractures in elderly and effect of less invasive stabilization

*Huang JG, Zhang ZY, Li L, Liu GB, Li X*

### SYSTEMATIC REVIEWS

- 4480** Distribution and changes in hepatitis C virus genotype in China from 2010 to 2020

*Yang J, Liu HX, Su YY, Liang ZS, Rao HY*

### CASE REPORT

- 4494** Bow hunter's syndrome successfully treated with a posterior surgical decompression approach: A case report and review of literature

*Orlandi N, Cavallieri F, Grisendi I, Romano A, Ghadirpour R, Napoli M, Moratti C, Zanichelli M, Pascarella R, Valzania F, Zedde M*

- 4502** Histological remission of eosinophilic esophagitis under asthma therapy with IL-5 receptor monoclonal antibody: A case report

*Huguenot M, Bruhm AC, Essig M*

- 4509** Cutaneous mucosa-associated lymphoid tissue lymphoma complicating Sjögren's syndrome: A case report and review of literature

*Liu Y, Zhu J, Huang YH, Zhang QR, Zhao LL, Yu RH*

- 4519** Plexiform neurofibroma of the cauda equina with follow-up of 10 years: A case report

*Chomanskis Z, Juskys R, Cepkus S, Dulko J, Hendrixson V, Ruksenas O, Rocka S*

- 4528** Mixed porokeratosis with a novel mevalonate kinase gene mutation: A case report

*Xu HJ, Wen GD*

- 4535** Isolated pancreatic injury caused by abdominal massage: A case report

*Sun BL, Zhang LL, Yu WM, Tuo HF*

- 4541** Bronchiolar adenoma with unusual presentation: Two case reports  
*Du Y, Wang ZY, Zheng Z, Li YX, Wang XY, Du R*
- 4550** Periodontal-orthodontic interdisciplinary management of a “periodontally hopeless” maxillary central incisor with severe mobility: A case report and review of literature  
*Jiang K, Jiang LS, Li HX, Lei L*
- 4563** Anesthesia management for cesarean section in a pregnant woman with odontogenic infection: A case report  
*Ren YL, Ma YS*
- 4569** Convulsive-like movements as the first symptom of basilar artery occlusive brainstem infarction: A case report  
*Wang TL, Wu G, Liu SZ*
- 4574** Globe luxation may prevent myopia in a child: A case report  
*Li Q, Xu YX*
- 4580** Computer tomography-guided negative pressure drainage treatment of intrathoracic esophagojejunal anastomotic leakage: A case report  
*Jiang ZY, Tao GQ, Zhu YF*
- 4586** Primary or metastatic lung cancer? Sebaceous carcinoma of the thigh: A case report  
*Wei XL, Liu Q, Zeng QL, Zhou H*
- 4594** Perianesthesia emergency repair of a cut endotracheal tube’s inflatable tube: A case report  
*Wang TT, Wang J, Sun TT, Hou YT, Lu Y, Chen SG*
- 4601** Diagnosis of cytomegalovirus encephalitis using metagenomic next-generation sequencing of blood and cerebrospinal fluid: A case report  
*Xu CQ, Chen XL, Zhang DS, Wang JW, Yuan H, Chen WF, Xia H, Zhang ZY, Peng FH*
- 4608** Primary sigmoid squamous cell carcinoma with liver metastasis: A case report  
*Li XY, Teng G, Zhao X, Zhu CM*
- 4617** Acute recurrent cerebral infarction caused by moyamoya disease complicated with adenomyosis: A case report  
*Zhang S, Zhao LM, Xue BQ, Liang H, Guo GC, Liu Y, Wu RY, Li CY*
- 4625** Serum-negative Sjogren's syndrome with minimal lesion nephropathy as the initial presentation: A case report  
*Li CY, Li YM, Tian M*
- 4632** Successful individualized endodontic treatment of severely curved root canals in a mandibular second molar: A case report  
*Xu LJ, Zhang JY, Huang ZH, Wang XZ*



- 4640** Successful treatment in one myelodysplastic syndrome patient with primary thrombocytopenia and secondary deep vein thrombosis: A case report  
*Liu WB, Ma JX, Tong HX*
- 4648** Diagnosis of an extremely rare case of malignant adenomyoepithelioma in pleomorphic adenoma: A case report  
*Zhang WT, Wang YB, Ang Y, Wang HZ, Li YX*
- 4654** Management about intravesical histological transformation of prostatic mucinous carcinoma after radical prostatectomy: A case report  
*Bai SJ, Ma L, Luo M, Xu H, Yang L*
- 4661** Hepatopulmonary metastases from papillary thyroid microcarcinoma: A case report  
*Yang CY, Chen XW, Tang D, Yang WJ, Mi XX, Shi JP, Du WD*
- 4669** PD-1 inhibitor in combination with fruquintinib therapy for initial unresectable colorectal cancer: A case report  
*Zhang HQ, Huang CZ, Wu JY, Wang ZL, Shao Y, Fu Z*
- 4676** Cutaneous metastasis from esophageal squamous cell carcinoma: A case report  
*Zhang RY, Zhu SJ, Xue P, He SQ*
- 4684** Rare pattern of Maisonneuve fracture: A case report  
*Zhao B, Li N, Cao HB, Wang GX, He JQ*
- 4691** Suprasellar cistern tuberculoma presenting as unilateral ocular motility disorder and ptosis: A case report  
*Zhao BB, Tian C, Fu LJ, Zhang XB*
- 4698** Development of plasma cell dyscrasias in a patient with chronic myeloid leukemia: A case report  
*Zhang N, Jiang TD, Yi SH*
- 4704** Ovarian growing teratoma syndrome with multiple metastases in the abdominal cavity and liver: A case report  
*Hu X, Jia Z, Zhou LX, Kakongoma N*

**LETTER TO THE EDITOR**

- 4709** Perfectionism and mental health problems: Limitations and directions for future research  
*Nazari N*

**ABOUT COVER**

Editorial Board Member of *World Journal of Clinical Cases*, Jamir Pitton Rissardo, MD, Academic Research, Adjunct Associate Professor, Research Associate, Department of Medicine, Federal University of Santa Maria, Santa Maria 97105110, Brazil. jamirrissardo@gmail.com

**AIMS AND SCOPE**

The primary aim of *World Journal of Clinical Cases* (WJCC, *World J Clin Cases*) is to provide scholars and readers from various fields of clinical medicine with a platform to publish high-quality clinical research articles and communicate their research findings online.

WJCC mainly publishes articles reporting research results and findings obtained in the field of clinical medicine and covering a wide range of topics, including case control studies, retrospective cohort studies, retrospective studies, clinical trials studies, observational studies, prospective studies, randomized controlled trials, randomized clinical trials, systematic reviews, meta-analysis, and case reports.

**INDEXING/ABSTRACTING**

The WJCC is now indexed in Science Citation Index Expanded (also known as SciSearch®), Journal Citation Reports/Science Edition, Scopus, PubMed, and PubMed Central. The 2021 Edition of Journal Citation Reports® cites the 2020 impact factor (IF) for WJCC as 1.337; IF without journal self cites: 1.301; 5-year IF: 1.742; Journal Citation Indicator: 0.33; Ranking: 119 among 169 journals in medicine, general and internal; and Quartile category: Q3. The WJCC's CiteScore for 2020 is 0.8 and Scopus CiteScore rank 2020: General Medicine is 493/793.

**RESPONSIBLE EDITORS FOR THIS ISSUE**

Production Editor: Hua-Ge Yin, Production Department Director: Xu Guo, Editorial Office Director: Jin-Lei Wang.

**NAME OF JOURNAL**

*World Journal of Clinical Cases*

**ISSN**

ISSN 2307-8960 (online)

**LAUNCH DATE**

April 16, 2013

**FREQUENCY**

Thrice Monthly

**EDITORS-IN-CHIEF**

Bao-Gan Peng, Jerzy Tadeusz Chudek, George Kontogeorgos, Maurizio Serati, Ja Hyeon Ku

**EDITORIAL BOARD MEMBERS**

<https://www.wjgnet.com/2307-8960/editorialboard.htm>

**PUBLICATION DATE**

May 16, 2022

**COPYRIGHT**

© 2022 Baishideng Publishing Group Inc

**INSTRUCTIONS TO AUTHORS**

<https://www.wjgnet.com/bpg/gerinfo/204>

**GUIDELINES FOR ETHICS DOCUMENTS**

<https://www.wjgnet.com/bpg/GerInfo/287>

**GUIDELINES FOR NON-NATIVE SPEAKERS OF ENGLISH**

<https://www.wjgnet.com/bpg/gerinfo/240>

**PUBLICATION ETHICS**

<https://www.wjgnet.com/bpg/GerInfo/288>

**PUBLICATION MISCONDUCT**

<https://www.wjgnet.com/bpg/gerinfo/208>

**ARTICLE PROCESSING CHARGE**

<https://www.wjgnet.com/bpg/gerinfo/242>

**STEPS FOR SUBMITTING MANUSCRIPTS**

<https://www.wjgnet.com/bpg/GerInfo/239>

**ONLINE SUBMISSION**

<https://www.f6publishing.com>



# Successful treatment in one myelodysplastic syndrome patient with primary thrombocytopenia and secondary deep vein thrombosis: A case report

Wen-Bin Liu, Jian-Xiong Ma, Hong-Xuan Tong

**Specialty type:** Hematology

**Provenance and peer review:**

Unsolicited article; Externally peer reviewed.

**Peer-review model:** Single blind

**Peer-review report's scientific quality classification**

Grade A (Excellent): 0  
Grade B (Very good): B  
Grade C (Good): C; C  
Grade D (Fair): 0  
Grade E (Poor): 0

**P-Reviewer:** Gaman MA, Romania;  
Gessler F, Germany

**Received:** November 16, 2021

**Peer-review started:** November 16, 2021

**First decision:** December 27, 2021

**Revised:** January 9, 2022

**Accepted:** April 3, 2022

**Article in press:** April 3, 2022

**Published online:** May 16, 2022



**Wen-Bin Liu**, Department of Hematology, The First Affiliated Hospital of Zhejiang Chinese Medical University, Hangzhou 310006, Zhejiang Province, China

**Jian-Xiong Ma**, The Second Clinical Medical College, Zhejiang Chinese Medical University, Hangzhou 320000, Zhejiang Province, China

**Hong-Xuan Tong**, Institute of Basic Theory for Chinese Medicine, China Academy of Chinese Medical Sciences, Beijing 100700, China

**Corresponding author:** Hong-Xuan Tong, PhD, Associate Professor, Institute of Basic Theory for Chinese Medicine, China Academy of Chinese Medical Sciences, No.16 Nanxiao Street, Dongcheng District, Beijing, 100700, China. [thongxuan1@163.com](mailto:thongxuan1@163.com)

## Abstract

### BACKGROUND

The contradictory process of coagulation and anticoagulation maintains normal physiological function, and platelets (PLTs) play a key role in hemostasis and bleeding. When severe thrombocytopenia and deep vein thrombosis (DVT) occur simultaneously, the physician will be confronted with a great challenge, especially when interventional thrombectomy fails.

### CASE SUMMARY

We describe a 52-year-old woman who suffered from myelodysplastic syndrome with severe thrombocytopenia and protein S deficiency with right lower extremity DVT. In this patient, the treatment of DVT was associated with numerous contradictions due to severe thrombocytopenia, especially when interventional thrombectomy was not successful. Fortunately, fondaparinux sodium effectively alleviated the thrombus status of the patient and gradually decreased the D-dimer level. In addition, no increase in bleeding was noted. The application of eltrombopag stimulated the maturation and differentiation of megakaryocytes and increased the peripheral blood PLT count. The clinical symptoms of DVT in the right lower extremities in this patient significantly improved. The patient resumed daily life activities, and the treatment effects were independent of PLT transfusion.

### CONCLUSION

This is a contradictory and complex case, and fondaparinux sodium and

eltrombopag may represent a good choice for the treatment of DVT in patients with severe thrombocytopenia.

**Key Words:** Thrombocytopenia; Deep vein thrombosis; Fondaparinux sodium; Thrombophilia; Myelodysplastic syndrome; Eltrombopag; Case report

©The Author(s) 2022. Published by Baishideng Publishing Group Inc. All rights reserved.

**Core Tip:** One 52-year-old Chinese female suffered from myelodysplastic syndrome of multilineage dysplasia with severe thrombocytopenia and thrombophilia with deep vein thrombosis. In the basic treatment for underlying diseases, the treatment of thrombosis is full of contradictions because of the low platelets, especially in the situation that the curative effect of surgical thrombectomy was not obvious. Pleasantly, Fondaparinux sodium effectively alleviated the thrombus status, and the D-dimer gradually decreased. In addition, there was not any unexpected bleeding. This patient's circumference of right lower limb recovered and restored the movement basically finally.

**Citation:** Liu WB, Ma JX, Tong HX. Successful treatment in one myelodysplastic syndrome patient with primary thrombocytopenia and secondary deep vein thrombosis: A case report. *World J Clin Cases* 2022; 10(14): 4640-4647

**URL:** <https://www.wjgnet.com/2307-8960/full/v10/i14/4640.htm>

**DOI:** <https://dx.doi.org/10.12998/wjcc.v10.i14.4640>

## INTRODUCTION

Myelodysplastic syndrome (MDS) is a common hematological malignancy, and its clinical outcome is closely related to the consequences of leukemic evolution or serious clinical events[1]. In all events, thrombosis is a low-risk symptom due to the high frequency of thrombocytopenia and severe anemia, and the rate is similar to that in the general population. However, when pathophysiological changes occur, including vascular complications and the activation of thrombophilia-associated genes, the risk of thrombosis may be increased. As one type of thrombosis, venous thromboembolism (VTE) is considered a multifactorial disease[2] affected by comprehensive clinical signs of interaction from single or multiple genetic, epigenetic and/or acquired predisposing factors[3]. Among them, mutations in these genes eventually lead to the formation of thrombi, including prothrombin, factor V Leiden, protein C (PC) and protein S (PS)[4].

As the typical blood pattern of MDS, thrombocytopenia [platelets (PLTs)  $< 100 \times 10^9/L$ ] occurs in approximately 40%-65% of MDS patients, and severe thrombocytopenia (PLTs  $< 20 \times 10^9/L$ ) accounts for approximately 17%[5], which is closely associated with a high risk of bleeding, rather than deep vein thrombosis (DVT). Thus, reports about the combination of severe thrombocytopenia and DVT in MDS patients are limited, and successful treatment is even rarer. Here, we present a case of an MDS patient with complicated comorbid diseases, and this is the first case of successful application of fondaparinux sodium and eltrombopag in the treatment of DVT with severe thrombocytopenia.

## CASE PRESENTATION

### Chief complaints

A 52-year-old woman was admitted to the hematology department of our hospital in November 2019 with dizziness and fatigue for 8 years and right lower limb swelling and pain for 6 d.

### History of present illness

The patient felt dizziness and fatigue in January 2011, and these symptoms worsened after activity and were aggravated gradually without treatment. She first presented at a local hospital in August 2011. Routine blood examination revealed the following: White blood cells (WBCs)  $4.0 \times 10^9/L$ , hemoglobin (Hb) 55 g/L, PLTs  $20 \times 10^9/L$ , and reticulocytes 2%. The bone marrow morphology was characterized by nucleated cells with active proliferation. Erythroid hyperplasia was noted in 48% of erythroid cells. Megaloblastic erythrocytes and 20 megakaryocytes were found. Bone marrow biopsy showed that hematopoietic tissue accounted for approximately 75% of the biopsy. Small megakaryocytes were noted with reticular fiber (+). Chromosome analysis revealed 46 XX. The patient was diagnosed with MDS with refractory anemia and treated with androgen, cyclosporin, and intermittent blood transfusion

support. Hb was maintained at 100-120 g/L, and the PLT count was  $50-80 \times 10^9/L$ . However, in 2014, she stopped taking cyclosporine due to renal damage. As she was no longer dependent on blood transfusion, the patient had stopped taking the medicine and her follow-up treatment on her own. In November 2019, the values for the peripheral blood factors decreased as follows: WBC  $2.9 \times 10^9/L$ , Hb 70 g/L, and PLT  $20 \times 10^9/L$ . She began treatment with 200 mg danazol quaque die (qd) and 50 mg thalidomide quaque nocte. Unfortunately, the patient presented with right lower limb swelling that had gradually become aggravated 1 mo later, and the patient gradually lost the ability to exercise. However, blisters were scattered on the skin of the right lower limb, and her temperature increased (Figure 1A and B). The patient underwent an emergency transfer to the hematology department of our hospital on November 25, 2019.

### History of past illness

The patient had type 2 diabetes for 5 years, which was controlled well by taking acarbose tablets (50 mg three times a day). She had a history of blood transfusion but no blood transfusion allergy response.

### Personal and family history

Her parents had died, and she had an older sister with parkinson's disease and a healthy son. She denied any history of family genetic disease.

### Physical examination

On admission, the patient presented with anemia, and occasional bleeding spots were seen on the skin. The skin of the right lower limb was red and swollen with several transparent soybean-sized blisters, and the temperature of the skin was elevated. Her limb showed extreme tenderness with mild concave edema, which resulted in dysmobility of the right lower limb.

### Laboratory examinations

The complete blood count analysis revealed pancytopenia (WBC  $2.8 \times 10^9/L$ , neutrophils  $1.6 \times 10^9/L$ , Hb 88 g/L, PLT  $15 \times 10^9/L$ ), and her D-dimer was 16.48 mg/L. Screening analysis of anticoagulant proteins demonstrated a markedly low level of PS activity (25%, reference value: 55%-130%), whereas antithrombin (AT) III and PC levels were normal. Lower extremity vascular ultrasound revealed extensive acute incomplete thrombosis in the right lower extremities, including the external iliac vein, common femoral vein, superficial femoral vein, deep femoral vein, popliteal vein, and posterior tibial vein of the right lower limb (November 6, 2019). Bone marrow morphology revealed nucleated cells with active proliferation. Primitive cells accounted for 3% of cells, and 12 megakaryocytes were found. Bone marrow biopsy showed that hematopoietic tissue accounted for approximately 70% of the biopsy. Activated nucleated cell hyperplasia was noted, and a small number of mature lymphocytes and plasma cells were observed. The chromosome analysis revealed 46 XX.

### Imaging examinations

Deep venous ultrasound of the right lower extremity showed that extensive acute incomplete thrombosis in the right lower extremities in November 26, 2019. While, it showed that old thrombosis in the common and superficial femoral veins of the right lower limb in January 2, 2020.

### Genetic examinations

Whole-exome sequencing detection: Figure 2 shows the gene sequencing results of the patient and the patient's son. A heterozygous mutation of the *PROS1* gene was found in the patient (c.1351C > T), but the same mutation was not observed in the patient's son.

### Bone marrow cell examination and bone marrow biopsy report

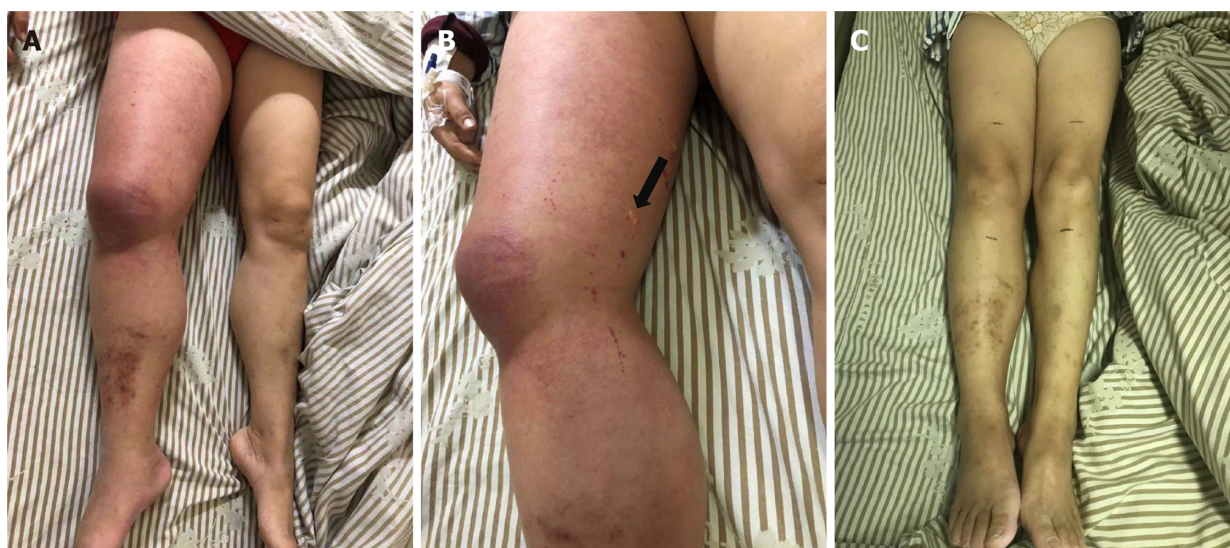
**Bone marrow cell examination (December 23, 2019):** Obvious proliferation of the erythroid cell line with poor platelet production function was observed in the megakaryocyte line (Figure 3A).

**Bone marrow biopsy (December 31, 2019):** Bone marrow hematopoiesis of the "posterior iliac spine" (Figure 3B) revealed approximately 70% fat. In addition, active nucleated cell hyperplasia was noted in 30% of cells. Granulocyte proliferation was still active. Granulocytes in the mature stage was slightly reduced. Erythroid hyperplasia was obviously active, mainly in the middle and late stages of erythroblasts, with some cells of different sizes. The number of megakaryocytes was reduced (0-2/high power field), and the morphology was roughly normal. A small number of mature lymphocytes and plasma cells were observed.

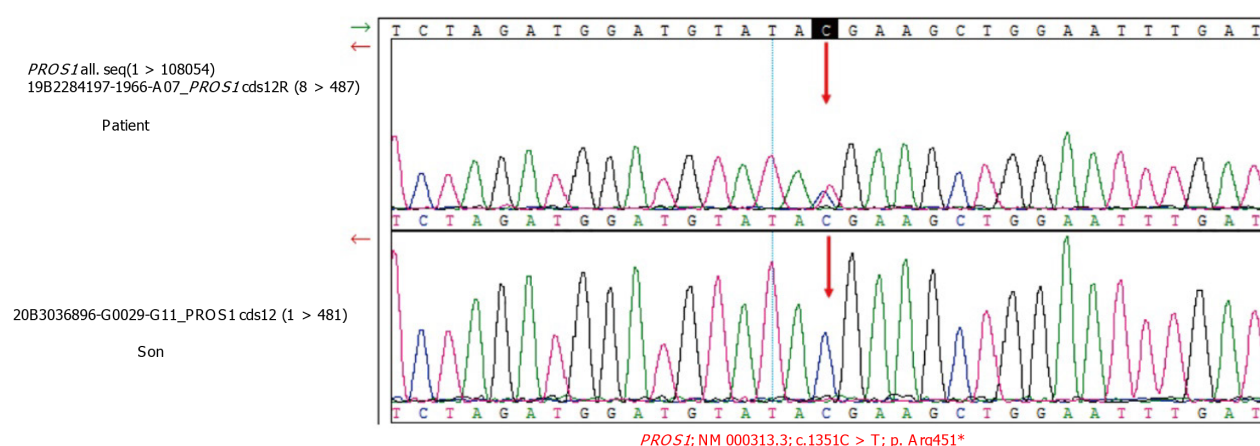
## FINAL DIAGNOSIS

The patient was diagnosed with MDS-multilineage dysplasia (MDS-MLD), international prognostic





**Figure 1 The right lower limb of the patient.** A: The skin of the right lower limb became red; B: Swollen with several soybean-sized transparent blisters before therapy (the black arrow indicates the blister site); C: Both lower limbs of the patient had the same circumference after 3 wk of treatment with fondaparinux sodium.

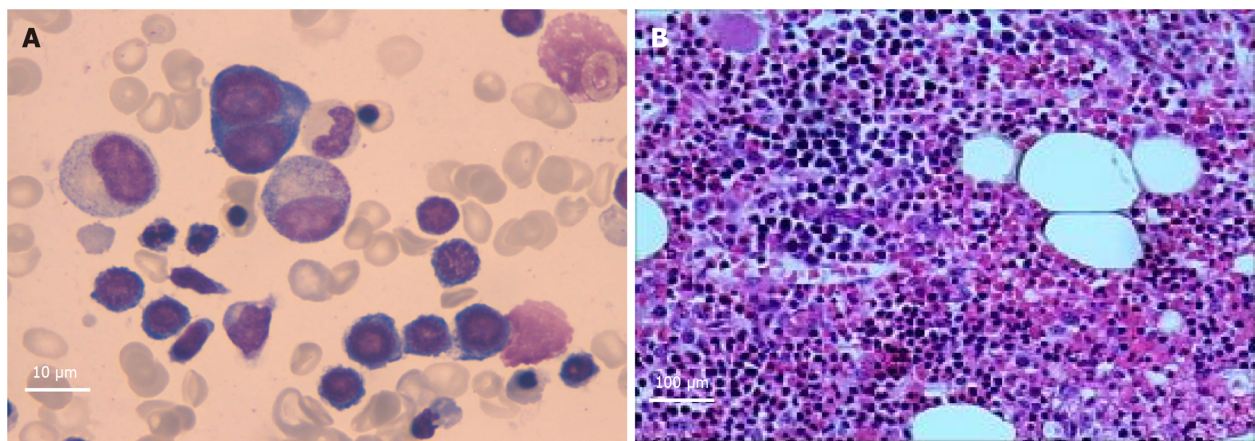


**Figure 2 Sanger sequencing results indicating a positive *PROS1* mutation [c.1351C > T (p. Arg451)] (red arrow indicates the mutation site). NM: RefSeq of mRNA.**

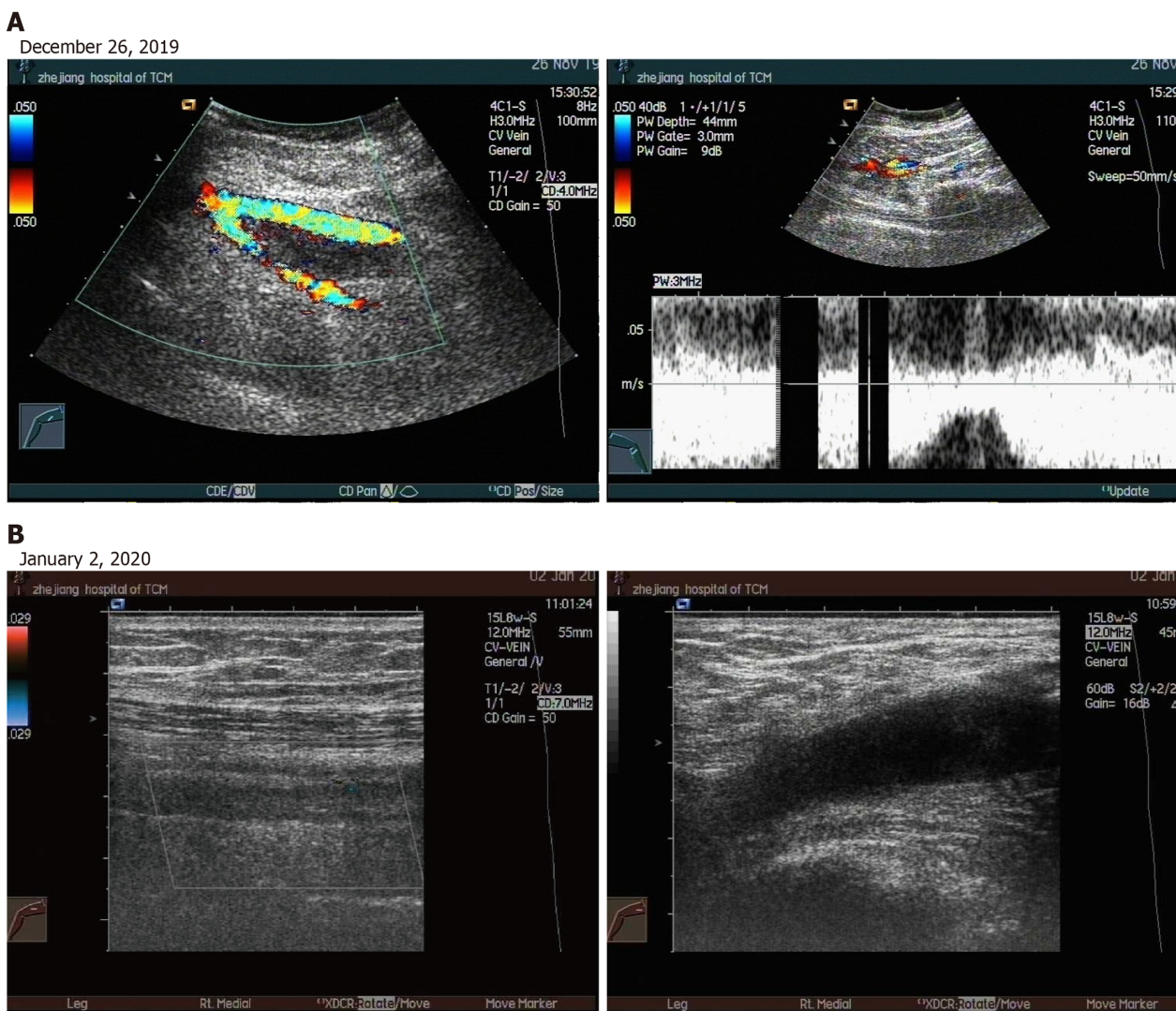
scoring system intermediate I-risk group, PS deficiency (*PROS1* heterozygous mutation), right lower extremity deep vein thrombosis, and Type 2 diabetes mellitus.

## TREATMENT

On admission, the patient discontinued treatment with thalidomide and danazole immediately. To improve the clinical condition as quickly as possible, the patient received treatment with deep venous thrombosis aspiration and inferior vena cava filter implantation on November 26, 2019. However, interventional thrombectomy failed. After the surgery, the patient developed chills and fever, which increased to 38.5 degrees. The PLT count dropped to less than  $10 \times 10^9/L$ , and PLT transfusions were necessary. However, the swelling of the right limb did not improve. In addition to anti-infection and transfusion therapy, the patient received anticoagulant therapy with fondaparinux sodium (2.5 mg injection hypodermic qd). Fortunately, the patient's temperature became normal, and the blisters in the right lower extremity subsided after 1 wk of therapy. In addition, the edema lessened after 2 wk, and swelling of the affected limb subsided to normal after 3 wk. Soon after, the patient regained basic mobility (Figure 1C). On December 26, the patient was administered eltrombopag (50 mg qd) to promote the maturation and differentiation of megakaryocytes and increase the peripheral blood platelet count. On January 2, 2020, vascular ultrasound showed thrombosis in the common femoral vein and superficial femoral vein of the right lower extremity; however, the conditions had improved compared to the first time (Figure 4A and B). More importantly, no serious bleeding occurred during



**Figure 3 Bone marrow cell examination and bone marrow biopsy.** A: Bone marrow cell examination (Magnification: 100 ×); B: Bone marrow biopsy (Magnification: 10 ×).



**Figure 4 Deep venous ultrasound of the right lower extremity.** A: Lower extremity vascular ultrasound: Extensive acute incomplete thrombosis in the right lower extremities; B: Lower extremity vascular ultrasound: Old thrombosis in the common and superficial femoral veins of the right lower limb.

the therapy.



## OUTCOME AND FOLLOW-UP

The PLT count of the patient was maintained at  $20\text{--}40 \times 10^9/\text{L}$  after 2 mo of treatment with eltrombopag. Then, the patient stopped taking eltrombopag and fondaparinux sodium and was switched to 5 mg/d rivaroxaban to prevent DVT. Currently, no swelling, pain or movement disorders are noted in the right lower limb. The latest vascular ultrasound revealed partial old thrombosis without new thrombosis.

## DISCUSSION

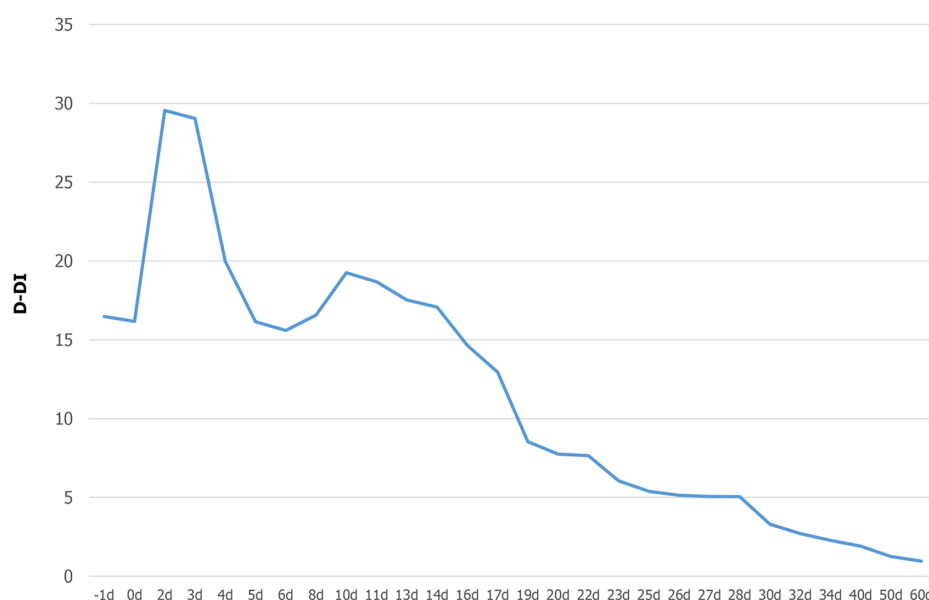
The contradictory process of coagulation and anticoagulation maintains normal physiological function. PLTs are pivotal in primary hemostasis and have nonhemostatic properties involved in angiogenesis, tissue repair, inflammation, and metastasis[6]. In most cases, patients suffering from hematological disease with low PLTs suffer from bleeding risk, and the aim to avoid bleeding is the normal strategy employed by clinical physicians to treat these patients[6]. However, we report a rare case of one MDS patient with severe thrombocytopenia and right lower limb DVT, and the patient was treated successfully with fondaparinux sodium and eltrombopag for the first time.

The patient, whose PLT count showed moderate to severe reductions, developed right lower limb DVT 1 mo after taking thalidomide and danazole. Low-dose thalidomide is an effective and safe treatment for patients with low- to intermediate-1-risk MDS, although it inhibits angiogenesis and has complex immunomodulatory effects[7]. However, in patients with multiple myeloma, receiving thalidomide in combination with multiagent chemotherapy and dexamethasone will significantly increase the risk of DVT[8,9]. Thalidomide may act as a procoagulant by significantly increasing the expression of phosphatidylserine and tissue factor and decreasing the expression of endothelial PC receptor, thrombomodulin and activated PC (APC) by a direct inhibitory effect when pretreated with multiple myeloma serum, thereby contributing to thrombogenesis[10]. Thalidomide-related thrombotic events are most common in the deep venous spindle of both limbs, followed by pulmonary embolism and superficial venous thrombosis[11–13]. Although there is not much evidence that danazol, a synthetic androgenic steroid, is related to thrombogenesis in humans, there are still some case reports of cerebral, coronary, and peripheral arterial thrombosis suggesting that danazol may be an independent risk factor for arterial thrombosis that may also contribute to this DVT[14]. In this patient, whole-exome sequencing detection revealed PS deficiency [*PROS1*+, c.1351C > T (p.Arg451)], which is a heterozygous mutation leading to thrombophilia[15]. The lack of PS, which is a nonenzyme cofactor of APC, reduces the ability of PC to inactivate coagulation factors Va and VIIIa, leading to thrombosis[16]. In addition, we should not overlook the fact that diabetes itself, as an individual risk factor for thromboembolic events, also contributes to the formation of thrombi. Therefore, we concluded that although the occurrence of DVT in this patient may be caused by a variety of factors, thalidomide-induced thrombophilia was the primary cause.

Severe thrombocytopenia with coexisting DVT in patients is quite challenging for physicians. The platelet count of the patient was severely reduced, and DVT continued to deplete the platelet count, which led to an increased risk of fatal bleeding and anticoagulant therapy[17]. The failure of interventional thrombectomy was exacerbated. To better balance bleeding and blood clots, fondaparinux sodium was first selected for anticoagulant therapy. Surprisingly, in this contradictory situation, fondaparinux sodium effectively alleviated the thrombus status, and the D-dimer gradually decreased without any unexpected bleeding (Figure 5). Binding to ATIII, a highly selective factor Xa (FXa) inhibitor, enhances the natural activity of ATIII against FXa, thereby effectively blocking the core steps of the clotting cascade and preventing the formation and development of thrombosis. Studies have shown that fondaparinux sodium is more effective and safer than other anticoagulant drugs when patients suffer from both thrombocytopenia and a high coagulation state. This is similar to the condition noted in this patient, although it was not induced by heparin[18,19]. Then, to increase platelet counts and reduce bleeding risk, we prescribed eltrombopag to promote the maturation and differentiation of megakaryocytes and increase the peripheral blood platelet count. Eltrombopag is an oral thrombopoietin receptor agonist indicated for the treatment of immune thrombocytopenia. Beyond the effect on megakaryopoiesis, the drug also showed a stimulating effect on hematopoietic stem cells with consistent clinical efficacy in aplastic anemia and MDS[20,21]. DVT is also an important rare adverse event for the long-term use of eltrombopag[22]. Thus, the patient discontinued eltrombopag once the platelet count reached the point that she did not need to rely on blood transfusion. In terms of the end result, we succeeded in breaking the patient's contradictory pathophysiological process with fondaparinux sodium and eltrombopag.

## CONCLUSION

This is the first report of the use of fondaparinux sodium and eltrombopag to successfully treat an MDS patient with severe thrombocytopenia and right lower limb DVT. In addition, no increased risk of



**Figure 5** The change in D-dimer during fondaparinux sodium therapy. D-DI: D-dimer.

bleeding was noted. Furthermore, clinicians should be aware of thrombotic problems in MDS patients taking thalidomide, especially patients with genetic backgrounds for thrombotic susceptibility.

## ACKNOWLEDGEMENTS

We thank the patient and the patient's family members for their support and cooperation.

## FOOTNOTES

**Author contributions:** Tong HX and Liu WB were involved in the medical treatment, designed the study, and wrote the article; Ma JX contributed to drafting and modifying the manuscript; all authors read and approved the final manuscript.

**Supported by** the Zhejiang Province Administration of Traditional Chinese Medicine, No. 2017ZB034 and No. 2020ZB096; the Zhejiang University of Traditional Chinese Medicine School-Level Fund, No. 2019ZG06; and the National Nonprofit Institute Research Grant for Institute of Basic Theory for Chinese Medicine, CACMS, No. YZ-202142.

**Informed consent statement:** Informed written consent was obtained from the patient for publication of this report and any accompanying images.

**Conflict-of-interest statement:** The authors declare that they have no conflict of interest.

**CARE Checklist (2016) statement:** The authors have read the CARE Checklist (2016), and the manuscript was prepared and revised according to the CARE Checklist (2016).

**Open-Access:** This article is an open-access article that was selected by an in-house editor and fully peer-reviewed by external reviewers. It is distributed in accordance with the Creative Commons Attribution NonCommercial (CC BY-NC 4.0) license, which permits others to distribute, remix, adapt, build upon this work non-commercially, and license their derivative works on different terms, provided the original work is properly cited and the use is non-commercial. See: <https://creativecommons.org/licenses/by-nc/4.0/>

**Country/Territory of origin:** China

**ORCID number:** Wen-Bin Liu 0000-0001-6837-9756; Jian-Xiong Ma 0000-0003-1088-9440; Hong-Xuan Tong 0000-0003-4788-1768.

**S-Editor:** Guo XR

**L-Editor:** A

P-Editor: Chen YX

## REFERENCES

- 1 **Patnaik MM**, Tefferi A. Myelodysplastic syndromes with ring sideroblasts (MDS-RS) and MDS/myeloproliferative neoplasm with RS and thrombocytosis (MDS/MPN-RS-T) - "2021 update on diagnosis, risk-stratification, and management". *Am J Hematol* 2021; **96**: 379-394 [PMID: [33428785](#) DOI: [10.1002/ajh.26090](#)]
- 2 **Badireddy M**, Mudipalli VR. Deep Venous Thrombosis Prophylaxis. StatPearls. Treasure Island (FL): StatPearls Publishing [DOI: [10.5772/31717](#)]
- 3 **Preston RJS**, O'Sullivan JM, O'Donnell JS. Advances in understanding the molecular mechanisms of venous thrombosis. *Br J Haematol* 2019; **186**: 13-23 [PMID: [30906986](#) DOI: [10.1111/bjh.15869](#)]
- 4 **Colucci G**, Tsakiris DA. Thrombophilia Screening: Universal, Selected, or Neither? *Clin Appl Thromb Hemost* 2017; **23**: 893-899 [PMID: [28049358](#) DOI: [10.1177/1076029616683803](#)]
- 5 **Basood M**, Oster HS, Mittelman M. Thrombocytopenia in Patients with Myelodysplastic Syndromes: Still an Unsolved Problem. *Mediterr J Hematol Infect Dis* 2018; **10**: e2018046 [PMID: [30002802](#) DOI: [10.4084/MJHID.2018.046](#)]
- 6 **Vinholt PJ**. The role of platelets in bleeding in patients with thrombocytopenia and hematological disease. *Clin Chem Lab Med* 2019; **57**: 1808-1817 [PMID: [31465290](#) DOI: [10.1515/ccbm-2019-0380](#)]
- 7 **Chung CY**, Lin SF, Chen PM, Chang MC, Kao WY, Chao TY, Hsiao LT, Yen CC, Yang MH, Hwang WS, Lin TL, Chiou TJ, Chang CS. Thalidomide for the treatment of myelodysplastic syndrome in Taiwan: results of a phase II trial. *Anticancer Res* 2012; **32**: 3415-3419 [PMID: [22843924](#)]
- 8 **Debbie Jiang MD**, Alfred Ian Lee MD. Thrombotic Risk from Chemotherapy and Other Cancer Therapies. *Cancer Treat Res* 2019; **179**: 87-101 [PMID: [31317482](#) DOI: [10.1007/978-3-030-20315-3\\_6](#)]
- 9 **Kahale LA**, Matar CF, Tzolakian I, Hakoum MB, Yosuco VE, Terrenato I, Sperati F, Barba M, Hicks LK, Schünemann H, Akl EA. Antithrombotic therapy for ambulatory patients with multiple myeloma receiving immunomodulatory agents. *Cochrane Database Syst Rev* 2021; **9**: CD014739 [PMID: [34582035](#) DOI: [10.1002/14651858.CD014739](#)]
- 10 **Gao Y**, Ma G, Liu S, Teng Y, Wang Y, Su Y. Thalidomide and multiple myeloma serum synergistically induce a hemostatic imbalance in endothelial cells in vitro. *Thromb Res* 2015; **135**: 1154-1159 [PMID: [25840743](#) DOI: [10.1016/j.thromres.2015.03.019](#)]
- 11 **Bujoreanu I**, Ferguson M, Saleh H. Chemotherapy associated dural sinus thrombosis presenting as a cerebrospinal fluid leak. *BMJ Case Rep* 2020; **13** [PMID: [32487533](#) DOI: [10.1136/bcr-2020-235240](#)]
- 12 **Ay C**, Beyer-Westendorf J, Pabinger I. Treatment of cancer-associated venous thromboembolism in the age of direct oral anticoagulants. *Ann Oncol* 2019; **30**: 897-907 [PMID: [30918939](#) DOI: [10.1093/annonc/mdz111](#)]
- 13 **Weitz IC**. Thrombotic microangiopathy in cancer. *Thromb Res* 2018; **164** Suppl 1: S103-S105 [PMID: [29703465](#) DOI: [10.1016/j.thromres.2018.01.014](#)]
- 14 **Alvarado RG**, Liu JY, Zwolak RM. Danazol and limb-threatening arterial thrombosis: two case reports. *J Vasc Surg* 2001; **34**: 1123-1126 [PMID: [11743571](#) DOI: [10.1067/mva.2001.118078](#)]
- 15 **Richards S**, Aziz N, Bale S, Bick D, Das S, Gastier-Foster J, Grody WW, Hegde M, Lyon E, Spector E, Voelkerding K, Rehm HL; ACMG Laboratory Quality Assurance Committee. Standards and guidelines for the interpretation of sequence variants: a joint consensus recommendation of the American College of Medical Genetics and Genomics and the Association for Molecular Pathology. *Genet Med* 2015; **17**: 405-424 [PMID: [25741868](#) DOI: [10.1038/gim.2015.30](#)]
- 16 **Iida H**, Nakahara M, Komori K, Fujise M, Wakiyama M, Urata M, Kinoshita S, Tsuda H, Sugimachi K, Hamasaki N. Failure in the detection of aberrant mRNA from the heterozygotic splice site mutant allele for protein S in a patient with protein S deficiency. *Thromb Res* 2001; **102**: 187-196 [PMID: [11369411](#) DOI: [10.1016/s0049-3848\(01\)00246-8](#)]
- 17 **Machin M**, Salim S, Tan M, Onida S, Davies AH, Shalhoub J. Surgical and non-surgical approaches in the management of lower limb post-thrombotic syndrome. *Expert Rev Cardiovasc Ther* 2021; **19**: 191-200 [PMID: [33455484](#) DOI: [10.1080/14779072.2021.1876563](#)]
- 18 **Schindewolf M**, Steindl J, Beyer-Westendorf J, Schellong S, Dohmen PM, Brachmann J, Madlener K, Pötzsch B, Klamroth R, Hankowitz J, Banik N, Eberle S, Müller MM, Kropff S, Lindhoff-Last E. Use of Fondaparinux Off-Label or Approved Anticoagulants for Management of Heparin-Induced Thrombocytopenia. *J Am Coll Cardiol* 2017; **70**: 2636-2648 [PMID: [29169470](#) DOI: [10.1016/j.jacc.2017.09.1099](#)]
- 19 **Mastroiacovo D**, Sala G, Dentali F. The safety of fondaparinux sodium for the treatment of venous thromboembolism. *Expert Opin Drug Saf* 2016; **15**: 1259-1265 [PMID: [27537418](#) DOI: [10.1080/14740338.2016.1221395](#)]
- 20 **Fattizzo B**, Levati G, Cassin R, Barcellini W. Eltrombopag in Immune Thrombocytopenia, Aplastic Anemia, and Myelodysplastic Syndrome: From Megakaryopoiesis to Immunomodulation. *Drugs* 2019; **79**: 1305-1319 [PMID: [31292909](#) DOI: [10.1007/s40265-019-01159-0](#)]
- 21 **Mittelman M**, Platzbecker U, Afanasyev B, Grosicki S, Wong RSM, Anagnostopoulos A, Brenner B, Denzlinger C, Rossi G, Nagler A, Garcia-Delgado R, Portella MSO, Zhu Z, Selleslag D. Eltrombopag for advanced myelodysplastic syndromes or acute myeloid leukaemia and severe thrombocytopenia (ASPIRE): a randomised, placebo-controlled, phase 2 trial. *Lancet Haematol* 2018; **5**: e34-e43 [PMID: [29241762](#) DOI: [10.1016/S2352-3026\(17\)30228-4](#)]
- 22 **Wong RSM**, Saleh MN, Khelif A, Salama A, Portella MSO, Burgess P, Bussell JB. Safety and efficacy of long-term treatment of chronic/persistent ITP with eltrombopag: final results of the EXTEND study. *Blood* 2017; **130**: 2527-2536 [PMID: [29042367](#) DOI: [10.1182/blood-2017-04-748707](#)]



Published by **Baishideng Publishing Group Inc**  
7041 Koll Center Parkway, Suite 160, Pleasanton, CA 94566, USA

**Telephone:** +1-925-3991568

**E-mail:** [bpgoffice@wjgnet.com](mailto:bpgoffice@wjgnet.com)

**Help Desk:** <https://www.f6publishing.com/helpdesk>

<https://www.wjgnet.com>

