


# World Journal of *Clinical Cases*

*World J Clin Cases* 2022 April 16; 10(11): 3321-3638



**REVIEW**

- 3321 Encouraging specific biomarkers-based therapeutic strategies for hepatocellular carcinoma  
*Yao M, Yang JL, Wang DF, Wang L, Chen Y, Yao DF*

**ORIGINAL ARTICLE****Clinical and Translational Research**

- 3334 Autophagy-related long non-coding RNA prognostic model predicts prognosis and survival of melanoma patients  
*Qiu Y, Wang HT, Zheng XF, Huang X, Meng JZ, Huang JP, Wen ZP, Yao J*
- 3352 Identification of circ\_0000375 and circ\_0011536 as novel diagnostic biomarkers of colorectal cancer  
*Yin TF, Du SY, Zhao DY, Sun XZ, Zhou YC, Wang QQ, Zhou GYJ, Yao SK*

**Retrospective Study**

- 3369 Echocardiography in the diagnosis of Shone's complex and analysis of the causes for missed diagnosis and misdiagnosis  
*Li YD, Meng H, Pang KJ, Li MZ, Xu N, Wang H, Li SJ, Yan J*
- 3379 Predictors and prognostic impact of post-operative atrial fibrillation in patients with hip fracture surgery  
*Bae SJ, Kwon CH, Kim TY, Chang H, Kim BS, Kim SH, Kim HJ*
- 3389 Added value of systemic inflammation markers for monitoring response to neoadjuvant chemotherapy in breast cancer patients  
*Ke ZR, Chen W, Li MX, Wu S, Jin LT, Wang TJ*
- 3401 Washed microbiota transplantation reduces serum uric acid levels in patients with hyperuricaemia  
*Cai JR, Chen XW, He YJ, Wu B, Zhang M, Wu LH*

**Clinical Trials Study**

- 3414 Concurrent chemoradiotherapy using gemcitabine and nedaplatin in recurrent or locally advanced head and neck squamous cell carcinoma  
*Huo RX, Jin YY, Zhuo YX, Ji XT, Cui Y, Wu XJ, Wang YJ, Zhang L, Zhang WH, Cai YM, Zheng CC, Cui RX, Wang QY, Sun Z, Wang FW*

**META-ANALYSIS**

- 3426 Effect of enhanced recovery after surgery on inflammatory bowel disease surgery: A meta-analysis  
*Peng D, Cheng YX, Tao W, Tang H, Ji GY*
- 3436 Accuracy of ultrasound elastography for predicting breast cancer response to neoadjuvant chemotherapy: A systematic review and meta-analysis  
*Chen W, Fang LX, Chen HL, Zheng JH*

- 3449** Association of chronic obstructive pulmonary disease with mild cognitive impairment and dementia risk: A systematic review and meta-analysis

Zhao LY, Zhou XL

### CASE REPORT

- 3461** Circulating tumor DNA genomic profiling reveals the complicated olaparib-resistance mechanism in prostate cancer salvage therapy: A case report

Yuan F, Liu N, Yang MZ, Zhang XT, Luo H, Zhou H

- 3472** Difference and similarity between type A interrupted aortic arch and aortic coarctation in adults: Two case reports

Ren SX, Zhang Q, Li PP, Wang XD

- 3478** Combination therapy (toripalimab and lenvatinib)-associated toxic epidermal necrolysis in a patient with metastatic liver cancer: A case report

Huang KK, Han SS, He LY, Yang LL, Liang BY, Zhen QY, Zhu ZB, Zhang CY, Li HY, Lin Y

- 3485** Unusual glomus tumor of the lower leg: A case report

Wang HY, Duan P, Chen H, Pan ZY

- 3490** Pulmonary *Cladosporium* infection coexisting with subcutaneous *Corynespora cassiicola* infection in a patient: A case report

Wang WY, Luo HB, Hu JQ, Hong HH

- 3496** Preoperational diagnosis and management of breast ductal carcinoma *in situ* arising within fibroadenoma: Two case reports

Wu J, Sun KW, Mo QP, Yang ZR, Chen Y, Zhong MC

- 3505** Reconstruction of complex chest wall defects: A case report

Huang SC, Chen CY, Qiu P, Yan ZM, Chen WZ, Liang ZZ, Luo KW, Li JW, Zhang YQ, Huang BY

- 3511** Young children with multidrug-resistant epilepsy and vagus nerve stimulation responding to perampanel: A case report

Yang H, Yu D

- 3518** Intramedullary nailing for pathological fractures of the proximal humerus caused by multiple myeloma: A case report and review of literature

Xu GQ, Wang G, Bai XD, Wang XJ

- 3527** Double tracheal stents reduce side effects of progression of malignant tracheoesophageal fistula treated with immunotherapy: A case report

Li CA, Yu WX, Wang LY, Zou H, Ban CJ, Wang HW

- 3533** Ankylosing spondylitis complicated with andersson lesion in the lower cervical spine: A case report

Peng YJ, Zhou Z, Wang QL, Liu XF, Yan J

- 3541** Severe gastric insufflation and consequent atelectasis caused by gas leakage using AIR-Q laryngeal mask airway: A case report

Zhao Y, Li P, Li DW, Zhao GF, Li XY

- 3547** Hypereosinophilic syndrome presenting as acute ischemic stroke, myocardial infarction, and arterial involvement: A case report  
*Sun RR, Chen TZ, Meng M*
- 3553** Cytochrome P450 family 17 subfamily A member 1 mutation causes severe pseudohermaphroditism: A case report  
*Gong Y, Qin F, Li WJ, Li LY, He P, Zhou XJ*
- 3561** Patellar dislocation following distal femoral replacement after extra-articular knee resection for bone sarcoma: A case report  
*Kubota Y, Tanaka K, Hirakawa M, Iwasaki T, Kawano M, Itonaga I, Tsumura H*
- 3573** Qingchang decoction retention enema may induce clinical and mucosal remission in left-sided ulcerative colitis: A case report  
*Li PH, Tang Y, Wen HZ*
- 3579** Anti-nuclear matrix protein 2+ juvenile dermatomyositis with severe skin ulcer and infection: A case report and literature review  
*Wang YT, Zhang Y, Tang T, Luo C, Liu MY, Xu L, Wang L, Tang XM*
- 3587** Ultrasound-guided local ethanol injection for fertility-preserving cervical pregnancy accompanied by fetal heartbeat: Two case reports  
*Kakinuma T, Kakinuma K, Matsuda Y, Ohwada M, Yanagida K, Kaijima H*
- 3593** Successful apatinib treatment for advanced clear cell renal carcinoma as a first-line palliative treatment: A case report  
*Wei HP, Mao J, Hu ZL*
- 3601** Del(5q) and inv(3) in myelodysplastic syndrome: A rare case report  
*Liang HP, Luo XC, Zhang YL, Liu B*
- 3609** Papillary thyroid microcarcinoma with contralateral lymphatic skip metastasis and breast cancer: A case report  
*Ding M, Kong YH, Gu JH, Xie RL, Fei J*
- 3615** Contrast-enhanced ultrasound manifestations of synchronous combined hepatocellular-cholangiocarcinoma and hepatocellular carcinoma: A case report  
*Gao L, Huang JY, Lu ZJ, Lu Q*
- 3624** Thyrotoxicosis after a massive levothyroxine ingestion: A case report  
*Du F, Liu SW, Yang H, Duan RX, Ren WX*
- 3630** Pleomorphic adenoma of the left lacrimal gland recurred and transformed into myoepithelial carcinoma after multiple operations: A case report  
*Huang WP, Li LM, Gao JB*

**ABOUT COVER**

Editorial Board Member of *World Journal of Clinical Cases*, Chi-Yuan Yeh, MD, PhD, Assistant Professor, Chief Doctor, radiation oncology, Tungs' Taichung MetroHarbor Hospital, Taichung 43503, Taiwan.  
peteryeh46@gmail.com

**AIMS AND SCOPE**

The primary aim of *World Journal of Clinical Cases* (WJCC, *World J Clin Cases*) is to provide scholars and readers from various fields of clinical medicine with a platform to publish high-quality clinical research articles and communicate their research findings online.

WJCC mainly publishes articles reporting research results and findings obtained in the field of clinical medicine and covering a wide range of topics, including case control studies, retrospective cohort studies, retrospective studies, clinical trials studies, observational studies, prospective studies, randomized controlled trials, randomized clinical trials, systematic reviews, meta-analysis, and case reports.

**INDEXING/ABSTRACTING**

The WJCC is now indexed in Science Citation Index Expanded (also known as SciSearch®), Journal Citation Reports/Science Edition, Scopus, PubMed, and PubMed Central. The 2021 Edition of Journal Citation Reports® cites the 2020 impact factor (IF) for WJCC as 1.337; IF without journal self cites: 1.301; 5-year IF: 1.742; Journal Citation Indicator: 0.33; Ranking: 119 among 169 journals in medicine, general and internal; and Quartile category: Q3. The WJCC's CiteScore for 2020 is 0.8 and Scopus CiteScore rank 2020: General Medicine is 493/793.

**RESPONSIBLE EDITORS FOR THIS ISSUE**

Production Editor: Hua-Ge Yin; Production Department Director: Xiang Li; Editorial Office Director: Jin-Lai Wang.

**NAME OF JOURNAL**

*World Journal of Clinical Cases*

**ISSN**

ISSN 2307-8960 (online)

**LAUNCH DATE**

April 16, 2013

**FREQUENCY**

Thrice Monthly

**EDITORS-IN-CHIEF**

Bao-Gan Peng, Jerzy Tadeusz Chudek, George Kontogeorgos, Maurizio Serati, Ja Hyeon Ku

**EDITORIAL BOARD MEMBERS**

<https://www.wjgnet.com/2307-8960/editorialboard.htm>

**PUBLICATION DATE**

April 16, 2022

**COPYRIGHT**

© 2022 Baishideng Publishing Group Inc

**INSTRUCTIONS TO AUTHORS**

<https://www.wjgnet.com/bpg/gerinfo/204>

**GUIDELINES FOR ETHICS DOCUMENTS**

<https://www.wjgnet.com/bpg/GerInfo/287>

**GUIDELINES FOR NON-NATIVE SPEAKERS OF ENGLISH**

<https://www.wjgnet.com/bpg/gerinfo/240>

**PUBLICATION ETHICS**

<https://www.wjgnet.com/bpg/GerInfo/288>

**PUBLICATION MISCONDUCT**

<https://www.wjgnet.com/bpg/gerinfo/208>

**ARTICLE PROCESSING CHARGE**

<https://www.wjgnet.com/bpg/gerinfo/242>

**STEPS FOR SUBMITTING MANUSCRIPTS**

<https://www.wjgnet.com/bpg/GerInfo/239>

**ONLINE SUBMISSION**

<https://www.f6publishing.com>





## Anti-nuclear matrix protein 2+ juvenile dermatomyositis with severe skin ulcer and infection: A case report and literature review

Ya-Ting Wang, Yu Zhang, Tao Tang, Chong Luo, Ming-Yue Liu, Li Xu, Li Wang, Xue-Mei Tang

**Specialty type:** Pediatrics

**Provenance and peer review:**

Unsolicited manuscript; Externally peer reviewed.

**Peer-review model:** Single blind

**Peer-review report's scientific quality classification**

Grade A (Excellent): 0  
Grade B (Very good): 0  
Grade C (Good): C, C  
Grade D (Fair): 0  
Grade E (Poor): 0

**P-Reviewer:** Poddighe D, Kazakhstan; Wang CR, Taiwan

**Received:** December 7, 2021

**Peer-review started:** December 7, 2021

**First decision:** January 25, 2022

**Revised:** February 7, 2022

**Accepted:** February 27, 2022

**Article in press:** February 27, 2022

**Published online:** April 16, 2022



Ya-Ting Wang, Yu Zhang, Tao Tang, Chong Luo, Ming-Yue Liu, Li Xu, Li Wang, Xue-Mei Tang, Department of Rheumatology and Immunology; Ministry of Education Key Laboratory of Child Development and Disorders; National Clinical Research Center for Child Health and Disorders (Chongqing); China International Science and Technology Cooperation base of Child Development and Critical Disorders; Children's Hospital of Chongqing Medical University, Chongqing 400014, China

Ya-Ting Wang, Yu Zhang, Tao Tang, Chong Luo, Ming-Yue Liu, Li Xu, Li Wang, Xue-Mei Tang, Chongqing Key Laboratory of Child Infection and Immunity, Children's Hospital of Chongqing Medical University, Chongqing 400014, China

**Corresponding author:** Xue-Mei Tang, PhD, Chief Doctor, Department of Rheumatology and Immunology; Ministry of Education Key Laboratory of Child Development and Disorders; National Clinical Research Center for Child Health and Disorders (Chongqing); China International Science and Technology Cooperation base of Child Development and Critical Disorders; Children's Hospital of Chongqing Medical University, No. 136 Zhongshan 2<sup>nd</sup> Road, Yuzhong District, Chongqing 400014, China. [tangxuemei2008@163.com](mailto:tangxuemei2008@163.com)

### Abstract

#### BACKGROUND

Juvenile dermatomyositis (JDM) is an idiopathic inflammatory myopathy that occurs in childhood. It is characterized by muscle weakness and a characteristic rash. Previous literature reports have rarely described JDM with severe skin ulcers and infections.

#### CASE SUMMARY

Herein, we describe a case of a 2-year-old female patient who suffered from JDM, whose myositis-specific autoantibodies were positive for anti-nuclear matrix protein 2 antibody, with progressively worsening skin ulcers and severe infections. The patient was treated with glucocorticoids and various immunosuppressants. Nevertheless, further progression of the disease and the combination of primary disease and severe infection in the later period were fatal.

#### CONCLUSION

In children, anti-nuclear matrix protein 2+ JDM combined with skin ulcers often indicates severe disease. In such cases, personalized treatment for the primary disease and infection prevention and control are essential.

**Key Words:** Juvenile dermatomyositis; Skin ulcer; Anti-nuclear matrix protein 2 antibody; Case report

©The Author(s) 2022. Published by Baishideng Publishing Group Inc. All rights reserved.

**Core Tip:** Juvenile dermatomyositis (JDM) is a rare systemic autoimmune disease characterized by specific skin lesions, chronic muscle inflammation, and systemic vasculitis. We report a very rare case of JDM with severe skin ulcers and infections. By reporting the disease development and treatment of this case of a patient positive for anti-nuclear matrix protein 2 (NXP2) antibody combined with skin ulcers and performing a comprehensive literature review, we summarize JDM with skin ulcers, the clinical characteristics of JDM combined with positivity for anti-NXP2 antibody, and treatment measures for severe JDM.

**Citation:** Wang YT, Zhang Y, Tang T, Luo C, Liu MY, Xu L, Wang L, Tang XM. Anti-nuclear matrix protein 2+ juvenile dermatomyositis with severe skin ulcer and infection: A case report and literature review. *World J Clin Cases* 2022; 10(11): 3579-3586

**URL:** <https://www.wjgnet.com/2307-8960/full/v10/i11/3579.htm>

**DOI:** <https://dx.doi.org/10.12998/wjcc.v10.i11.3579>

## INTRODUCTION

Juvenile dermatomyositis (JDM) is a rare systemic autoimmune disease characterized by vascular disease that mainly affects muscles and skin, as well as the lungs, intestines, heart, and other organs[1-3]. JDM can also lead to macrophage activation syndrome, which is a potentially fatal complication of a number of rheumatological conditions[4]. JDM is the most common inflammatory myopathy in children and has been reported to affect 1.9 individuals per million children in the United Kingdom and 2.4-4.1 individuals per million children in the United States[5,6]. Skin ulcers are one of the severe manifestations of childhood dermatomyositis; however, cases of severe skin ulcers with infections are rarely reported. Here, we report a single case of a 2-year-old female patient who suffered from JDM and whose myositis-specific autoantibodies (MSAs) were positive for anti-nuclear matrix protein 2 antibody, with progressively worsening skin ulcers and severe infections.

## CASE PRESENTATION

### Chief complaints

A 2-year-old Chinese girl came to the Department of Rheumatology and Immunology with a heliotrope rash for 1 mo and muscle weakness for 10 d.

### History of present illness

This patient developed a heliotrope rash, periorbital edema, and nailfold capillary changes within 1 mo, with symmetric proximal muscle weakness. There was no fever, cough, hoarseness, or sensory disturbance.

### History of past illness

The patient had no significant medical or surgical history.

### Personal and family history

The child was born at full term. Her parents and other family members had no family history of autoimmune or other diseases.

### Physical examination

After admission, the patient's weight was 14 kg. There were heliotrope rashes on her face, periorbital edema, changes in nailfold capillaries, Gottron papules on the dorsal surface of the proximal interdigital (PIP), symmetric proximal muscle weakness of arms and legs, no erythema butterfly, and arthritis.

### Laboratory examinations

Investigations revealed elevated creatine kinase of 12647 U/L (reference range, 50-220 U/L), lactate dehydrogenase (LDH) of 1358 U/L (reference range, 80-300 U/L), erythrocyte sedimentation rate (ESR) of 79 mm/h (reference range, 0-20 mm/h), and ferritin of 726 ng/mL (reference range, 10-120 ng/mL).

The autoantibody, immunoglobulin, and complement profiles were normal. Anti-nuclear matrix protein 2 (NXP-2) antibody was positive in the myositis spectrum, as determined by the dot-ELISA method, and no other myositis-associated autoantibodies were present (Table 1).

### Imaging examinations

Magnetic resonance imaging (MRI) of the bilateral thighs revealed inflammatory changes in the musculature and subcutaneous fat layer of the thigh muscles on both sides, which were also characteristic of dermatomyositis. Electromyography (EMG) showed that the motor unit potential amplitude of the tibialis anterior and rectus femoris muscle was reduced, and the duration was shortened, thus suggesting myogenic abnormalities.

## FINAL DIAGNOSIS

Characteristic skin lesions, proximal muscle weakness, elevated serum muscle enzyme levels, EMG myopathic abnormalities, and changes in muscle MRI findings confirmed the diagnosis of juvenile dermatomyositis.

## TREATMENT

When the patient was diagnosed with anti-nuclear matrix protein 2 (NXP2)+ juvenile dermatomyositis, she initially received intravenous immunoglobulin (IVIG; 1 g/kg) for 2 d and high-dose glucocorticoids (GC; 15 mg/kg) for 3 d, after which she was treated with oral methylprednisolone (1.15 mg/kg·d), intravenous cyclophosphamide (IV CYC; 0.1 g/kg) for 2 d, methotrexate (MTX; 7.5 mg qw), hydroxychloroquine (0.05 g qd), and other symptomatic and supportive treatment. Following these treatments, the child's rash and edema basically disappeared, and her muscle strength improved.

In the following 8 mo, the girl was hospitalized 9 times, and she received IVIG 9 times (1 g/kg for 2 d each time) and IV CYC 6 times, replacing MTX and hydroxychloroquine with mycophenolate mofetil (MMF) and thalidomide. From the 4th month of the illness, she was treated with tofacitinib (2.5 mg bid). In the first three months after diagnosis, the child developed livedo reticularis on the skin of the extremities (Figure 1A) and ulcers on the buttock and left upper arm, while the ulcerated surfaces gradually increased. In the 6th month, yellow necrotic fascia was visible on the left buttock (Figure 1B). After she received proper wound care, anti-infection, and adjustment of immunosuppressants, the ulcers improved (in the 8th month), showing gradual scabbing. Nonetheless, her mother discontinued the patient's hospitalization. One month later, the patient suffered fatigue, anorexia, and multiple ulcers on the whole body again, which were worse than before. She never showed calcinosis during the whole course of the disease. After rehospitalization, she was given tocilizumab (12 mg/kg). However, when she received 20% of the infusion, the patient developed irritability, and her heart rate increased; thus, the administration of tocilizumab was stopped.

In the 10th month after diagnosis, the child was hospitalized for the last time because of bloody stools, fever, anorexia, listlessness, and multiple painful skin ulcers throughout the whole body (Figure 1C and D). The patient could not move on the bed by herself because of low muscle strength. Laboratory examinations revealed CK of 289 U/L, LDH of 689 U/L, and ESR of 92 mm/hr. Skin tissue biopsy of the left upper arm and left neck suggested epidermal necrosis, hyperplasia of subepidermal fibers and fatty tissues, visible vitreous and mucous changes, multifocal necrosis of the subepidermis and dermis, and focal chronic inflammatory cell infiltration. We used ceftazidime to fight infections and added vancomycin after 2 d. Pathogen detection in the pus from the buttock suggested *Escherichia coli*. Accordingly, the antibiotics were adjusted to vancomycin and meropenem; however, the ulcers further deepened (Figure 2A and B). After 9 d, re-examination of the culture revealed *Pseudomonas aeruginosa* and *Staphylococcus epidermidis*. Based on susceptibility testing, the antibiotics were changed to amikacin and ciprofloxacin. Other treatments included adjusting oral methylprednisolone at 6 mg qd (0.5 mg/kg·d) to intravenous methylprednisolone at 10 mg bid (2 mg/kg·d). During this period, the systemic dressing was changed at least 3 times per week, while IVIG, human albumin, component blood transfusion, and other symptomatic and supportive treatments were intermittently given.

## OUTCOME AND FOLLOW-UP

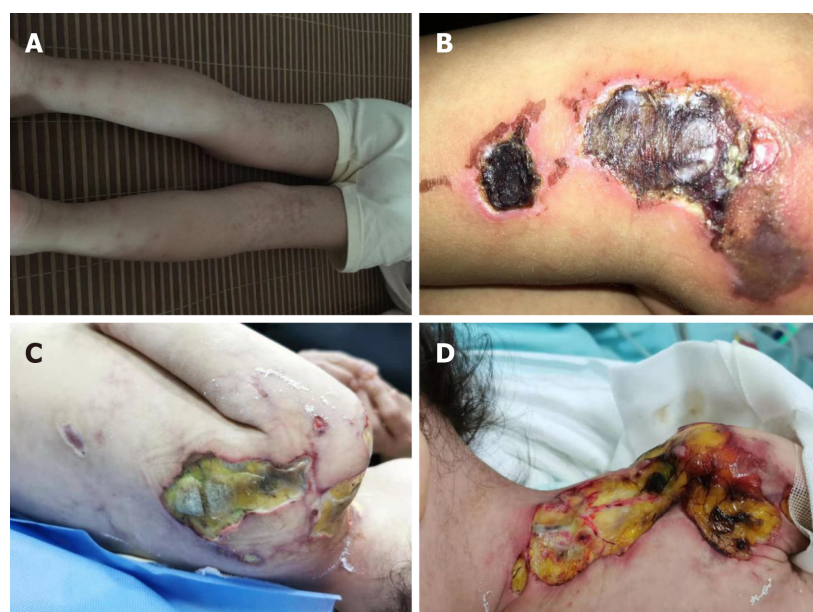On the 48th day after admission, gastrointestinal bleeding and shock occurred, after which the girl was transferred to the ICU. She was discharged 6 d later and died a few days after leaving the hospital.



**Table 1 Laboratory examinations at the first hospital admission**

Laboratory examinations	
CBC	WBC: $6.71 \times 10^9/L$ , PLT: $165 \times 10^9/L$ , L: 0.37, N: 0.54, Hb: 120 g/L, CRP < 8 mg/L
Biochemical examination	CK: 12647 U/L, LDH: 1358 U/L, ALT: 116.6 U/L, AST: 359.5 U/L
ESR	79 mm/h
Ferritin	726 ng/mL
Autoantibody profile	Negative
Immunoglobulins	Normal
Complements	Normal
MSA	Anti-nuclear matrix protein 2 antibody positive

ALT: Alanine aminotransferase; AST: Aspartate transaminase; CBC: Complete blood count; CK: Creatine kinase; ESR: Erythrocyte sedimentation rate; LDH: Lactate dehydrogenase; MSA: Myositis-specific autoantibody.



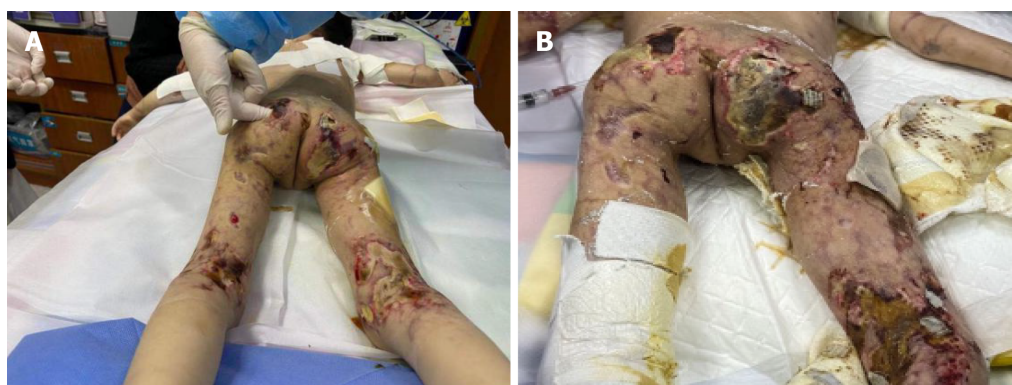DOI: 10.12998/wjcc.v10.i11.3579 Copyright © The Author(s) 2022.

**Figure 1** Clinical examination 3, 6, and 10 mo after diagnosis. A: 3 mo, livedo reticularis; B: 6 mo, ulcers in the buttock; C and D: 10 mo, ulcers in the back (C) and left (D) shoulder.

## DISCUSSION

JDM is a rheumatic disease that occurs in childhood, with a mortality rate reaching approximately < 4%, which is second only to systemic lupus erythematosus[7,8]. With early treatment, 30%-50% of patients are likely to achieve remission within 2-3 years from the onset of the disease. In addition to the characteristic skin lesions, other criteria include symmetric proximal muscle weakness, elevated serum muscle enzyme levels, myopathic changes on electromyogram, and typical muscle biopsy results[9].

An ulcer is one of the most serious skin manifestations of JDM and is widely regarded as an indication for more intensive treatment[10]. In different cohorts, the incidence of JDM skin ulcers has been reported to range from 2.6%-23%[7,11,12]. Rare cases have shown such severe skin ulceration with multiple pathogenic infections. Cutaneous ulceration may occur on any soft tissue in JDM, especially the armpits, elbows, or pressure points. Although rare, gluteal ulcers are more likely to worsen due to irritation caused by stool, urine, friction, and maceration, especially in infants and young children[13]. In our case, the child's gluteal ulcer had a protracted condition that gradually expanded and deepened and was accompanied by refractory bacterial infection. Infection and JDM promote each other, which increases the difficulty of treatment and leads to prolonged and unhealed ulcers. A case of JDM in an infant with gluteal ulcer has been reported in Japan. After treatment with high-dose glucocorticoids with cyclophosphamide and MTX, the ulcer gradually healed[13]; however, this case was not



DOI: 10.12998/wjcc.v10.i11.3579 Copyright © The Author(s) 2022.

**Figure 2** Deepening of the ulcers after treatment (A and B).

accompanied by serious infection. To prevent infection and promote ulcer healing, topical treatments and routine care for skin ulcers are necessary. In 2020, guidelines for skin ulcers related to connective tissue diseases were published in Japan, which in detail described systemic and local medication, nursing, and other treatment methods for skin ulcers and for different connective tissue diseases[14].

Persistent progression of skin ulcers has also been associated with neglected assessment of skin manifestations and severity of JDM. An expert group recommends that the follow-up of patients with JDM should focus more on the evaluation of the skin, including the use of multiple scales[8]. The Cutaneous Dermatomyositis Disease Activity and Severity Index (CDASI) and the Cutaneous Assessment Tool (CAT) have good interrater reliability and correlation with other measures of activity and damage in children with JDM[15]. The child in our case had prominent skin damage in the later stage. Early assessment of skin may help with follow-up treatment. Additional assessment tools can be used in clinical practice to more comprehensively assess disease activity[16].

In recent years, JDM combined with different MSAs has received extensive clinical attention. Different MSAs have been associated with different clinical phenotypes, prognoses, and risks of associated malignancy. In United States and European cohorts, MSAs were reported to be present in approximately 70% of JDM cases[17,18].

NXP2 is a protein involved in transcription and RNA metabolism regulation[19]. The autoantibody was first identified in 1997 in childhood myositis and was considered a key biomarker for the diagnosis of idiopathic inflammatory myopathy[20]. Clinically, anti-NXP2+ JDM often manifests as obvious skin rash, muscle weakness, dysphagia, calcinosis, limb edema, younger age of onset and less remission at 2 years[16]. The incidence of anti-NXP2+ JDM is 20%-25% among JDM cases, making anti-NXP2 a common type of antibody[19]. Two different studies in China have revealed detection rates of anti-NXP2 antibodies in JDM of 30.6% and 20%[21,22]. Albayda *et al*[23] found that NXP2+ dermatomyositis with limb weakness and neck muscle weakness were more serious than NXP2- dermatomyositis; accordingly, as our patient showed severe weakness. Another feature of NXP2+ JDM is calcinosis, although this was not present in our case. Early diagnosis and treatment of JDM can prevent the occurrence of calcinosis[24]. As there is no definitive treatment for severe calcinosis, surgical treatment is often necessary; however, there is still the possibility of recurrence[25]. Although most NXP2+ JDM patients are sensitive to GC, some patients are prone to severe and refractory JDM manifestations.

Immediately after the diagnosis of JDM was made, we treated this patient with corticosteroids and immunosuppressants. Systemic corticosteroids are the gold-standard initial treatment for JDM. However, they should not be used as monotherapy because this approach is frequently ineffective and associated with the development of unacceptable long-term adverse effects[26]. Immunosuppressants have steroid protection and are recommended even for mild cases to minimize the adverse effects of long-term GC treatment. Treatments used for refractory disease include IVIG, cyclophosphamide, cyclosporine, azathioprine, MMF, hydroxychloroquine, tacrolimus, rituximab, infliximab, and autologous stem cell transplantation[8]. Some studies suggest that treatment with GC and cyclophosphamide combined with calcineurin inhibitors is very important for dermatomyositis patients with skin ulcers or other severe manifestations[27]. A JAK-inhibitor (JAKi) can be used to treat JDM and has been reported to be partially effective for interstitial lung disease and cutaneous dermatomyositis[28,29]. However, in the present case, a JAKi did not stop the progression of the disease. For NXP2+ JDM and severe JDM, many studies have reported a favorable therapeutic effect of rituximab[19,30], which can reduce disease activity and reduce GC use. Additionally, rituximab can ameliorate the skin symptoms of refractory JDM and is effective for skin ulcers of JDM[19]. However, because the skin ulcers in this case were accompanied by severe infection, we were worried that the use of rituximab would further aggravate the infection, so it was not used. We tried tocilizumab, but the patient could not tolerate it. Plasmapheresis can be considered for the treatment of cases refractory to immunosuppressants[8].

For JDM-related skin ulcers, steroids and immunosuppressants should be first used to control the primary disease. However, if skin ulcers are complicated by infections, this type of treatment may exacerbate the ulcers due to the increased susceptibility of the patient to infection[14]. Therefore, in such cases, it is necessary to treat the primary disease and the infection simultaneously. According to the pathogenic examination and drug susceptibility results of the site of infection, appropriate antibacterial drugs were chosen, and the use of IVIG was considered. Due to the refractory nature of cutaneous vasculitis in JDM, case studies suggest that nifedipine, sildenafil, intravenous prostaglandins, and bosentan should be added as early adjuncts[26,31].

In the present case, after high-dose GC treatment, IVIG, MTX, MMF, hydroxychloroquine, a JAKi, thalidomide, and tocilizumab were given to the patient, and improvement was observed; however, the disease was not completely prevented. Further progression of the disease and the combination of primary disease and severe infection in the later period were fatal. It remains unknown whether the early use of vasodilatory agents and rituximab or plasmapheresis at the proper time could save patients' lives, which future studies should address.

## CONCLUSION

Only scarce reports of JDM with severe ulcers accompanied by infection have been reported. Skin ulcer-complicated and anti-NXP2+ JDM usually represent severe cases, and it is important to actively prevent the occurrence of infection while GC and appropriate immunosuppressive therapy are used. According to the different clinical manifestations and immunological indicators of JDM patients, appropriate assessment tools should be used to comprehensively assess the condition of JDM patients at an early stage, and individualized treatment plans should be customized.

## FOOTNOTES

**Author contributions:** Tang XM conceived and designed the study and revised the manuscript; Wang YT collected medical records and wrote the manuscript; Zhang Y collected medical records and participated in its design; Tang T collected medical records and provided pictures; Luo C participated in study design and coordination; Liu MY, Xu L, and Wang L collected and organized the literature; All authors read and approved the final manuscript.

**Informed consent statement:** All study participants, or their legal guardian, provided informed written consent prior to study enrollment.

**Conflict-of-interest statement:** The authors declare that they have no conflict of interest.

**CARE Checklist (2016) statement:** The authors have read the CARE Checklist (2016), and the manuscript was prepared and revised according to the CARE Checklist (2016).

**Open-Access:** This article is an open-access article that was selected by an in-house editor and fully peer-reviewed by external reviewers. It is distributed in accordance with the Creative Commons Attribution NonCommercial (CC BY-NC 4.0) license, which permits others to distribute, remix, adapt, build upon this work non-commercially, and license their derivative works on different terms, provided the original work is properly cited and the use is non-commercial. See: <https://creativecommons.org/licenses/by-nc/4.0/>

**Country/Territory of origin:** China

**ORCID number:** Ya-Ting Wang 0000-0003-3498-6181; Yu Zhang 0000-0003-1124-6543; Tao Tang 0000-0002-6467-0922; Chong Luo 0000-0002-7271-3064; Ming-Yue Liu 0000-0002-1934-778X; Li Xu 0000-0002-7288-1607; Li Wang 0000-0003-4663-102X; Xue-Mei Tang 0000-0002-6658-8084.

**S-Editor:** Gong ZM

**L-Editor:** A

**P-Editor:** Gong ZM

## REFERENCES

- 1 **Rider LG**, Lidsley CB, Miller FW. Juvenile dermatomyositis. In: Petty RE, Laxer RM, Lindsey CB, Wedderburn LR, editors. Textbook of pediatric rheumatology, 7th ed. Philadelphia: Elsevier Saunders; 2016: 351-384
- 2 **Feldman BM**, Rider LG, Reed AM, Pachman LM. Juvenile dermatomyositis and other idiopathic inflammatory myopathies of childhood. *Lancet* 2008; **371**: 2201-2212 [PMID: 18586175 DOI: 10.1016/S0140-6736(08)60955-1]
- 3 **Varnier GC**, Pilkington CA, Wedderburn LR. Juvenile dermatomyositis: novel treatment approaches and outcomes. *Curr*



- Opin Rheumatol* 2018; **30**: 650-654 [PMID: 30124602 DOI: 10.1097/BOR.0000000000000538]
- 4 **Poddighe D**, Dauey K. Macrophage activation syndrome in juvenile dermatomyositis: a systematic review. *Rheumatol Int* 2020; **40**: 695-702 [PMID: 31529231 DOI: 10.1007/s00296-019-04442-1]
  - 5 **Mendez EP**, Lipton R, Ramsey-Goldman R, Roettcher P, Bowyer S, Dyer A, Pachman LM; NIAMS Juvenile DM Registry Physician Referral Group. US incidence of juvenile dermatomyositis, 1995-1998: results from the National Institute of Arthritis and Musculoskeletal and Skin Diseases Registry. *Arthritis Rheum* 2003; **49**: 300-305 [PMID: 12794783 DOI: 10.1002/art.11122]
  - 6 **Gowdie PJ**, Allen RC, Kornberg AJ, Akikusa JD. Clinical features and disease course of patients with juvenile dermatomyositis. *Int J Rheum Dis* 2013; **16**: 561-567 [PMID: 24164844 DOI: 10.1111/1756-185X.12107]
  - 7 **Mathiesen PR**, Zak M, Herlin T, Nielsen SM. Clinical features and outcome in a Danish cohort of juvenile dermatomyositis patients. *Clin Exp Rheumatol* 2010; **28**: 782-789 [PMID: 21029565]
  - 8 **Bellutti Enders F**, Bader-Meunier B, Baildam E, Constantin T, Dolezalova P, Feldman BM, Lahdenne P, Magnusson B, Nistala K, Ozen S, Pilkington C, Ravelli A, Russo R, Uziel Y, van Brussel M, van der Net J, Vastert S, Wedderburn LR, Wulffraat N, McCann LJ, van Royen-Kerkhof A. Consensus-based recommendations for the management of juvenile dermatomyositis. *Ann Rheum Dis* 2017; **76**: 329-340 [PMID: 27515057 DOI: 10.1136/annrheumdis-2016-209247]
  - 9 **Bohan A**, Peter JB. Polymyositis and dermatomyositis (first of two parts). *N Engl J Med* 1975; **292**: 344-347 [PMID: 1090839 DOI: 10.1056/NEJM197502132920706]
  - 10 **Martin N**, Krol P, Smith S, Beard L, Pilkington CA, Davidson J, Wedderburn LR; Juvenile Dermatomyositis Research Group (JDRG). Comparison of children with onset of juvenile dermatomyositis symptoms before or after their fifth birthday in a UK and Ireland juvenile dermatomyositis cohort study. *Arthritis Care Res (Hoboken)* 2012; **64**: 1665-1672 [PMID: 22674907 DOI: 10.1002/acr.21753]
  - 11 **Sun C**, Lee JH, Yang YH, Yu HH, Wang LC, Lin YT, Chiang BL. Juvenile dermatomyositis: a 20-year retrospective analysis of treatment and clinical outcomes. *Pediatr Neonatol* 2015; **56**: 31-39 [PMID: 24985888 DOI: 10.1016/j.pedneo.2014.02.006]
  - 12 **Sag E**, Demir S, Bilginer Y, Talim B, Haliloglu G, Topaloglu H, Ozen S. Clinical features, muscle biopsy scores, myositis specific antibody profiles and outcome in juvenile dermatomyositis. *Semin Arthritis Rheum* 2021; **51**: 95-100 [PMID: 33360233 DOI: 10.1016/j.semarthrit.2020.10.007]
  - 13 **Wakiguchi H**, Takei S, Imanaka H, Hiraki T, Higashi M, Yamatou T, Yamasaki Y, Kubota T, Kawano Y. Severe gluteal skin ulcers in an infant with juvenile dermatomyositis. *Eur J Dermatol* 2016; **26**: 192-193 [PMID: 26712099 DOI: 10.1684/ejd.2015.2701]
  - 14 **Fujimoto M**, Asai J, Asano Y, Ishii T, Iwata Y, Kawakami T, Koderia M, Abe M, Amano M, Ikegami R, Isei T, Isogai Z, Ito T, Inoue Y, Irisawa R, Ohtsuka M, Omoto Y, Kato H, Kadono T, Kaneko S, Kanoh H, Kawaguchi M, Kukino R, Kono T, Koga M, Sakai K, Sakurai E, Sarayama Y, Shintani Y, Tanioka M, Tanizaki H, Tsujita J, Doi N, Nakanishi T, Hashimoto A, Hasegawa M, Hayashi M, Hirotsaki K, Fujita H, Fujiwara H, Maekawa T, Matsuo K, Madokoro N, Motegi SI, Yatsushiro H, Yamasaki O, Yoshino Y, Pavoux AJL, Tachibana T, Ihn H; Japanese Dermatological Association Guidelines. Wound, pressure ulcer and burn guidelines - 4: Guidelines for the management of connective tissue disease/vasculitis-associated skin ulcers. *J Dermatol* 2020; **47**: 1071-1109 [PMID: 31960490 DOI: 10.1111/1346-8138.15186]
  - 15 **Tiao J**, Feng R, Berger EM, Brandsema JF, Coughlin CC, Khan N, Kichula EA, Lerman MA, Lvovich S, McMahon PJ, Rider LG, Rubin AI, Scalzi LV, Smith DM, Taxter AJ, Treat JR, Williams RP, Yum SW, Okawa J, Werth VP. Evaluation of the reliability of the Cutaneous Dermatomyositis Disease Area and Severity Index and the Cutaneous Assessment Tool-Binary Method in juvenile dermatomyositis among paediatric dermatologists, rheumatologists and neurologists. *Br J Dermatol* 2017; **177**: 1086-1092 [PMID: 28421601 DOI: 10.1111/bjd.15596]
  - 16 **Kim H**, Huber AM, Kim S. Updates on Juvenile Dermatomyositis from the Last Decade: Classification to Outcomes. *Rheum Dis Clin North Am* 2021; **47**: 669-690 [PMID: 34635298 DOI: 10.1016/j.rdc.2021.07.003]
  - 17 **Tansley SL**, Betteridge ZE, Gunawardena H, Jacques TS, Owens CM, Pilkington C, Arnold K, Yasin S, Moraitis E, Wedderburn LR, McHugh NJ; UK Juvenile Dermatomyositis Research Group. Anti-MDA5 autoantibodies in juvenile dermatomyositis identify a distinct clinical phenotype: a prospective cohort study. *Arthritis Res Ther* 2014; **16**: R138 [PMID: 24989778 DOI: 10.1186/ar4600]
  - 18 **Rider LG**, Nistala K. The juvenile idiopathic inflammatory myopathies: pathogenesis, clinical and autoantibody phenotypes, and outcomes. *J Intern Med* 2016; **280**: 24-38 [PMID: 27028907 DOI: 10.1111/joim.12444]
  - 19 **Aggarwal R**, Loganathan P, Koontz D, Qi Z, Reed AM, Oddis CV. Cutaneous improvement in refractory adult and juvenile dermatomyositis after treatment with rituximab. *Rheumatology (Oxford)* 2017; **56**: 247-254 [PMID: 27837048 DOI: 10.1093/rheumatology/kew396]
  - 20 **Oddis CV**, Fertig N, Goel A, Espada G, Confalone Gregorian M, Cocco JAM, Londino AV. Clinical and serological characterization of the anti-MJ antibody in childhood myositis. *Arthritis Rheum* 1997; **40**: S139
  - 21 **Wang X**, Ding Y, Zhou Z, Hou J, Xu Y, Li J. Clinical characteristics and poor predictors of anti-NXP2 antibody-associated Chinese JDM children. *Pediatr Rheumatol Online J* 2021; **19**: 6 [PMID: 33407621 DOI: 10.1186/s12969-020-00492-z]
  - 22 **Li DM**, Wang L, Liu MY, Xu L, Tang XM. [The analysis of clinical phenotypes and autoantibodies in juvenile dermatomyositis]. *Zhonghua Er Ke Za Zhi* 2020; **58**: 966-972 [PMID: 33256317 DOI: 10.3760/cma.j.cn112140-20200724-00751]
  - 23 **Albayda J**, Pinal-Fernandez I, Huang W, Parks C, Paik J, Casciola-Rosen L, Danoff SK, Johnson C, Christopher-Stine L, Mammen AL. Antinuclear Matrix Protein 2 Autoantibodies and Edema, Muscle Disease, and Malignancy Risk in Dermatomyositis Patients. *Arthritis Care Res (Hoboken)* 2017; **69**: 1771-1776 [PMID: 28085235 DOI: 10.1002/acr.23188]
  - 24 **Hoeltzel MF**, Oberle EJ, Robinson AB, Aggarwal A, Rider LG. The presentation, assessment, pathogenesis, and treatment of calcinosis in juvenile dermatomyositis. *Curr Rheumatol Rep* 2014; **16**: 467 [PMID: 25366934 DOI: 10.1007/s11926-014-0467-y]
  - 25 **Kobayashi I**, Akioka S, Kobayashi N, Iwata N, Takezaki S, Nakaseko H, Sato S, Nishida Y, Nozawa T, Yamasaki Y, Yamazaki K, Arai S, Nishino I, Mori M. Clinical practice guidance for juvenile dermatomyositis (JDM) 2018-Update. *Mod*

- Rheumatol* 2020; **30**: 411-423 [PMID: [31955618](#) DOI: [10.1080/14397595.2020.1718866](#)]
- 26 **Waldman R**, DeWane ME, Lu J. Dermatomyositis: Diagnosis and treatment. *J Am Acad Dermatol* 2020; **82**: 283-296 [PMID: [31279813](#) DOI: [10.1016/j.jaad.2019.05.105](#)]
- 27 **Ishigaki K**, Maruyama J, Hagino N, Murota A, Takizawa Y, Nakashima R, Mimori T, Setoguchi K. Skin ulcer is a predictive and prognostic factor of acute or subacute interstitial lung disease in dermatomyositis. *Rheumatol Int* 2013; **33**: 2381-2389 [PMID: [23553518](#) DOI: [10.1007/s00296-013-2735-y](#)]
- 28 **Kurasawa K**, Arai S, Namiki Y, Tanaka A, Takamura Y, Owada T, Arima M, Maezawa R. Tofacitinib for refractory interstitial lung diseases in anti-melanoma differentiation-associated 5 gene antibody-positive dermatomyositis. *Rheumatology (Oxford)* 2018; **57**: 2114-2119 [PMID: [30060040](#) DOI: [10.1093/rheumatology/key188](#)]
- 29 **Moghadam-Kia S**, Charlton D, Aggarwal R, Oddis CV. Management of refractory cutaneous dermatomyositis: potential role of Janus kinase inhibition with tofacitinib. *Rheumatology (Oxford)* 2019; **58**: 1011-1015 [PMID: [30608616](#) DOI: [10.1093/rheumatology/key366](#)]
- 30 **Oddis CV**, Reed AM, Aggarwal R, Rider LG, Ascherman DP, Levesque MC, Barohn RJ, Feldman BM, Harris-Love MO, Koontz DC, Fertig N, Kelley SS, Pryber SL, Miller FW, Rockette HE; RIM Study Group. Rituximab in the treatment of refractory adult and juvenile dermatomyositis and adult polymyositis: a randomized, placebo-phase trial. *Arthritis Rheum* 2013; **65**: 314-324 [PMID: [23124935](#) DOI: [10.1002/art.37754](#)]
- 31 **Combalia A**, Giavedoni P, Tamez L, Grau-Junyent JM, Mascaró JM Jr. Bosentan for Cutaneous Ulcers in Anti-MDA5 Dermatomyositis. *JAMA Dermatol* 2018; **154**: 371-373 [PMID: [29344607](#) DOI: [10.1001/jamadermatol.2017.5462](#)]





Published by **Baishideng Publishing Group Inc**  
7041 Koll Center Parkway, Suite 160, Pleasanton, CA 94566, USA

**Telephone:** +1-925-3991568

**E-mail:** [bpgoffice@wjgnet.com](mailto:bpgoffice@wjgnet.com)

**Help Desk:** <https://www.f6publishing.com/helpdesk>

<https://www.wjgnet.com>

