

World Journal of *Gastroenterology*

World J Gastroenterol 2022 July 21; 28(27): 3282-3534



REVIEW

- 3282 Hepatitis B and circadian rhythm of the liver
Skrlec I, Talapko J
- 3297 Tumor microenvironment in pancreatic ductal adenocarcinoma: Implications in immunotherapy
Smith C, Zheng W, Dong J, Wang Y, Lai J, Liu X, Yin F
- 3314 Crosstalk between dietary patterns, obesity and nonalcoholic fatty liver disease
Ristic-Medic D, Bajerska J, Vucic V

MINIREVIEWS

- 3334 Application of intravoxel incoherent motion diffusion-weighted imaging in hepatocellular carcinoma
Zhou Y, Zheng J, Yang C, Peng J, Liu N, Yang L, Zhang XM
- 3346 Regulatory T cells and their associated factors in hepatocellular carcinoma development and therapy
Zhang CY, Liu S, Yang M
- 3359 Single-incision laparoscopic surgery to treat hepatopancreatobiliary cancer: A technical review
Chuang SH, Chuang SC
- 3370 Probiotics and postbiotics in colorectal cancer: Prevention and complementary therapy
Kvakova M, Kamlarova A, Stofilova J, Benetinova V, Bertkova I
- 3383 Interventional strategies in infected necrotizing pancreatitis: Indications, timing, and outcomes
Purschke B, Bolm L, Meyer MN, Sato H
- 3398 Artificial intelligence in liver ultrasound
Cao LL, Peng M, Xie X, Chen GQ, Huang SY, Wang JY, Jiang F, Cui XW, Dietrich CF
- 3410 Risk factors and diagnostic biomarkers for nonalcoholic fatty liver disease-associated hepatocellular carcinoma: Current evidence and future perspectives
Ueno M, Takeda H, Takai A, Seno H

ORIGINAL ARTICLE

Basic Study

- 3422 Accumulation of poly (adenosine diphosphate-ribose) by sustained supply of calcium inducing mitochondrial stress in pancreatic cancer cells
Jeong KY, Sim JJ, Park M, Kim HM

- 3435** RING finger and WD repeat domain 3 regulates proliferation and metastasis through the Wnt/ β -catenin signalling pathways in hepatocellular carcinoma

Liang RP, Zhang XX, Zhao J, Lu QW, Zhu RT, Wang WJ, Li J, Bo K, Zhang CX, Sun YL

- 3455** Associations of gut microbiota with dyslipidemia based on sex differences in subjects from Northwestern China

Guo L, Wang YY, Wang JH, Zhao HP, Yu Y, Wang GD, Dai K, Yan YZ, Yang YJ, Lv J

Retrospective Cohort Study

- 3476** Prognostic significance of hemoglobin, albumin, lymphocyte, platelet in gastrointestinal stromal tumors: A propensity matched retrospective cohort study

Zhao Z, Yin XN, Wang J, Chen X, Cai ZL, Zhang B

Retrospective Study

- 3488** Contrast-enhanced ultrasound Liver Imaging Reporting and Data System: Lights and shadows in hepatocellular carcinoma and cholangiocellular carcinoma diagnosis

Vidili G, Arru M, Solinas G, Calvisi DF, Meloni P, Sauchella A, Turilli D, Fabio C, Cossu A, Madeddu G, Babudieri S, Zocco MA, Iannetti G, Di Lembo E, Delitala AP, Manetti R

- 3503** Novel index for the prediction of significant liver fibrosis and cirrhosis in chronic hepatitis B patients in China

Liao MJ, Li J, Dang W, Chen DB, Qin WY, Chen P, Zhao BG, Ren LY, Xu TF, Chen HS, Liao WJ

SYSTEMATIC REVIEWS

- 3514** Percutaneous transhepatic cholangiography *vs* endoscopic ultrasound-guided biliary drainage: A systematic review

Hassan Z, Gadour E

CASE REPORT

- 3524** Isolated gastric variceal bleeding related to non-cirrhotic portal hypertension following oxaliplatin-based chemotherapy: A case report

Zhang X, Gao YY, Song DZ, Qian BX

LETTER TO THE EDITOR

- 3532** Hepatitis B core-related antigen: Are we near a treatment endpoint?

Gupta T

ABOUT COVER

Editorial Board Member of *World Journal of Gastroenterology*, Govind K Makharia, MD, DM,DNB, Professor, Department of Gastroenterology and Human Nutrition, All India Institute of Medical Sciences, Ansari Nagar, New Delhi 110029, India. govindmakharia@aiims.edu

AIMS AND SCOPE

The primary aim of *World Journal of Gastroenterology* (WJG, *World J Gastroenterol*) is to provide scholars and readers from various fields of gastroenterology and hepatology with a platform to publish high-quality basic and clinical research articles and communicate their research findings online. WJG mainly publishes articles reporting research results and findings obtained in the field of gastroenterology and hepatology and covering a wide range of topics including gastroenterology, hepatology, gastrointestinal endoscopy, gastrointestinal surgery, gastrointestinal oncology, and pediatric gastroenterology.

INDEXING/ABSTRACTING

The WJG is now abstracted and indexed in Science Citation Index Expanded (SCIE, also known as SciSearch®), Current Contents/Clinical Medicine, Journal Citation Reports, Index Medicus, MEDLINE, PubMed, PubMed Central, Scopus, Reference Citation Analysis, China National Knowledge Infrastructure, China Science and Technology Journal Database, and Superstar Journals Database. The 2022 edition of Journal Citation Reports® cites the 2021 impact factor (IF) for WJG as 5.374; IF without journal self cites: 5.187; 5-year IF: 5.715; Journal Citation Indicator: 0.84; Ranking: 31 among 93 journals in gastroenterology and hepatology; and Quartile category: Q2. The WJG's CiteScore for 2021 is 8.1 and Scopus CiteScore rank 2021: Gastroenterology is 18/149.

RESPONSIBLE EDITORS FOR THIS ISSUE

Production Editor: Wen-Wen Qi; Production Department Director: Xiang Li; Editorial Office Director: Jia-Ru Fan.

NAME OF JOURNAL

World Journal of Gastroenterology

ISSN

ISSN 1007-9327 (print) ISSN 2219-2840 (online)

LAUNCH DATE

October 1, 1995

FREQUENCY

Weekly

EDITORS-IN-CHIEF

Andrzej S Tarnawski

EDITORIAL BOARD MEMBERS

<http://www.wjgnet.com/1007-9327/editorialboard.htm>

PUBLICATION DATE

July 21, 2022

COPYRIGHT

© 2022 Baishideng Publishing Group Inc

INSTRUCTIONS TO AUTHORS

<https://www.wjgnet.com/bpg/gerinfo/204>

GUIDELINES FOR ETHICS DOCUMENTS

<https://www.wjgnet.com/bpg/GerInfo/287>

GUIDELINES FOR NON-NATIVE SPEAKERS OF ENGLISH

<https://www.wjgnet.com/bpg/gerinfo/240>

PUBLICATION ETHICS

<https://www.wjgnet.com/bpg/GerInfo/288>

PUBLICATION MISCONDUCT

<https://www.wjgnet.com/bpg/gerinfo/208>

ARTICLE PROCESSING CHARGE

<https://www.wjgnet.com/bpg/gerinfo/242>

STEPS FOR SUBMITTING MANUSCRIPTS

<https://www.wjgnet.com/bpg/GerInfo/239>

ONLINE SUBMISSION

<https://www.f6publishing.com>



Percutaneous transhepatic cholangiography vs endoscopic ultrasound-guided biliary drainage: A systematic review

Zeinab Hassan, Eyad Gadour

Specialty type: Gastroenterology and hepatology

Provenance and peer review: Unsolicited article; Externally peer reviewed

Peer-review model: Single blind

Peer-review report's scientific quality classification

Grade A (Excellent): A

Grade B (Very good): 0

Grade C (Good): C

Grade D (Fair): 0

Grade E (Poor): 0

P-Reviewer: Jin G, China; Villa E, United States

Received: November 22, 2021

Peer-review started: November 23, 2021

First decision: January 9, 2022

Revised: January 21, 2022

Accepted: June 23, 2022

Article in press: June 23, 2022

Published online: July 21, 2022



Zeinab Hassan, Internal Medicine, Stockport Hospitals NHS Foundation Trust, Manchester SK2 7JE, United Kingdom

Eyad Gadour, Department of Gastroenterology, University Hospitals of Morecambe Bay NHS Foundation Trust, Lancaster LA1 4RP, United Kingdom

Corresponding author: Eyad Gadour, CCST, FRCP, MBBS, MRCP, Consultant Physician-Scientist, Department of Gastroenterology, University Hospitals of Morecambe Bay NHS Foundation Trust, Royal Lancaster Infirmary, Lancaster LA1 4RP, United Kingdom.
eyadgadour@doctors.org.uk

Abstract

BACKGROUND

Percutaneous transhepatic cholangiography is a diagnostic and therapeutic procedure that involves inserting a needle into the biliary tree, followed by the immediate insertion of a catheter. Endoscopic ultrasound-guided biliary drainage (EUS-BD) is a novel technique that allows BD by echoendoscopy and fluoroscopy using a stent from the biliary tree to the gastrointestinal tract.

AIM

To compare the technical aspects and outcomes of percutaneous transhepatic BD (PTBD) and EUS-BD.

METHODS

Different databases, including PubMed, Embase, clinicaltrials.gov, the Cochrane library, Scopus, and Google Scholar, were searched according to the guidelines for Preferred Reporting Items for Systematic reviews and Meta-Analyses to obtain studies comparing PTBD and EUS-BD.

RESULTS

Among the six studies that fulfilled the inclusion criteria, PTBD patients underwent significantly more reinterventions (4.9 *vs* 1.3), experienced more postprocedural pain (4.1 *vs* 1.9), and experienced more late adverse events (53.8% *vs* 6.6%) than EUS-BD patients. There was a significant reduction in the total bilirubin levels in both the groups (16.4-3.3 $\mu\text{mol/L}$ and 17.2-3.8 $\mu\text{mol/L}$ for EUS-BD and PTBD, respectively; $P = 0.002$) at the 7-d follow-up. There were no significant differences observed in the complication rates between PTBD and EUS-BD (3.3 *vs* 3.8). PTBD was associated with a higher adverse event rate than EUS-BD in all the procedures, including reinterventions (80.4% *vs* 15.7%, respectively).

and a higher index procedure (39.2% vs 18.2%, respectively).

CONCLUSION

The findings of this systematic review revealed that EUS-BD is linked with a higher rate of effective BD and a more manageable procedure-related adverse event profile than PTBD. These findings highlight the evidence for successful EUS-BD implementation.

Key Words: Percutaneous transhepatic cholangiography; Endoscopic ultrasound; Biliary drainage; Obstructive cholangiopathy

©The Author(s) 2022. Published by Baishideng Publishing Group Inc. All rights reserved.

Core Tip: Endoscopic transpapillary biliary drainage (BD) is the preferred approach for biliary decompression in patients with unresectable pancreatic cancer and obstructive jaundice. We conducted a systematic review of studies comparing the technical aspects and outcomes of two distinct approaches for BD: Endoscopic ultrasound-guided BD (EUS-BD) and percutaneous transhepatic BD (PTBD). The evaluation of six studies that fulfilled the inclusion criteria revealed that PTBD was associated with more reinterventions, postprocedural pain, and late adverse events compared with EUS-BD. Both procedures were associated with a significant reduction in the total bilirubin levels at the 7-d follow-up, and there were no significant differences in the complication rates between the two procedures. In summary, EUS-BD was associated with a higher rate of effective BD and manageable procedure-related adverse events compared with PTBD, highlighting its utility in successful BD.

Citation: Hassan Z, Gadour E. Percutaneous transhepatic cholangiography vs endoscopic ultrasound-guided biliary drainage: A systematic review. *World J Gastroenterol* 2022; 28(27): 3514-3523

URL: <https://www.wjgnet.com/1007-9327/full/v28/i27/3514.htm>

DOI: <https://dx.doi.org/10.3748/wjg.v28.i27.3514>

INTRODUCTION

Endoscopic transpapillary biliary drainage (BD) is the preferred approach for biliary decompression in patients with unresectable pancreatic cancer and obstructive jaundice[1]. Percutaneous transhepatic cholangiography (PTC) is a diagnostic and therapeutic procedure that involves inserting a needle into the biliary tree, followed by immediately inserting a catheter to achieve percutaneous BD. During the procedure, contrast is injected into one or more bile ducts (cholangiography) and sometimes into the duodenum. PTC can be performed using fluoroscopic guidance alone or using both fluoroscopic and ultrasound guidance[2,3].

In cases of suspected malignant biliary stricture, imaging alone may not be sufficient to provide a precise diagnosis. PTC was first introduced several decades ago to visualize biliary obstructions, treat malignant obstructive jaundice palliatively, and access BD[4]. Fine needle aspiration (FNA), brush cytology, and forceps biopsy have been performed using percutaneous biliary catheterization during PTC since the 1980s[5]. For biliary stenosis, endoscopic retrograde cholangiopancreatography (ERCP) has recently been recognized as a reliable diagnostic and therapeutic procedure.

Endoscopic retrograde BD (ERBD) is the most commonly used method of biliary decompression in patients with blockage of the distal central bile duct. This technique has a success rate of 90%-95% in the United States[6]. Altered anatomy, presenting pathology (tumor infiltration, impacted stone, and duodenal compression by a pancreatic pseudocyst), previous surgery, or variations in normal anatomy (periampullary diverticula and tortuous ducts) can contribute to the failure of ERBD. The failure rate of ERBD is 6%-7% in cases with obstructive jaundice caused by a blockage or altered anatomy[7]. Percutaneous transhepatic BD (PTBD) has a lower risk of complications than surgical decompression, but it is associated with complications such as fistula formation, repeat intervention, recurrent infection, and the requirement for long-term external catheter drainage, which contribute to a low quality of life [8]. Although PTBD is associated with severe morbidity and mortality, the only relative contraindication of PTBD is perihepatic ascites[6-9]. Furthermore, PTBD usually requires separate surgery after the failure of ERCP BD, thereby increasing the morbidity associated with biliary stasis.

Endoscopic ultrasound-guided BD (EUS-BD) has become more widely used as an alternative to PTBD in patients with anatomical abnormalities, which make endoscopic transpapillary insertion of a biliary stent difficult[10]. It offers advantages of being compatible with anatomic internal drainage, being more comfortable, and resulting in a recovery associated with fewer complications and reduced expenditure [11].

EUS is an extremely useful imaging method for examining the gastrointestinal luminal wall and surrounding tissues. The proximity of the EUS probe to the area of interest enables high-resolution imaging and EUS-guided FNA tissue collection in real time. EUS has become a crucial diagnostic technique due to its high-quality imaging and FNA capacity and is also used as a treatment tool. However, until recently, its use was limited to the introduction of various drugs[12,13]. The therapeutic uses of EUS have been expanded due to larger channel echoendoscopes, which combine the benefits of real-time ultrasound and fluoroscopy imaging with the use of ERCP-based devices and procedures, such as EUS-BD. In 1996, Wiersema *et al*[14] first reported EUS-guided diagnostic cholangiography and in 2001, Giovannini *et al*[10] first reported EUS-BD in a patient with pancreatic cancer, establishing a choledochoduodenal fistula with a needle knife followed by transduodenal stenting.

These early reports were followed by modified techniques and expanded indications, such as EUS-guided hepatic gastrostomy with stent placement[15], transduodenal EUS-*rendezvous* (EUS-RV) biliary access[16], and EUS-guided choledocholithiasis therapy with the creation of a neo papilla[17]. Since then, several studies have reported modifications to these techniques, including the use of a covered metal stent as a conduit for interventional endoscopic procedures in the bile duct[18,19]. Few studies have compared EUS-BD and PTBD in failed ERCP cases in terms of success rate and adverse event profile[20]; therefore, we performed a systematic review of the relevant literature to investigate the combined efficacy and adverse effects of EUS-BD and PTBD.

MATERIALS AND METHODS

Literature search

This systematic review was conducted using an electronic search of different databases, including PubMed, Embase, clinicaltrials.gov, the Cochrane library, Scopus, and Google Scholar using the guidelines for Preferred Reporting Items for Systematic reviews and Meta-Analyses[21]. Two investigators independently searched for the following key terms: all field “failed EUS”, all field “Percutaneous biliary drainage”, and all field “EUS-guided biliary drainage”. All the three search headings were connected using the Boolean operator “AND”. Studies published in English comparing PTBD with EUS-BD were chronologically limited to those published from their inception to October 2021. After completing the literature search, the references were imported to Endnote citation manager (Endnote X9) for removing any duplicates, following which the abstracts were screened for potential relevance by two independent investigators. This study included intervention studies, retrospective or prospective observational studies, case reports, randomized controlled trials, and published abstracts that reported at least some adverse events. And this study also cited high-quality articles in Reference Citation Analysis (<https://www.referencecitationanalysis.com>).

Letters, comments, seminar proceedings, and animal studies were excluded from our analysis. Moreover, only human studies were included and limited to the English language. Publications judged to be potentially relevant underwent a full text assessment by two independent investigators to determine their inclusion. Disagreements regarding study eligibility were resolved by consensus or adjudication between the investigators.

Data extraction

The baseline study details, including study identifiers, such as first author, publication year, title, and country, and study-specific methodological data, such as sample size, study design, single-center *vs* multicenter study types, and healthcare setting, are presented in Table 1. Technical and clinical success rates, including the total number of patients enrolled, number of patients in each arm, mean age, sex ratio, comorbidity index, mean preprocedural bilirubin, mean diameter of the bile duct, etiology of biliary obstruction, and reasons for EUS failure are shown in Table 2.

Risk of bias evaluation

The GRADE checklist was used to evaluate the risk of bias in the included studies[22]. Table 3 shows a summary of the methodological qualities of studies reporting the prevalence data. Questions were answered as “yes”, “no”, “unclear”, or “not applicable”.

RESULTS

Our literature search yielded 315 manuscripts, of which 132 studies remained after excluding duplicate studies. After reviewing the title and abstract, only nine articles were left for the thorough screening of data by reviewing the full text. Further, two studies were eliminated after reading the manuscripts because they included primary EUS-BD cases wherein EUS was not attempted as the primary procedure. The third study was excluded, as it did not contain full text. A total of six studies met the abovementioned inclusion criteria of the study[23-28] (Figure 1).

Table 1 Baseline characteristics of the studies

Ref.	Artifon <i>et al</i> [23]	Bapaye <i>et al</i> [24]	Khashab <i>et al</i> [25]	Giovannini[26]	Jung <i>et al</i> [27]	Sharaiha <i>et al</i> [28]
Type of study (country)	Single-center, prospective, randomized, controlled trial(Brazil)	Single-center, retrospective, comparative study (India)	Single-center, retrospective, comparative, cohort study (United States)	Multicenter, randomized, phase II trial (France)	Multicenter, prospective, randomized, controlled trial (South Korea)	Single-center, retrospective, cohort review (United States)
Age [mean (SD)/median \pm SD], yr	63.4 (11.1) <i>vs</i> 71.0 (11.9)	59.9 \pm 13.3 <i>vs</i> 62.4 \pm 10.2	64.9 \pm 12.5 <i>vs</i> 66.9 \pm 12.5	N/A	66.5 <i>vs</i> 68.4	68.7 \pm 13.9 <i>vs</i> 58.8 \pm 13.6
Males/females	2.25 <i>vs</i> 2.0	1.08 <i>vs</i> 1.6	1.2 <i>vs</i> 1.31	0.91 <i>vs</i> 9	3.25 <i>vs</i> 3	12 <i>vs</i> 1.47
Comorbidity/quality index (mean)	58.3 <i>vs</i> 57.8 (QoL sF 36)	N/A	N/A	N/A	40.7 <i>vs</i> 40.5 (global health status/QoL)	5.9 <i>vs</i> 6.4 (Charleston comorbidity index)
Total bilirubin (mean), mg/dL	16.4 <i>vs</i> 17.2	7.11 \pm 7.6 <i>vs</i> 9.41 \pm 12.4	15.8 \pm 11.3 <i>vs</i> 14.5 \pm 8.8	N/A	10.4 <i>vs</i> 11.8	N/A
Mean diameter of bile duct	13.7 <i>vs</i> 11.9	N/A	N/A	N/A	11.22 <i>vs</i> 12.6	N/A
Etiology of obstruction						
Adenocarcinoma of the pancreatic	10 <i>vs</i> 6	15 <i>vs</i> 18	43	N/A	12 <i>vs</i> 12	22
Advanced lymphoma/liposarcoma	0 <i>vs</i> 1	0	1	N/A	0	0
Cholangiocarcinoma	1 <i>vs</i> 1	2 <i>vs</i> 2	12	N/A	7 <i>vs</i> 14	9
Duodenal carcinoma	0	0	1	N/A	3 <i>vs</i> 0	5
Gall bladder cancer	0	0	0	N/A	5 <i>vs</i> 5	0
Gastric carcinoma	0 <i>vs</i> 1	0	1	N/A	3 <i>vs</i> 2	4
Metastasis	0 <i>vs</i> 3	0	12	N/A	3 <i>vs</i> 1	7
Plasmacytoma	1 <i>vs</i> 0	0	0	N/A	0	0
Total malignancy		0	37	N/A		
Reason for ERCP failure						
Altered anatomy	1	9	0	N/A	12 <i>vs</i> 10	N/A
Duodenal/stomach invasion	8	32	0	N/A	22 <i>vs</i> 22	N/A
Indwelling duodenal stent	0	16	0	N/A	0	N/A
Unable to cannulate	16	42	0	N/A	0	N/A

N/A: Not applicable; QoL sF: Quality of life Short Form Survey (SF-36); ERCP: Endoscopic retrograde cholangiopancreatography.

DISCUSSION

The most common method for gaining access to the biliary tree is ERCP. In patients with unmodified upper gastrointestinal anatomy, the success rate of bile duct cannulation using ERCP is > 90%[25]. Affected or variant anatomy, ampullary pathology (stones, stenosis, and tumor infiltration), periampullary diverticulum, gastric outlet obstruction, indwelling duodenal stent, and previous gastric bypass surgery are the prevalent causes of failed cannulation[29]. The rate of adverse outcomes associated with PTBD and surgery is extremely high, although these approaches are traditionally used to treat these clinical conditions[30]. The most prevalent issues related to long-term PTBD therapy are drain blockage, dislocation, and cholangitis, which require multiple interventions and longer hospital stays[31]. Moreover, patients are left with a permanent external drain, resulting in poor quality of life[32]. EUS-BD has emerged as a viable, extremely safe, effective, and minimally invasive approach[33]. Using echoendoscopy and fluoroscopy, the biliary tree is accessed from the gastrointestinal lumen, a fistulous tract is created, and a stent is deployed in a single step, eliminating the need for an external drain[34]. However, the rates of success and adverse events associated with EUS-BD remain unclear. The use of EUS-BD was first reported by Giovannini *et al*[10] in 2001. Subsequently, several studies reported the

Table 2 Rates of clinical and technical success in the included studies

Ref.	Technical success		Clinical success	
	EUS-guided Choledochoduodenostomy	Percutaneous transhepatic biliarydrainage	EUS-guided Choledochoduodenostomy	Percutaneous transhepatic biliarydrainage
Artifon <i>et al</i> [23]	13/13	12/12	13/13	12/12
Bapaye <i>et al</i> [24]	23/25	26/26	23/25	26/26
Khashab <i>et al</i> [25]	19/22	51/51	19/19	47/51
Giovannini [26]	19/20	17/17	18/19	17/17
Jung <i>et al</i> [27]	32/34	31/32	28/32	27/31
Sharaiha <i>et al</i> [28]	43/47	12/13	27/43	3/12

Table 3 Quality of identified studies

Ref.	Criteria									Overall appraisal
	C1	C2	C3	C4	C5	C6	C7	C8	C9	
Artifon <i>et al</i> [23]	Yes	Yes	Yes	Yes	Yes	Yes	Yes	Unclear	Yes	Included
Bapaye <i>et al</i> [24]	Yes	Yes	Yes	Yes	Yes	Yes	Yes	Yes	Yes	Included
Khashab <i>et al</i> [25]	Yes	Yes	Yes	Yes	Yes	Yes	Yes	Yes	Yes	Included
Giovannini [26]	Unclear	Yes	Yes	Yes	Yes	Yes	Yes	Yes	Yes	Included
Jung <i>et al</i> [27]	Yes	Yes	Yes	Yes	Yes	Yes	Yes	Unclear	Yes	Included
Sharaiha <i>et al</i> [28]	Yes	Yes	Yes	Yes	Yes	Unclear	Yes	Yes	Yes	Included

C1: Did the study sample represent the target population? C2: Were participants in the study appropriately recruited? C3: Was the sample size adequate? C4: Were the study subjects and study setting described in detail? C5: Did the data analysis cover a sufficient portion of the identified population? C6: Were objective and standard criteria used to measure the condition of interest? C7: Was the condition reliably measured? C8: Was the statistical analysis appropriate? C9: Were all important confounding factors/subgroups/differences identified and taken into account?

efficacy of EUS-BD as an alternative BD method after a failed ERCP. The EUS-BD procedures are divided into three techniques: (1) EUS-RV; (2) EUS-guided antegrade (EUS-AG); and (3) EUS-guided transluminal BD, including EUS-guided choledochoduodenostomy (EUS-CDS) and EUS-guided hepaticogastrostomy (EUS-HGS)[6]. In EUS-RV, the biliary duct is accessed using fluoroscopy and EUS, forming a temporary fistula, followed by guidewire placement into the duodenum *via* the biliary duct and ampulla. After guidewire placement, ERCP is performed using the EUS-placed guidewire, which is removed once biliary cannulation is obtained. Thus, EUS-RV should be performed in patients with an endoscopically accessible ampulla after unsuccessful biliary cannulation using conventional ERCP.

In EUS-AG, the intrahepatic biliary duct is accessed by creating a temporary fistula between the intestine and intrahepatic biliary duct from the upper intestine. Stent placement or balloon dilation is performed after the dilation of the fistula to achieve biliary obstruction through the fistula without reaching the ampulla using the endoscope. This technique is appropriate when reaching the biliary orifice using endoscopy is impossible or unmanageable, such as in biliary obstruction in patients with surgically altered anatomy or upper intestinal obstruction.

In EUS-guided transluminal BD, including EUS-CDS and EUS-HGS, the biliary duct is accessed followed by guidewire placement and fistula dilation under EUS guidance. For BD, a permanent fistula is created by inserting the stent between the biliary duct and the intestine. This procedure can be performed in cases where reaching the biliary orifice using endoscopy is possible or accessible; however, in patients with unresectable malignant biliary obstruction, its indication should be limited given the features of permanent fistula creation.

Recent studies have demonstrated that EUS-BD could be an alternative to PTBD in patients with inoperable malignant biliary blockage and failed ERCP. However, individual study outcomes show inconsistent results. We performed a systemic analysis to aggregate information from individual trials

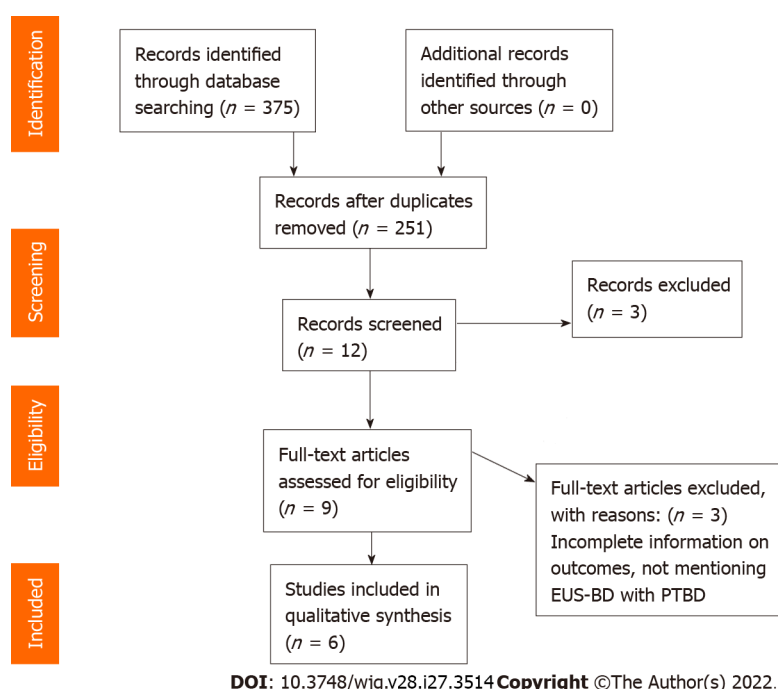


Figure 1 PRISMA Flow Diagram. EUS-BD: Endoscopic ultrasound-guided biliary drainage; PTBD: Percutaneous transhepatic biliary drainage.

and examine the overall outcomes of EUS-BD compared with PTBD. EUS-BD was associated with a lower rate of adverse events compared with PTBD. The healthcare cost of PTBD was twice that of EUS-BD due to the high reintervention rate in the PTBD group. A retrospective study by Sharaiha *et al*[28] reported that the technical success rate was comparable between PTBD and EUS-BD in patients with inoperable malignant biliary obstruction and inaccessible papilla. In a retrospective study examining patients with incurable malignant biliary obstruction with failed ERCP due to an inaccessible papilla, Bapaye *et al*[24] found that the EUS-BD group had a higher success rate of BD (92% *vs* 46%, respectively, $P > 0.05$) and a lower rate of adverse events than the PTBD group (20% *vs* 46%, respectively, $P = 0.05$) [24]. These results were partially due to the use of EUS-BD in high-volume centers by experienced endoscopists. The rates of success and the complications of EUS-BD are expected to improve with technical advances.

In the present systematic review, the only randomized controlled study comparing EUS-BD and PTBD in patients with inoperable malignant biliary blockage was conducted by Artifon *et al*[8]. The study, which included 13 patients in the EUS-BD group and 12 patients in the PTBD group, reported that EUS-BD and PTBD were comparable in terms of cost, adverse events, and clinically meaningful improvements in bilirubin levels. The bilirubin levels in the EUS-BD group declined from 16.4 $\mu\text{mol/L}$ to 3.3 $\mu\text{mol/L}$, whereas the bilirubin levels in the PTBD group declined from 17.2 $\mu\text{mol/L}$ to 3.3 $\mu\text{mol/L}$ [8]. The postprocedural follow-up period was 7 d in both the groups. Choi *et al*[32] reported a higher technical success rate in the PTBD group than in the EUS-BD group, although the functional success rate was comparable between the two groups[35].

In most facilities, PTBD is used as an alternative technique in cases of failed ERCP. In high-volume clinics, endoscopic ultrasound-guided gallbladder drainage has begun replacing PTBD, which was developed only a decade ago as the fourth approach for biliary decompression after surgical drainage, percutaneous transhepatic drainage, and endoscopic transpapillary drainage[36]. Although the type of BD approach used in cases of failed ERCP is currently determined by local competence, EUS-BD is a less intrusive and more physiologic technique. This approach improves nutrition absorption, prevents electrolyte loss, reduces reinterventions, and eliminates the stress of external drainage[37]. EUS-BD can also be performed in a single setting before ERCP if the patient agrees.

However, EUS-BD is associated with several specific issues. Only a small number of centers have the operational skills to perform EUS-BD, whereas most centers have extensive experience and skills to perform PTBD, and interventional radiologists are well-trained and equipped to perform PTBD[25]. The inherent risk of advanced endoscopy necessitates specialized training. Therefore, EUS-BD can only be performed in high-volume treatment institutions with adequate interventional radiology and surgical backup to prevent complications such as bile leak, pneumoperitoneum, hemorrhage, and stent migration[38,39].

The invasion of the sterile biliary tree by transmural puncture from the luminal side of the gastrointestinal tract poses a modest theoretical risk of infection in EUS-BD[40]. However, such negative events should improve with the further evolution of this technique. Despite its classification as a rescue

treatment for failed ERCP, primary EUS-BD is currently compared with ERCP, and a recent study indicated similar short-term outcomes between EUS-BD and ERCP[41]. In addition, unlike ERCP, there is no risk of pancreatitis following EUS-BD. Furthermore, the clinical success rates and complications do not differ between EUS-BD and ERCP if performed by skilled endoscopists. The current systematic review revealed that EUS-BD was safe and effective when performed by skilled individuals, with a lower risk of adverse events and similar technical and clinical success rates.

Our analyses also indicated that: In patients with inoperable biliary blockage after a failed ERCP, EUS-BD was associated with a higher chance of successful BD and a lower risk of procedure-related adverse effects and infectious complications compared with PTBD. Furthermore, the number of patients with bile leaks was lower in the EUS-BD group than in the PTBD group.

CONCLUSION

Several case reports, series, and retrospective investigations regarding EUS-BD have been published to date. However, no prospective studies or comparisons of the various BD systems have been published; therefore, the technical success, functional success, adverse events, and stent patency of EUS-BD with long-term follow-up remain unknown. Prospective, randomized controlled studies are required to clarify these issues. However, it is clear that EUS-BD is clinically useful as a BD option. EUS-BD could become a first-line BD treatment instead of ERCP if the outcomes of clinical studies are positive and technologies are simplified.

ARTICLE HIGHLIGHTS

Research background

Percutaneous transhepatic cholangiography is a diagnostic and therapeutic procedure. Endoscopic ultrasound-guided biliary drainage (EUS-BD) is a novel technique that allows BD whose technicality, success rate, and outcomes are not negligible.

Research motivation

We aimed to compare the technical details and outcomes of 132 studies concerning interventional BD procedures in patients with obstructive cholangiopathy. We conducted a systematic review of six studies that met the inclusion criteria.

Research objectives

To assess the suitability and appropriability of different clinical biliary interventions in achieving optimal BD for obstructive cholangiopathy.

Research methods

An extensive systematic review was independently conducted by two investigators using an electronic search of different databases, including PubMed, Embase, clinicaltrials.gov, the Cochrane library, Scopus, and Google Scholar, using the guidelines for Preferred Reporting Items for Systematic reviews and Meta-Analyses to identify studies comparing percutaneous transhepatic BD (PTBD) and EUS-BD.

Research results

PTBD patients underwent significantly more reinterventions (4.9 *vs* 1.3), experienced more postprocedural pain (4.1 *vs* 1.9), and experienced more late adverse events (53.8% *vs* 6.6%) than EUS-BD patients. There was a significant reduction in the total bilirubin levels in both the groups (16.4-3.3 $\mu\text{mol/L}$ and 17.2-3.8 $\mu\text{mol/L}$ in the EUS-BD and PTBD groups, respectively; $P = 0.002$) at the postprocedural 7-d follow-up. There were no significant differences in the complication rates between the PTBD and EUS-BD groups (3.3 *vs* 3.8). PTBD was associated with a higher adverse event rate than EUS-BD in all the procedures, including reinterventions (80.4% *vs* 15.7%, respectively) and a higher rate of index procedure (39.2% *vs* 18.2%, respectively).

Research conclusions

EUS-BD might be considered as a first-line BD treatment instead of PTBD if the outcomes of clinical studies are favorable and the technical approach is simplified.

Research perspectives

EUS-BD following failed ERCP was superior to PTBD in patients with obstructive cholangiopathy.

FOOTNOTES

Author contributions: Hassan Z contributed in study selection, data analysis, and writing of the manuscript; Gadour E contributed in study conception, analysis and interpretation of the data, and drafting of the manuscript; and all authors have approved the final manuscript.

Conflict-of-interest statement: All the authors report no relevant conflicts of interest for this article.

PRISMA 2009 Checklist statement: The authors have read the PRISMA 2009 Checklist, and the manuscript was prepared and revised according to the PRISMA 2009 Checklist.

Open-Access: This article is an open-access article that was selected by an in-house editor and fully peer-reviewed by external reviewers. It is distributed in accordance with the Creative Commons Attribution NonCommercial (CC BY-NC 4.0) license, which permits others to distribute, remix, adapt, build upon this work non-commercially, and license their derivative works on different terms, provided the original work is properly cited and the use is non-commercial. See: <https://creativecommons.org/licenses/by-nc/4.0/>

Country/Territory of origin: United Kingdom

ORCID number: Zeinab Hassan 0000-0003-0703-6500; Eyad Gadour 0000-0001-5087-1611.

Corresponding Author's Membership in Professional Societies: British Society of Gastroenterology, BSG64346.

S-Editor: Wang JJ

L-Editor: A

P-Editor: Wang JJ

REFERENCES

- 1 Ang TL, Teo EK, Fock KM. EUS-guided transduodenal biliary drainage in unresectable pancreatic cancer with obstructive jaundice. *JOP* 2007; **8**: 438-443 [PMID: 17625296]
- 2 Mastier C, Valette PJ, Adham M, Mabrut JY, Glehen O, Ponchon T, Rousset P, Rode A. Complex Biliary Leaks: Effectiveness of Percutaneous Radiological Treatment Compared to Simple Leaks in 101 Patients. *Cardiovasc Intervent Radiol* 2018; **41**: 1566-1572 [PMID: 29872897 DOI: 10.1007/s00270-018-2005-1]
- 3 Azeemuddin M, Turab N Al Qamari, Chaudhry MBH, Hamid S, Hasan M, Sayani R. Percutaneous Management of Biliary Enteric Anastomotic Strictures: An Institutional Review. *Cureus* 2018; **10**: e2228 [PMID: 29713573 DOI: 10.7759/cureus.2228]
- 4 DeMasi CJ, Akdamar K, Hunter FM, Sparks RD. Percutaneous transhepatic cholangiography in the diagnosis of jaundice. *Am J Med Sci* 1967; **254**: 316-321 [PMID: 6054533 DOI: 10.1097/0000441-196709000-00006]
- 5 Voegeli DR, Crummy AB, Weese JL. Percutaneous transhepatic cholangiography, drainage, and biopsy in patients with malignant biliary obstruction. An alternative to surgery. *Am J Surg* 1985; **150**: 243-247 [DOI: 10.1016/0002-9610(85)90129-1]
- 6 Komaki T, Kitano M, Sakamoto H, Kudo M. Endoscopic ultrasonography-guided biliary drainage: evaluation of a choledochoduodenostomy technique. *Pancreatol* 2011; **11** Suppl 2: 47-51 [PMID: 21464587 DOI: 10.1159/000323508]
- 7 Enochsson L, Swahn F, Arnell U, Nilsson M, Löhr M, Persson G. Nationwide, population-based data from 11,074 ERCP procedures from the Swedish Registry for Gallstone Surgery and ERCP. *Gastrointest Endosc* 2010; **72**: 1175-1184, 1184.e1 [PMID: 20970787 DOI: 10.1016/j.gie.2010.07.047]
- 8 Artifon EL, Sakai P, Cunha JE, Dupont A, Filho FM, Hondo FY, Ishioka S, Raju GS. Surgery or endoscopy for palliation of biliary obstruction due to metastatic pancreatic cancer. *Am J Gastroenterol* 2006; **101**: 2031-2037 [PMID: 16968509 DOI: 10.1111/j.1572-0241.2006.00764.x]
- 9 Weber A, Gaa J, Rosca B, Born P, Neu B, Schmid RM, Prinz C. Complications of percutaneous transhepatic biliary drainage in patients with dilated and nondilated intrahepatic bile ducts. *Eur J Radiol* 2009; **72**: 412-417 [PMID: 18926655 DOI: 10.1016/j.ejrad.2008.08.012]
- 10 Giovannini M, Moutardier V, Pesenti C, Bories E, Lelong B, Delperio JR. Endoscopic ultrasound-guided bilioduodenal anastomosis: a new technique for biliary drainage. *Endoscopy* 2001; **33**: 898-900 [PMID: 11571690 DOI: 10.1055/s-2001-17324]
- 11 Lesmana CRA, Gani RA, Hasan I, Sulaiman AS, Ho KY, Dhir V, Lesmana LA. Palliative Endoscopic Ultrasound Biliary Drainage for Advanced Malignant Biliary Obstruction: Should It Replace the Percutaneous Approach? *Case Rep Gastroenterol* 2019; **13**: 385-397 [PMID: 31616233 DOI: 10.1159/000502835]
- 12 Kozarek RA. Malignant jaundice. *Eur J Cancer Suppl* 2005; **3**: 183-190 [DOI: 10.1016/S1359-6349(05)80275-7]
- 13 Collins D, Penman I, Mishra G, Draganov P. EUS-guided celiac block and neurolysis. *Endoscopy* 2006; **38**: 935-939 [PMID: 16981114 DOI: 10.1055/s-2006-944734]
- 14 Wiersema MJ, Sandusky D, Carr R, Wiersema LM, Erdel WC, Frederick PK. Endosonography-guided cholangiopancreatography. *Gastrointest Endosc* 1996; **43**: 102-106 [PMID: 8635700 DOI: 10.1016/s0016-5107(06)80108-2]
- 15 Giovannini M, Dotti M, Bories E, Moutardier V, Pesenti C, Danisi C, Delperio JR. Hepaticogastrostomy by echo-endoscopy as a palliative treatment in a patient with metastatic biliary obstruction. *Endoscopy* 2003; **35**: 1076-1078 [PMID: 12811114 DOI: 10.1055/s-2003-45473]

- 14648424 DOI: 10.1055/s-2003-44596]
- 16 **Mallery S**, Matlock J, Freeman ML. EUS-guided rendezvous drainage of obstructed biliary and pancreatic ducts: Report of 6 cases. *Gastrointest Endosc* 2004; **59**: 100-107 [PMID: 14722561 DOI: 10.1016/s0016-5107(03)02300-9]
 - 17 **Itoi T**, Itokawa F, Sofuni A, Kurihara T, Tsuchiya T, Ishii K, Tsuji S, Ikeuchi N, Moriyasu F. Endoscopic ultrasound-guided choledochoduodenostomy in patients with failed endoscopic retrograde cholangiopancreatography. *World J Gastroenterol* 2008; **14**: 6078-6082 [PMID: 18932289 DOI: 10.3748/wjg.14.6078]
 - 18 **Kahaleh M**, Yoshida C, Kane L, Yeaton P. Interventional EUS cholangiography: A report of five cases. *Gastrointest Endosc* 2004; **60**: 138-142 [PMID: 15229448 DOI: 10.1016/s0016-5107(04)01528-7]
 - 19 **Chavalitthamrong D**, Draganov PV. Endoscopic ultrasound-guided biliary drainage. *World J Gastroenterol* 2012; **18**: 491-497 [PMID: 22363114 DOI: 10.3748/wjg.v18.i6.491]
 - 20 **Lee TH**, Choi JH, Park do H, Song TJ, Kim DU, Paik WH, Hwangbo Y, Lee SS, Seo DW, Lee SK, Kim MH. Similar Efficacies of Endoscopic Ultrasound-guided Transmural and Percutaneous Drainage for Malignant Distal Biliary Obstruction. *Clin Gastroenterol Hepatol* 2016; **14**: 1011-1019.e3 [PMID: 26748220 DOI: 10.1016/j.cgh.2015.12.032]
 - 21 **Beller EM**, Glasziou PP, Altman DG, Hopewell S, Bastian H, Chalmers I, Gøtzsche PC, Lasserson T, Tovey D; PRISMA for Abstracts Group. PRISMA for Abstracts: reporting systematic reviews in journal and conference abstracts. *PLoS Med* 2013; **10**: e1001419 [PMID: 23585737 DOI: 10.1371/journal.pmed.1001419]
 - 22 **Guyatt GH**, Oxman AD, Schünemann HJ, Tugwell P, Knottnerus A. GRADE guidelines: a new series of articles in the Journal of Clinical Epidemiology. *J Clin Epidemiol* 2011; **64**: 380-382 [PMID: 21185693 DOI: 10.1016/j.jclinepi.2010.09.011]
 - 23 **Artifon EL**, Aparicio D, Paione JB, Lo SK, Bordini A, Rabello C, Otoch JP, Gupta K. Biliary drainage in patients with unresectable, malignant obstruction where ERCP fails: endoscopic ultrasonography-guided choledochoduodenostomy versus percutaneous drainage. *J Clin Gastroenterol* 2012; **46**: 768-774 [PMID: 22810111 DOI: 10.1097/MCG.0b013e31825f264c]
 - 24 **Bapaye A**, Dubale N, Aher A. Comparison of endosonography-guided vs. percutaneous biliary stenting when papilla is inaccessible for ERCP. *United European Gastroenterol J* 2013; **1**: 285-293 [PMID: 24917973 DOI: 10.1177/2050640613490928]
 - 25 **Khashab MA**, Valeshabad AK, Afghani E, Singh VK, Kumbhari V, Messallam A, Saxena P, El Zein M, Lennon AM, Canto MI, Kalloo AN. A comparative evaluation of EUS-guided biliary drainage and percutaneous drainage in patients with distal malignant biliary obstruction and failed ERCP. *Dig Dis Sci* 2015; **60**: 557-565 [PMID: 25081224 DOI: 10.1007/s10620-014-3300-6]
 - 26 **Giovannini M**. Learning in therapeutic EUS. *Endosc Ultrasound* 2021; **10**: 317-318 [PMID: 34677158 DOI: 10.4103/EUS-D-21-00205]
 - 27 **Jung Y**, Lee J, Cho JY, Kim YD, Park CG, Kim MW, Kim KJ, Kim SW. Comparison of efficacy and safety between endoscopic submucosal dissection and transanal endoscopic microsurgery for the treatment of rectal tumor. *Saudi J Gastroenterol* 2018; **24**: 115-121 [PMID: 29637919 DOI: 10.4103/sjg.SJG_440_17]
 - 28 **Sharaiha RZ**, Kumta NA, Desai AP, DeFilippis EM, Gabr M, Sarkisian AM, Salgado S, Millman J, Benvenuto A, Cohen M, Tyberg A, Gaidhane M, Kahaleh M. Endoscopic ultrasound-guided biliary drainage versus percutaneous transhepatic biliary drainage: predictors of successful outcome in patients who fail endoscopic retrograde cholangiopancreatography. *Surg Endosc* 2016; **30**: 5500-5505 [PMID: 27129552 DOI: 10.1007/s00464-016-4913-y]
 - 29 **Laméris JS**, Stoker J, Nijs HG, Zonderland HM, Terpstra OT, van Blankenstein M, Schütte HE. Malignant biliary obstruction: percutaneous use of self-expandable stents. *Radiology* 1991; **179**: 703-707 [PMID: 2027978 DOI: 10.1148/radiology.179.3.2027978]
 - 30 **Smith AC**, Dowsett JF, Russell RC, Hatfield AR, Cotton PB. Randomised trial of endoscopic stenting versus surgical bypass in malignant low bileduct obstruction. *Lancet* 1994; **344**: 1655-1660 [PMID: 7996958 DOI: 10.1016/S0140-6736(94)90455-3]
 - 31 **Nennstiel S**, Weber A, Frick G, Haller B, Meining A, Schmid RM, Neu B. Drainage-related Complications in Percutaneous Transhepatic Biliary Drainage: An Analysis Over 10 Years. *J Clin Gastroenterol* 2015; **49**: 764-770 [PMID: 25518004 DOI: 10.1097/MCG.0000000000000275]
 - 32 **Choi JH**, Kim HW, Lee JC, Paik KH, Seong NJ, Yoon CJ, Hwang JH, Kim J. Percutaneous transhepatic versus EUS-guided gallbladder drainage for malignant cystic duct obstruction. *Gastrointest Endosc* 2017; **85**: 357-364 [PMID: 27566055 DOI: 10.1016/j.gie.2016.07.067]
 - 33 **Irani S**, Baron TH, Grimm IS, Khashab MA. EUS-guided gallbladder drainage with a lumen-apposing metal stent (with video). *Gastrointest Endosc* 2015; **82**: 1110-1115 [PMID: 26142558 DOI: 10.1016/j.gie.2015.05.045]
 - 34 **Teoh AY**, Binmoeller KF, Lau JY. Single-step EUS-guided puncture and delivery of a lumen-apposing stent for gallbladder drainage using a novel cautery-tipped stent delivery system. *Gastrointest Endosc* 2014; **80**: 1171 [PMID: 24830582 DOI: 10.1016/j.gie.2014.03.038]
 - 35 **Caglar E**, Atasoy D, Tozlu M, Altinkaya E, Dogan S, Senturk H. Experience of the Endoscopists Matters in Endoscopic Retrograde Cholangiopancreatography in Billroth II Gastrectomy Patients. *Clin Endosc* 2020; **53**: 82-89 [PMID: 31476843 DOI: 10.5946/ce.2019.073]
 - 36 **Baniya R**, Upadhaya S, Madala S, Subedi SC, Shaik Mohammed T, Bachuwa G. Endoscopic ultrasound-guided biliary drainage versus percutaneous transhepatic biliary drainage after failed endoscopic retrograde cholangiopancreatography: a meta-analysis. *Clin Exp Gastroenterol* 2017; **10**: 67-74 [PMID: 28408850 DOI: 10.2147/CEG.S132004]
 - 37 **Holt BA**, Hawes R, Hasan M, Canipe A, Tharian B, Navaneethan U, Varadarajulu S. Biliary drainage: role of EUS guidance. *Gastrointest Endosc* 2016; **83**: 160-165 [PMID: 26215648 DOI: 10.1016/j.gie.2015.06.019]
 - 38 **Kahaleh M**, Artifon EL, Perez-Miranda M, Gupta K, Itoi T, Binmoeller KF, Giovannini M. Endoscopic ultrasonography guided biliary drainage: summary of consortium meeting, May 7th, 2011, Chicago. *World J Gastroenterol* 2013; **19**: 1372-1379 [PMID: 23538784 DOI: 10.3748/wjg.v19.i9.1372]
 - 39 **Kawakubo K**, Isayama H, Kato H, Itoi T, Kawakami H, Hanada K, Ishiwatari H, Yasuda I, Kawamoto H, Itokawa F, Kuwatani M, Iiboshi T, Hayashi T, Doi S, Nakai Y. Multicenter retrospective study of endoscopic ultrasound-guided biliary

- drainage for malignant biliary obstruction in Japan. *J Hepatobiliary Pancreat Sci* 2014; **21**: 328-334 [PMID: 24026963 DOI: 10.1002/jhbp.27]
- 40 **Lakhtakia S.** Complications of diagnostic and therapeutic Endoscopic Ultrasound. *Best Pract Res Clin Gastroenterol* 2016; **30**: 807-823 [PMID: 27931638 DOI: 10.1016/j.bpg.2016.10.008]
- 41 **Dhir V,** Itoi T, Khashab MA, Park DH, Yuen Bun Teoh A, Attam R, Messallam A, Varadarajulu S, Maydeo A. Multicenter comparative evaluation of endoscopic placement of expandable metal stents for malignant distal common bile duct obstruction by ERCP or EUS-guided approach. *Gastrointest Endosc* 2015; **81**: 913-923 [PMID: 25484326 DOI: 10.1016/j.gie.2014.09.054]



Published by **Baishideng Publishing Group Inc**
7041 Koll Center Parkway, Suite 160, Pleasanton, CA 94566, USA

Telephone: +1-925-3991568

E-mail: bpgoffice@wjgnet.com

Help Desk: <https://www.f6publishing.com/helpdesk>

<https://www.wjgnet.com>

