

World Journal of *Clinical Cases*

World J Clin Cases 2022 May 16; 10(14): 4327-4712



OPINION REVIEW

- 4327 Emerging role of biosimilars in the clinical care of inflammatory bowel disease patients
Najeeb H, Yasmin F, Surani S

MINIREVIEWS

- 4334 Practical insights into chronic management of hepatic Wilson's disease
Lynch EN, Campani C, Innocenti T, Dragoni G, Forte P, Galli A
- 4348 Adipose-derived stem cells in the treatment of hepatobiliary diseases and sepsis
Satilmis B, Cicek GS, Cicek E, Akbulut S, Sahin TT, Yilmaz S

ORIGINAL ARTICLE

Clinical and Translational Research

- 4357 Learning curve for a surgeon in robotic pancreaticoduodenectomy through a "G"-shaped approach: A cumulative sum analysis
Wei ZG, Liang CJ, Du Y, Zhang YP, Liu Y
- 4368 Clinical and prognostic significance of expression of phosphoglycerate mutase family member 5 and Parkin in advanced colorectal cancer
Wu C, Feng ML, Jiao TW, Sun MJ

Case Control Study

- 4380 Significance of preoperative peripheral blood neutrophil-lymphocyte ratio in predicting postoperative survival in patients with multiple myeloma bone disease
Xu ZY, Yao XC, Shi XJ, Du XR

Retrospective Study

- 4395 Association between depression and malnutrition in pulmonary tuberculosis patients: A cross-sectional study
Fang XE, Chen DP, Tang LL, Mao YJ
- 4404 Pancreatic cancer incidence and mortality patterns in 2006-2015 and prediction of the epidemiological trend to 2025 in China
Yin MY, Xi LT, Liu L, Zhu JZ, Qian LJ, Xu CF
- 4414 Evaluation of short- and medium-term efficacy and complications of ultrasound-guided ablation for small liver cancer
Zhong H, Hu R, Jiang YS

- 4425** Hematopoiesis reconstitution and anti-tumor effectiveness of Pai-Neng-Da capsule in acute leukemia patients with haploidentical hematopoietic stem cell transplantation

Yuan JJ, Lu Y, Cao JJ, Pei RZ, Gao RL

- 4436** Oral and maxillofacial pain as the first sign of metastasis of an occult primary tumour: A fifteen-year retrospective study

Shan S, Liu S, Yang ZY, Wang TM, Lin ZT, Feng YL, Pakezhati S, Huang XF, Zhang L, Sun GW

- 4446** Reduced serum high-density lipoprotein cholesterol levels and aberrantly expressed cholesterol metabolism genes in colorectal cancer

Tao JH, Wang XT, Yuan W, Chen JN, Wang ZJ, Ma YB, Zhao FQ, Zhang LY, Ma J, Liu Q

Observational Study

- 4460** Correlation of pressure gradient in three hepatic veins with portal pressure gradient

Wang HY, Song QK, Yue ZD, Wang L, Fan ZH, Wu YF, Dong CB, Zhang Y, Meng MM, Zhang K, Jiang L, Ding HG, Zhang YN, Yang YP, Liu FQ

- 4470** Multi-slice spiral computed tomography in diagnosing unstable pelvic fractures in elderly and effect of less invasive stabilization

Huang JG, Zhang ZY, Li L, Liu GB, Li X

SYSTEMATIC REVIEWS

- 4480** Distribution and changes in hepatitis C virus genotype in China from 2010 to 2020

Yang J, Liu HX, Su YY, Liang ZS, Rao HY

CASE REPORT

- 4494** Bow hunter's syndrome successfully treated with a posterior surgical decompression approach: A case report and review of literature

Orlandi N, Cavallieri F, Grisendi I, Romano A, Ghadirpour R, Napoli M, Moratti C, Zanichelli M, Pascarella R, Valzania F, Zedde M

- 4502** Histological remission of eosinophilic esophagitis under asthma therapy with IL-5 receptor monoclonal antibody: A case report

Huguenot M, Bruhm AC, Essig M

- 4509** Cutaneous mucosa-associated lymphoid tissue lymphoma complicating Sjögren's syndrome: A case report and review of literature

Liu Y, Zhu J, Huang YH, Zhang QR, Zhao LL, Yu RH

- 4519** Plexiform neurofibroma of the cauda equina with follow-up of 10 years: A case report

Chomanskis Z, Juskys R, Cepkus S, Dulko J, Hendrixson V, Ruksenas O, Rocka S

- 4528** Mixed porokeratosis with a novel mevalonate kinase gene mutation: A case report

Xu HJ, Wen GD

- 4535** Isolated pancreatic injury caused by abdominal massage: A case report

Sun BL, Zhang LL, Yu WM, Tuo HF

- 4541** Bronchiolar adenoma with unusual presentation: Two case reports
Du Y, Wang ZY, Zheng Z, Li YX, Wang XY, Du R
- 4550** Periodontal-orthodontic interdisciplinary management of a “periodontally hopeless” maxillary central incisor with severe mobility: A case report and review of literature
Jiang K, Jiang LS, Li HX, Lei L
- 4563** Anesthesia management for cesarean section in a pregnant woman with odontogenic infection: A case report
Ren YL, Ma YS
- 4569** Convulsive-like movements as the first symptom of basilar artery occlusive brainstem infarction: A case report
Wang TL, Wu G, Liu SZ
- 4574** Globe luxation may prevent myopia in a child: A case report
Li Q, Xu YX
- 4580** Computer tomography-guided negative pressure drainage treatment of intrathoracic esophagojejunal anastomotic leakage: A case report
Jiang ZY, Tao GQ, Zhu YF
- 4586** Primary or metastatic lung cancer? Sebaceous carcinoma of the thigh: A case report
Wei XL, Liu Q, Zeng QL, Zhou H
- 4594** Perianesthesia emergency repair of a cut endotracheal tube's inflatable tube: A case report
Wang TT, Wang J, Sun TT, Hou YT, Lu Y, Chen SG
- 4601** Diagnosis of cytomegalovirus encephalitis using metagenomic next-generation sequencing of blood and cerebrospinal fluid: A case report
Xu CQ, Chen XL, Zhang DS, Wang JW, Yuan H, Chen WF, Xia H, Zhang ZY, Peng FH
- 4608** Primary sigmoid squamous cell carcinoma with liver metastasis: A case report
Li XY, Teng G, Zhao X, Zhu CM
- 4617** Acute recurrent cerebral infarction caused by moyamoya disease complicated with adenomyosis: A case report
Zhang S, Zhao LM, Xue BQ, Liang H, Guo GC, Liu Y, Wu RY, Li CY
- 4625** Serum-negative Sjogren's syndrome with minimal lesion nephropathy as the initial presentation: A case report
Li CY, Li YM, Tian M
- 4632** Successful individualized endodontic treatment of severely curved root canals in a mandibular second molar: A case report
Xu LJ, Zhang JY, Huang ZH, Wang XZ

- 4640** Successful treatment in one myelodysplastic syndrome patient with primary thrombocytopenia and secondary deep vein thrombosis: A case report
Liu WB, Ma JX, Tong HX
- 4648** Diagnosis of an extremely rare case of malignant adenomyoepithelioma in pleomorphic adenoma: A case report
Zhang WT, Wang YB, Ang Y, Wang HZ, Li YX
- 4654** Management about intravesical histological transformation of prostatic mucinous carcinoma after radical prostatectomy: A case report
Bai SJ, Ma L, Luo M, Xu H, Yang L
- 4661** Hepatopulmonary metastases from papillary thyroid microcarcinoma: A case report
Yang CY, Chen XW, Tang D, Yang WJ, Mi XX, Shi JP, Du WD
- 4669** PD-1 inhibitor in combination with fruquintinib therapy for initial unresectable colorectal cancer: A case report
Zhang HQ, Huang CZ, Wu JY, Wang ZL, Shao Y, Fu Z
- 4676** Cutaneous metastasis from esophageal squamous cell carcinoma: A case report
Zhang RY, Zhu SJ, Xue P, He SQ
- 4684** Rare pattern of Maisonneuve fracture: A case report
Zhao B, Li N, Cao HB, Wang GX, He JQ
- 4691** Suprasellar cistern tuberculoma presenting as unilateral ocular motility disorder and ptosis: A case report
Zhao BB, Tian C, Fu LJ, Zhang XB
- 4698** Development of plasma cell dyscrasias in a patient with chronic myeloid leukemia: A case report
Zhang N, Jiang TD, Yi SH
- 4704** Ovarian growing teratoma syndrome with multiple metastases in the abdominal cavity and liver: A case report
Hu X, Jia Z, Zhou LX, Kakongoma N

LETTER TO THE EDITOR

- 4709** Perfectionism and mental health problems: Limitations and directions for future research
Nazari N

ABOUT COVER

Editorial Board Member of *World Journal of Clinical Cases*, Jamir Pitton Rissardo, MD, Academic Research, Adjunct Associate Professor, Research Associate, Department of Medicine, Federal University of Santa Maria, Santa Maria 97105110, Brazil. jamirrissardo@gmail.com

AIMS AND SCOPE

The primary aim of *World Journal of Clinical Cases* (WJCC, *World J Clin Cases*) is to provide scholars and readers from various fields of clinical medicine with a platform to publish high-quality clinical research articles and communicate their research findings online.

WJCC mainly publishes articles reporting research results and findings obtained in the field of clinical medicine and covering a wide range of topics, including case control studies, retrospective cohort studies, retrospective studies, clinical trials studies, observational studies, prospective studies, randomized controlled trials, randomized clinical trials, systematic reviews, meta-analysis, and case reports.

INDEXING/ABSTRACTING

The WJCC is now indexed in Science Citation Index Expanded (also known as SciSearch®), Journal Citation Reports/Science Edition, Scopus, PubMed, and PubMed Central. The 2021 Edition of Journal Citation Reports® cites the 2020 impact factor (IF) for WJCC as 1.337; IF without journal self cites: 1.301; 5-year IF: 1.742; Journal Citation Indicator: 0.33; Ranking: 119 among 169 journals in medicine, general and internal; and Quartile category: Q3. The WJCC's CiteScore for 2020 is 0.8 and Scopus CiteScore rank 2020: General Medicine is 493/793.

RESPONSIBLE EDITORS FOR THIS ISSUE

Production Editor: Hua-Ge Yin, Production Department Director: Xu Guo, Editorial Office Director: Jin-Lei Wang.

NAME OF JOURNAL

World Journal of Clinical Cases

ISSN

ISSN 2307-8960 (online)

LAUNCH DATE

April 16, 2013

FREQUENCY

Thrice Monthly

EDITORS-IN-CHIEF

Bao-Gan Peng, Jerzy Tadeusz Chudek, George Kontogeorgos, Maurizio Serati, Ja Hyeon Ku

EDITORIAL BOARD MEMBERS

<https://www.wjgnet.com/2307-8960/editorialboard.htm>

PUBLICATION DATE

May 16, 2022

COPYRIGHT

© 2022 Baishideng Publishing Group Inc

INSTRUCTIONS TO AUTHORS

<https://www.wjgnet.com/bpg/gerinfo/204>

GUIDELINES FOR ETHICS DOCUMENTS

<https://www.wjgnet.com/bpg/GerInfo/287>

GUIDELINES FOR NON-NATIVE SPEAKERS OF ENGLISH

<https://www.wjgnet.com/bpg/gerinfo/240>

PUBLICATION ETHICS

<https://www.wjgnet.com/bpg/GerInfo/288>

PUBLICATION MISCONDUCT

<https://www.wjgnet.com/bpg/gerinfo/208>

ARTICLE PROCESSING CHARGE

<https://www.wjgnet.com/bpg/gerinfo/242>

STEPS FOR SUBMITTING MANUSCRIPTS

<https://www.wjgnet.com/bpg/GerInfo/239>

ONLINE SUBMISSION

<https://www.f6publishing.com>



PD-1 inhibitor in combination with fruquintinib therapy for initial unresectable colorectal cancer: A case report

Hong-Qiang Zhang, Chang-Zhi Huang, Jing-Yu Wu, Zhen-Ling Wang, Yu Shao, Zan Fu

Specialty type: Medicine, research and experimental

Provenance and peer review:

Unsolicited article; Externally peer reviewed.

Peer-review model: Single blind

Peer-review report's scientific quality classification

Grade A (Excellent): 0
Grade B (Very good): B
Grade C (Good): C, C, C
Grade D (Fair): D
Grade E (Poor): 0

P-Reviewer: Bhusal U, Nepal;
Jeong KY, South Korea; Tchilikidi KY, Russia; Vyshka G, Albania

Received: January 9, 2022

Peer-review started: January 9, 2022

First decision: February 21, 2022

Revised: March 3, 2022

Accepted: March 27, 2022

Article in press: March 27, 2022

Published online: May 16, 2022



Hong-Qiang Zhang, Chang-Zhi Huang, Jing-Yu Wu, Zhen-Ling Wang, Yu Shao, Zan Fu, Department of General Surgery, The First Affiliated Hospital of Nanjing Medical University, Nanjing 210029, Jiangsu Province, China

Corresponding author: Zan Fu, MD, Chief Doctor, Department of General Surgery, The First Affiliated Hospital of Nanjing Medical University, No. 300 Guangzhou Road, Nanjing 210029, Jiangsu Province, China. fuzan1971@njmu.edu.cn

Abstract

BACKGROUND

PD-1 inhibitors in combination with fruquintinib have not previously been reported as neoadjuvant therapy for patients with colorectal cancer. In this case report, the combination of a PD-1 inhibitor and fruquintinib demonstrated good efficacy in patients with MSI-H colorectal cancer.

CASE SUMMARY

The patient was a young man in his 30s who had MSI-H type colon cancer. The patient underwent four cycles of neoadjuvant therapy with a PD-1 inhibitor combined with fruquintinib before surgery, resulting in regression of the mass and a successful surgery.

CONCLUSION

Some patients with colorectal cancer have the MSI-H type, and the first-line chemotherapy regimen is not effective. However, PD-1 monoclonal antibody immunotherapy has a good therapeutic effect, which can be improved by combination therapy with fruquintinib. We recommend that patients with a history of colon or rectal cancer receive universal MSI testing; then, neoadjuvant therapy should be used.

Key Words: Colorectal cancer; Neoadjuvant; PD-1 inhibitors; Fruquintinib; MSI-H; Case report

©The Author(s) 2022. Published by Baishideng Publishing Group Inc. All rights reserved.

Core Tip: A 30-year-old man was diagnosed with microsatellite unstable colon cancer. Prior to his surgical treatment, he was treated with a neoadjuvant regimen of PD1 inhibitors in combination with fruquintinib. This neoadjuvant regimen is rarely used; however, this patient had a good outcome. Subsequently, we performed a laparoscopic radical resection of his right colon cancer, which revealed no microscopic tumour cells. The patient was in good condition after the surgical treatment.

Citation: Zhang HQ, Huang CZ, Wu JY, Wang ZL, Shao Y, Fu Z. PD-1 inhibitor in combination with fruquintinib therapy for initial unresectable colorectal cancer: A case report. *World J Clin Cases* 2022; 10(14): 4669-4675

URL: <https://www.wjgnet.com/2307-8960/full/v10/i14/4669.htm>

DOI: <https://dx.doi.org/10.12998/wjcc.v10.i14.4669>

INTRODUCTION

Colorectal cancer is the third most common malignancy worldwide, and MSI-H is present in approximately 15% of colorectal cancers[1]. Microsatellites are short tandem repeats throughout the human genome, with single nucleotide, double nucleotide or high nucleotide repeats that are comprised of 10-50 repeats. Changes in the microsatellite length that result from the insertion or deletion of repeating units in tumour cells (rather than normal cells) are called microsatellite instability. A large number of studies have shown that MSI is caused by defects in mismatch repair (MMR) genes, which are closely related to the occurrence of tumours. MSI has been clinically used as a molecular marker for the prognosis and adjuvant treatment of colorectal cancer and other solid tumours[2].

Most patients with microsatellite instability colorectal cancer develop resistance to first-line chemotherapy when having a longer course of treatment. After its successful application in the treatment of melanomas, immunotherapy has been actively explored in different types of solid cancers, including colorectal cancer. PD-1 inhibitors have been shown to be effective in the MSI-H subtypes that are associated with mismatch repair defects in patients with metastatic colorectal cancer (CRC). Immunotherapy can allow for long-term remission in a subset of patients with metastatic CRC[3]. The latest guidelines also recommend pembrolizumab or nivolumab as first-line treatment options for patients with MSI-H CRC[2].

For patients with CRC who have failed to receive standard first-line and second-line treatments, the third-line treatment consists of regorafenib, fruquintinib, and TAS-102[4]. Clinical studies have shown that antiangiogenic drugs combined with an immune checkpoint blockade can significantly improve the effectiveness of the malignant tumour treatments[5-8]. In addition, patients with MSI-H colorectal cancer are characterized by high VEGF expression, which can be inhibited by fruquintinib. In this case, the combination of fruquintinib resulted in a better efficacy of the neoadjuvant therapy.

CASE PRESENTATION

Chief complaints

A 30-year-old man had an increased stool frequency and unformed stool over a year.

History of present illness

One year ago, the patient had an increased stool frequency without any obvious inciting cause, and his stool properties had changed. He had abdominal distension for 2 mo prior to presentation, and his stools were loose and unformed 3 to 4 times a day. On May 26, 2021, the patient underwent a colonoscopy. The colonoscopy found that the patient had a mass that was approximately 60 cm away from the anus. Pathology showed severe atypical hyperplasia and adenocarcinoma in parts of the glandular epithelium (Figure 1 and Table 1).

History of past illness

The patient's previous medical history was free of disease.

Personal and family history

The patient's personal and family history was free of disease.

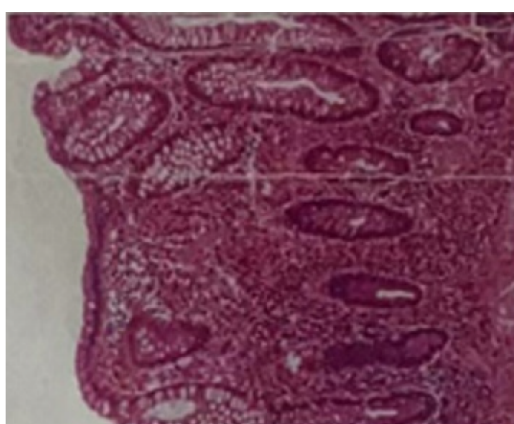
Physical examination

The patient's vital signs were as follows: his temperature was 36.5 °C, his heart rate was 78 bpm, his respiratory rate was 17 breaths per minute, and his blood pressure was 121/84 mmHg. His abdomen was flat and soft, there were no gastrointestinal peristaltic waves, and he had no abdominal varicose

Table 1 Organization of the case into a timeline

Date	[T]/[S]/[E]
May, 2021	[E] Colonoscopy, pathological examination, Abdominal CT examination
June, 2021	[E] The evaluation of three tumour markers in the serum (AFP, CEA, CA199), Faecal occult blood test; [T] Four cycles of immunotherapy (paprizumab+ fruquintinib)
July, 2021	[E] Abdominal CT examination
September, 2021	[E] Abdominal CT examination
October, 2021	[T] Radical resection of the right colon cancer; [E] Pathologic evaluation of the posttreatment tumour regression after neoadjuvant therapy; [S] The patient's general appearance had improved; the patient was discharged smoothly
November, 2021	[E] An abdominal CT was re-evaluated after surgery

[T]: Treatment; [S]: Symptoms; [E]: Examination; CT: Computed tomography.



DOI: 10.12998/wjcc.v10.i14.4669 Copyright ©The Author(s) 2022.

Figure 1 The pathology before neoadjuvant therapy. Magnification × 100.

and no tenderness or rebound pain in any part of his abdomen. He did not have any abdominal muscle tension, or any pain in his liver, spleen or ribs, no obvious masses were detected, and Murphy's sign was negative. The test for shifting dullness was negative, no percussion pain was present in the area of the liver or in the areas of either of his kidneys, and his bowel sounds were heard at a frequency of 4 times/min. A digital rectal examination showed no obvious abnormalities.

Laboratory examinations

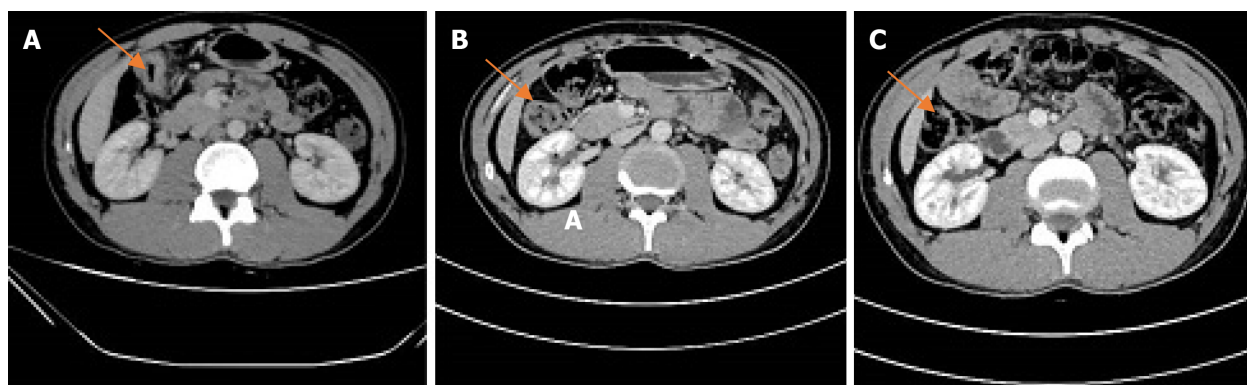
CEA 3.23 ng/mL, faecal occult blood test (+).

Imaging examinations

2021-05 Whole abdominal computed tomography (CT): The intestinal wall at the hepatic curvature of the colon was significantly thickened with enhancement, the surrounding fat space was blurred, and the adjacent lymph nodes were enlarged (Figure 2A). Enlarged lymph nodes were found beside the abdominal aorta and were approximately 1 cm in size (Figure 3A). It was recommended that an abnormal density of the left liver lobe be further evaluated.

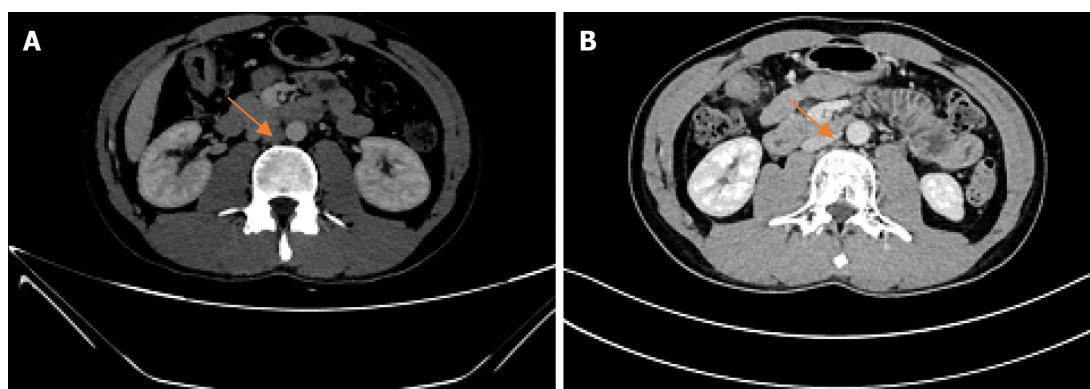
FINAL DIAGNOSIS

The final diagnosis was a hepatic flexure tumour of the colon.



DOI: 10.12998/wjcc.v10.i14.4669 Copyright ©The Author(s) 2022.

Figure 2 Computed tomography images of the patient (Colon hepatic flexure). A: On the first abdominal computed tomography (CT) examination (2021-05), the intestinal wall at the hepatic curvature of the colon was significantly thickened with enhancement, the surrounding fat space was blurred, and the adjacent lymph nodes were enlarged; B: Abdominal CT examination (2021-07). The range of colonic lesions was reduced, and the surrounding lymph nodes were reduced; C: Abdominal CT examination (2021-09); the results showed improvement compared to the previous imaging results.



DOI: 10.12998/wjcc.v10.i14.4669 Copyright ©The Author(s) 2022.

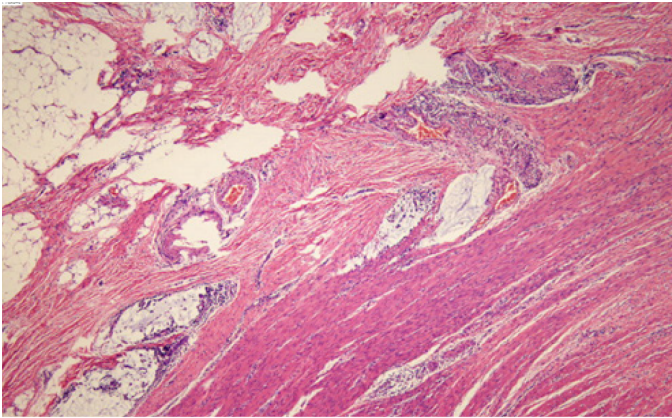
Figure 3 Computed tomography images of the patient (para-aortic lymph nodes). A: Abdominal computed tomography (CT) examination (2021-05), enlarged lymph nodes beside the abdominal aorta; B: Abdominal CT examination (2021-07). The para-aortic lymph nodes were smaller than before.

TREATMENT

Considering the results of the relevant examinations, the patient's tumour had a high degree of malignancy. We decided to treat him with neoadjuvant therapy to decrease the size of the mass, reduce the stage of the tumour, and improve the complete resection rate, instead of going straight to surgery. After the exclusion of contraindications, the patient received the first cycle of the "PD-1 inhibitor (Paprizumab) 200 mg DL + Fruquintinib 1# Po QD DL -- 21" from 2021-06, and the process went smoothly without any complaints of discomfort from the patient.

Another abdominal CT was obtained on 2021-07. The range of the colonic lesions and the surrounding lymph nodes were reduced (Figure 2B). The para-aortic lymph nodes were smaller than before, with a reduction in size from 1 cm to 0.5 cm (Figure 3B). Abdominal CT (2021-09) showed further shrinkage of the colonic lesion (Figure 2C).

After 4 cycles of PD1+ fruquintinib treatment, the patient was admitted to the Department of Colorectal Surgery on 2021-10 for a radical colon cancer resection. Radical resection of a right colon cancer occurred on 2021-10. Laparoscopic examination showed that after the patient received neoadjuvant chemotherapy for the colon cancer, the tumour was located in the hepatic curvature of the transverse colon and did not invade the serous membrane, so a laparoscopic CME was planned. The operation went smoothly, the bleeding was minimal, the patient's vital signs were stable, and the postoperative specimens were sent out for examination. The pathologic evaluation of the posttreatment tumour regression (TRG) after neoadjuvant therapy showed a complete regression microscopically; no tumour cells were visible; and there were only a few mucous lakes that were infiltrating below the serosal membrane (Figure 4).



DOI: 10.12998/wjcc.v10.i14.4669 Copyright ©The Author(s) 2022.

Figure 4 Haematoxylin-eosin staining and immunohistochemistry staining of the colon cancer tissue specimens. Pathology after the neoadjuvant therapy. Magnification × 100.

OUTCOME AND FOLLOW-UP

Postoperative immunomodulatory, anti-inflammatory, anti-venous thrombosis, nutritional and other treatments were provided to the patient. The patient's symptoms improved, and no special complaints of discomfort or general conditions were observed. The patient was successfully discharged 7 d after surgery. A postoperative abdominal CT (2021-11) showed that a metal suture shadow was present in the operative area, and no obvious mass shadow or abnormal enhancement was observed in the anastomosis (Figure 5).

DISCUSSION

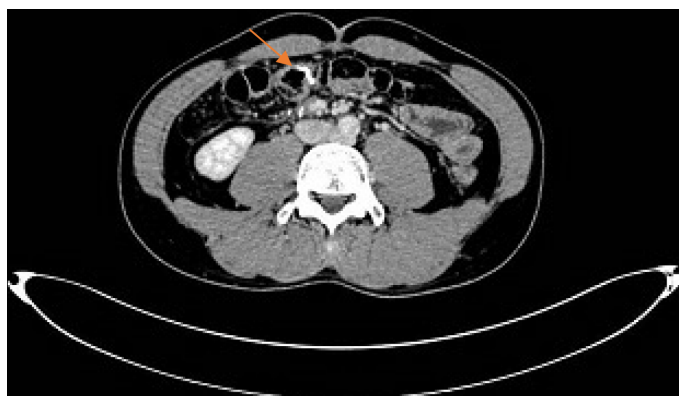In this case report, the neoadjuvant therapy for colon cancer included a combination of a PD-1 inhibitor and fruquintinib, which is a third-line treatment for colorectal cancer. PD1 inhibitors have fewer side effects than the existing neoadjuvant therapies, such as FOLFIRI, FOLFOX or CAPOX. The chemotherapeutic drugs of the previous regimen, such as capecitabine and oxaliplatin, can cause gastrointestinal reactions and abnormalities in the blood cell counts. Patients are also less likely to develop resistance to PD1 inhibitors. The patient was very responsive to immunotherapy and had excellent results.

The main treatment mode of microsatellite instability in colorectal cancer is immunomonootherapy. However, the current response rate of immunomonootherapy is only 60%. Immunomonootherapy combined with antiangiogenic drugs is an important method to improve the treatment efficacy. A study showed[9] that, compared with monotherapy, combination therapy could significantly inhibit tumour growth and could prolong the survival time of mice. In addition, fruquintinib combined with anti-PD-1 therapy reduced angiogenesis, enhanced the normalization of the vascular structure, and alleviated the tumour hypoxia. In addition, combination therapy reprogrammed the immune microenvironment by enhancing the release of chemokines, increasing the infiltration and activation of CD8+ T cells, decreasing the proportion of regulatory T cells, and increasing the proportion of M1/M2 macrophages. Therefore, a combination therapy that is comprised of PD1 inhibitors and antiangiogenic therapy is needed.

Regular CT examination also played an important role in observing the efficacy of the neoadjuvant therapy in this case. CT showed that there was a progressive regression of the intestinal masses after the neoadjuvant therapy. This also suggests that the examination of intestinal masses is convenient and intuitive, and people with a family history of this condition should undergo early screening with abdominal imaging examinations or colonoscopies, as well as regular screening.

It is also worth noting that the patient was in his 30 s, and this young of a patient has been very rare in previous studies. Is age a factor affecting the efficacy of immunotherapy? Are young people more resistant to PD1 inhibitors and drug combinations, such as fruquintinib? Further research is needed.

According to the NCCN guidelines for colon cancer (<https://www.nccn.org/>), it is recommended that all patients with a personal history of colon or rectal cancer undergo universal MMR or MSI testing [10]. After the test is completed, an appropriate treatment plan can be developed according to the results. For patients with colorectal cancer who have the opportunity to undergo surgery, preoperative neoadjuvant therapy is helpful for mass retraction and symptom relief and is conducive to the implementation of later surgery. Surgical treatment of colorectal tumours is still the most important treatment method, and neoadjuvant therapy is of great benefit prior to surgery. For example, in patients with rectal cancer who originally did not have anal preservation after neoadjuvant therapy, their masses



DOI: 10.12998/wjcc.v10.i14.4669 Copyright ©The Author(s) 2022.

Figure 5 Abdominal computed tomography examination (2021-11): Postoperative review showed no evidence of recurrence.

had retreated, the distances between the lower edges of the mass and the anus had increased, and there was a chance to retain the anuses in these patients[11].

CONCLUSION

To our knowledge, PD-1 inhibitors in combination with fruquintinib have not previously been reported as a neoadjuvant therapy option in patients with colorectal cancer. This case report suggests that immunotherapy has a significant effect on microsatellite unstable colorectal cancer patients and that combining it with antiangiogenic drugs can improve the treatment efficacy. It is of great importance to improve relevant examinations, specify appropriate neoadjuvant therapy and combine medical treatment with surgical treatment in these patients.

ACKNOWLEDGEMENTS

We thank Sun J, MD (Department of Oncology, The First Affiliated Hospital of Nanjing Medical University, Nanjing, Jiangsu Province, China).

FOOTNOTES

Author contributions: Zhang HQ designed the writing ideas and wrote the manuscript; Huang CZ participated in the operation of the patient as an assistant and made important modifications to the manuscript; Wu JY, Wang ZL, and Shao Y collected patient's data and followed the patient; Fu Z performed the surgery and developed the patient's treatment plan; all authors have read and approved the final manuscript.

Informed consent statement: Written informed consent was obtained from the patient for publication of this report and any accompanying images.

Conflict-of-interest statement: The authors declare that they have no conflicts of interest.

CARE Checklist (2016) statement: The authors have read the CARE Checklist (2016), and the manuscript was prepared and revised according to the CARE Checklist (2016).

Open-Access: This article is an open-access article that was selected by an in-house editor and fully peer-reviewed by external reviewers. It is distributed in accordance with the Creative Commons Attribution NonCommercial (CC BY-NC 4.0) license, which permits others to distribute, remix, adapt, build upon this work non-commercially, and license their derivative works on different terms, provided the original work is properly cited and the use is non-commercial. See: <https://creativecommons.org/licenses/by-nc/4.0/>

Country/Territory of origin: China

ORCID number: Hong-Qiang Zhang 0000-0002-7410-6911; Chang-Zhi Huang 0000-0003-2620-9817; Jing-Yu Wu 0000-0001-9366-5906; Zhen-Ling Wang 0000-0002-6834-8607; Yu Shao 0000-0001-8718-3193; Zan Fu 0000-0003-4753-1821.

S-Editor: Wang LL

L-Editor: A

P-Editor: Wang LL

REFERENCES

- 1 **Goldstein J**, Tran B, Ensor J, Gibbs P, Wong HL, Wong SF, Vilar E, Tie J, Broaddus R, Kopetz S, Desai J, Overman MJ. Multicenter retrospective analysis of metastatic colorectal cancer (CRC) with high-level microsatellite instability (MSI-H). *Ann Oncol* 2014; **25**: 1032-1038 [PMID: [24585723](#) DOI: [10.1093/annonc/mdl100](#)]
- 2 **Benson AB**, Venook AP, Al-Hawary MM, Arain MA, Chen YJ, Ciombor KK, Cohen S, Cooper HS, Deming D, Farkas L, Garrido-Laguna I, Grem JL, Gunn A, Hecht JR, Hoffe S, Hubbard J, Hunt S, Johung KL, Kirilcuk N, Krishnamurthi S, Messersmith WA, Meyerhardt J, Miller ED, Mulcahy MF, Nurkin S, Overman MJ, Parikh A, Patel H, Pedersen K, Saltz L, Schneider C, Shibata D, Skibber JM, Sofocleous CT, Stoffel EM, Stotsky-Himelfarb E, Willett CG, Gregory KM, Gurski LA. Colon Cancer, Version 2.2021, NCCN Clinical Practice Guidelines in Oncology. *J Natl Compr Canc Netw* 2021; **19**: 329-359 [PMID: [33724754](#) DOI: [10.6004/jnccn.2021.0012](#)]
- 3 **Kishore C**, Bhadra P. Current advancements and future perspectives of immunotherapy in colorectal cancer research. *Eur J Pharmacol* 2021; **893**: 173819 [PMID: [33347822](#) DOI: [10.1016/j.ejphar.2020.173819](#)]
- 4 **Dhillon S**. Regorafenib: A Review in Metastatic Colorectal Cancer. *Drugs* 2018; **78**: 1133-1144 [PMID: [29943375](#) DOI: [10.1007/s40265-018-0938-y](#)]
- 5 **Hodi FS**, Lawrence D, Lezcano C, Wu X, Zhou J, Sasada T, Zeng W, Giobbie-Hurder A, Atkins MB, Ibrahim N, Friedlander P, Flaherty KT, Murphy GF, Rodig S, Velazquez EF, Mihm MC Jr, Russell S, DiPiro PJ, Yap JT, Ramaiya N, Van den Abbeele AD, Gargano M, McDermott D. Bevacizumab plus ipilimumab in patients with metastatic melanoma. *Cancer Immunol Res* 2014; **2**: 632-642 [PMID: [24838938](#) DOI: [10.1158/2326-6066.CIR-14-0053](#)]
- 6 **Konecny GE**. Inhibition of PD-1 and VEGF in microsatellite-stable endometrial cancer. *Lancet Oncol* 2019; **20**: 612-614 [PMID: [30922730](#) DOI: [10.1016/S1470-2045\(19\)30079-8](#)]
- 7 **Shigeta K**, Datta M, Hato T, Kitahara S, Chen IX, Matsui A, Kikuchi H, Mamessier E, Aoki S, Ramjiawan RR, Ochiai H, Bardeesy N, Huang P, Cobbold M, Zhu AX, Jain RK, Duda DG. Dual Programmed Death Receptor-1 and Vascular Endothelial Growth Factor Receptor-2 Blockade Promotes Vascular Normalization and Enhances Antitumor Immune Responses in Hepatocellular Carcinoma. *Hepatology* 2020; **71**: 1247-1261 [PMID: [31378984](#) DOI: [10.1002/hep.30889](#)]
- 8 **Zhao S**, Ren S, Jiang T, Zhu B, Li X, Zhao C, Jia Y, Shi J, Zhang L, Liu X, Qiao M, Chen X, Su C, Yu H, Zhou C, Zhang J, Camidge DR, Hirsch FR. Low-Dose Apatinib Optimizes Tumor Microenvironment and Potentiates Antitumor Effect of PD-1/PD-L1 Blockade in Lung Cancer. *Cancer Immunol Res* 2019; **7**: 630-643 [PMID: [30755403](#) DOI: [10.1158/2326-6066.CIR-17-0640](#)]
- 9 **Wang Y**, Wei B, Gao J, Cai X, Xu L, Zhong H, Wang B, Sun Y, Guo W, Xu Q, Gu Y. Combination of Fruquintinib and Anti-PD-1 for the Treatment of Colorectal Cancer. *J Immunol* 2020; **205**: 2905-2915 [PMID: [33028620](#) DOI: [10.4049/jimmunol.2000463](#)]
- 10 **Cui S**, Zhang X, Zou R, Ye F, Wang Y, Sun J. MLH1 Exon 12 Gene Deletion Leading to Lynch Syndrome: A Case Report. *Oncol Res Treat* 2021; **44**: 414-421 [PMID: [34091457](#) DOI: [10.1159/000516659](#)]
- 11 **Hata T**, Takahashi H, Sakai D, Haraguchi N, Nishimura J, Kudo T, Chu M, Takemasa I, Taroh S, Mizushima T, Doki Y, Mori M. Neoadjuvant CapeOx therapy followed by sphincter-preserving surgery for lower rectal cancer. *Surg Today* 2017; **47**: 1372-1377 [PMID: [28474202](#) DOI: [10.1007/s00595-017-1527-5](#)]



Published by **Baishideng Publishing Group Inc**
7041 Koll Center Parkway, Suite 160, Pleasanton, CA 94566, USA

Telephone: +1-925-3991568

E-mail: bpgoffice@wjgnet.com

Help Desk: <https://www.f6publishing.com/helpdesk>

<https://www.wjgnet.com>

