

World Journal of *Clinical Pediatrics*

World J Clin Pediatr 2022 July 9; 11(4): 321-384



MINIREVIEWS

- 321 Hereditary fructose intolerance: A comprehensive review
Singh SK, Sarma MS

ORIGINAL ARTICLE**Case Control Study**

- 330 Effects of adherence to the Mediterranean diet in children and adolescents with irritable bowel syndrome
Al-Biltagi M, El Amrousy D, El Ashry H, Maher S, Mohammed MA, Hasan S

Retrospective Study

- 341 Prevalence, phenotype and medication for the pediatric inflammatory bowel disease population of a state in Southeastern Brazil
Martins AL, Fróes RSB, Zago-Gomes MP
- 351 Frequency of celiac disease and distribution of HLA-DQ2/DQ8 haplotypes among siblings of children with celiac disease
Sahin Y, Mermer S

Observational Study

- 360 Adipocytokine profile in children with Kawasaki disease at a mean follow-up period of 5.5 years: A study from North India
Praharaj DL, Rawat A, Gupta A, Arora K, Piloni RK, Bhattad S, Singh S
- 369 Children with lysinuric protein intolerance: Experience from a lower middle income country
Hashmi SB, Ahmed S

SYSTEMATIC REVIEWS

- 375 Impact of sports participation on cardiovascular health markers of children and adolescents: Systematic review and meta-analysis
Torres W, Maillane-Vanegas S, Urban JB, Fernandes RA

ABOUT COVER

Editorial Board Member of *World Journal of Clinical Pediatrics*, Setila Dalili, MD, Associate Professor, Department of Pediatric Endocrinology, Pediatric Diseases Research Center, 17 Shahrivar Hospital, Guilan University of Medical Sciences, Iran, Siadati Street, Rasht, Iran. setiladalili1346@yahoo.com

AIMS AND SCOPE

The primary aim of the *World Journal of Clinical Pediatrics* (WJCP, *World J Clin Pediatr*) is to provide scholars and readers from various fields of pediatrics with a platform to publish high-quality clinical research articles and communicate their research findings online.

WJCP mainly publishes articles reporting research results and findings obtained in the field of pediatrics and covering a wide range of topics including anesthesiology, cardiology, endocrinology, gastroenterology, hematology, immunology, infections and infectious diseases, medical imaging, neonatology, nephrology, neurosurgery, nursing medicine, perinatology, pharmacology, respiratory medicine, and urology.

INDEXING/ABSTRACTING

The WJCP is now abstracted and indexed in PubMed, PubMed Central, Scopus, Reference Citation Analysis, China National Knowledge Infrastructure, China Science and Technology Journal Database, and Superstar Journals Database.

RESPONSIBLE EDITORS FOR THIS ISSUE

Production Editor: Wen-Wen Qi; Production Department Director: Xu Guo; Editorial Office Director: Yu-Jie Ma.

NAME OF JOURNAL

World Journal of Clinical Pediatrics

ISSN

ISSN 2219-2808 (online)

LAUNCH DATE

June 8, 2012

FREQUENCY

Bimonthly

EDITORS-IN-CHIEF

Toru Watanabe, Consolato M Sergi, Elena Daniela Serban, Surjit Singh

EDITORIAL BOARD MEMBERS

<https://www.wjgnet.com/2219-2808/editorialboard.htm>

PUBLICATION DATE

July 9, 2022

COPYRIGHT

© 2022 Baishideng Publishing Group Inc

INSTRUCTIONS TO AUTHORS

<https://www.wjgnet.com/bpg/gerinfo/204>

GUIDELINES FOR ETHICS DOCUMENTS

<https://www.wjgnet.com/bpg/gerinfo/287>

GUIDELINES FOR NON-NATIVE SPEAKERS OF ENGLISH

<https://www.wjgnet.com/bpg/gerinfo/240>

PUBLICATION ETHICS

<https://www.wjgnet.com/bpg/gerinfo/288>

PUBLICATION MISCONDUCT

<https://www.wjgnet.com/bpg/gerinfo/208>

ARTICLE PROCESSING CHARGE

<https://www.wjgnet.com/bpg/gerinfo/242>

STEPS FOR SUBMITTING MANUSCRIPTS

<https://www.wjgnet.com/bpg/gerinfo/239>

ONLINE SUBMISSION

<https://www.f6publishing.com>

Hereditary fructose intolerance: A comprehensive review

Sumit Kumar Singh, Moinak Sen Sarma

Specialty type: Gastroenterology and hepatology

Provenance and peer review: Invited article; Externally peer reviewed.

Peer-review model: Single blind

Peer-review report's scientific quality classification

Grade A (Excellent): 0
Grade B (Very good): 0
Grade C (Good): 0
Grade D (Fair): 0
Grade E (Poor): 0

P-Reviewer: Barone M, Italy

A-Editor: Wang JL, United States

Received: November 27, 2021

Peer-review started: November 27, 2021

First decision: April 13, 2022

Revised: May 8, 2022

Accepted: June 20, 2022

Article in press: June 20, 2022

Published online: July 9, 2022



Sumit Kumar Singh, Department of Pediatrics, Sri Aurobindo Medical College and PGI, Indore 453555, Madhya Pradesh, India

Moinak Sen Sarma, Department of Pediatric Gastroenterology, Sanjay Gandhi Postgraduate Institute of Medical Sciences, Lucknow 226014, India

Corresponding author: Moinak Sen Sarma, MD, Associate Professor, Department of Pediatric Gastroenterology, Sanjay Gandhi Postgraduate Institute of Medical Sciences, Raebareli Road, Lucknow 226014, India. moinaksen@yahoo.com

Abstract

Hereditary fructose intolerance (HFI) is a rare autosomal recessive inherited disorder that occurs due to the mutation of enzyme aldolase B located on chromosome 9q22.3. A fructose load leads to the rapid accumulation of fructose 1-phosphate and manifests with its downstream effects. Most commonly children are affected with gastrointestinal symptoms, feeding issues, aversion to sweets and hypoglycemia. Liver manifestations include an asymptomatic increase of transaminases, steatohepatitis and rarely liver failure. Renal involvement usually occurs in the form of proximal renal tubular acidosis and may lead to chronic renal insufficiency. For confirmation, a genetic test is favored over the measurement of aldolase B activity in the liver biopsy specimen. The crux of HFI management lies in the absolute avoidance of foods containing fructose, sucrose, and sorbitol (FSS). There are many dilemmas regarding tolerance, dietary restriction and occurrence of steatohepatitis. Patients with HFI who adhere strictly to FSS free diet have an excellent prognosis with a normal lifespan. This review attempts to increase awareness and provide a comprehensive review of this rare but treatable disorder.

Key Words: Hereditary; Fructose; Intolerance; Children; Liver; Steatohepatitis; Aldolase

©The Author(s) 2022. Published by Baishideng Publishing Group Inc. All rights reserved.

Core Tip: Hereditary Fructose Intolerance is a rare autosomal recessive inherited disorder due to the mutation of enzyme aldolase B. Awareness regarding its diverse manifestations is required to clinically suspect and diagnose this condition. Genetic testing clinches the diagnosis. Treatment is simple and involves only the dietary exclusion of fructose, sucrose and sorbitol. The prognosis is favourable. This review provides a comprehensive understanding of the disease.

Citation: Singh SK, Sarma MS. Hereditary fructose intolerance: A comprehensive review. *World J Clin Pediatr* 2022; 11(4): 321-329

URL: <https://www.wjgnet.com/2219-2808/full/v11/i4/321.htm>

DOI: <https://dx.doi.org/10.5409/wjcp.v11.i4.321>

INTRODUCTION

Fructose is a monosaccharide found in honey, fruits and many vegetables consumed daily. It is also the component of the main sweetening agent, sucrose in the majority of sweets and syrups. Small amounts of fructose are also produced in the human brain *via* the polyol pathway[1]. After ingestion, fructose is absorbed from the intestine through glucose transport proteins (GLUT) 5 and 2[2]. Subsequent metabolism is carried out predominantly in the liver, kidney and small intestine by the enzymes fructokinase, aldolase B, and triokinase[3]. Hereditary fructose intolerance (HFI) is a pathological condition that occurs due to a deficiency of enzyme aldolase B[3]. It is characterized by hypoglycemia, lactic acidosis, hypophosphatemia, hyperuricemia, hypermagnesemia and hyperalanemia due to dysregulation of gluconeogenesis, glycogenolysis and decreased inorganic phosphate[4].

EPIDEMIOLOGY AND GENETICS

HFI is a rare autosomal recessive inherited disorder with an estimated population prevalence ranging from 1 in 20000 to 1 in 60000[5]. There is no sex predilection. The gene for the enzyme aldolase B (ALDOB) is located on chromosome 9q22.3. Mutational aberrations include simple missense mutations, deletions, frameshift mutations, and mutations at splicing sites. A systemic review was conducted to assess *ALDOB* gene variants among patients with HFI[6]. The prevalence of HFI was estimated from the carrier frequency of variants described in patients, as well as rare variants predicted as pathogenic by *in silico* tools. *In silico* predictive software allows assessing the effect of amino acid substitutions on the structure or function of a protein without conducting functional studies[7]. The application of *in silico* tools can significantly improve the detection of genes and variation[8]. The studies included in the systematic review described 1426 alleles involved in the pathogenesis of HFI, spread in 29 countries on four continents[6]. 68 variants in *ALDOB* were identified among patients with HFI distributed in different populations. These variants were detected in 85 different genotypic combinations. Most of the mutations described in patients with HFI are restricted to a single ethnic group. The commonest variants distributed worldwide that account for most of the identified cases are: NM_000035_3:c.178C>T, NP_000026.2:p.(Arg60Ter); NM_000035_3:c.360_363del, NP_000026.2:p.(Asn120LysfsTer32); NM_000035_3:c.448G>C, NP_000026.2:p.(Ala150Pro); NM_000035_3:c.524C>A, NP_000026.2:p.(Ala175Asp) and NM_000035_3:c.1005C>G, NP_000026.2:p.(Asn335Lys). The analyses showed that the variants p.(Ala150Pro) and p.(Ala175Asp) are the most frequent in patients, accounting for approximately 68% of the alleles. The p.(Ala150Pro) variant alone accounts for 53% of all alleles identified worldwide, and has a variable frequency between the different geographic regions. p.(Asn120LysfsTer32) variant is the third most frequent (4.6%)[9-11]. Five novel mutations, (c.324+1G>A, c.112+1delG, c.380-1G>A, c.677G>A, and c.689delA) have been reported from an Indian community[12].

PATHOGENESIS

It carries out the reversible conversion of fructose 1-phosphate (F-1P) to glyceraldehyde (GAH) and dihydroxyacetone phosphate (DHAP) as shown in (Figure 1). Aldolase B also plays a role in gluconeogenesis and glycolytic pathways as it catalyzes fructose 1,6-bisphosphate (F-1,6P2) conversion to DHAP and glyceraldehyde 3-phosphate (G3P) in a reversible manner (Figure 1). There are two other isoenzymes, aldolase A (predominantly expressed in skeletal muscle and red blood cells) and aldolase C (predominantly expressed in brain and smooth muscle) and both have a high affinity for F-1,6-P2 as a substrate[13]. The deficiency of aldolase A manifests mainly as recurrent rhabdomyolysis which may sometimes be accompanied by hemolysis and termed glycogen storage disorder type 12[14,15]. Aldolase C expression has been found to be associated with certain neuroendocrine tumors and is being studied as a marker of neuroendocrine tumors[16].

Metabolic consequences

In a patient with HFI, a fructose load leads to the rapid accumulation of F-1P which results in depletion of intracellular inorganic phosphate (Pi) and adenosine triphosphate (ATP). As a result, adenosine 5'-monophosphate (AMP) degradation is increased, and hence, inosine monophosphate (IMP) and urate

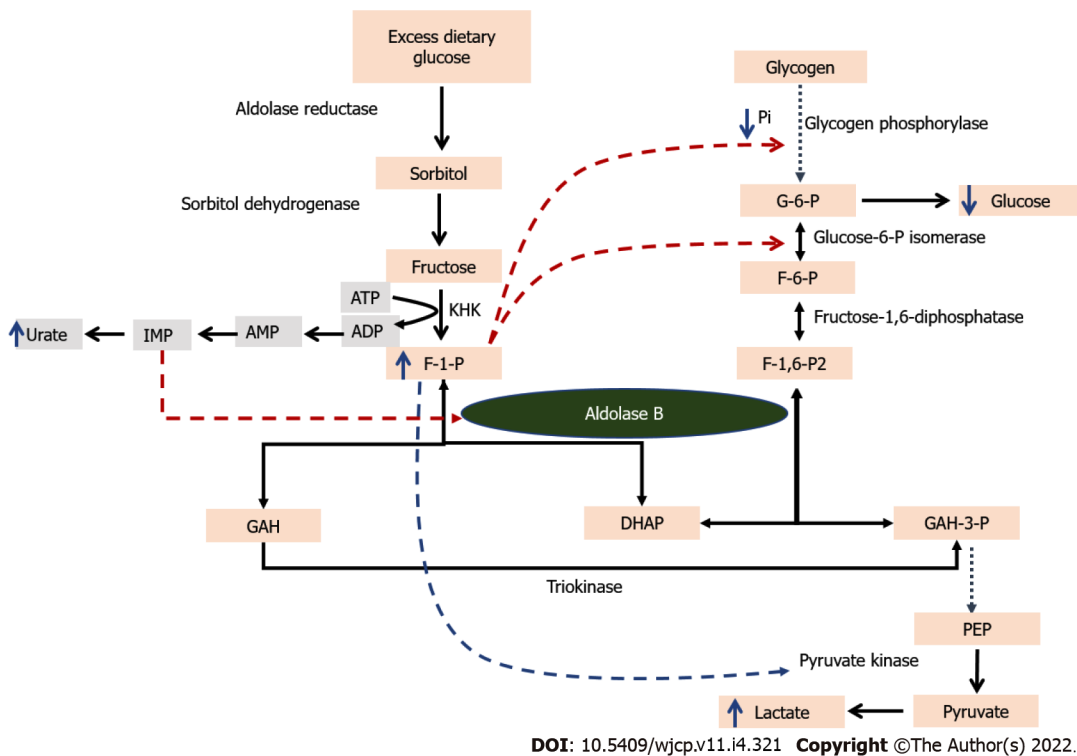


Figure 1 illustrates the pathway of fructose metabolism. Fructose is converted by ketohexokinase to F-1P that acts as substrate for Aldolase B which forms dihydroxyacetone phosphate (DHAP) and glyceraldehyde (GAH) that enter the glycolytic/gluconeogenic pathways. Aldolase B also catalyzes the reversible conversion of F-1,6P2 to DHAP and GAH-3P. Accumulation of F-1P leads to inhibition of glucose -6 P isomerase and along with depletion of inorganic phosphate, inhibits glycogen phosphorylase (red broken line). Similarly, increased IMP inhibits any residual Aldolase B activity if present. F-1P also activated PK which promotes lactic acid production. ADP: Adenosine diphosphate; AMP: adenosine monophosphate; ATP: adenosine triphosphate; DHAP: dihydroxyacetone phosphate; F-6P: Fructose 6-phosphate; F-1P: Fructose 1-phosphate; F-1,6-P2: Fructose 1,6-biphosphate; G-6P: glucose 6-phosphate, GAH glyceraldehyde; GAH-3P: Glyceraldehyde 3-phosphate; IMP: inosine monophosphate; KHK: Ketohexokinase; PEP: Phosphoenolpyruvate; Pi: Inorganic phosphate; PK: Pyruvate kinase.

are generated rapidly resulting in hyperuricemia which is responsible for gout in patients with HFI (Figure 1). Increased IMP through specific inhibition of aldolase B creates a vicious cycle leading to a further increase in F-1P. Depletion of ATP also results in increased release of magnesium as well as impaired protein synthesis and ultrastructural lesions which are responsible for hepatic and renal dysfunction. The consequences of increased F-1P are shown in Figure 2.

Increased F-1P along with reduced Pi is also responsible for inhibition of glycogenolysis through impairment of glycogen phosphorylase. This fructose-induced hypoglycemia in HFI is not corrected by the administration of exogenous glucagon which again emphasizes the impaired glycogenolysis pathway. Further, the accumulation of F-1P impedes gluconeogenesis by inhibition of glucose-6-phosphate isomerase (G6PI) (Figure 1). Overall, when a patient with HFI is given a fructose load, it leads to hypoglycemia due to deranged gluconeogenesis and glycogenolysis. In addition, lactic acidosis occurs due to activation of glycolytic pathway through increased activity of pyruvate kinase by F-1P and inability of aldolase B to convert DHAP and G3P to F-1,6P2. Notably, the metabolic consequences of fructose load also occur after ingestion of sorbitol found in various syrups and those with high glycemic foods such as rice. Sorbitol, through polyol pathways, is responsible for the endogenous production of fructose (Figure 1)[1].

CLINICAL FEATURES

The genotype-phenotype correlation has not been identified in patients with HFI. Patients with HFI develop symptoms only when exposed to dietary fructose directly or indirectly through sucrose or sorbitol. The classical presentation is described as an infant, otherwise healthy, presenting with nausea, protracted vomiting, poor feeding and lethargy and sometimes with seizures following the introduction of weaning foods containing sugar or starch[17]. Li *et al*[18] reported four cases of neonatal and early infantile acute liver failure associated with multi-organ failure induced by sucrose-containing common infant formula in patients with undiagnosed HFI. All patients were appropriately grown, born at term after uncomplicated pregnancies and deliveries, and discharged within the first week of life. There was no known consanguinity. One patient had a family history of an older brother who died on day 28 of life with a similar illness, though a specific diagnosis could not be ascertained. Another patient had a

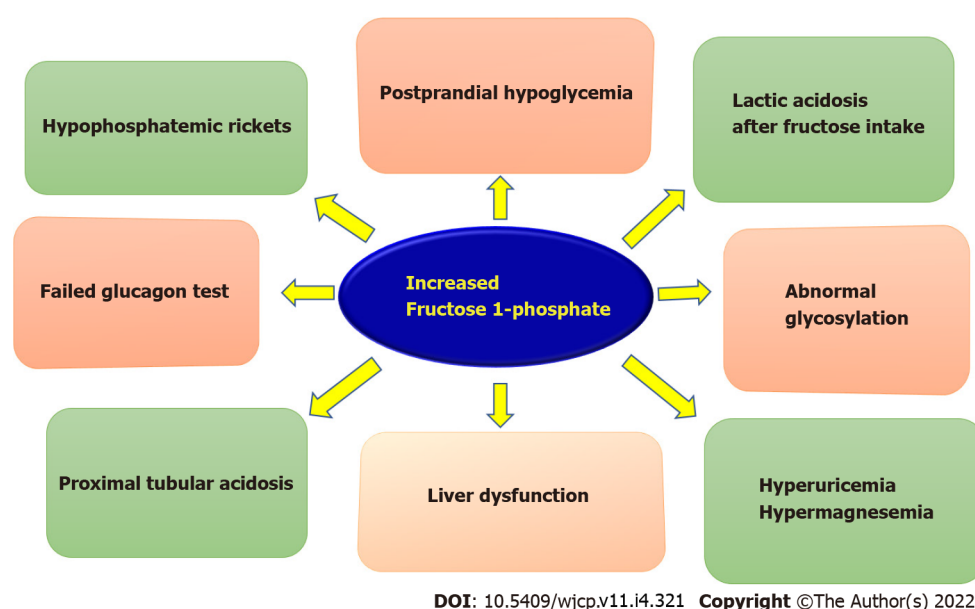


Figure 2 Illustrates the consequences of hereditary fructose intolerance.

maternal half-sister who required a liver transplant for an indeterminate liver failure. Careful dietary history was obtained in all infants, though fructose exposure was unclear in two of the 4 cases due to unreliable history or unclear ingredient labelling, which delayed diagnosis. In all four cases, the newborn screen was normal. The diagnosis was confirmed by ALDOB gene sequencing. All infants were homozygous for the common c.448G>C (p.A150P) pathogenic variant[19]. Sometimes, it may present late in childhood or adulthood owing to the self-imposed strict dietary restriction of fructose-containing food items[19,20]. The child shows a strong aversion to sweets.

An intermittent dietary restriction can have a subtle presentation in the form of isolated hepatomegaly or intermittent elevations in transaminases[21]. Thus, a dietary history of fructose intake and the presence of fatty liver are important clues to suspect an underlying HFI in infants. Chronic liver disease in form of fatty liver, steatohepatitis and even cirrhosis may occur in patients with HFI who are fed regularly on a fructose-rich diet. Examination typically shows growth failure and hepatomegaly with or without jaundice. Renal involvement usually occurs in the form of proximal renal tubular acidosis and may lead to chronic renal insufficiency. Metabolic derangements include hypoglycemia, lactic acidosis, hypophosphatemia, hyperuricemia and hypermagnesemia[6]. HFI presenting as relapsing acute axonal neuropathy has also been reported recently, which improves after dietary fructose omission[22].

In contrast to the classical presentation of the above acute symptoms, some patients with residual enzymatic activity may remain asymptomatic or require a larger burden of fructose to become symptomatic. HFI can also remain masked in the presence of concomitant diseases. Aldag *et al*[23] reported an infant developing unexplained liver failure and metabolic dysfunction soon after a successful pyloromyotomy for hypertrophic pyloric stenosis and the diagnosis was confirmed by genetic testing. Similarly, Bobrus-Chociey reported that elevated transaminases and fatty liver may continue to prevail despite a compliant gluten-free diet in patients with celiac disease. In such a situation, a strong degree of suspicion for HFI is required[24].

Heterozygotes with HFI do not present with classical manifestations of HFI. It has been shown that there are significant but occult metabolic derangements in HFI heterozygous carriers. Randomized cross-over trials show that a high fructose diet (1.4 g/kg/d) increased postprandial plasma uric acid, insulin and hepatic insulin resistance index as compared to those on a low fructose diet (< 10 g/d). This analysis provides insight as to the extent of metabolic damages that can take place in homozygotes in whom these trials are deemed unethical[25]. There are several reports of gouty arthritis due to hyperuricemia in children with heterozygous mutation for HFI[26].

EVALUATION

A meticulous history revealing a clear correlation between exposure to dietary fructose and the onset of symptoms is the key to suspecting the possibility of underlying HFI. There are various pitfalls in the diagnosis of HFI. Kim *et al*[27] in their case series of 5 patients with subtle symptoms and aversion to sweets. They make a pertinent point that emphasis of classic teaching on infantile acute liver failure and biochemical derangements, such as hypoglycemia and hypophosphatemia, after the first exposure to

fructose may inadvertently increase the likelihood of missing cases of HFI characterized by other manifestations. Hence index of suspicion must be high and wide screening must be employed. HFI should be looked for in any patient with unexplained reasons for failing to thrive. HFI is also often misdiagnosed with other nongenetic and genetic conditions, including an eating disorder, recurrent hepatitis, and glycogen storage disease. Moreover, fructose intolerance may not be pathognomonic for HFI alone, given the description of rare patients with fruit-induced, food protein-induced enterocolitis syndrome. Furthermore, the lack of a specific and practical biomarker for HFI means that neither newborn screening nor biochemical testing can be used to establish the diagnosis. Compliance, discrimination and psychosocial issues may be specific problems in adolescence[28].

Detection of non-glucose-reducing substances in the urine sample while on a fructose-containing diet is a bedside screening test. The presence of reducing sugars (glucose/fructose/Lactose) in urine can be detected by Benedict's test[29]. While glucose can be detected in urine by glucose dipsticks, a positive Benedict's test in urine with a negative glucose dipstick test points to the presence of other reducing sugars like fructose/Lactose. Provocative fructose tolerance tests in young children are cumbersome and fraught with the dangers of hypoglycemia. Are there simpler biochemical ways to screen for HFI? Untreated HFI patients present abnormal transferrin (Tf) glycosylation patterns due to the inhibition of mannose-6-phosphate isomerase by fructose-1-phosphate. Hence, elevated serum carbohydrate-deficient Tf (CDT) may allow the prompt detection of HFI. The CDT values improve when an FSS-restrictive diet is followed. Cano *et al*[30] showed that by capillary zone electrophoresis method, asialoTf correlated with dietary intake of sucrose and that pentasialoTf + hexasialoTf negatively correlated with dietary intake of fructose in patients with HFI. Moreover, the tetrasialoTf/disialoTf ratio also differentiated treated HFI patients from healthy controls. However some patients with HFI have been initially misdiagnosed with type 1 congenital disorders of glycosylation[31].

Liver biopsy in patients with HFI shows macro vesicular steatosis with or without changes in inflammation and fibrosis[32]. For confirmation, a genetic test is favoured over the measurement of aldolase B activity in liver biopsy specimens as later is invasive and not widely available. Genetic testing has high sensitivity and specificity and includes single gene sequencing, multi-gene panels, and genomic testing [33].

DIFFERENTIAL DIAGNOSIS

Acute presentation of HFI mimics sepsis, acute infectious hepatitis, hemophagocytic lymphohistiocytosis and other metabolic diseases such as galactosemia, tyrosinemia, organic academia and urea cycle defect. In children presenting with hepatomegaly, fatty liver and raised transaminases, possibilities of Wilson disease, glycogen storage disorder, alpha-1 antitrypsin deficiency should be considered. Presentation as hypoglycemia, acidosis and hepatomegaly mimic fructose 1,6 bisphosphate deficiency, beta-ketothiolase deficiency, pyruvate carboxylase deficiency, congenital disorder of glycosylation, fatty acid oxidation defects and milder variants of respiratory chain defects. Predominant gastrointestinal symptoms and aversion to sweets distinguish HFI from the rest of the differential diagnoses.

TREATMENT

Being a complex metabolic disorder, management of HFI needs a multidisciplinary approach with the involvement of a pediatrician, clinical geneticist, dietician with experience in metabolic disorders, hepatologist and nephrologist. The crux of HFI management lies in the absolute avoidance of foods containing fructose, sucrose, and sorbitol (FSS). Patients presenting with an acute metabolic crisis should be admitted to an intensive care setting and initiated intravenous glucose (dextrose), treatment of metabolic acidosis, (if present) and supportive treatment. Strict avoidance of FSS in the diet along with supplementation of other sources of carbohydrate (glucose, corn-starch) results in rapid reversal of symptoms. At length repetitive counselling, clear instructions on dietary restrictions and continuous reinforcement are required to maintain long-term dietary compliance and precipitations of breakthrough events. Table 1 enlists the food items which should be avoided and which are permitted in patients with HFI. Patients with HFI on a strict FSS elimination diet can develop several nutritional deficiencies, especially vitamins mainly Vitamin C found predominantly in fruits and vitamin B complex. Thus, it is recommended to add multivitamin supplements to prevent the consequences of these deficiencies[34].

CONTROVERSIES IN MANAGEMENT

Diet

Although a strict FSS diet is recommended while treating HFI, there is no clarity as to whether small

Table 1 Food items to be avoided and permitted in hereditary fructose intolerance

Food category	Foods to be avoided	Foods permitted
Fruits	All fruits, fruit juices, fruit extracts, shakes, squashes	None
Cereals	Sweetened/sugar-coated cereals	All except sweetened/sugar coated cereals
Vegetables	Sweet potatoes, peas, Zucchini	All others including potatoes and onions
Breads	Any breads prepared with fructose/sucrose/sugar/sorbitol	Breads prepared without fructose, sucrose, sugar, or sorbitol
Deserts and sweeteners	All desserts/sweets prepared with sugar (cake, pie, ice cream, sherbet, sweetened lime soda)	Dietetic ice cream, dietetic puddings; natural yogurt
Poultry	Milk products added with sugar (sweetened curd/yogurt, fruit yogurt, milkshake, chocolate milk)	Milk without sugar, chicken, Turkey
Meat	Ham, bacon, hot dogs, processed meats; any other meat where sugar is used in processing	Beef, veal, lamb, pork; All Fish
Miscellaneous	Ketchup and other sauces/ condiments containing sugar, Honey, Jam, jelly, Candy, Cookies, Chocolates, , Carbonated beverages, medicinal syrups	Vegetable juices, coffee, tea, salt, pepper, broths/soups from permitted vegetables, eggs, nuts

amounts of fructose can be tolerated in the diet. At what permissible limit of fructose will liver and kidney damage not occur? Restriction of FSS may lead to growth failure even in clinically asymptomatic HFI patients. There is insufficient information about the long-term outcomes of minimal fructose ingestion. A recent study from Italy reported the ten years of follow-up of patients with HFI. Fatty liver (on sonography) persisted in 93.8% of patients despite being on FSS restricted diet of < 1.5 g/d (35). The authors also found that a significant proportion of patients continued to have raised transaminases (37.5%) even when dietary compliant. There are two reasons for the persisting liver abnormalities in patients with HFI. Firstly, fructose may be endogenously produced by the sorbitol-aldose reductase pathway, which can be activated after a glucose-enriched meal, nephrotoxic drugs or stressful conditions like sepsis and major surgery. Secondly, the permissible limits of fructose ingestion may not be safe in asymptomatic patients of HFI. The latter is supported by the determination of CDT by isoelectric focusing among the patients with HFI on an FSS-free diet by Di Dato *et al*[35]. They showed a significant correlation between the amount of fructose consumed and the percentage of disialoTf and tetrasialoTf/disialoTf ratio. The authors suggested that serum CDT profile could be considered a good tool to monitor FSS intake. In addition, CDT determination could be used to identify the maximum daily fructose tolerability of each HFI patient. However, the lack of widespread availability and high cost are the main barriers to the application of this tool.

Non-alcoholic fatty liver disease and HFI

As evident from the study by Di Dato *et al*[35], the majority of the patients with HFI despite being on an FSS-free diet continued to have fatty liver. In another cross-sectional study of 16 patients, non-alcoholic fatty liver disease (NAFLD) was found in 9 (56%) patients[32]. The importance lies in the fact that fatty liver may progress to steatohepatitis, hepatic fibrosis and cirrhosis. Moreover, there is an increased risk of type 2 diabetes and cardiovascular diseases[36,37]. The studies in ALDOB-KO mice as well as in patients with HFI have demonstrated that NAFLD may not be the result of direct lipogenic effects of fructose[38,39]. In addition, when ALDOB-KO mice were chronically exposed to small amounts of fructose in the chow (approximately 0.3%), they showed an increased accumulation of hepatic triglycerides, hepatic inflammation and signs of periportal fibrosis[38,40]. Notably, these ALDOB-KO mice also had increased intrahepatic F-1P concentrations[38]. Lanaspá *et al*[38] also showed the increased hepatic expression of enzymes was seen in de novo lipogenesis with an abundance of cytosolic glucokinase in ALDOB-KO mice. Thus, it can be speculated that the accumulation of F-1P in ALDOB-KO mice may stimulate hepatic glucose uptake, thereby enhancing the storage of glycogen and fat.

In the experimental model, almost all the metabolic abnormalities in the ALDOB-KO mice were ameliorated when supplemented with ketohexokinase (KHK), an enzyme involved in the phosphorylation of fructose[38]. Treatment with osthole, a natural KHK inhibitor also showed the same results[41]. Additionally, osthole treatment inhibited de novo lipogenesis in ALDOB KO mice. In humans, a loss of KHK results in essential fructosuria (OMIM #229800) which is a benign condition[42]. Hence, KHK inhibition may serve as a potential therapeutic target for the treatment of NAFLD in patients with HFI. Ghannem *et al*[43] have unusually reported epithelioid granulomas in association with liver adenomatosis and macrovesicular steatosis in an adult with HFI that yielded negative workup for tuberculosis, sarcoidosis and other infectious diseases. They postulated that the granulomas in the non-tumour liver sections may have developed from the inflammatory stress due to inflammatory hepatocellular adenomas.

Vaccines

There are considerable controversies about the safety concerns of vaccines that contain fructose, sucrose or sorbitol in HFI. Saborido-Fiaño *et al*[44,45] argue that the safe threshold of fructose was 2.4 mg/kg/dose and various oral rotavirus vaccines would not qualify for that category. This requires the need to revisit the vaccine content. The authors also cautioned against the use of Sars-Cov-2 vaccines in children affected with HFI. Urru *et al*[46] demonstrated the safety of these vaccines in adults.

PROGNOSIS

The data on long-term follow-up of patients with HFI is not available in the literature. However, In a recent study of HFI children with a mean follow-up of 10.3 ± 5.6 years, all of them were asymptomatic but had evidence of fatty liver in the majority and raised transaminases in some of them[26]. Interestingly, fructose intake in these children did not correlate with either of the two findings. The two case reports of HFI being diagnosed in adulthood because of self-imposed restriction to fructose in the diet since infancy may signify that the patients with HFI who adhere strictly to an FSS-free diet may have a good prognosis and normal lifespan[19,20]. On the other hand, when compliance is poor, renal and liver-related complications in the form of chronic renal insufficiency and hepatic fibrosis may ensue.

FUTURE RESEARCH

There is a need for data on the long-term outcome of HFI patients on an FSS-restricted diet to provide more insights into the consequences of NAFLD, cardiovascular disease and type 2 diabetes. Recent studies emphasized the role of F-1P in the hepatic fat accumulation of ALDOB-KO mice and the development of NAFLD. However, the exact role of endogenous fructose production (*via* the polyol pathway) in the accumulation of intrahepatic F-1P remains to be determined in animals as well as humans. Finally, clinical trials are required to show the benefit of KHK inhibition in the treatment of NAFLD in HFI patients.

CONCLUSION

HFI has diverse manifestations involving gastrointestinal, liver and renal issues. It mimics many metabolic conditions which present similarly. Other than genetics, there are no reliable laboratory markers that effectively diagnose this condition. A straight-forward FSS-free diet generally leads to a good long-term prognosis. There are however considerable controversies on the effect of dietary therapy on the liver, biochemistry, coexistence of steatosis and permissible levels of fructose in vaccines. Future research should be directed to basic sciences and long-term outcomes of this disease.

FOOTNOTES

Author contributions: Sarma MS conception, final drafting of the manuscript; Singh SK conception, primary drafting of the manuscript.

Conflict-of-interest statement: All the authors declare that they have no conflict of interest.

Open-Access: This article is an open-access article that was selected by an in-house editor and fully peer-reviewed by external reviewers. It is distributed in accordance with the Creative Commons Attribution NonCommercial (CC BY-NC 4.0) license, which permits others to distribute, remix, adapt, build upon this work non-commercially, and license their derivative works on different terms, provided the original work is properly cited and the use is non-commercial. See: <https://creativecommons.org/licenses/by-nc/4.0/>

Country/Territory of origin: India

ORCID number: Sumit Kumar Singh 0000-0001-8588-3460; Moinak Sen Sarma 0000-0003-2015-4069.

S-Editor: Liu JH

L-Editor: A

P-Editor: Liu JH

REFERENCES

- 1 **Hwang JJ**, Jiang L, Hamza M, Dai F, Belfort-DeAguiar R, Cline G, Rothman DL, Mason G, Sherwin RS. The human brain produces fructose from glucose. *JCI Insight* 2017; **2**: e90508 [PMID: 28239653 DOI: 10.1172/jci.insight.90508]
- 2 **Douard V**, Ferraris RP. Regulation of the fructose transporter GLUT5 in health and disease. *Am J Physiol Endocrinol Metab* 2008; **295**: E227-E237 [PMID: 18398011 DOI: 10.1152/ajpendo.90245.2008]
- 3 **Allgöwer M**, Leutenegger A. [On the editorial "Parenteral feeding: glucose or glucose replacements? *Schweiz Med Wochenschr* 1978; **108**: 1791-1792 [PMID: 100880]
- 4 **Bouteldja N**, Timson DJ. The biochemical basis of hereditary fructose intolerance. *J Inherit Metab Dis* 2010; **33**: 105-112 [PMID: 20162364 DOI: 10.1007/s10545-010-9053-2]
- 5 **Schrodi SJ**, DeBarber A, He M, Ye Z, Peissig P, Van Wormer JJ, Haws R, Brilliant MH, Steiner RD. Prevalence estimation for monogenic autosomal recessive diseases using population-based genetic data. *Hum Genet* 2015; **134**: 659-669 [PMID: 25893794 DOI: 10.1007/s00439-015-1551-8]
- 6 **Pinheiro FC**, Sperb-Ludwig F, Schwartz IVD. Epidemiological aspects of hereditary fructose intolerance: A database study. *Hum Mutat* 2021; **42**: 1548-1566 [PMID: 34524712 DOI: 10.1002/humu.24282]
- 7 **Pshennikova VG**, Barashkov NA, Romanov GP, Teryutin FM, Solov'ev AV, Gotovtsev NN, Nikanorova AA, Nakhodkin SS, Sazonov NN, Morozov IV, Bondar AA, Dzhemileva LU, Khusnutdinova EK, Posukh OL, Fedorova SA. Comparison of Predictive *In Silico* Tools on Missense Variants in *GJB2*, *GJB6*, and *GJB3* Genes Associated with Autosomal Recessive Deafness 1A (DFNB1A). *ScientificWorldJournal* 2019; **2019**: 5198931 [PMID: 31015822 DOI: 10.1155/2019/5198931]
- 8 **Yu B**. Role of in silico tools in gene discovery. *Mol Biotechnol* 2009; **41**: 296-306 [PMID: 19101827 DOI: 10.1007/s12033-008-9134-8]
- 9 **Coffee EM**, Yerkes L, Ewen EP, Zee T, Tolan DR. Increased prevalence of mutant null alleles that cause hereditary fructose intolerance in the American population. *J Inherit Metab Dis* 2010; **33**: 33-42 [PMID: 20033295 DOI: 10.1007/s10545-009-9008-7]
- 10 **Cross NC**, de Franchis R, Sebastio G, Dazzo C, Tolan DR, Gregori C, Odievre M, Vidailhet M, Romano V, Mascali G. Molecular analysis of aldolase B genes in hereditary fructose intolerance. *Lancet* 1990; **335**: 306-309 [PMID: 1967768 DOI: 10.1016/0140-6736(90)90603-3]
- 11 **Caciotti A**, Donati MA, Adami A, Guerrini R, Zammarchi E, Morrone A. Different genotypes in a large Italian family with recurrent hereditary fructose intolerance. *Eur J Gastroenterol Hepatol* 2008; **20**: 118-121 [PMID: 18188031 DOI: 10.1097/MEG.0b013e3282f172e6]
- 12 **Bijarnia-Mahay S**, Movva S, Gupta N, Sharma D, Puri RD, Kotecha U, Saxena R, Kabra M, Mohan N, Verma IC. Molecular Diagnosis of Hereditary Fructose Intolerance: Founder Mutation in a Community from India. *JIMD Rep* 2015; **19**: 85-93 [PMID: 25595217 DOI: 10.1007/8904_2014_374]
- 13 **Le TP**, Feng J, Ding L, Hu R, Lou XB, Ulrich JN, Cabrera MT. Survey of current retinopathy of prematurity practices in China. *Int J Ophthalmol* 2021; **14**: 1241-1247 [PMID: 34414091 DOI: 10.18240/ijo.2021.08.17]
- 14 **Yao DC**, Tolan DR, Murray MF, Harris DJ, Darras BT, Geva A, Neufeld EJ. Hemolytic anemia and severe rhabdomyolysis caused by compound heterozygous mutations of the gene for erythrocyte/muscle isozyme of aldolase, ALDOA(Arg303X/Cys338Tyr). *Blood* 2004; **103**: 2401-2403 [PMID: 14615364 DOI: 10.1182/blood-2003-09-3160]
- 15 **Mamoune A**, Bahuau M, Hamel Y, Serre V, Pelosi M, Habarou F, Nguyen Morel MA, Boisson B, Vergnaud S, Viou MT, Nonnenmacher L, Piraud M, Nusbaum P, Vamecq J, Romero N, Ottolenghi C, Casanova JL, de Lonlay P. A thermolabile aldolase A mutant causes fever-induced recurrent rhabdomyolysis without hemolytic anemia. *PLoS Genet* 2014; **10**: e1004711 [PMID: 25392908 DOI: 10.1371/journal.pgen.1004711]
- 16 **Inagaki H**, Eimoto T, Haimoto H, Hosoda S, Kato K. Aldolase C in neuroendocrine tumors: an immunohistochemical study. *Virchows Arch B Cell Pathol Incl Mol Pathol* 1993; **64**: 297-302 [PMID: 8287126 DOI: 10.1007/BF02915126]
- 17 **Ali M**, Rellos P, Cox TM. Hereditary fructose intolerance. *J Med Genet* 1998; **35**: 353-365 [PMID: 9610797 DOI: 10.1136/jmg.35.5.353]
- 18 **Li H**, Byers HM, Diaz-Kuan A, Vos MB, Hall PL, Tortorelli S, Singh R, Wallenstein MB, Allain M, Dimmock DP, Farrell RM, McCandless S, Gambello MJ. Acute liver failure in neonates with undiagnosed hereditary fructose intolerance due to exposure from widely available infant formulas. *Mol Genet Metab* 2018; **123**: 428-432 [PMID: 29510902 DOI: 10.1016/j.ymgme.2018.02.016]
- 19 **Yasawy MI**, Folsch UR, Schmidt WE, Schwend M. Adult hereditary fructose intolerance. *World J Gastroenterol* 2009; **15**: 2412-2413 [PMID: 19452588 DOI: 10.3748/wjg.15.2412]
- 20 **Kim MS**, Moon JS, Kim MJ, Seong MW, Park SS, Ko JS. Hereditary Fructose Intolerance Diagnosed in Adulthood. *Gut Liver* 2021; **15**: 142-145 [PMID: 33028743 DOI: 10.5009/gnl20189]
- 21 **Choi HW**, Lee YJ, Oh SH, Kim KM, Ryu JM, Lee BH, Kim GH, Yoo HW. A Novel Frameshift Mutation of the ALDOB Gene in a Korean Girl Presenting with Recurrent Hepatitis Diagnosed as Hereditary Fructose Intolerance. *Gut Liver* 2012; **6**: 126-128 [PMID: 22375183 DOI: 10.5009/gnl.2012.6.1.126]
- 22 **Maitre A**, Maw A, Ramaswami U, Morley SL. Relapsing Acute Axonal Neuropathy in Hereditary Fructose Intolerance. *Pediatr Neurol* 2016; **64**: 92-93 [PMID: 27720712 DOI: 10.1016/j.pediatrneurol.2016.06.021]
- 23 **Aldag E**, Fan EM, Marshall I, Christensen RD, Shayota BJ, Mezmarich JA. An Infant With Hereditary Fructose Intolerance and a Novel Presentation of Disseminated Intravascular Coagulopathy following Pyloromyotomy. *J Pediatr Hematol Oncol* 2022 [PMID: 35398868 DOI: 10.1097/MPH.0000000000002443]
- 24 **Bobrus-Chociej A**, Pollak A, Kopiczko N, Flisiak-Jackiewicz M, Płoski R, Lebensztejn DM. Celiac Disease in Conjunction with Hereditary Fructose Intolerance as a Rare Cause of Liver Steatosis with Mild Hypertransaminasemia-A Case Report. *Pediatr Rep* 2021; **13**: 589-593 [PMID: 34842789 DOI: 10.3390/pediatric13040070]
- 25 **Debray FG**, Seyssel K, Fadeur M, Tappy L, Paquot N, Tran C. Effect of a high fructose diet on metabolic parameters in carriers for hereditary fructose intolerance. *Clin Nutr* 2021; **40**: 4246-4254 [PMID: 33551217 DOI: 10.1016/j.clnu.2021.01.026]
- 26 **Seegmiller JE**, Dixon RM, Kemp GJ, Angus PW, McAlindon TE, Dieppe P, Rajagopalan B, Radda GK. Fructose-induced

- aberration of metabolism in familial gout identified by 31P magnetic resonance spectroscopy. *Proc Natl Acad Sci U S A* 1990; **87**: 8326-8330 [PMID: 2236043 DOI: 10.1073/pnas.87.21.8326]
- 27 **Kim AY**, Hughes JJ, Pipitone Dempsey A, Sondergaard Schatz K, Wang T, Gunay-Aygun M. Pitfalls in the Diagnosis of Hereditary Fructose Intolerance. *Pediatrics* 2020; **146** [PMID: 32709737 DOI: 10.1542/peds.2019-3324]
 - 28 **Izquierdo-García E**, Escobar-Rodríguez I, Moreno-Villares JM, Iglesias-Peinado I. Social and health care needs in patients with hereditary fructose intolerance in Spain. *Endocrinol Diabetes Nutr (Engl Ed)* 2020; **67**: 253-262 [PMID: 31399332 DOI: 10.1016/j.endinu.2019.06.005]
 - 29 **Simoni RD**, Hill RL and Vaughan M. "Benedict's Solution, a Reagent for Measuring Reducing Sugars: the Clinical Chemistry of Stanley R. Benedict". *J Biol Chem* 2002; **277**: E5-E6 [DOI: 10.1016/s0021-9258(19)61050-1]
 - 30 **Cano A**, Alcalde C, Belanger-Quintana A, Cañedo-Villarroya E, Ceberio L, Chumillas-Calzada S, Correcher P, Couce ML, García-Arenas D, Gómez I, Hernández T, Izquierdo-García E, Martínez Chicano D, Morales M, Pedrón-Giner C, Petrina Jáuregui E, Peña-Quintana L, Sánchez-Pintos P, Serrano-Nieto J, Unceta Suarez M, Vitoria Miñana I, de Las Heras J. Transferrin Isoforms, Old but New Biomarkers in Hereditary Fructose Intolerance. *J Clin Med* 2021; **10** [PMID: 34208868 DOI: 10.3390/jcm10132932]
 - 31 **Adamowicz M**, Ploski R, Rokicki D, Morava E, Gizewska M, Mierzevska H, Pollak A, Lefeber DJ, Wevers RA, Pronicka E. Transferrin hypoglycosylation in hereditary fructose intolerance: using the clues and avoiding the pitfalls. *J Inher Metab Dis* 2007; **30**: 407 [PMID: 17457694 DOI: 10.1007/s10545-007-0569-z]
 - 32 **Aldámiz-Echevarría L**, de Las Heras J, Couce ML, Alcalde C, Vitoria I, Bueno M, Blasco-Alonso J, Concepción García M, Ruiz M, Suárez R, Andrade F, Villate O. Non-alcoholic fatty liver in hereditary fructose intolerance. *Clin Nutr* 2020; **39**: 455-459 [PMID: 30833214 DOI: 10.1016/j.clnu.2019.02.019]
 - 33 **Steinmann B**, Gitzelmann R, van den Berghe G. Disorders of fructose metabolism. In: Scriver CR, Beaudet AL, Sly WS, Valle D, Childs B, Kinzler K, Vogelstein B. The metabolic and molecular basis of inherited disease. 8th ed. New York: McGraw-Hill; 2001; 1489-1520 [DOI: 10.1007/s00439-001-0669-z]
 - 34 **Hegde VS**, Sharman T. Hereditary Fructose Intolerance. 2021 Jun 29. In: StatPearls [Internet]. Treasure Island (FL): StatPearls Publishing; 2022 [PMID: 32644528]
 - 35 **Di Dato F**, Spadarella S, Puoti MG, Caprio MG, Pagliardini S, Zuppaldi C, Vallone G, Fecarotta S, Esposito G, Iorio R, Parenti G, Spagnuolo MI. Daily Fructose Traces Intake and Liver Injury in Children with Hereditary Fructose Intolerance. *Nutrients* 2019; **11** [PMID: 31591370 DOI: 10.3390/nu11102397]
 - 36 **Mantovani A**, Byrne CD, Bonora E, Targher G. Nonalcoholic Fatty Liver Disease and Risk of Incident Type 2 Diabetes: A Meta-analysis. *Diabetes Care* 2018; **41**: 372-382 [PMID: 29358469 DOI: 10.2337/dc17-1902]
 - 37 **Targher G**, Byrne CD, Lonardo A, Zoppini G, Barbui C. Non-alcoholic fatty liver disease and risk of incident cardiovascular disease: A meta-analysis. *J Hepatol* 2016; **65**: 589-600 [PMID: 27212244 DOI: 10.1016/j.jhep.2016.05.013]
 - 38 **Lanaspa MA**, Andres-Hernando A, Orlicky DJ, Cicerchi C, Jang C, Li N, Milagres T, Kuwabara M, Wempe MF, Rabinowitz JD, Johnson RJ, Tolan DR. Ketohexokinase C blockade ameliorates fructose-induced metabolic dysfunction in fructose-sensitive mice. *J Clin Invest* 2018; **128**: 2226-2238 [PMID: 29533924 DOI: 10.1172/JCI94427]
 - 39 **Simons N**, Debray FG, Schaper NC, Kooi ME, Feskens EJM, Hollak CEM, Lindeboom L, Koek GH, Bons JAP, Lefeber DJ, Hodson L, Schalkwijk CG, Stehouwer CDA, Cassiman D, Brouwers MCGJ. Patients With Aldolase B Deficiency Are Characterized by Increased Intrahepatic Triglyceride Content. *J Clin Endocrinol Metab* 2019; **104**: 5056-5064 [PMID: 30901028 DOI: 10.1210/je.2018-02795]
 - 40 **Oppelt SA**, Sennott EM, Tolan DR. Aldolase-B knockout in mice phenocopies hereditary fructose intolerance in humans. *Mol Genet Metab* 2015; **114**: 445-450 [PMID: 25637246 DOI: 10.1016/j.ymgme.2015.01.001]
 - 41 **Le MT**, Lanaspa MA, Cicerchi CM, Rana J, Scholten JD, Hunter BL, Rivard CJ, Randolph RK, Johnson RJ. Bioactivity-Guided Identification of Botanical Inhibitors of Ketohexokinase. *PLoS One* 2016; **11**: e0157458 [PMID: 27322374 DOI: 10.1371/journal.pone.0157458]
 - 42 **Tran C**. Inborn Errors of Fructose Metabolism. What Can We Learn from Them? *Nutrients* 2017; **9** [PMID: 28368361 DOI: 10.3390/nu9040356]
 - 43 **Ghannem L**, Beaufrère A, Zucman-Rossi J, Paradis V. Liver adenomatosis and NAFLD developed in the context of hereditary fructose intolerance. *Liver Int* 2020; **40**: 3125-3126 [PMID: 32970909 DOI: 10.1111/liv.14673]
 - 44 **Saborido-Fiaño R**, Martínón-Torres N, Crujeiras-Martínez V, Couce ML, Leis R. Letter to the editor concerning the article 'Safety of vaccines administration in hereditary fructose intolerance'. *Hum Vaccin Immunother* 2021; **17**: 2593-2594 [PMID: 33653220 DOI: 10.1080/21645515.2021.1891816]
 - 45 **Saborido-Fiaño R**, Martínón-Torres N, Crujeiras-Martínez V, Couce ML, Leis R. Reply letter to "safety of SARS-Cov-2 vaccines administration for adult patients with hereditary fructose intolerance". *Hum Vaccin Immunother* 2021; **17**: 4115-4116 [PMID: 34473597 DOI: 10.1080/21645515.2021.1959149]
 - 46 **Urru SAM**, Maines E, Campomori A, Soffiati M. Safety of Sars-Cov-2 vaccines administration for adult patients with hereditary fructose intolerance. *Hum Vaccin Immunother* 2021; **17**: 4112-4114 [PMID: 34197272 DOI: 10.1080/21645515.2021.1943992]



Published by **Baishideng Publishing Group Inc**
7041 Koll Center Parkway, Suite 160, Pleasanton, CA 94566, USA

Telephone: +1-925-3991568

E-mail: bpgoffice@wjgnet.com

Help Desk: <https://www.f6publishing.com/helpdesk>

<https://www.wjgnet.com>

