

World Journal of *Clinical Cases*

World J Clin Cases 2022 August 16; 10(23): 8057-8431



Contents

Thrice Monthly Volume 10 Number 23 August 16, 2022

OPINION REVIEW

- 8057** Invasive intervention timing for infected necrotizing pancreatitis: Late invasive intervention is not late for collection

Xiao NJ, Cui TT, Liu F, Li W

- 8063** Clinical utility of left atrial strain in predicting atrial fibrillation recurrence after catheter ablation: An up-to-date review

Yu ZX, Yang W, Yin WS, Peng KX, Pan YL, Chen WW, Du BB, He YQ, Yang P

MINIREVIEWS

- 8076** Gut microbiota and COVID-19: An intriguing pediatric perspective

Valentino MS, Esposito C, Colosimo S, Caprio AM, Puzone S, Guarino S, Marzuillo P, Miraglia del Giudice E, Di Sessa A

- 8088** Beta receptor blocker therapy for the elderly in the COVID-19 era

Santillo E, Migale M

ORIGINAL ARTICLE

Retrospective Cohort Study

- 8097** Nonselective beta-blocker use is associated with increased hepatic encephalopathy-related readmissions in cirrhosis

Fallahzadeh MA, Asrani SK, Tapper EB, Saracino G, Rahimi RS

Retrospective Study

- 8107** Different squatting positions after total knee arthroplasty: A retrospective study

Li TJ, Sun JY, Du YQ, Shen JM, Zhang BH, Zhou YG

- 8115** Outcomes of seromuscular bladder augmentation compared with standard bladder augmentation in the treatment of children with neurogenic bladder

Sun XG, Li YX, Ji LF, Xu JL, Chen WX, Wang RY

- 8124** Distinctive clinical features of spontaneous pneumoperitoneum in neonates: A retrospective analysis

Kim SH, Cho YH, Kim HY

- 8133** Cognitive training for elderly patients with early Alzheimer's disease in the Qinghai-Tibet Plateau: A pilot study

Wang XH, Luo MQ

- 8141** Diagnostic value of elevated serum carbohydrate antigen 125 level in sarcoidosis

Zhang Q, Jing XY, Yang XY, Xu ZJ

- 8152** Evaluation of progressive early rehabilitation training mode in intensive care unit patients with mechanical ventilation

Qie XJ, Liu ZH, Guo LM

- 8161** Comparison of demographic features and laboratory parameters between COVID-19 deceased patients and surviving severe and critically ill cases

Wang L, Gao Y, Zhang ZJ, Pan CK, Wang Y, Zhu YC, Qi YP, Xie FJ, Du X, Li NN, Chen PF, Yue CS, Wu JH, Wang XT, Tang YJ, Lai QQ, Kang K

Clinical Trials Study

- 8170** Role of H₂receptor blocker famotidine over the clinical recovery of COVID-19 patients: A randomized controlled trial

Mohiuddin Chowdhury ATM, Kamal A, Abbas MKU, Karim MR, Ali MA, Talukder S, Hamidullah Mehedi HM, Hassan H, Shahin AH, Li Y, He S

Observational Study

- 8186** Short-term prognostic factors for hepatitis B virus-related acute-on-chronic liver failure

Ye QX, Huang JF, Xu ZJ, Yan YY, Yan Y, Liu LG

- 8196** Three-dimensional psychological guidance combined with evidence-based health intervention in patients with liver abscess treated with ultrasound

Shan YN, Yu Y, Zhao YH, Tang LL, Chen XM

- 8205** Role of serum β 2-microglobulin, glycosylated hemoglobin, and vascular endothelial growth factor levels in diabetic nephropathy

Yang B, Zhao XH, Ma GB

SYSTEMATIC REVIEWS

- 8212** Gallbladder neuroendocrine carcinoma diagnosis, treatment and prognosis based on the SEER database: A literature review

Cai XC, Wu SD

CASE REPORT

- 8224** Sepsis complicated with secondary hemophagocytic syndrome induced by giant gouty tophi rupture: A case report

Lai B, Pang ZH

- 8232** Spontaneous remission of autoimmune pancreatitis: Four case reports

Zhang BB, Huo JW, Yang ZH, Wang ZC, Jin EH

- 8242** Epstein-Barr-virus-associated hepatitis with aplastic anemia: A case report

Zhang WJ, Wu LQ, Wang J, Lin SY, Wang B

- 8249** Aspiration as the first-choice procedure for airway management in an infant with large epiglottic cysts: A case report

Zheng JQ, Du L, Zhang WY

- 8255** Sequential multidisciplinary minimally invasive therapeutic strategy for heart failure caused by four diseases: A case report
Zhao CZ, Yan Y, Cui Y, Zhu N, Ding XY
- 8262** Primary ascending colon cancer accompanying skip metastases in left shoulder skin and left neck lymph node: A case report
Zhou JC, Wang JJ, Liu T, Tong Q, Fang YJ, Wu ZQ, Hong Q
- 8271** Clinical and genetic study of ataxia with vitamin E deficiency: A case report
Zhang LW, Liu B, Peng DT
- 8277** Complete resection of large-cell neuroendocrine and hepatocellular carcinoma of the liver: A case report
Noh BG, Seo HI, Park YM, Kim S, Hong SB, Lee SJ
- 8284** Immunotherapy combined with antiangiogenic agents in patients with advanced malignant pleural mesothelioma: A case report
Xuan TT, Li GY, Meng SB, Wang ZM, Qu LL
- 8291** Bladder malacoplakia: A case report
Wang HK, Hang G, Wang YY, Wen Q, Chen B
- 8298** Delayed inflammatory response evoked in nasal alloplastic implants after COVID-19 vaccination: A case report
Seo MG, Choi EK, Chung KJ
- 8304** Phosphoglyceride crystal deposition disease requiring differential diagnosis from malignant tumors and confirmed by Raman spectroscopy: A case report
Ohkura Y, Uruga H, Shiiba M, Ito S, Shimoyama H, Ishihara M, Ueno M, Udagawa H
- 8312** Vulvovaginal myeloid sarcoma with massive pelvic floor infiltration: A case report and review of literature
Wang JX, Zhang H, Ning G, Bao L
- 8323** Femoral neck stress fracture and medial tibial stress syndrome following high intensity interval training: A case report and review of literature
Tan DS, Cheung FM, Ng D, Cheung TLA
- 8330** Periosteal chondroma of the rib: A case report
Gao Y, Wang JG, Liu H, Gao CP
- 8336** Papillary thyroid carcinoma occurring with undifferentiated pleomorphic sarcoma: A case report
Lee YL, Cheng YQ, Zhu CF, Huo HZ
- 8344** Laparoscopic treatment of bilateral duplex kidney and ectopic ureter: A case report
Wang SB, Wan L, Wang Y, Yi ZJ, Xiao C, Cao JZ, Liu XY, Tang RP, Luo Y
- 8352** Incontinentia pigmenti with intracranial arachnoid cyst: A case report
Li WC, Li ML, Ding JW, Wang L, Wang SR, Wang YY, Xiao LF, Sun T

- 8360** Relapsing polychondritis causing breathlessness: Two case reports
Zhai SY, Zhang YH, Guo RY, Hao JW, Wen SX
- 8367** Endodontic management of a fused left maxillary second molar and two paramolars using cone beam computed tomography: A case report
Mei XH, Liu J, Wang W, Zhang QX, Hong T, Bai SZ, Cheng XG, Tian Y, Jiang WK
- 8375** Infant biliary cirrhosis secondary to a biliary inflammatory myofibroblastic tumor: A case report and review of literature
Huang Y, Shu SN, Zhou H, Liu LL, Fang F
- 8384** Metastatic low-grade endometrial stromal sarcoma with variable morphologies in the ovaries and mesentery: A case report
Yu HY, Jin YL
- 8392** Bronchogenic cysts with infection in the chest wall skin of a 64-year-old asymptomatic patient: A case report
Ma B, Fu KW, Xie XD, Cheng Y, Wang SQ
- 8400** Incidental accumulation of Technetium-99m pertechnetate in subacute cerebral infarction: A case report
Han YH, Jeong HJ, Kang HG, Lim ST
- 8406** Metal stent combined with ileus drainage tube for the treatment of delayed rectal perforation: A case report
Cheng SL, Xie L, Wu HW, Zhang XF, Lou LL, Shen HZ
- 8417** Using ketamine in a patient with a near-occlusion tracheal tumor undergoing tracheal resection and reconstruction: A case report
Xu XH, Gao H, Chen XM, Ma HB, Huang YG

LETTER TO THE EDITOR

- 8422** Reflections on the prevalence of human leukocyte antigen-B27 and human leukocyte antigen-B51 co-occurrence in patients with spondylarthritis
Gonçalves Júnior J, Sampaio-Barros PD, Shinjo SK
- 8425** Comment on "Disease exacerbation is common in inflammatory bowel disease patients treated with immune checkpoint inhibitors for malignancy"
Argyriou K, Kotsakis A
- 8428** Intranasal sufentanil combined with intranasal dexmedetomidine: A promising method for non-anesthesiologist sedation during endoscopic ultrasonography
Wang Y, Ge ZJ, Han C

ABOUT COVER

Editorial Board Member of *World Journal of Clinical Cases*, Peng Liang, MD, Associate Professor, Day Surgery Center, Department of Anesthesiology, West China Hospital of Sichuan University, Chengdu 610041, Sichuan Province, China. 39485572@qq.com

AIMS AND SCOPE

The primary aim of *World Journal of Clinical Cases* (WJCC, *World J Clin Cases*) is to provide scholars and readers from various fields of clinical medicine with a platform to publish high-quality clinical research articles and communicate their research findings online.

WJCC mainly publishes articles reporting research results and findings obtained in the field of clinical medicine and covering a wide range of topics, including case control studies, retrospective cohort studies, retrospective studies, clinical trials studies, observational studies, prospective studies, randomized controlled trials, randomized clinical trials, systematic reviews, meta-analysis, and case reports.

INDEXING/ABSTRACTING

The WJCC is now abstracted and indexed in Science Citation Index Expanded (SCIE, also known as SciSearch®), Journal Citation Reports/Science Edition, Current Contents®/Clinical Medicine, PubMed, PubMed Central, Scopus, Reference Citation Analysis, China National Knowledge Infrastructure, China Science and Technology Journal Database, and Superstar Journals Database. The 2022 Edition of Journal Citation Reports® cites the 2021 impact factor (IF) for WJCC as 1.534; IF without journal self cites: 1.491; 5-year IF: 1.599; Journal Citation Indicator: 0.28; Ranking: 135 among 172 journals in medicine, general and internal; and Quartile category: Q4. The WJCC's CiteScore for 2021 is 1.2 and Scopus CiteScore rank 2021: General Medicine is 443/826.

RESPONSIBLE EDITORS FOR THIS ISSUE

Production Editor: Hua-Ge Yin; Production Department Director: Xiang Li; Editorial Office Director: Jin-Lei Wang.

NAME OF JOURNAL

World Journal of Clinical Cases

ISSN

ISSN 2307-8960 (online)

LAUNCH DATE

April 16, 2013

FREQUENCY

Thrice Monthly

EDITORS-IN-CHIEF

Bao-Gan Peng, Jerzy Tadeusz Chudek, George Kontogeorgos, Maurizio Serati, Ja Hyeon Ku

EDITORIAL BOARD MEMBERS

<https://www.wjnet.com/2307-8960/editorialboard.htm>

PUBLICATION DATE

August 16, 2022

COPYRIGHT

© 2022 Baishideng Publishing Group Inc

INSTRUCTIONS TO AUTHORS

<https://www.wjnet.com/bpg/gerinfo/204>

GUIDELINES FOR ETHICS DOCUMENTS

<https://www.wjnet.com/bpg/GerInfo/287>

GUIDELINES FOR NON-NATIVE SPEAKERS OF ENGLISH

<https://www.wjnet.com/bpg/gerinfo/240>

PUBLICATION ETHICS

<https://www.wjnet.com/bpg/GerInfo/288>

PUBLICATION MISCONDUCT

<https://www.wjnet.com/bpg/gerinfo/208>

ARTICLE PROCESSING CHARGE

<https://www.wjnet.com/bpg/gerinfo/242>

STEPS FOR SUBMITTING MANUSCRIPTS

<https://www.wjnet.com/bpg/GerInfo/239>

ONLINE SUBMISSION

<https://www.f6publishing.com>



Aspiration as the first-choice procedure for airway management in an infant with large epiglottic cysts: A case report

Jian-Qiao Zheng, Li Du, Wei-Yi Zhang

Specialty type: Medicine, research and experimental

Provenance and peer review: Unsolicited article; Externally peer reviewed.

Peer-review model: Single blind

Peer-review report's scientific quality classification

Grade A (Excellent): 0
Grade B (Very good): B
Grade C (Good): C, C, C
Grade D (Fair): D
Grade E (Poor): 0

P-Reviewer: Amornytin S, Thailand; Arslan M, Turkey; Arumugam EAP, India; Moschovi MA, Greece

Received: December 1, 2021

Peer-review started: December 1, 2021

First decision: March 15, 2022

Revised: June 3, 2022

Accepted: June 21, 2022

Article in press: June 21, 2022

Published online: August 16, 2022



Jian-Qiao Zheng, Wei-Yi Zhang, Department of Anesthesiology, West China Hospital, Sichuan University, Chengdu 610041, Sichuan Province, China

Li Du, Department of Anesthesiology, Sichuan Cancer Hospital and Institute, Sichuan Cancer Center, School of Medicine, University of Electronic Science and Technology of China, Chengdu 610041, Sichuan Province, China

Corresponding author: Wei-Yi Zhang, MD, PhD, Professor, Department of Anesthesiology, West China Hospital, Sichuan University, No. 37 Guoxue Lane, Wuhou District, Chengdu 610041, Sichuan Province, China. anesthesiology_scu@163.com

Abstract

BACKGROUND

Epiglottic cysts is a rare but potentially lethal supraglottic airway pathology in infants due to the high risk of cannot intubation or cannot ventilation. Awake fiberoptic intubation appeared to be the safest technique, but it is very challenging in infants with large epiglottic cysts. Even it has the risk of airway loss. We report that cyst aspiration is an effective treatment as the first-choice procedure for airway management in an infant with large epiglottic cysts.

CASE SUMMARY

A 46-day-old male infant weighing 2.3 kg presented to the emergency room with difficulty feeding, worsening stridor, and progressive respiratory distress. Epiglottic cysts was diagnosed, but fibro bronchoscopy examination failed, as the fiberoptic bronchoscope was unable to cross the epiglottic cysts to the trachea. The infant was transferred to the operating room for emergency cystectomy under general anesthesia. Spontaneous respiration was maintained during anesthesia induction, and cyst aspiration was performed as the first procedure for airway management under video laryngoscopy considering that the preoperative fibro bronchoscopy examination failed. Then, the endotracheal tube was intubated successfully. Cystectomy was performed uneventfully, and the infant was safely transferred to the intensive care unit after surgery. The infant was extubated smoothly on the third postoperative day and discharged on the eighth day after surgery. On follow-up 1 year after the surgery, a normal airway was found by fibro bronchoscopy examination.

CONCLUSION

Epiglottic cyst aspiration can be considered the first procedure for airway management in infants with large epiglottic cysts.

Key Words: Epiglottic cysts; Infant; Airway management; Difficult airway; Case report

©The Author(s) 2022. Published by Baishideng Publishing Group Inc. All rights reserved.

Core Tip: Epiglottic cysts is a rare but potentially lethal supraglottic airway pathology in infants. Surgical cystectomy is the mainstay and established treatment method, which poses a significant anesthetic challenge for airway management due to the increased risk of difficult tracheal intubation and airway occlusion resulting in hypoventilation, hypoxemia, and even death. In this report, cysts aspiration was selected as the first treatment for airway management in an infant with large epiglottic cysts, and an endotracheal tube was successfully intubated after cysts aspiration. This anesthesia technique is considered as the first choice for airway management in infants with large epiglottic cysts.

Citation: Zheng JQ, Du L, Zhang WY. Aspiration as the first-choice procedure for airway management in an infant with large epiglottic cysts: A case report. *World J Clin Cases* 2022; 10(23): 8249-8254

URL: <https://www.wjgnet.com/2307-8960/full/v10/i23/8249.htm>

DOI: <https://dx.doi.org/10.12998/wjcc.v10.i23.8249>

INTRODUCTION

Epiglottic cysts is a rare but potentially lethal supraglottic airway pathology in infants and are caused by ductal obstruction of either mucous glands or minor salivary glands in the vallecula and base of the tongue[1]. Epiglottic cysts can cause stridor, wheezing, respiratory distress, swallowing difficulty, failure to thrive, and even life-threatening conditions according to the extent of airway obstruction by its location and size[2]. Acute life-threatening airway compromise always requires emergency airway management[3]. However, patients with catastrophic cases are still reported during airway management[4]. Airway management of epiglottic cysts has been associated with grave consequences such as respiratory failure, emergency tracheostomy, and even death in past reports[1-5].

Surgery is the mainstay and established treatment method for epiglottic cysts[6]. Surgical cystectomy for epiglottic cysts poses a significant anesthetic challenge for airway management, as these patients are at increased risk of difficult tracheal intubation and airway occlusion resulting in hypoventilation, hypoxemia, and even death[4,5,7]. Particularly in infants with large epiglottic cysts, the success rate of tracheal intubation by different equipment remains low[8,9]. Tracheal intubation may not be able to be completed by straight blade laryngoscopy, video laryngoscopy, and even fiberoptic intubation, as the passage for endotracheal intubation could be blocked by the cysts[8-11]. Therefore, a meticulous airway assessment and an anesthetic plan are mandatory before surgery and anesthesia induction.

Considering the risk of pulmonary aspiration, epiglottic cysts aspiration is only used in an emergency, such as cannot intubation or cannot ventilation[8,9]. Whether epiglottic cysts aspiration could be used as the first-choice procedure for airway management in infants with large epiglottic cysts remains unclear as the speculated risk of pulmonary inspiration[4,8,9]. In our case report, cysts aspiration was selected as the first treatment for airway management in an infant with large epiglottic cysts, and an endotracheal tube was successfully intubated after cysts aspiration. Herein, we recommend cysts aspiration as the first choice for airway management in infants with large epiglottic cysts.

CASE PRESENTATION

Chief complaints

A 46-d-old male infant weighing 2.3 kg presented to the emergency room with difficulty feeding, worsening stridor, and progressive respiratory distress.

History of present illness

The infant developed difficulty feeding, worsening stridor, and progressive respiratory distress for 1 wk.

History of past illness

The infant had no past history.

Personal and family history

The infant had no personal or family history.

Physical examination

The physical examination of the infant showed stridor and progressive respiratory distress.

Laboratory examinations

Preoperative blood biochemistry was normal. Saturation of pulse oximetry ranged from 85% to 90% on 60% oxygen by nasal catheters.

Imaging examinations

Preoperative electrocardiogram, transthoracic echocardiography, and chest X-ray were normal. Computed tomography (CT) showed a giant round mass on the lingual surface of the epiglottis (Figure 1). Fibro bronchoscopy examination failed, but video laryngoscopy confirmed the giant cyst to be implanted on the tip of the epiglottis (Figure 2).

FINAL DIAGNOSIS

The infant was diagnosed with epiglottic cysts.

TREATMENT

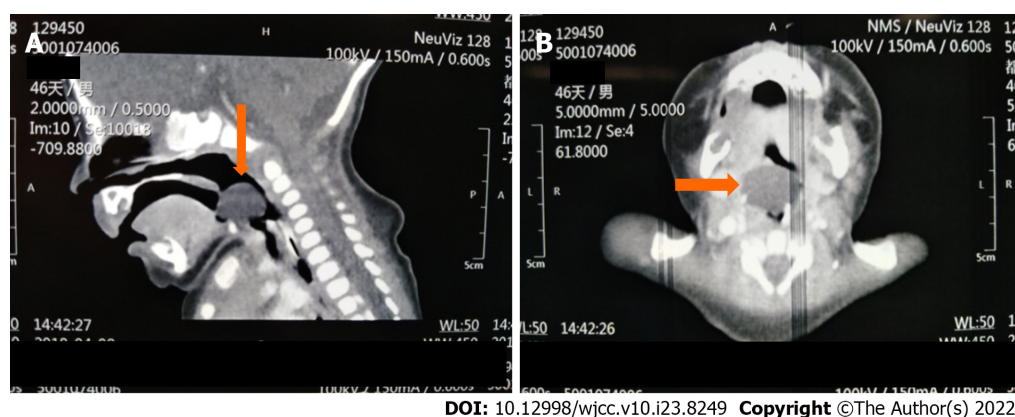
The infant was transferred to the operating room for emergency cystectomy under general anesthesia. The anesthesia induction plan was inhalational induction maintaining spontaneous breathing and keeping an otolaryngologist on standby for emergency tracheostomy if necessary. The infant was placed in the sniffing position on the operation table preoxygenated with 100% oxygen and premedicated with intravenous atropine 0.02 mg/kg. Inhalational induction was performed by upward titration of sevoflurane from 1% to 6% with 100% oxygen. Spontaneous breathing was maintained, and the effectiveness of mask ventilation was confirmed during the induction process. When the skeletal muscle relaxation was adequate, a video laryngoscope blade was inserted from the right side of the mouth. Large epiglottic cysts was visualized in the midline of the laryngeal inlet, and the epiglottis was not revealed (Figure 2). Considering that fiberoptic bronchoscopy failed to cross the epiglottic cysts during fibro bronchoscopy examination, fiberoptic intubation was not attempted. Any repeated attempts to reveal the epiglottis by pushing cysts to the left could rupture the cysts by accident, which could increase the risk of pulmonary aspiration. Therefore, cysts aspiration was performed as the first procedure for airway management after careful consideration. Aspiration was used by an 18-gauge needle with an attached 20 mL syringe (Figure 2). Six milliliters of transparent fluid were aspirated from the cysts, and then the epiglottis and arytenoid cartilage appeared. A 3.0 mm inner diameter cuffed endotracheal tube was intubated successfully under the infant's spontaneous breathing (Figure 3). Thereafter, fentanyl and atracurium were administered intravenously and general anesthesia was maintained with sevoflurane. Carbon dioxide laser cystectomy was performed under the suspended laryngoscope. The infant was safely transferred to the intensive care unit for gradual weaning considering the development of edema at the surgical site after surgery.

OUTCOME AND FOLLOW-UP

Tracheomalacia was suspected on the postoperative first day as the positive cuff leak test. So, the infant was extubated smoothly until the postoperative third day after repeated postoperative fiberoptic bronchoscopy to ruled out tracheomalacia. Diagnostic fibro bronchoscopy examination revealed a normal airway on the fifth day and the infant was discharged on the eighth day after surgery. On follow-up 1 year after the surgery, a normal airway was found by fibro bronchoscopy examination.

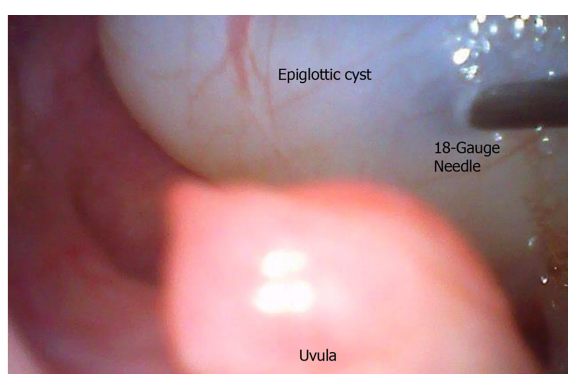DISCUSSION

Epiglottic cysts pose a great challenge to airway management, especially in neonates and young infants with a relatively small airway. Detailed preoperative assessment, including obstructive symptoms assessment, CT scan, and fiberoptic bronchoscope examination, must be determined to make a meticulous airway assessment and anesthetic plan[12].



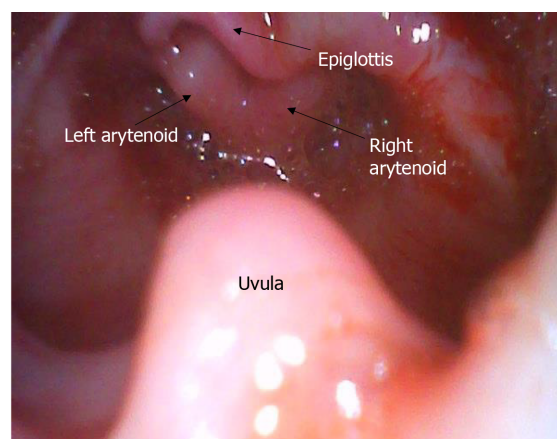
DOI: 10.12998/wjcc.v10.i23.8249 Copyright ©The Author(s) 2022.

Figure 1 The preoperative computed tomography imaging of head showing a giant round mass on the lingual surface of the epiglottis. A: Sagittal computed tomography (CT) scan (The yellow arrow indicates the epiglottic cyst); B: Transverse CT scan (The yellow arrow indicates the epiglottic cyst).



DOI: 10.12998/wjcc.v10.i23.8249 Copyright ©The Author(s) 2022.

Figure 2 Video laryngoscopy confirmed the giant cyst to be implanted on the tip of the epiglottis. Aspiration was used by an 18-gauge needle.



DOI: 10.12998/wjcc.v10.i23.8249 Copyright ©The Author(s) 2022.

Figure 3 Video laryngoscopy imaging after epiglottic cysts aspiration. Epiglottis and arytenoid cartilage appeared.

Due to the high risk of difficult endotracheal intubation and difficult mask ventilation, spontaneous breathing should be maintained to avoid the disastrous consequences caused by cannot intubation or cannot ventilation[8,9]. Otolaryngologists must standby for emergency tracheostomy if required during anesthesia induction. Muscle relaxants (preferred succinylcholine) can be used to improve intubation conditions only when the effectiveness of face-mask ventilation is confirmed. Successful tracheal intubation by direct laryngoscopy, video laryngoscope, awake fiberoptic bronchoscope or tongue tip traction suture technique or “three-person technique” of fiberoptic intubation in patients with large epiglottic cysts was reported[7-11,13-17]. However, the success rate is low, and several attempts are often needed, which could increase the risk of airway trauma[8,9].

Awake fiberoptic intubation appeared to be the safest technique, particularly in adult patients with upper airway obstruction. However, in infants, several hurdles could be encountered during awake fiberoptic intubation. First, there was a lack of cooperation in this age group. Second, the hypopharynx is occupied by the large cyst, and the space available for manipulation of the scope in the hypopharynx is limited even in expert hands. Third, anatomical structures such as the larynx and arytenoid cartilage were severely distorted, and the glottis was pushed to an unusually acute angle to the arytenoid cartilage, which created an awkward passage for advancement of the endotracheal tube under the guidance of the bronchoscope. In addition, the resistance of upper airway soft tissue can make it difficult to intubate using fiberoptic intubation. In this situation, the tracheal tube could rupture the cysts by accident during intubation. Last, adequate topicalization could be difficult to acquire due to the limitations in the volume of local anesthetic. As a result, awake fiberoptic intubation still has the potential for loss of airway patency. In infants with large epiglottic cysts, it can be very distressing and may even fail in well-trained anesthesiologists[9,11,13,18,19].

Cyst aspiration by a large-bore needle to improve the intubation conditions can be beneficial. It is only used in an emergency as the previous clinical case reported, considering the risk of pulmonary aspiration[8,9]. Even in a clinical case, emergency tracheostomy was performed as the first treatment for cannot intubation and cannot ventilation, rather than epiglottic cyst aspiration[4]. Obviously, the complications of tracheostomy are significantly higher than epiglottic cyst aspiration[20]. In addition, aspiration is a safe surgical approach for the epiglottic cyst[6]. Reviewing the literature on anesthesia management of epiglottic cysts, we found that epiglottic cyst aspiration is a safe and effective procedure for airway management. However, it was only used as the rescue technique, when the routine intubation techniques failed. It can reduce the cyst size and can avoid a tracheostomy[21-25]. Based on the safety and feasibility of this procedure, if this method is preferred as the first procedure for airway management, it will be more beneficial to these patients.

Pulmonary aspiration is the most concerning complication for the clinical application of epiglottic cyst aspiration. Adequate aspiration and quick endotracheal intubation are the key factors of this technique, as to avoid pulmonary aspiration. However, aspiration treatment is a safe and established surgical approach for epiglottic cyst in the clinic. In our case, adequate aspiration by a large-bore needle (18-gauge needle) with an attached syringe (20 mL) can safely expose arytenoids and epiglottis, facilitating endotracheal intubation. In addition, it is a safe and effective procedure for airway management based on a literature review. Simultaneously, adequate aspiration could prevent pulmonary aspiration caused by accidental cysts rupture during repeated attempts of endotracheal intubation. It should be noted that when the patient's coagulation function was abnormal, epiglottic cysts aspiration was considered contraindicated. Hence, we propose that cysts aspiration could be considered as the first choice for airway management in infants with large epiglottic cysts.

CONCLUSION

Epiglottic cysts aspiration by a large-bore needle can facilitate endotracheal intubation in infants with giant epiglottic cysts. It could be considered the first procedure for airway management in infants with large epiglottic cysts. It is also an effective and safe procedure to protect the airway away from pulmonary aspiration caused by accidental cysts rupture.

FOOTNOTES

Author contributions: Zheng JQ and Du L drafted the manuscript; Zhang WY supervised the writing of the manuscript; both authors participated in the management of the patient in this case report, and read and approved the manuscript.

Informed consent statement: Informed written consent was obtained from the patient's father for publication of this report and any accompanying images.

Conflict-of-interest statement: All authors declare that have no conflicts of interest.

CARE Checklist (2016) statement: The authors have read the CARE Checklist (2016) statement, and the manuscript was prepared and revised according to the CARE Checklist (2016) statement.

Open-Access: This article is an open-access article that was selected by an in-house editor and fully peer-reviewed by external reviewers. It is distributed in accordance with the Creative Commons Attribution NonCommercial (CC BY-NC 4.0) license, which permits others to distribute, remix, adapt, build upon this work non-commercially, and license their derivative works on different terms, provided the original work is properly cited and the use is non-commercial. See: <https://creativecommons.org/licenses/by-nc/4.0/>

Country/Territory of origin: China

ORCID number: Jian-Qiao Zheng 0000-0002-8091-1837; Li Du 0000-0002-1809-344X; Wei-Yi Zhang 0000-0001-6188-8451.

S-Editor: Wang LL

L-Editor: A

P-Editor: Wang LL

REFERENCES

- Mulcahy CF, Reddy SK, Wikner EE, Mudd PA. Neonatal airway anomaly: vallecular cyst. *BMJ Case Rep* 2017; **2017** [PMID: 29141934 DOI: 10.1136/bcr-2017-223082]
- Oelsen JM, Hewett KM, Discolo CM, Jackson BF. Congenital Vallecular Cyst as a Cause of Neonatal Stridor and Apnea. *Pediatr Emerg Care* 2018; **34**: e152-e154 [PMID: 30020251 DOI: 10.1097/PEC.0000000000001571]
- Sugiyama T, Kamijo A, Aoyama K, Kuroda Y, Masuyama K, Sugita K. Rapid development of severe respiratory distress due to a vallecular cyst in a 3-day-old infant. *Pediatr Int* 2012; **54**: 297-299 [PMID: 22507159 DOI: 10.1111/j.1442-200X.2011.03476.x]
- Batra UB, Kale S, Malik A. Anaesthetic management of an infant with vallecular cyst: A challenging situation. *Indian J Anaesth* 2012; **56**: 423-425 [PMID: 23087478 DOI: 10.4103/0019-5049.100842]
- Breysem L, Goosens V, Vander Poorten V, Vanhole C, Proesmans M, Smet M. Vallecular cyst as a cause of congenital stridor: report of five patients. *Pediatr Radiol* 2009; **39**: 828-831 [PMID: 19458946 DOI: 10.1007/s00247-009-1299-1]
- Li Y, Irace AL, Dombrowski ND, Perez-Atayde AR, Robson CD, Rahbar R. Vallecular cyst in the pediatric population: Evaluation and management. *Int J Pediatr Otorhinolaryngol* 2018; **113**: 198-203 [PMID: 30173985 DOI: 10.1016/j.ijporl.2018.07.040]
- Leibowitz JM, Smith LP, Cohen MA, Dunham BP, Guttenberg M, Elden LM. Diagnosis and treatment of pediatric vallecular cysts and pseudocysts. *Int J Pediatr Otorhinolaryngol* 2011; **75**: 899-904 [PMID: 21531029 DOI: 10.1016/j.ijporl.2011.03.032]
- Vorobeichik L, Hare GM, Zirkle M, Garavaglia MM. Airway Management of Incidental Vallecular Cysts in Adults. *A A Case Rep* 2015; **5**: 223-227 [PMID: 26657703 DOI: 10.1213/XAA.0000000000000222]
- Cheng KS, Ng JM, Li HY, Hartigan PM. Vallecular cyst and laryngomalacia in infants: report of six cases and airway management. *Anesth Analg* 2002; **95**: 1248-1250 [PMID: 12401604 DOI: 10.1097/00000539-200211000-00026]
- Sugita T, Arisaka H. AirWay Scope™ for Difficult Ventilation in a Patient With Epiglottic Cyst. *Anesth Prog* 2018; **65**: 204-205 [PMID: 30235438 DOI: 10.2344/anpr-66-01-03]
- Gupta A, Gupta N. Failed videolaryngoscopy in an infant with giant vallecular cyst managed successfully with a 'three-person technique' of fibre-optic intubation. *BMJ Case Rep* 2019; **12** [PMID: 31570357 DOI: 10.1136/bcr-2019-231035]
- Suzuki J, Hashimoto S, Watanabe K, Takahashi K. Congenital vallecular cyst in an infant: case report and review of 52 recent cases. *J Laryngol Otol* 2011; **125**: 1199-1203 [PMID: 21669020 DOI: 10.1017/S0022215111001368]
- Wong CM, Ghazal EA, Dyleski RA, Applegate RL 2nd. Management of Near-Complete Airway Obstruction Caused by a Vallecular Cyst in an Infant Using a Tongue Tip Traction Suture. *A A Case Rep* 2016; **6**: 31-33 [PMID: 26599736 DOI: 10.1213/XAA]
- Lin N, Li M, Shi S, Li TZ, Zhang BX. Shikani™ Seeing Optical Stylet-aided tracheal intubation in patients with a large epiglottic cyst. *Chin Med J (Engl)* 2011; **124**: 2795-2798 [PMID: 22040447]
- Choi GS, Park SI, Lee EH, Yoon SH. Awake Glidescope® intubation in a patient with a huge and fixed supraglottic mass - A case report-. *Korean J Anesthesiol* 2010; **59** Suppl: S26-S29 [PMID: 21286452 DOI: 10.4097/kjae.2010.59.S.S26]
- Kothandan H, Ho VK, Chan YM, Wong T. Difficult intubation in a patient with vallecular cyst. *Singapore Med J* 2013; **54**: e62-e65 [PMID: 23546038 DOI: 10.11622/smedj]
- Ajimi J, Nishikawa K, Niwa Y, Suzuki T. Successful tracheal intubation in a patient with a large epiglottic cyst using the MedAn video laryngoscope with Nishikawa blade. *J Clin Anesth* 2021; **71**: 110232 [PMID: 33706035 DOI: 10.1016/j.jclinane]
- Kalra S, Saraswat N, Kaur R, Agarwal R. Vallecular cyst in a newborn: a challenging airway. *Anaesth Intensive Care* 2011; **39**: 509-510 [PMID: 21675081]
- Ku AS. Vallecular cyst: report of four cases—one with co-existing laryngomalacia. *J Laryngol Otol* 2000; **114**: 224-226 [PMID: 10829117 DOI: 10.1258/0022215001905184]
- Pereira KD, MacGregor AR, Mitchell RB. Complications of neonatal tracheostomy: a 5-year review. *Otolaryngol Head Neck Surg* 2004; **131**: 810-813 [PMID: 15577773 DOI: 10.1016/j.otohns.2004.07.009]
- Choi YW, Chon JY, Moon HS, Kim JY, Lee JY. Anesthetic management of a neonate with congenital laryngeal cyst. *Korean J Anesthesiol* 2012; **63**: 282-283 [PMID: 23060991 DOI: 10.4097/kjae.2012.63.3.282]
- Reiersen DA, Gungor AA. Airway management in an infant with a giant vallecular cyst. *Am J Otolaryngol* 2014; **35**: 261-264 [PMID: 24462111 DOI: 10.1016/j.amjoto]
- Ouchi K, Onizawa Y, Kido T, Iwabuchi A, Sumazaki R. Congenital epiglottic cyst: Neck position-dependent respiratory distress in newborns. *Pediatr Int* 2017; **59**: 939-940 [PMID: 28653789 DOI: 10.1111/ped.13316]
- AlAbdulla AF. Congenital Vallecular Cyst Causing Airway Compromise in a 2-Month-Old Girl. *Case Rep Med* 2015; **2015**: 975859 [PMID: 26240568]
- Kislal FM, Acar B, Inan Y, Degerli S, Günbey E. Giant congenital epiglottic cyst presenting with airway obstruction at birth. *J Craniofac Surg* 2012; **23**: 602-603 [PMID: 22446425 DOI: 10.1097/SCS.0b013e31824cd79a]



Published by **Baishideng Publishing Group Inc**
7041 Koll Center Parkway, Suite 160, Pleasanton, CA 94566, USA

Telephone: +1-925-3991568

E-mail: bpgoffice@wjgnet.com

Help Desk: <https://www.f6publishing.com/helpdesk>

<https://www.wjgnet.com>

