

# World Journal of *Clinical Cases*

*World J Clin Cases* 2022 August 6; 10(22): 7620-8056



## Contents

Thrice Monthly Volume 10 Number 22 August 6, 2022

### OPINION REVIEW

- 7620** Whipple's operation with a modified centralization concept: A model in low-volume Caribbean centers  
*Cawich SO, Pearce NW, Naraynsingh V, Shukla P, Deshpande RR*

### REVIEW

- 7631** Role of micronutrients in Alzheimer's disease: Review of available evidence  
*Fei HX, Qian CF, Wu XM, Wei YH, Huang JY, Wei LH*

### MINIREVIEWS

- 7642** Application of imaging techniques in pancreaticobiliary maljunction  
*Wang JY, Mu PY, Xu YK, Bai YY, Shen DH*
- 7653** Update on gut microbiota in gastrointestinal diseases  
*Nishida A, Nishino K, Ohno M, Sakai K, Owaki Y, Noda Y, Imaeda H*
- 7665** Vascular complications of pancreatitis  
*Kalas MA, Leon M, Chavez LO, Canalizo E, Surani S*

### ORIGINAL ARTICLE

#### Clinical and Translational Research

- 7674** Network pharmacology and molecular docking reveal zedoary turmeric-trisomes in Inflammatory bowel disease with intestinal fibrosis  
*Zheng L, Ji YY, Dai YC, Wen XL, Wu SC*

#### Case Control Study

- 7686** Comprehensive proteomic signature and identification of CDKN2A as a promising prognostic biomarker and therapeutic target of colorectal cancer  
*Wang QQ, Zhou YC, Zhou Ge YJ, Qin G, Yin TF, Zhao DY, Tan C, Yao SK*

#### Retrospective Cohort Study

- 7698** Is anoplasty superior to scar revision surgery for post-hemorrhoidectomy anal stenosis? Six years of experience  
*Weng YT, Chu KJ, Lin KH, Chang CK, Kang JC, Chen CY, Hu JM, Pu TW*

#### Retrospective Study

- 7708** Short- (30-90 days) and mid-term (1-3 years) outcomes and prognostic factors of patients with esophageal cancer undergoing surgical treatments  
*Shi MK, Mei YQ, Shi JL*

- 7720** Effectiveness of pulsed radiofrequency on the medial cervical branches for cervical facet joint pain  
*Chang MC, Yang S*
- 7728** Clinical performance evaluation of O-Ring Halcyon Linac: A real-world study  
*Wang GY, Zhu QZ, Zhu HL, Jiang LJ, Zhao N, Liu ZK, Zhang FQ*
- 7738** Correlation between the warning symptoms and prognosis of cardiac arrest  
*Zheng K, Bai Y, Zhai QR, Du LF, Ge HX, Wang GX, Ma QB*
- 7749** Serum ferritin levels in children with attention deficit hyperactivity disorder and tic disorder  
*Tang CY, Wen F*
- 7760** Application of metagenomic next-generation sequencing in the diagnosis of infectious diseases of the central nervous system after empirical treatment  
*Chen YY, Guo Y, Xue XH, Pang F*
- 7772** Prognostic role of multiple abnormal genes in non-small-cell lung cancer  
*Yan LD, Yang L, Li N, Wang M, Zhang YH, Zhou W, Yu ZQ, Peng XC, Cai J*
- 7785** Prospective single-center feasible study of innovative autorelease bile duct supporter to delay adverse events after endoscopic papillectomy  
*Liu SZ, Chai NL, Li HK, Feng XX, Zhai YQ, Wang NJ, Gao Y, Gao F, Wang SS, Linghu EQ*

**Clinical Trials Study**

- 7794** Performance of Dexcom G5 and FreeStyle Libre sensors tested simultaneously in people with type 1 or 2 diabetes and advanced chronic kidney disease  
*Ólafsdóttir AF, Andelin M, Saeed A, Sofizadeh S, Hamoodi H, Jansson PA, Lind M*

**Observational Study**

- 7808** Complications of chronic pancreatitis prior to and following surgical treatment: A proposal for classification  
*Murruste M, Kirsimägi Ü, Kase K, Veršinina T, Talving P, Lepner U*
- 7825** Effects of comprehensive nursing on postoperative complications, mental status and quality of life in patients with glioma  
*Dong H, Zhang XL, Deng CX, Luo B*

**Prospective Study**

- 7832** Predictors of long-term anxiety and depression in discharged COVID-19 patients: A follow-up study  
*Boyraz RK, Şahan E, Boylu ME, Kırpınar İ*

**META-ANALYSIS**

- 7844** Same-day single-dose vs large-volume split-dose regimens of polyethylene glycol for bowel preparation: A systematic review and meta-analysis  
*Pan H, Zheng XL, Fang CY, Liu LZ, Chen JS, Wang C, Chen YD, Huang JM, Zhou YS, He LP*

- 7859** Rectal nonsteroidal anti-inflammatory drugs, glyceryl trinitrate, or combinations for prophylaxis of post-endoscopic retrograde cholangiopancreatography pancreatitis: A network meta-analysis

*Shi QQ, Huang GX, Li W, Yang JR, Ning XY*

- 7872** Effect of celecoxib on improving depression: A systematic review and meta-analysis

*Wang Z, Wu Q, Wang Q*

### CASE REPORT

- 7883** Rectal mature teratoma: A case report

*Liu JL, Sun PL*

- 7890** Antibiotic and glucocorticoid-induced recapitulated hematological remission in acute myeloid leukemia: A case report and review of literature

*Sun XY, Yang XD, Yang XQ, Ju B, Xiu NN, Xu J, Zhao XC*

- 7899** Non-secretory multiple myeloma expressed as multiple extramedullary plasmacytoma with an endobronchial lesion mimicking metastatic cancer: A case report

*Lee SB, Park CY, Lee HJ, Hong R, Kim WS, Park SG*

- 7906** Latamoxef-induced severe thrombocytopenia during the treatment of pulmonary infection: A case report

*Zhang RY, Zhang JJ, Li JM, Xu YY, Xu YH, Cai XJ*

- 7913** Multicentric reticulohistiocytosis with prominent skin lesions and arthritis: A case report

*Xu XL, Liang XH, Liu J, Deng X, Zhang L, Wang ZG*

- 7924** Brainstem abscesses caused by *Listeria monocytogenes*: A case report

*Wang J, Li YC, Yang KY, Wang J, Dong Z*

- 7931** Primary hypertension in a postoperative paraganglioma patient: A case report

*Wei JH, Yan HL*

- 7936** Long-term survival of gastric mixed neuroendocrine-non-neuroendocrine neoplasm: Two case reports

*Woo LT, Ding YF, Mao CY, Qian J, Zhang XM, Xu N*

- 7944** Percutaneous transforaminal endoscopic decompression combined with percutaneous vertebroplasty in treatment of lumbar vertebral body metastases: A case report

*Ran Q, Li T, Kuang ZP, Guo XH*

- 7950** Atypical imaging features of the primary spinal cord glioblastoma: A case report

*Liang XY, Chen YP, Li Q, Zhou ZW*

- 7960** Resection with limb salvage in an Asian male adolescent with Ewing's sarcoma: A case report

*Lai CY, Chen KJ, Ho TY, Li LY, Kuo CC, Chen HT, Fong YC*

- 7968** Early detection of circulating tumor DNA and successful treatment with osimertinib in thr790met-positive leptomeningeal metastatic lung cancer: A case report

*Xu LQ, Wang YJ, Shen SL, Wu Y, Duan HZ*

- 7973** Delayed arterial symptomatic epidural hematoma on the 14<sup>th</sup> day after posterior lumbar interbody fusion: A case report  
*Hao SS, Gao ZF, Li HK, Liu S, Dong SL, Chen HL, Zhang ZF*
- 7982** Clinical and genetic analysis of nonketotic hyperglycinemia: A case report  
*Ning JJ, Li F, Li SQ*
- 7989** Ectopic Cushing's syndrome in a patient with metastatic Merkel cell carcinoma: A case report  
*Ishay A, Touma E, Vornicova O, Dodiuk-Gad R, Goldman T, Bisharat N*
- 7994** Occurrence of MYD88L265P and CD79B mutations in diffuse large b cell lymphoma with bone marrow infiltration: A case report  
*Huang WY, Weng ZY*
- 8003** Rare case of compartment syndrome provoked by inhalation of polyurethane agent: A case report  
*Choi JH, Oh HM, Hwang JH, Kim KS, Lee SY*
- 8009** Acute ischemic Stroke combined with Stanford type A aortic dissection: A case report and literature review  
*He ZY, Yao LP, Wang XK, Chen NY, Zhao JJ, Zhou Q, Yang XF*
- 8018** Compound-honeysuckle-induced drug eruption with special manifestations: A case report  
*Zhou LF, Lu R*
- 8025** Spontaneous internal carotid artery pseudoaneurysm complicated with ischemic stroke in a young man: A case report and review of literature  
*Zhong YL, Feng JP, Luo H, Gong XH, Wei ZH*
- 8034** Microcystic adnexal carcinoma misdiagnosed as a "recurrent epidermal cyst": A case report  
*Yang SX, Mou Y, Wang S, Hu X, Li FQ*
- 8040** Accidental discovery of appendiceal carcinoma during gynecological surgery: A case report  
*Wang L, Dong Y, Chen YH, Wang YN, Sun L*
- 8045** Intra-ampullary papillary-tubular neoplasm combined with ampullary neuroendocrine carcinoma: A case report  
*Zavrtanik H, Luzar B, Tomažič A*

**LETTER TO THE EDITOR**

- 8054** Commentary on "Primary orbital monophasic synovial sarcoma with calcification: A case report"  
*Tokur O, Aydin S, Karavas E*

**ABOUT COVER**

Editorial Board Member of *World Journal of Clinical Cases*, Bennete Aloysius Fernandes, MDS, Professor, Faculty of Dentistry, SEGi University, Kota Damansara 47810, Selangor, Malaysia. drben17@yahoo.com

**AIMS AND SCOPE**

The primary aim of *World Journal of Clinical Cases* (WJCC, *World J Clin Cases*) is to provide scholars and readers from various fields of clinical medicine with a platform to publish high-quality clinical research articles and communicate their research findings online.

WJCC mainly publishes articles reporting research results and findings obtained in the field of clinical medicine and covering a wide range of topics, including case control studies, retrospective cohort studies, retrospective studies, clinical trials studies, observational studies, prospective studies, randomized controlled trials, randomized clinical trials, systematic reviews, meta-analysis, and case reports.

**INDEXING/ABSTRACTING**

The WJCC is now abstracted and indexed in Science Citation Index Expanded (SCIE, also known as SciSearch®), Journal Citation Reports/Science Edition, Current Contents®/Clinical Medicine, PubMed, PubMed Central, Scopus, Reference Citation Analysis, China National Knowledge Infrastructure, China Science and Technology Journal Database, and Superstar Journals Database. The 2022 Edition of Journal Citation Reports® cites the 2021 impact factor (IF) for WJCC as 1.534; IF without journal self cites: 1.491; 5-year IF: 1.599; Journal Citation Indicator: 0.28; Ranking: 135 among 172 journals in medicine, general and internal; and Quartile category: Q4. The WJCC's CiteScore for 2021 is 1.2 and Scopus CiteScore rank 2021: General Medicine is 443/826.

**RESPONSIBLE EDITORS FOR THIS ISSUE**

Production Editor: *Xu Guo*; Production Department Director: *Xiang Li*; Editorial Office Director: *Jin-Lei Wang*.

**NAME OF JOURNAL**

*World Journal of Clinical Cases*

**ISSN**

ISSN 2307-8960 (online)

**LAUNCH DATE**

April 16, 2013

**FREQUENCY**

Thrice Monthly

**EDITORS-IN-CHIEF**

Bao-Gan Peng, Jerzy Tadeusz Chudek, George Kontogeorgos, Maurizio Serati, Ja Hyeon Ku

**EDITORIAL BOARD MEMBERS**

<https://www.wjgnet.com/2307-8960/editorialboard.htm>

**PUBLICATION DATE**

August 6, 2022

**COPYRIGHT**

© 2022 Baishideng Publishing Group Inc

**INSTRUCTIONS TO AUTHORS**

<https://www.wjgnet.com/bpg/gerinfo/204>

**GUIDELINES FOR ETHICS DOCUMENTS**

<https://www.wjgnet.com/bpg/GerInfo/287>

**GUIDELINES FOR NON-NATIVE SPEAKERS OF ENGLISH**

<https://www.wjgnet.com/bpg/gerinfo/240>

**PUBLICATION ETHICS**

<https://www.wjgnet.com/bpg/GerInfo/288>

**PUBLICATION MISCONDUCT**

<https://www.wjgnet.com/bpg/gerinfo/208>

**ARTICLE PROCESSING CHARGE**

<https://www.wjgnet.com/bpg/gerinfo/242>

**STEPS FOR SUBMITTING MANUSCRIPTS**

<https://www.wjgnet.com/bpg/GerInfo/239>

**ONLINE SUBMISSION**

<https://www.f6publishing.com>



## Atypical imaging features of the primary spinal cord glioblastoma: A case report

Xin-Yu Liang, Yao-Ping Chen, Qiao Li, Ze-Wang Zhou

**Specialty type:** Radiology, nuclear medicine and medical imaging

**Provenance and peer review:** Unsolicited article; Externally peer reviewed.

**Peer-review model:** Single blind

**Peer-review report's scientific quality classification**

Grade A (Excellent): A  
Grade B (Very good): B  
Grade C (Good): 0  
Grade D (Fair): 0  
Grade E (Poor): 0

**P-Reviewer:** Burger MC, Germany; Kołat D, Poland

**Received:** December 13, 2021

**Peer-review started:** December 13, 2021

**First decision:** April 8, 2022

**Revised:** April 29, 2022

**Accepted:** June 23, 2022

**Article in press:** June 23, 2022

**Published online:** August 6, 2022



**Xin-Yu Liang, Ze-Wang Zhou,** Department of Radiology, The First Affiliated Hospital of Guangzhou University of Chinese Medicine, Guangzhou 510405, Guangdong Province, China

**Yao-Ping Chen,** Department of Radiology, The Third Affiliated Hospital of Sun Yat-Sen University, Guangzhou 510630, Guangdong Province, China

**Qiao Li,** Department of Endocrinology, The First Affiliated Hospital of Guangzhou University of Chinese Medicine, Guangzhou 510405, Guangdong Province, China

**Corresponding author:** Ze-Wang Zhou, MM, Doctor, Department of Radiology, The First Affiliated Hospital of Guangzhou University of Chinese Medicine, No. 12 Airport Road, Guangzhou 510405, Guangdong Province, China. [zhouzewang666@163.com](mailto:zhouzewang666@163.com)

### Abstract

#### BACKGROUND

Primary spinal cord (PSC) glioblastoma (GB) is an extremely rare but fatal primary tumor of the central nervous system and associated with a poor prognosis. While typical tumor imaging features are generally easy to recognize, glioblastoma multiforme can have a wide range of imaging findings. Atypical GB is often misdiagnosed, which usually delays the optimal time for treatment. In this article, we discuss a clinical case of pathologically confirmed PSC GB under the guise of benign tumor imaging findings, as well as the most recent literature pertaining to PSC GB.

#### CASE SUMMARY

A 70-year-old female complained of limb weakness lasting more than 20 d. Irregular masses were observed inside and outside the left foramina of the spinal canal at C7-T1 on medical imaging. Based on the imaging features, radiologists diagnosed the patient with schwannoma. Tumor resection was performed under general anesthesia. The final histopathological findings revealed a final diagnosis of PSC GB, world health organization Grade IV. The patient subsequently underwent a 4-wk course of radiotherapy (60 Gy in 20 fractions) combined with temozolomide chemotherapy. The patient was alive at the time of submission of this manuscript.

#### CONCLUSION

Atypical GB presented unusual imaging findings, which led to misdiagnosis. Therefore, a complete recognition of imaging signs may facilitate early accurate diagnosis.

**Key Words:** Primary spinal cord glioblastoma; Atypical imaging features; Benign-looking; Misdiagnosis; Pathology confirmed; Case report

©The Author(s) 2022. Published by Baishideng Publishing Group Inc. All rights reserved.

**Core Tip:** This is the first literature review to summarize the imaging features of surgical and pathologically confirmed glioblastoma in the spinal cord. Lesions reported in previous cases were located in the spinal canal exclusively. Intramedullary glioma that extended beyond the spinal canal has not been reported before. In this case, the tumor grew across and beyond the spinal canal and appeared benign, which led to the misdiagnosis of neurogenic tumors. A definitive diagnosis requires histopathological confirmation. However, complete recognition of the imaging signs of the disease may facilitate early accurate diagnosis.

**Citation:** Liang XY, Chen YP, Li Q, Zhou ZW. Atypical imaging features of the primary spinal cord glioblastoma: A case report. *World J Clin Cases* 2022; 10(22): 7950-7959

**URL:** <https://www.wjgnet.com/2307-8960/full/v10/i22/7950.htm>

**DOI:** <https://dx.doi.org/10.12998/wjcc.v10.i22.7950>

## INTRODUCTION

Glioblastoma (GB) is the most common malignancy of the nervous system. Primary spinal cord (PSC) GB is a fairly rare tumor, accounting for 1% to 5% of all GB and 1.5% of all spinal cord neoplasms[1]. Due to its rare occurrence, most reported studies are either case reports or focused on its treatment and prognosis. Apart from histopathological findings, a precise imaging diagnosis also plays an essential role in the prognosis of GB. Furthermore, as it presents a variety of imaging features, it is difficult to differentiate this tumor from ependymoma and astrocytoma as well as neurogenic neoplasms[2,3]. To the best of our knowledge, this is the first literature review to summarize the imaging findings of this rare disease. Due to a misdiagnosed case of pathologically confirmed PSC GB with atypical imaging features in our clinical practice (Figure 1), we reviewed and summarized the imaging and clinical features of PSC GB from 2011 to 2021. By aggregating these data, we intend to improve the diagnostic accuracy of PSC GB for radiologists and clinicians.

## CASE PRESENTATION

### Chief complaints

A 70-year-old female, with no history of previous illnesses, complained of limb weakness and an inability to walk lasting more than 20 d.

### History of present illness

The patient reported feeling weak in her limbs, especially her left arm and leg. She described that, in the previous 2 wk, she had been unable to walk as before.

### History of past illness

The patient had no chronic illnesses or history of surgery.

### Personal and family history

The patient did not have any significant family history.

### Physical examination

Physical examination revealed no deformity in the spine and limbs, with a normal cranial nerve sensation detected. However, there was decreased needling reflection below the bilateral nipples and a muscle strength score of Grade 0 in both lower limbs. Additionally, bilateral abdominal reflexes, anal sphincter reflex, bilateral knee tendon, and Achilles tendon reflexes were absent.

### Imaging examination

In the cervical computed tomography and magnetic resonance imaging (MRI) scans (Figures 2 and 3), irregular masses were observed inside and outside of the left foramina of the spinal canal, at C7-T1. The



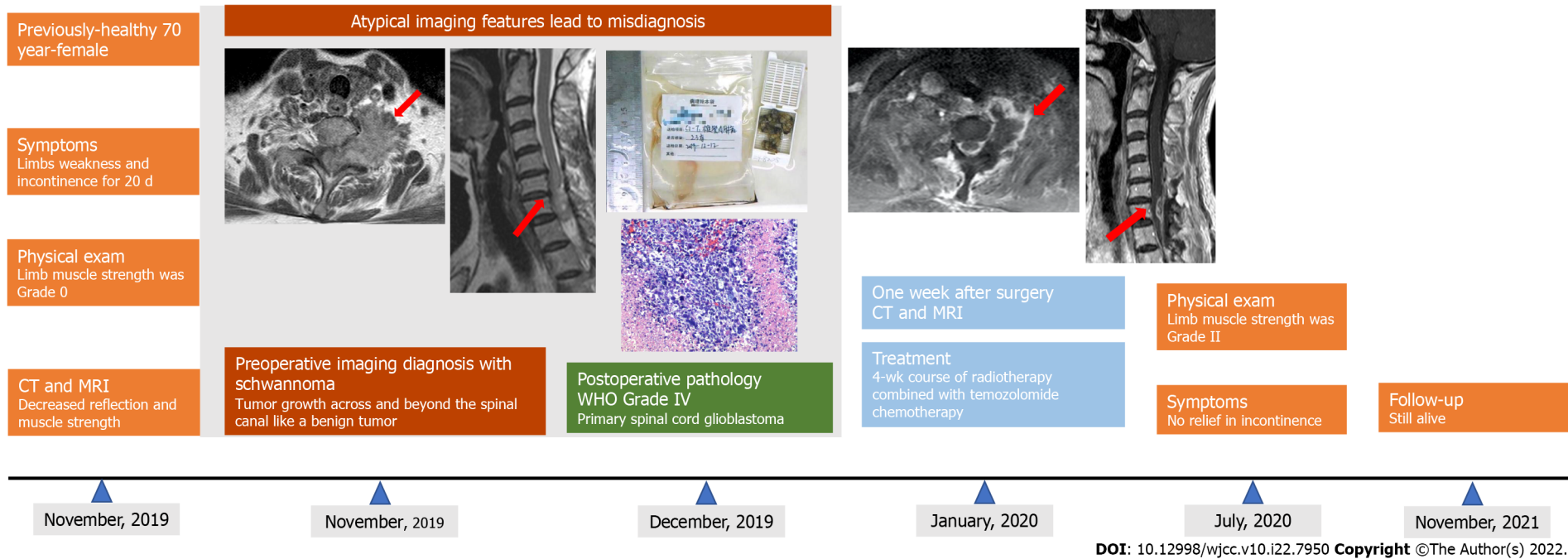


Figure 1 Timeline of this case report. CT: Computed tomography; MRI: Magnetic resonance imaging; WHO: World Health Organization.

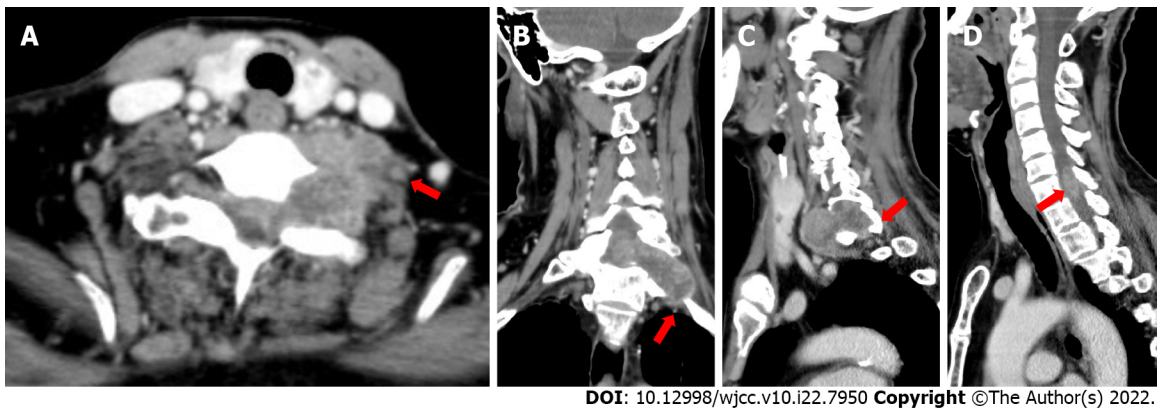
margins between the medial part and the spinal cord were not clear, whereas the lateral margin was rough, and the foramina was enlarged, with a significantly heterogeneous enhancement.

### MULTIDISCIPLINARY EXPERT CONSULTATION

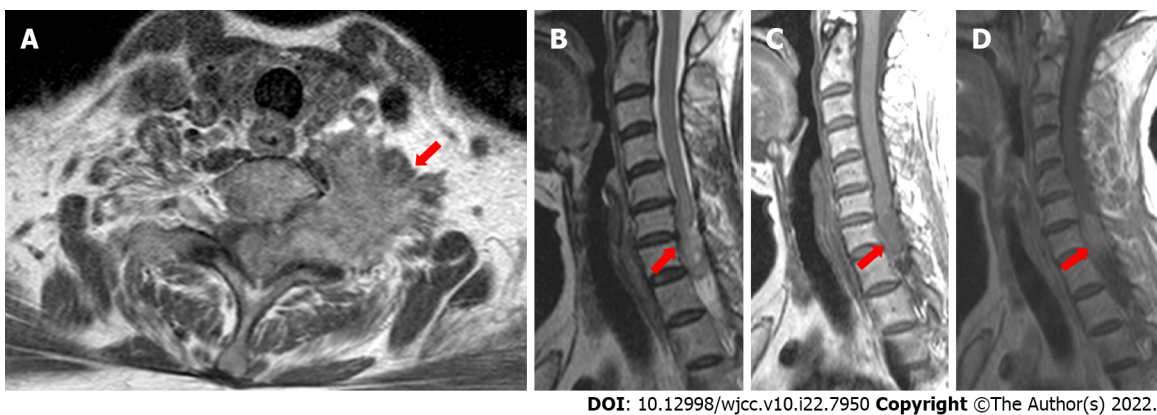
According to the results of physical examinations and imaging features, the physicians and radiologists made an initial diagnosis of a benign tumor, like schwannoma. A section surgery was recommended.

### FINAL DIAGNOSIS

Based on the imaging features, radiologists, and multidisciplinary expert conclusion, the final diagnosis was schwannoma.



**Figure 2** Computed tomography images of lesions of the present case. A and B: The tumor was irregular in shape, growing across and beyond the left foramina; C: The left intervertebral foramina was enlarged with inhomogeneous enhancement; D: The lesion was intramedullary and indistinctly demarcated from the surrounding spinal cord.



**Figure 3** Magnetic resonance images of the present case. A-C: The tumor was irregular in shape with a rough margin, and having slightly lower signal intensity on T1-weighted imaging and slightly higher signal intensity on T2-weighted imaging; D: The mass had heterogeneous enhancement.

## TREATMENT

After the primary diagnosis, C7-T1 spinal canal tumor resection was performed under general anesthesia. During the procedure, the surgeons noticed edema from the C7-T1 spinal cord, with the residing tumor on the left side, which was obscuring the boundary of the spinal cord. The tumor crossed the foramina and was in proximity to the vertebral and internal carotid arteries and left lung tip. The C7 nerve root was observed passing through it, with a visible small amount of subarachnoid hemorrhage. After resection of the tumor (Figure 4A), histopathological findings revealed a primary spinal cord glioblastoma, World Health Organization (WHO) Grade IV (Figure 4B and C).

The patient underwent MRI re-examination 1 wk after surgery (Figure 5). She subsequently underwent a 4-wk course of radiotherapy (60 Gy in 20 fractions) combined with temozolomide chemotherapy.

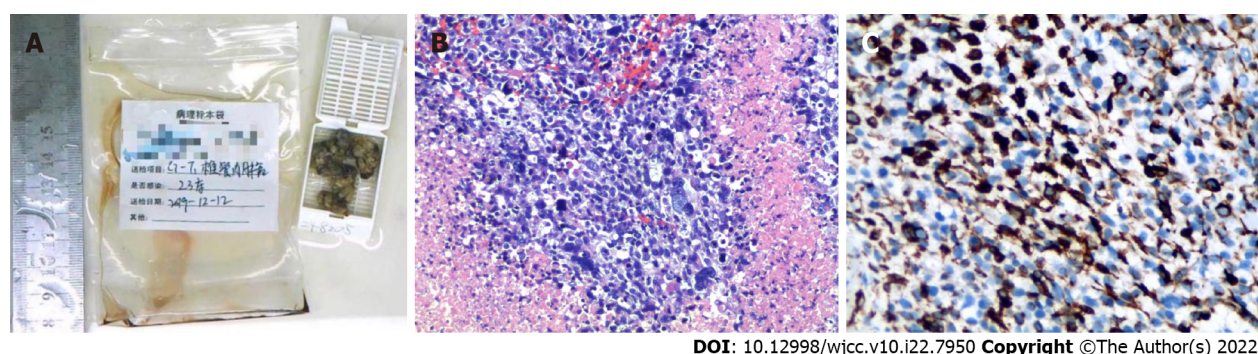
## OUTCOME AND FOLLOW-UP

For the next 6 mo, the patient's upper limb muscle strength was Grade II, although lower limb muscle strength was Grade 0, with no relief in incontinence. However, the patient is still alive at this time (day of submission of this manuscript).

## DISCUSSION

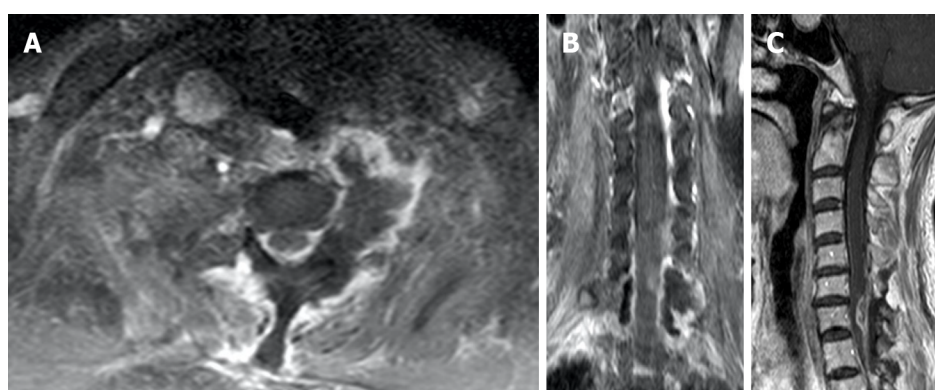
### Significance

This is one of the rare cases of PSC GB that was characterized by tumor growth across and beyond the



DOI: 10.12998/wjcc.v10.i22.7950 Copyright ©The Author(s) 2022.

**Figure 4** Diagnosis of World Health Organization Grade IV primary spinal cord glioblastoma was made. A: Resected gross tissue; B and C: Histopathology imaging (magnification  $\times 200$ ). Pleomorphic astrocytic cells with marked nuclear atypia and brisk mitotic activity were observed along with necrosis and microvascular proliferation. Immunohistochemically, the cells were slightly positive for glial fibrillary acidic protein, p53, and vimentin and negative for S-100, isocitrate dehydrogenase, and H3K27M. The proliferation index (measured by Ki67) was found to be at 30%.



DOI: 10.12998/wjcc.v10.i22.7950 Copyright ©The Author(s) 2022.

**Figure 5** Magnetic resonance imaging re-examination 1 wk after tumor resection. A: Axial view; B: Coronal view; C: Sagittal view.

spinal canal, like a benign tumor, which led to the misdiagnosis of neurogenic tumors. To the best of our knowledge, an intramedullary glioma that extends beyond the spinal canal has not been reported before. Also, lesions reported previously were located in the spinal canal exclusively.

### Literature review

For conducting the extensive literature review, articles were selected in PubMed and Google Scholar for the most recent 10 years (2011-2021) by using search terms of “spinal cord glioblastoma,” “spinal cord malignant glioma,” and “spinal cord malignant neoplasm.” The search resulted in 79 publications, which were carefully screened by two authors (Liang XY and Zhou ZW) based on the following criteria: (1) Patients with surgically and pathologically confirmed PSC GB; (2) Patients with whole clinical information and high-quality preoperative computed tomography/MR images; and (3) Only literature available in English language. However, publications were excluded from the study if they reported: (1) PSC GB with other malignant or benign tumors; (2) Patients with secondary spinal cord GB who had previously undergone low-grade glioma resection; or (3) Patients who had been diagnosed with primary cerebral GB secondary metastases. The publications were also examined for patient clinical details and reported department to rule out duplicates. After the screening, 8 studies (involving 11 patients) fulfilled our requirements and were included in the analysis. The clinical and imaging characteristics of these 11 lesions are listed in Table 1. The detailed screening flow chart is shown in Figure 6.

### Imaging features

Generally, the typical imaging features of GB can be easily recognized by most radiologists. However, benign-looking masses, cystic lesions, multifocal/multicentric tumors, and spinal cord abnormalities may all represent features of GB[2]. Therefore, a precise preoperative neuroimaging diagnosis is much more difficult, owing to the high variability of PSC GB. MRI is widely used in early diagnosis and preoperative evaluation of PSC GBs as a non-destructive and high-qualified imaging modality[2,3]. Usually, PSC GBs appear as infiltrative and expansile intramedullary lesions, with T2 hyperintensity and T1 isointensity or hypointensity with different heterogeneous enhancement post-contrast on T1[2,3]. Both the location and shape of the tumor play significant roles in the radiological differential



Table 1 Review of the literature on primary spinal cord glioblastoma with qualified magnetic resonance images

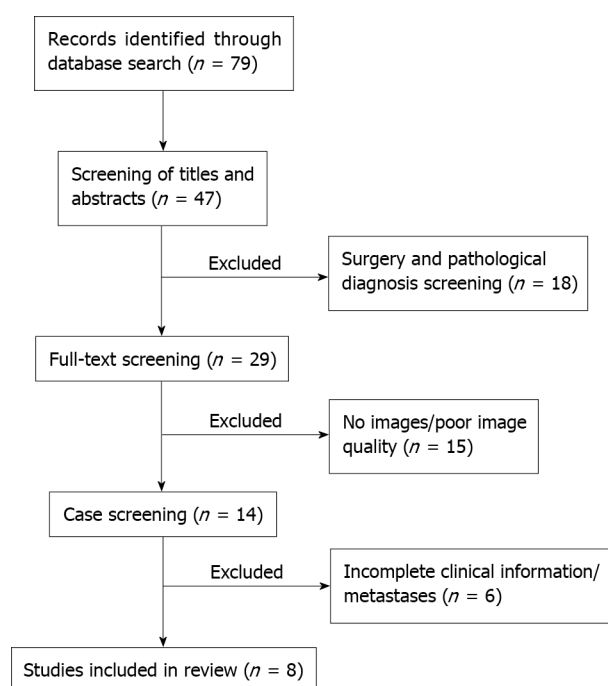
Case No.	Ref.	Age/sex	Symptoms	Lesion location	Intramedullary only	Imaging findings	Surgery/therapy	Survival in month
1	Ferrante <i>et al</i> [3], 2021	34 yr/F	MW, SD	Nearly entire cervical spinal cord and medulla oblongata	Yes	Isointense to hypointense on T1WI, isointense to hyperintense on T2WI, homogeneous enhancement	None	NR
		64 yr/M	MW, SD	Conus medullaris	Yes	Hyperintense on T2WI, peripheral enhancement, necrosis enhancing nodule	STR, radio/chemotherapy	33
		47 yr/M	Paresthesia, pain, MW, SD	Cervical and thoracic	Yes	Multifocal lesion (C5-C7) and (T3-T5), peripheral enhancement, necrotic center	Biopsy, radio/chemotherapy	10
2	Shen <i>et al</i> [4], 2020	47 yr/F	Paresthesia, paralysis	T12	Yes	T12 nodular, isointense to hyperintense on T2WI, central significant enhancement	surgical resection, NR	NR
3	Delgado <i>et al</i> [5], 2019	21 yr/F	Pain, weakness, paresthesia	T10-T12, L1	Yes	60 mm expansile mass, T10-T12 down to L1, nodular significant enhancement	NTR, radio/chemotherapy	Recurrence in 4 mo
4	Chanchotisatien <i>et al</i> [6], 2019	27 yr/F	Dysuria, numbness, weakness, back Pain	T4-T12, T5-T12, respectively	No	Homogenous, hyperintense T2WI, intra-/extramedullary regions from T4-T12 and T5-T12, respectively, homogenous enhancement	Biopsy, radio/chemotherapy	NR
5	Caro-Osorio <i>et al</i> [7], 2018	48 yr/F	Numbness, pain	C1-C3	Yes	Hypointense on T1WI, hyperintense on T2WI, heterogeneous enhancement	STR, radio/chemotherapy	8
6	Shen <i>et al</i> [1], 2017	15 yr/F	Numbness, weakness	C4-C7	Yes	Hyperintense on T2WI, inhomogeneous enhancement	NTR, radio/chemotherapy	13
7	Nunn <i>et al</i> [12], 2017	31 yr/M	MW, SD	T9-T12	Yes	Hyperintense on T2WI, spinal cord expanding, heterogeneous enhancement	Surgical resection, radio/chemotherapy	14
8	Prasad <i>et al</i> [13], 2012	15 yr/F	Paraparesis, dyesthesia, urinary incontinence, SD	C6-T7	Yes	Enlargement of cord, heterogeneously enhancing	STR, radio/chemotherapy	6
		35 yr/M	Pain, paraplegia, urinary incontinence, SD	T11-L1	Yes	Enlargement of cord, heterogeneously enhancing	NTR, radio/chemotherapy	15

F: Female; M: Male; MW: Motor weakness; NR: No relief; NTR: Near total resection; SD: Sensory disturbances; STR: Subtotal resection; WI: Weighted imaging.

diagnosis of intramedullary lesions.

In our case, the tumor was detected as a dumbbell mass, spanning the intramedullary and extramedullary region through the foramina. This disguised appearance led us to an erroneous diagnosis of the neurogenic tumor. However, in the reviewed publications, the tumor had an appearance of nodular[3,4], elongated lesions, growing along the spinal cord and confined to the intramedullary area[1,5-7].

The distinction of PSC GB from pathologies like myelitis or other types of intramedullary tumors, such as astrocytomas or ependymomas, are most difficult due to its nonspecific and often very similar



DOI: 10.12998/wjcc.v10.i22.7950 Copyright ©The Author(s) 2022.

Figure 6 Detailed flow of screening of publications for review of the literature.

manifestations. The majority of ependymomas are often hyperintense on T2-weighted imaging with inhomogeneous enhancement after injection of gadolinium. Usually, ependymomas show high uptake of 18F-fluorodeoxyglucose, while myxopapillary ependymomas have low uptake of fluorodeoxyglucose [4]. Pilocytic astrocytomas often appear as a well-circumscribed mass with a highly enhanced T2 signal. Nonconventional MRI sequences, such as diffusion tensor images and dynamic susceptibility contrast perfusion weighted imaging, may provide more comprehensive information, which can be useful to differentiate and grade the lesion[8].

A normalized (referenced to brain region of interest) relative cerebral blood volume threshold of 1.75 has been used to predict GB progression. An increase in normalized relative cerebral blood volume (> 1.75) with a decrease in fractional anisotropy of the corresponding region of the tumor might suggest a high-grade glioma[8]. In our case, the tumor demonstrated atypical MRI and computed tomography appearances of PSC GB, although prior familiarity with these imaging features may help to differentiate from other intramedullary tumors.

### Clinical characteristics

PSC GB is extremely rare, reported in about 1.5% of all the spinal cord tumors[9]. Due to its rare occurrence, few studies focus on it. Most of the published literature on PSC GB are case reports. Therefore, due to the lack of properly related literature, the clinical features, optimal therapy, and prognosis of PSC GB remain controversial[10]. This tumor is more prone to grow in the cervical or cervicothoracic region and is associated with severe disability and poor prognosis in most patients[11]. The early symptoms of these patients are usually weakness of unilateral or bilateral limbs[1,3,5], sensorimotor disorders, and incontinence[6,12,13]. However, when accompanied by metastasis of other parts, the symptoms are usually different.

To the best of our knowledge, the largest sample study involving 190 PSC GB patients was reported by Moinuddin *et al*[14]. They found that PSC GB had a higher incidence in the younger age group (age < 18). In contrast, our patient's age (70 years old) contributes to the rarity of the present case. They also reported a better overall survival in the 18-year-old to 65-year-old group (13.2 mo)[14]. Previous studies have also suggested that genetic mutations may be a contributing factor for the onset of the disease. It has been observed that patients with constitutional mismatch repair deficiency are more prone to develop high-grade gliomas in the central nervous system[15].

### Pathology diagnosis

Due to its diverse and heterogeneous nature, PSC GB is difficult to diagnose merely by imaging techniques. Most PSC GB are confirmed by histopathological parameters, including nuclear atypia, mitotic activity, vascular proliferation, and necrosis[16,17], along with immunohistochemical parameters, such as glial fibrillary acidic protein and S-Ifln protein 100 (S-100) positivity with a high Ki-67 index[16-18].

The tissue section of our patient revealed many pleomorphic astrocytic cells with marked nuclear atypia and brisk mitotic activity, which was accompanied by necrosis and microvascular proliferation. The diagnosis of WHO Grade IV GB is mainly based on the routine histopathological findings[16]. Immunohistochemically, the cells were slightly positive for glial fibrillary acidic protein, p53, and vimentin but were negative for S-100, isocitrate dehydrogenase, and histone H3 lysine 27 methylation (H3K27M). The proliferation index (measured by Ki67) was about 30% in the resected tumor. High-grade glioma with isocitrate dehydrogenase gene mutation and positive for H3K27M is reported to have a significantly better prognosis[17,19,20]. However, H3K27M-positive PSC GBs are also at risk of developing local hemorrhage[18]. Before the submission of the current manuscript, our patient was still alive after surgery and radio-/chemotherapy. The survival of our patient might be attributed to an H3K27M mutation.

### Treatments and prognosis

Although not implying causation, there is a trend towards improved overall survival with the use of chemotherapy and surgical resection for patients suffering from GB[21]. Despite the advancement in surgical techniques and postoperative adjuvant therapies, PSC GB still has an overall poor prognosis[9, 21]. The overall survival in patients with PSC GB is approximately 10-14 mo[9]. The disease often leads to severe neurological deficits and poor quality of life, even after treatment.

In our case, the patient underwent surgical resection with subsequent radiotherapy and chemotherapy. Unfortunately, neither treatment alleviated or improved her symptoms nor improved her quality of life. According to a single-center retrospective study by Cheng *et al*[22], the extent of surgical resection did not have any significance, but radiotherapy accompanied with postoperative chemotherapy was the major prognostic factor for longer survival in adult GB patients. However, the previous study reported that gross-total resection followed by radiotherapy had beneficial effects on the overall outcome of PSC GB in the pediatric age group[23,24]. More effective and targeted therapies need specific investigation in the future for helping patients with unique gene mutations achieve better prognosis[25,26]. Further, broadening treatment avenues would help improve the efficacy of therapies and help in recovery for these patients.

### Limitations

Due to the large mass in C7-T1, the conventional cervical MR field of view was not able to cover the whole lesion.

## CONCLUSION

A definitive PSC GB diagnosis requires histopathological confirmation. However, complete recognition of the imaging signs of the disease may facilitate early accurate diagnosis.

## FOOTNOTES

**Author contributions:** Liang XY contributed to literature retrieval and screening, data reduction, and drafting of the manuscript; Chen YP contributed to literature retrieval and screening, and data analysis; Li Q contributed to acquisition of data and images, and data analysis; Zhou ZW contributed to study design and revising the manuscript critically for important intellectual content.

**Supported by** the “Excellent Doctoral Dissertation Incubation Grant of First Clinical School of Guangzhou University of Chinese Medicine”, No. YB201903.

**Informed consent statement:** The obtained informed consent is presented in the supplementary materials for the case report to be published.

**Conflict-of-interest statement:** All the authors report no relevant conflicts of interest for this article.

**CARE Checklist (2016) statement:** The authors have read the CARE Checklist (2016), and the manuscript was prepared and revised according to the CARE Checklist (2016).

**Open-Access:** This article is an open-access article that was selected by an in-house editor and fully peer-reviewed by external reviewers. It is distributed in accordance with the Creative Commons Attribution NonCommercial (CC BY-NC 4.0) license, which permits others to distribute, remix, adapt, build upon this work non-commercially, and license their derivative works on different terms, provided the original work is properly cited and the use is non-commercial. See: <http://creativecommons.org/licenses/by-nc/4.0/>.

**Country/Territory of origin:** China

**ORCID number:** Xin-Yu Liang 0000-0002-0526-2048; Yao-Ping Chen 0000-0001-8570-3722; Qiao Li 0000-0002-4133-1258; Ze-Wang Zhou 0000-0002-2489-3291.

**S-Editor:** Yan JP

**L-Editor:** A

**P-Editor:** Yan JP

## REFERENCES

- 1 **Shen CX**, Wu JF, Zhao W, Cai ZW, Cai RZ, Chen CM. Primary spinal glioblastoma multiforme: A case report and review of the literature. *Medicine (Baltimore)* 2017; **96**: e6634 [PMID: 28422860 DOI: 10.1097/MD.0000000000006634]
- 2 **Khandwala K**, Mubarak F, Minhas K. The many faces of glioblastoma: Pictorial review of atypical imaging features. *Neuroradiol J* 2021; **34**: 33-41 [PMID: 33081585 DOI: 10.1177/1971400920965970]
- 3 **Ferrante P**, Mora JA, Salazar L, Sáez EM, Auger C, Rovira À. MR imaging findings in primary spinal cord glioblastoma. *Radiol Case Rep* 2021; **16**: 72-77 [PMID: 33193932 DOI: 10.1016/j.radcr.2020.10.043]
- 4 **Shen G**, Ma H, Pan L, Su M, Kuang A. FDG PET/CT and MRI in Primary Spinal Cord Glioblastoma. *Clin Nucl Med* 2020; **45**: e144-e145 [PMID: 31693607 DOI: 10.1097/RLU.0000000000002800]
- 5 **Delgado BJ**, Moosavi L, Rangel E, Stull W, Polineni RD, Chen J, Cobos E. An Unusual Presentation of Spinal Giant Cell Glioblastoma in a 21-Year-Old Female. *J Investig Med High Impact Case Rep* 2019; **7**: 2324709619868255 [PMID: 31394931 DOI: 10.1177/2324709619868255]
- 6 **Chanchotisatien A**, Xiong J, Yu J, Chu S. Exophytic Primary Intramedullary Spinal Cord Glioblastoma: Case Report and Critical Review of Literature. *World Neurosurg* 2019; **122**: 573-576 [PMID: 30476666 DOI: 10.1016/j.wneu.2018.11.113]
- 7 **Caro-Orsorio E**, Herrera-Castro JC, Barbosa-Quintana A, Benvenuti-Regato M. Primary Spinal Cord Small-Cell Glioblastoma: Case Report and Literature Review. *World Neurosurg* 2018; **118**: 69-70 [PMID: 30017760 DOI: 10.1016/j.wneu.2018.07.007]
- 8 **Liu X**, Germin BI, Ekholm S. A case of cervical spinal cord glioblastoma diagnosed with MR diffusion tensor and perfusion imaging. *J Neuroimaging* 2011; **21**: 292-296 [PMID: 20040012 DOI: 10.1111/j.1552-6569.2009.00459.x]
- 9 **Alharbi B**, Alammam H, Alkhaibary A, Alharbi A, Khairy S, Allassiri AH, AlSufiani F, Aloraidi A, Alkhani A. Primary spinal cord glioblastoma: A rare cause of paraplegia. *Surg Neurol Int* 2022; **13**: 160 [PMID: 35509569 DOI: 10.25259/SNI\_135\_2022]
- 10 **Cheng L**, Yao Q, Ma L, Duan W, Guan J, Zhang C, Wang K, Liu Z, Jian F, Wu H, Chen Z, Wang X, Wang Z. Predictors of mortality in patients with primary spinal cord glioblastoma. *Eur Spine J* 2020; **29**: 3203-3213 [PMID: 32594232 DOI: 10.1007/s00586-020-06515-3]
- 11 **Lakhdar F**, Benzagmout M, Chakour K, Chaoui FM. Primary bulbo-medullary glioblastoma in a child: case report. *Childs Nerv Syst* 2019; **35**: 2417-2421 [PMID: 31667535 DOI: 10.1007/s00381-019-04396-6]
- 12 **Nunn A**, Polyzoidis S, Piechowski-Jozwiak B, Brazil L, Ashkan K. Primary glioblastoma multiforme of the conus medullaris with leptomeningeal metastasis. *J Neurol Sci* 2017; **381**: 315-317 [PMID: 28991705 DOI: 10.1016/j.jns.2017.09.004]
- 13 **Prasad GL**, Borkar SA, Subbarao KC, Suri V, Mahapatra AK. Primary spinal cord glioblastoma multiforme: a report of two cases. *Neurol India* 2012; **60**: 333-335 [PMID: 22824699 DOI: 10.4103/0028-3886.98530]
- 14 **Moinuddin FM**, Alvi MA, Kerezoudis P, Wahood W, Meyer J, Lachance DH, Bydon M. Variation in management of spinal glioblastoma multiforme: results from a national cancer registry. *J Neurooncol* 2019; **141**: 441-447 [PMID: 30460627 DOI: 10.1007/s11060-018-03054-2]
- 15 **Jarrar SM**, Daoud SS, Jbarah OF, Albustami IS, Daise MA. Primary cervical glioblastoma multiforme as a presentation of constitutional mismatch repair deficiency: Case report and literature review. *Ann Med Surg (Lond)* 2021; **64**: 102263 [PMID: 33868684 DOI: 10.1016/j.amsu.2021.102263]
- 16 **Song D**, Xu D, Gao Q, Hu P, Guo F. Intracranial Metastases Originating From Pediatric Primary Spinal Cord Glioblastoma Multiforme: A Case Report and Literature Review. *Front Oncol* 2020; **10**: 99 [PMID: 32117750 DOI: 10.3389/fonc.2020.00099]
- 17 **Yi S**, Choi S, Shin DA, Kim DS, Choi J, Ha Y, Kim KN, Suh CO, Chang JH, Kim SH, Yoon DH. Impact of H3.3 K27M Mutation on Prognosis and Survival of Grade IV Spinal Cord Glioma on the Basis of New 2016 World Health Organization Classification of the Central Nervous System. *Neurosurgery* 2019; **84**: 1072-1081 [PMID: 29718432 DOI: 10.1093/neuros/nyy150]
- 18 **Akinduro OO**, Garcia DP, Higgins DMO, Vivas-Buitrago T, Jentoft M, Solomon DA, Daniels DJ, Pennington Z, Sherman WJ, Delgado M, Bydon M, Kalani MA, Zanazzi G, Tsankova N, Bendok BR, McCormick PC, Sciubba DM, Lo SL, Clarke JL, Abode-Iyamah K, Quiñones-Hinojosa A. A multicenter analysis of the prognostic value of histone H3 K27M mutation in adult high-grade spinal glioma. *J Neurosurg Spine* 2021; **35**: 834-843 [PMID: 34416733 DOI: 10.3171/2021.2.SPINE201675]
- 19 **Yan H**, Parsons DW, Jin G, McLendon R, Rasheed BA, Yuan W, Kos I, Batinić-Haberle I, Jones S, Riggins GJ, Friedman H, Friedman A, Reardon D, Herndon J, Kinzler KW, Velculescu VE, Vogelstein B, Bigner DD. IDH1 and IDH2 mutations in gliomas. *N Engl J Med* 2009; **360**: 765-773 [PMID: 19228619 DOI: 10.1056/NEJMoa0808710]
- 20 **Lu VM**, Alvi MA, McDonald KL, Daniels DJ. Impact of the H3K27M mutation on survival in pediatric high-grade glioma: a systematic review and meta-analysis. *J Neurosurg Pediatr* 2018; **23**: 308-316 [PMID: 30544362 DOI: 10.3171/2018.9.PEDS18419]
- 21 **Haque W**, Verma V, Barber S, Tremont IW, Brian Butler E, Teh BS. Management, outcomes, and prognostic factors of adult primary spinal cord gliomas. *J Clin Neurosci* 2021; **84**: 8-14 [PMID: 33485604 DOI: 10.1016/j.jocn.2020.12.015]

- 22 **Darbari S**, Manjunath N, Doddamani RS, Meena R, Nambirajan A, Sawarkar D, Singh PK, Garg K, Chandra PS, Kale SS. Primary spinal cord glioblastoma multiforme: a single-center experience. *Br J Neurosurg* 2022; 1-7 [PMID: [35441567](#) DOI: [10.1080/02688697.2022.2064427](#)]
- 23 **Konar SK**, Bir SC, Maiti TK, Nanda A. A systematic review of overall survival in pediatric primary glioblastoma multiforme of the spinal cord. *J Neurosurg Pediatr* 2017; **19**: 239-248 [PMID: [27813458](#) DOI: [10.3171/2016.8.PEDS1631](#)]
- 24 **Yang R**, Isaacs AM, Cadieux M, Hirmer TJ, CreveCoeur TS, Lapointe AP, Opoku-Darko M, Premji Z, Riva-Cambrin J, Gallagher CN. Primary and metastatic glioblastoma of the spine in the pediatric population: a systematic review. *Childs Nerv Syst* 2021; **37**: 1849-1858 [PMID: [33675391](#) DOI: [10.1007/s00381-021-05098-8](#)]
- 25 **Grady C**, Melnick K, Porche K, Dastmalchi F, Hoh DJ, Rahman M, Ghiaseddin A. Glioma Immunotherapy: Advances and Challenges for Spinal Cord Gliomas. *Neurospine* 2022; **19**: 13-29 [PMID: [35130421](#) DOI: [10.14245/ns.2143210.605](#)]
- 26 **He JH**, Wang J, Yang YZ, Chen QX, Liu LL, Sun L, Hu WM, Zeng J. SSTR2 is a prognostic factor and a promising therapeutic target in glioma. *Am J Transl Res* 2021; **13**: 11223-11234 [PMID: [34786053](#)]





Published by **Baishideng Publishing Group Inc**  
7041 Koll Center Parkway, Suite 160, Pleasanton, CA 94566, USA

**Telephone:** +1-925-3991568

**E-mail:** [bpgoffice@wjgnet.com](mailto:bpgoffice@wjgnet.com)

**Help Desk:** <https://www.f6publishing.com/helpdesk>

<https://www.wjgnet.com>

