

World Journal of *Clinical Cases*

World J Clin Cases 2022 July 26; 10(21): 7187-7619



Contents

Thrice Monthly Volume 10 Number 21 July 26, 2022

OPINION REVIEW

- 7187 Effects of glucocorticoids on leukocytes: Genomic and non-genomic mechanisms
Jia WY, Zhang JJ

MINIREVIEWS

- 7195 Apheresis: A cell-based therapeutic tool for the inflammatory bowel disease
Yasmin F, Najeeb H, Naeem U, Moeed A, Koritala T, Surani S
- 7209 *Helicobacter pylori* infection and small intestinal bacterial overgrowth—more than what meets the eye
Dharan M, Wozny D
- 7215 Anatomy of the anterolateral ligament of the knee joint
Park JG, Han SB, Rhim HC, Jeon OH, Jang KM

ORIGINAL ARTICLE

Clinical and Translational Research

- 7224 Molecular mechanisms of Biyu decoction as treatment for psoriasis: A network pharmacology and molecular docking study
Wang Z, Zhang HM, Guo YR, Li LL
- 7242 Expression of hepatocyte nuclear factor 4 alpha, wingless-related integration site, and β -catenin in clinical gastric cancer
Hu Q, Li LL, Peng Z, Yi P

Case Control Study

- 7256 Improved Pittsburgh Sleep Quality Index scores on first postoperative night achieved by propofol anesthesia in patients undergoing ambulatory gynecologic surgery
Hu CH, Chou WY
- 7265 Efficacy of Guhong injection *versus* Butylphthalide injection for mild ischemic stroke: A multicenter controlled study
Zhang WW, Xin J, Zhang GY, Zhai QJ, Zhang HM, Wu CS

Retrospective Study

- 7275 Clinical values of Barcelona Clinic Liver Cancer subgroup and up-to-7 criteria in intermediate stage hepatocellular carcinoma with transcatheter arterial chemoembolization
Lee SW, Peng YC, Lien HC, Ko CW, Tung CF, Chang CS
- 7285 Intervention effect of encouraging mental and programmed nursing of patients in interventional operating room on their compliance and bad moods
Chi RB, Cai YY, Mao HP

- 7293** Preoperative neoadjuvant chemotherapy in patients with breast cancer evaluated using strain ultrasonic elastography
Pan HY, Zhang Q, Wu WJ, Li X
- 7302** Risk factors for delayed intracranial hemorrhage secondary to ventriculoperitoneal shunt: A retrospective study
Chen JC, Duan SX, Xue ZB, Yang SY, Li Y, Lai RL, Tan DH
- 7314** Sequential treatment of severe pneumonia with respiratory failure and its influence on respiratory mechanical parameters and hemodynamics
Niu BY, Wang G, Li B, Zhen GS, Weng YB
- 7324** Effects of alendronate sodium combined with InterTan on osteoporotic femoral intertrochanteric fractures and fracture recurrence
Wang KM, Wei SP, Yin XY, Meng QJ, Kong YM
- 7333** Correlation of magnetic resonance imaging quantitative parameters and apparent diffusion coefficient value with pathological breast cancer
Wang Z, Ren GY, Yin Q, Wang Q
- 7341** Risk factors for delirium after surgery for craniocerebral injury in the neurosurgical intensive care unit
Chen RY, Zhong CH, Chen W, Lin M, Feng CF, Chen CN

Observational Study

- 7348** Effect of osteoarthritic knee flexion deformity correction by total knee arthroplasty on sagittal spinopelvic alignment in Indian population
Puthiyapura LK, Jain M, Tripathy SK, Puliappadamb HM
- 7356** Imaging characteristics of orbital peripheral nerve sheath tumors: Analysis of 34 cases
Dai M, Wang T, Wang JM, Fang LP, Zhao Y, Thakur A, Wang D

Randomized Controlled Trial

- 7365** Comparison of involved-field intensity-modulated radiotherapy combined with S-1 *vs* radiotherapy alone for elderly patients with esophageal cancer
Liu LH, Yan MH, Di YP, Fu ZG, Zhang XD, Li HQ

Randomized Clinical Trial

- 7376** Dexmedetomidine in pediatric unilateral internal inguinal ring ligation
Liu G, Zhang L, Wang HS, Lin Y, Jin HQ, Wang XD, Qiao WN, Zhang YT, Sun JQ, Liu ZN

META-ANALYSIS

- 7386** Impact of cancer on mortality rates in patients with sepsis: A meta-analysis and meta-regression of current studies
Xiang MJ, Chen GL

CASE REPORT

- 7397** Updated clinical and glycomic features of mannosyl-oligosaccharide glucosidase deficiency: Two case reports
Abuduxikuer K, Wang L, Zou L, Cao CY, Yu L, Guo HM, Liang XM, Wang JS, Chen L
- 7409** Solitary necrotic nodules of the liver with "ring"-like calcification: A case report
Bao JP, Tian H, Wang HC, Wang CC, Li B
- 7415** Corticosteroid-induced bradycardia in multiple sclerosis and maturity-onset diabetes of the young due to hepatocyte nuclear factor 4- α mutation: A case report
Sohn SY, Kim SY, Joo IS
- 7422** Essential thrombocythemia with non-ST-segment elevation myocardial infarction as the first manifestation: A case report
Wang ZM, Chen WH, Wu YM, Wang LQ, Ye FL, Yin RL
- 7429** Extranasopharyngeal angiofibroma in children: A case report
Yan YY, Lai C, Wu L, Fu Y
- 7438** Deep Sylvian fissure meningiomas: A case report
Wang A, Zhang X, Sun KK, Li C, Song ZM, Sun T, Wang F
- 7445** Acute pulmonary embolism originating from upper limb venous thrombosis following breast cancer surgery: Two case reports
Duan Y, Wang GL, Guo X, Yang LL, Tian FG
- 7451** Managing spondylitis tuberculosis in a patient with underlying diabetes and hypothyroidism: A case report
Novita BD, Muliono AC, Wijaya S, Theodora I, Tjahjono Y, Supit VD, Willianto VM
- 7459** Ovarian mucinous tumor with mural nodules of anaplastic carcinoma: Three case reports
Wang XJ, Wang CY, Xi YF, Bu P, Wang P
- 7467** Transcatheter arterial infusion chemotherapy and embolization for primary lacrimal sac squamous cell carcinoma: A case report
Sun MH, Yi WD, Shen L, Zhou L, Lu JX
- 7474** Programmed cell death-1 inhibitor combination treatment for recurrent proficient mismatch repair/microsatellite-stable type endometrial cancer: A case report
Zhai CY, Yin LX, Han WD
- 7483** Novel compound heterozygous mutation of *SLC12A3* in Gitelman syndrome co-existent with hyperthyroidism: A case report and literature review
Qin YZ, Liu YM, Wang Y, You C, Li LN, Zhou XY, Lv WM, Hong SH, Xiao LX
- 7495** Successful treatment of hyperglycemia with liraglutide in a hospitalized 27-year-old patient with schizophrenia: A case report
Zhang L, Yu WJ, Zhu H, Li HF, Qiao J

- 7502** Refractory lymphoma treated with chimeric antigen receptor T cells combined with programmed cell death-1 inhibitor: A case report
Zhang CJ, Zhang JY, Li LJ, Xu NW
- 7509** Median arcuate ligament syndrome with retroperitoneal haemorrhage: A case report
Lu XC, Pei JG, Xie GH, Li YY, Han HM
- 7517** Novel frameshift mutation in the *AHDC1* gene in a Chinese global developmental delay patient: A case report
Lin SZ, Xie HY, Qu YL, Gao W, Wang WQ, Li JY, Feng XC, Jin CQ
- 7523** Selective nerve block for the treatment of neuralgia in Kummell's disease: A case report
Zhang X, Li ZX, Yin LJ, Chen H
- 7531** Traditional Chinese medicine manipulative reduction combined with percutaneous vertebroplasty for treating type III Kummell's disease: A case report
Hao SS, Zhang RJ, Dong SL, Li HK, Liu S, Li RF, Ren HH, Zhang LY
- 7539** Differential diagnosis and treatment of foot drop caused by an extraneural ganglion cyst above the knee: A case report
Won KH, Kang EY
- 7545** Effect of hydrogen intervention on refractory wounds after radiotherapy: A case report
Zhao PX, Luo RL, Dang Z, Wang YB, Zhang XJ, Liu ZY, Wen XH, Liu MY, Zhang MZ, Adzavon YM, Ma XM
- 7553** Chronic urticaria associated with lung adenocarcinoma — a paraneoplastic manifestation: A case report and literature review
Jiménez LF, Castellón EA, Marengo JD, Mejía JM, Rojas CA, Jiménez FT, Coronell L, Osorio-Llanes E, Mendoza-Torres E
- 7565** Spinal giant cell-rich osteosarcoma-diagnostic dilemma and treatment strategy: A case report
Tseng CS, Wong CE, Huang CC, Hsu HH, Lee JS, Lee PH
- 7571** Primary clear cell sarcoma of soft tissue in the posterior cervical spine invading the medulla oblongata: A case report
Liu CC, Huang WP, Gao JB
- 7577** *Pseudomonas aeruginosa*-related effusive-constrictive pericarditis diagnosed with echocardiography: A case report
Chen JL, Mei DE, Yu CG, Zhao ZY
- 7585** Maternal peripartum bacteremia caused by intrauterine infection with *Comamonas kerstersii*: A case report
Qu H, Zhao YH, Zhu WM, Liu L, Zhu M
- 7592** Considerations of single-lung ventilation in neonatal thoracoscopic surgery with cardiac arrest caused by bilateral pneumothorax: A case report
Zhang X, Song HC, Wang KL, Ren YY

- 7599** Rare primary rectal mucosa-associated lymphoid tissue lymphoma with curative resection by endoscopic submucosal dissection: A case report and review of literature

Tao Y, Nan Q, Lei Z, Miao YL, Niu JK

- 7609** Differences in examination results of small anastomotic fistula after radical gastrectomy with afterward treatments: A case report

Lu CY, Liu YL, Liu KJ, Xu S, Yao HL, Li L, Guo ZS

LETTER TO THE EDITOR

- 7617** Baseline differences may impact on relationship between dietary tryptophan and risk of obesity and type 2 diabetes

Ren XH, Ye YW, He LP

ABOUT COVER

Editorial Board Member of *World Journal of Clinical Cases*, Rajesh Kumar Rajnish, MBBS, MS, Assistant Professor, Department of Orthopaedics, All India Institute of Medical Sciences, Bilaspur, Bilaspur 174001, Himachal Pradesh, India. duktiraj@gmail.com

AIMS AND SCOPE

The primary aim of *World Journal of Clinical Cases* (WJCC, *World J Clin Cases*) is to provide scholars and readers from various fields of clinical medicine with a platform to publish high-quality clinical research articles and communicate their research findings online.

WJCC mainly publishes articles reporting research results and findings obtained in the field of clinical medicine and covering a wide range of topics, including case control studies, retrospective cohort studies, retrospective studies, clinical trials studies, observational studies, prospective studies, randomized controlled trials, randomized clinical trials, systematic reviews, meta-analysis, and case reports.

INDEXING/ABSTRACTING

The WJCC is now abstracted and indexed in Science Citation Index Expanded (SCIE, also known as SciSearch®), Journal Citation Reports/Science Edition, Current Contents®/Clinical Medicine, PubMed, PubMed Central, Scopus, Reference Citation Analysis, China National Knowledge Infrastructure, China Science and Technology Journal Database, and Superstar Journals Database. The 2022 Edition of Journal Citation Reports® cites the 2021 impact factor (IF) for WJCC as 1.534; IF without journal self cites: 1.491; 5-year IF: 1.599; Journal Citation Indicator: 0.28; Ranking: 135 among 172 journals in medicine, general and internal; and Quartile category: Q4. The WJCC's CiteScore for 2021 is 1.2 and Scopus CiteScore rank 2021: General Medicine is 443/826.

RESPONSIBLE EDITORS FOR THIS ISSUE

Production Editor: *Ying-Yi Yuan*; Production Department Director: *Xiang Li*; Editorial Office Director: *Jin-Lei Wang*.

NAME OF JOURNAL

World Journal of Clinical Cases

ISSN

ISSN 2307-8960 (online)

LAUNCH DATE

April 16, 2013

FREQUENCY

Thrice Monthly

EDITORS-IN-CHIEF

Bao-Gan Peng, Jerzy Tadeusz Chudek, George Kontogeorgos, Maurizio Serati, Ja Hyeon Ku

EDITORIAL BOARD MEMBERS

<https://www.wjgnet.com/2307-8960/editorialboard.htm>

PUBLICATION DATE

July 26, 2022

COPYRIGHT

© 2022 Baishideng Publishing Group Inc

INSTRUCTIONS TO AUTHORS

<https://www.wjgnet.com/bpg/gerinfo/204>

GUIDELINES FOR ETHICS DOCUMENTS

<https://www.wjgnet.com/bpg/GerInfo/287>

GUIDELINES FOR NON-NATIVE SPEAKERS OF ENGLISH

<https://www.wjgnet.com/bpg/gerinfo/240>

PUBLICATION ETHICS

<https://www.wjgnet.com/bpg/GerInfo/288>

PUBLICATION MISCONDUCT

<https://www.wjgnet.com/bpg/gerinfo/208>

ARTICLE PROCESSING CHARGE

<https://www.wjgnet.com/bpg/gerinfo/242>

STEPS FOR SUBMITTING MANUSCRIPTS

<https://www.wjgnet.com/bpg/GerInfo/239>

ONLINE SUBMISSION

<https://www.f6publishing.com>



Novel frameshift mutation in the *AHDC1* gene in a Chinese global developmental delay patient: A case report

Shuang-Zhu Lin, Hong-Yan Xie, Yan-Lai Qu, Wen Gao, Wan-Qi Wang, Jia-Yi Li, Xiao-Chun Feng, Chun-Quan Jin

Specialty type: Pediatrics

Provenance and peer review:

Unsolicited article; Externally peer reviewed.

Peer-review model: Single blind

Peer-review report's scientific quality classification

Grade A (Excellent): 0

Grade B (Very good): 0

Grade C (Good): C, C

Grade D (Fair): 0

Grade E (Poor): 0

P-Reviewer: Mesquita J, Portugal; Sahin Y, Turkey

A-Editor: Bedane DA, Ethiopia

Received: December 21, 2021

Peer-review started: December 21, 2021

First decision: February 8, 2022

Revised: February 21, 2022

Accepted: June 3, 2022

Article in press: June 3, 2022

Published online: July 26, 2022



Shuang-Zhu Lin, Hong-Yan Xie, Yan-Lai Qu, Xiao-Chun Feng, Chun-Quan Jin, Diagnosis and Treatment Center for Children, The First Affiliated Hospital to Changchun University of Chinese Medicine, Changchun 130021, Jilin Province, China

Wen Gao, Wan-Qi Wang, Jia-Yi Li, Changchun University of Chinese Medicine, Changchun 130000, Jilin Province, China

Corresponding author: Chun-Quan Jin, MD, Professor, Diagnosis and Treatment Center for Children, The First Affiliated Hospital to Changchun University of Chinese Medicine, No. 1478 Gongnong Road, Chaoyang District, Changchun 130021, Jilin Province, China. jinchunquan@126.com

Abstract

BACKGROUND

Xia-Gibbs syndrome (XGS, OMIM: 615829), caused by mutations within the AT-Hook DNA-binding motif-containing protein 1 (*AHDC1*) gene (OMIM: 615790), located on the short arm of chromosome 1 within the cytogenetic band 1p36.11, contains five noncoding 5 exons, a single 4.9-kb coding exon, and a noncoding 3 exon.

CASE SUMMARY

In this case report, we diagnosed and treated a 6-mo-old girl with XGS. The primary clinical symptoms included global developmental delay, hypotonia, and mild dysmorphic features. Using high-throughput whole-exome sequencing to sequence the patient and her parents, and the results showed a novel frameshift mutation of c.1155dupG (p.Arg386Alafs*3) in the *AHDC1* gene. The paternal gene was wild type.

CONCLUSION

This report extends the mutation spectrum of the *AHDC1* gene to provide the diagnostic basis for genetic counseling in families with XGS.

Key Words: Xia-Gibbs syndrome; AT-Hook DNA-binding motif-containing protein 1; Children; Global developmental delay; Case report

©The Author(s) 2022. Published by Baishideng Publishing Group Inc. All rights reserved.

Core Tip: We report a 6-mo-old girl with Xia-Gibbs syndrome (XGS). The main clinical manifestations were global developmental delay, hypotonia, and other mild dysmorphic features. DNA sequencing showed that there was a novel frameshift mutation of c.1155dupG (p.Arg386Alafs*3) in the AT-Hook DNA-binding motif-containing protein 1 (*AHDC1*) gene. This study extends the mutation spectrum of the *AHDC1* gene, and provides a molecular basis for the etiological diagnosis of XGS and genetic consultation for the family.

Citation: Lin SZ, Xie HY, Qu YL, Gao W, Wang WQ, Li JY, Feng XC, Jin CQ. Novel frameshift mutation in the *AHDC1* gene in a Chinese global developmental delay patient: A case report. *World J Clin Cases* 2022; 10(21): 7517-7522

URL: <https://www.wjgnet.com/2307-8960/full/v10/i21/7517.htm>

DOI: <https://dx.doi.org/10.12998/wjcc.v10.i21.7517>

INTRODUCTION

Xia-Gibbs syndrome (XGS) is an autosomal dominant genetic disease caused by mutation of the AT-Hook DNA-binding motif-containing protein 1 (*AHDC1*) gene. Typical features include global developmental delay, hypotonia, obstructive sleep apnea, seizures, delayed myelination, micrognathia, and other mild dysmorphic features[1,2]. The *AHDC1* gene is located on the short arm of chromosome 1 within the cytogenetic band 1p36.11, and consists of seven exons with only one coding exon (exon 6), five noncoding 5 exons, and a noncoding 3 exon[3].

In this case, a novel frameshift mutation of c.1155dupG (p.Arg386Alafs*3) in the *AHDC1* gene was found by high-throughput whole-exome sequencing (WES) in a patient with global developmental delay, hypotonia, micrognathia, and other mild dysmorphic features.

CASE PRESENTATION

Chief complaints

A 6-mo-old female patient presented to our hospital due to global developmental delay.

History of present illness

In June 2021, the patient presented with a 6-mo history of global developmental delay. Since birth, the child had lagged behind in developmental milestones. She could not raise her head until she was age 4 mo, and she still shook her head sometimes. She could not sit alone without the help of others, and turning over was not flexible. She could not crawl, and the stability of her lower limbs was too poor to support her weight. She had no difficulty in pronunciation.

History of past illness

The patient weighed 3.7 kg and was 52 cm long after full-term normal delivery without a history of asphyxiation and resuscitation. The patient did not have a history of feeding difficulties. There was no history of encephalitis and brain trauma since disease onset.

Personal and family history

Her parents were clinically normal. Genetic history or family history of infectious diseases were denied.

Physical examination

At her visit at 6 mo of age, we performed a physical examination. Her weight was 9.0 kg and length 70.0 cm. Mild dysmorphic features were observed, such as micrognathia. Grasping reflex was present, and limb muscle tension showed hypotonia. Ankle clonus was positive. Muscle strength was level 4. Physiological reflexes were present.

Laboratory examinations

We performed a series of examinations of the patient, including liver function, kidney function, electrolytes, and organic acids in blood and urine, which showed no abnormalities.

Imaging examinations

In June 2021, brain magnetic resonance imaging showed bilateral frontal subdural effusion, hydrocephalus, and hydrops in the mastoid area. Electroencephalography (EEG) was abnormal,

showing sharp waves and spike waves in the Rolandic area or right forehead region.

Further diagnostic work-up

The patient underwent a Peabody Developmental Motor Scales (PDMS-2) test on May 14, 2021[4]. The Fine Motor Quotient (FMQ) was 9 points, with a motor quotient of 67, and the Gross Motor Quotient (GMQ) was 21 points with a motor quotient of 81; both measures were worse than those of her peers. Griffiths Mental Development Scales (GMDS) showed that motor ability was equivalent to that of a 3-mo-old child, with a development quotient (DQ) of 46 points; human-social ability was equivalent to that of a 4-mo-old child, with a DQ of 62 points; hearing and language ability was equivalent to that of a 4.5-mo-old child with a DQ of 69 points, and hand and eye coordination was equivalent to that of a 3.5-mo-old child, with a DQ of 54 points. The patients' overall performance was equivalent to that of a 3.5-mo-old child, with a DQ of 54 points.

High throughput WES and mitochondrial sequencing

Informed parental consent was obtained for WES, mitochondrial sequencing, and publication of photographs on behalf of the proband. DNA samples were extracted from the peripheral blood of the child and her parents to detect whole-exome sequences and whole-genome copy number variants. The results revealed a novel frameshift mutation of c.1155dupG (p.Arg386Alafs*3) in the *AHDC1* gene. Polymorphic sites were detected in each sample data using GATK software and statistical analysis was performed on 1000 human genomes and ExAC databases. The reported pathogenic locus has been confirmed using the Human Gene Mutation Database (HGMD) and the Human Online Mendelian Genetic Database (OMIM). The pathogenicity of the mutation locus was comprehensively assessed using the American College of Medical Genetics and Genomics (ACMG) standards and guidelines for the interpretation of sequence variation.

Gene detection and pathogenicity analysis

The WES results showed the presence of a novel frameshift variant in the *AHDC1* gene, which was an unreported frameshift mutation, c.1155dupG (p.Arg386Alafs*3), and may result in altered gene function. The frequency at which variation occurs in the normal population database is unknown, and is a low-frequency variation. The results of protein function prediction are unknown, and are not reported in the HGMD database.

According to Sanger sequencing, the variation occurred in the child, while the parental genes were wild type (Figures 1-3). The mutation was suspected to be a pathogenic according to the ACMG guidelines[5].

FINAL DIAGNOSIS

Sanger sequencing showed that there was a novel frameshift variation of c.1155dupG (p.Arg386Alafs*3) in the *AHDC1* gene. Based on clinical presentation, laboratory tests and gene sequencing results, the clinical diagnosis was XGS.

TREATMENT

To improve quality of life of the patient, she has been provided with rehabilitation training and behavioral guidance therapy since June 2021.

OUTCOME AND FOLLOW-UP

The patient had been receiving rehabilitation treatment for nearly 6 mo. The patient is now age 11 mo, her weight is 11.0 kg and length is 74.0 cm. She can sit alone, and her hands can engage in more elaborate movements, and have increased responses to external stimuli, and she is able to speak some simple vowels. The patient underwent the PDMS-2 test in November 2021. The FMQ was 13 points with a motor quotient of 79, and GMQ was 17 points with a motor quotient of 72. GMDS showed that motor ability was equivalent to that of a 5.3-mo-old child, with a DQ of 46 points. Performance was equivalent to that of a 6.5-mo-old child, with a DQ of 56 points.

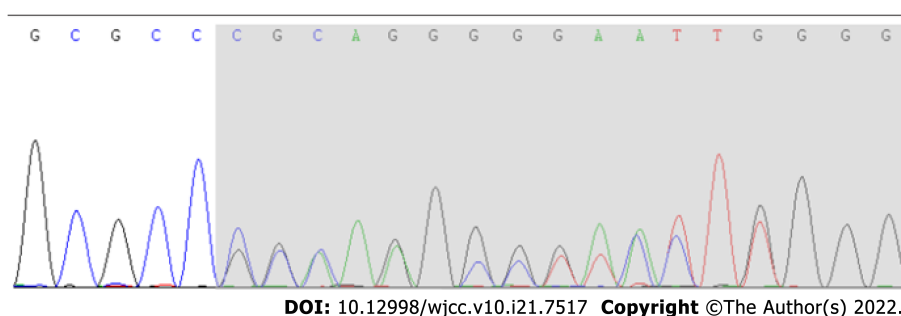


Figure 1 A novel frameshift variation in c.1155dupG (p.Arg386Alafs*3) of the AT-Hook DNA-binding motif-containing protein 1 gene was revealed by Sanger sequencing.

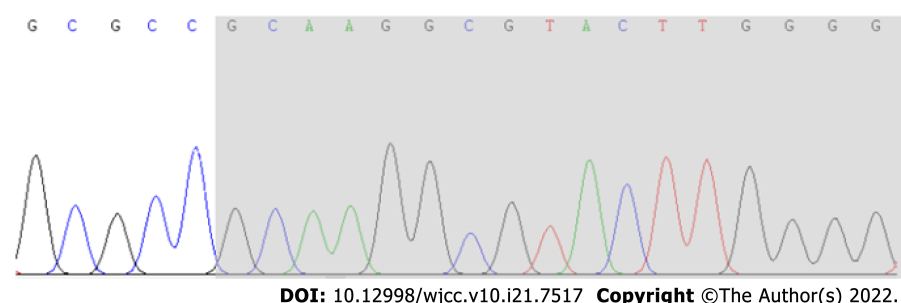


Figure 2 No anomalies were found in the AT-Hook DNA-binding motif-containing protein 1 gene in the child's father as revealed by Sanger sequencing.

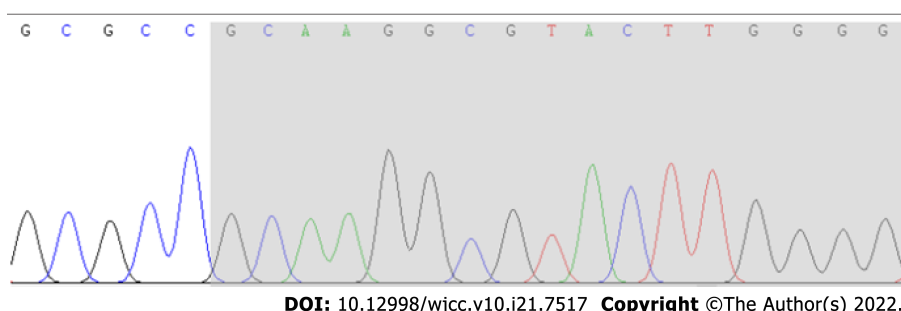


Figure 3 No anomalies were found in the AT-Hook DNA-binding motif-containing protein 1 gene in the child's mother as revealed by Sanger sequencing.

DISCUSSION

The *AHDC1* gene is located on chromosome 1p36.11, and likely functions in DNA binding. The *AHDC1* gene is part of the CBX family of proteins associated with human chromodomain-containing Polycomb proteins. It encodes a protein of 1603 amino acids, consisting of five noncoding 5 exons, a noncoding 3 exon and a single 4.9-kb coding exon (exon 6) containing 2 AT hooks[1,3]. Previous studies have shown that *AHDC1* interacts with nuclear proteins involved in epigenetic regulation during development, mainly at neural loci and neuronal protein transport. Mutation of the *AHDC1* gene can lead to XGS.

XGS (OMIM: 615829) is an autosomal dominant genetic disease caused by mutation of the *AHDC1* gene. Typical features include global developmental delay, intellectual disability, structural abnormalities of the brain, global hypotonia, feeding problems, sleep difficulties, apnea, and short stature[6]. In addition to neurological seizures, delayed myelination, micrognathia, and other mild dysmorphic manifestations[7], XGS patients may also have a broad clinical range and multisystem involvement[8,9]. Not all XGS patients show a typical phenotype, and there are differences in the disease manifestations [10,11].

The present patient first attended hospital due to delayed motor milestones over 2 mo when she was age 6 mo. In order to clarify the cause of the disease, we used high-throughput WES and identified an unreported mutation of the *AHDC1* gene.

According to previous studies, more than 90% of patients had motor and speech delay, hypotonia occurred in approximately 85% of patients, and less than 40% of patients had short stature. About 30% of patients had symptoms of autism. Some patients showed sleep apnea (34.33%), laryngomalacia (14.93%), and other manifestations. Approximately 35% of patients developed epileptic seizures[8,12,13].

In this case report, the child conformed to the typical clinical manifestations of XGS. The child developed significant motor delay and hypotonia, but speech ability was not delayed. She was able to respond positively to external stimuli. There was no sufficient evidence of sleep apnea and laryngomalacia. Although the child's EEG showed the distribution of spike waves and sharp waves, she did not appear to have the related actions, and she did not have other related manifestations of epilepsy [14,15].

Our patient has not yet developed growth hormone deficiency or short stature. Height and weight were within the mean range of normal, in contrast to two previously reported Chinese children who exhibited partial growth hormone deficiency and attended hospital due to short stature[16].

In this report, we describe a Chinese patient with XGS, with a new mutation c.1155dupG (p.Arg386Alafs*3) in the *AHDC1* gene identified by WES, and compared the results with those from two Chinese cases reported in the literature, to better understand the clinical phenotype and the association with the *AHDC1* gene.

CONCLUSION

Previous studies have shown that global developmental delay occurs in the *AHDC1*-related phenotype of XGS. Our patient was found to have a novel frameshift variation of c.1155dupG (p.Arg386Alafs*3) in the *AHDC1* gene, which was an unreported frameshift mutation. Typical features of XGS include global developmental delay, hypotonia, obstructive sleep apnea, seizures, delayed myelination, micrognathia, and other mild dysmorphic features. This report result showed clinicians could consider XGS in patients with similar clinical characteristics. Genetic testing can help physicians confirm the diagnosis and help with further genetic counseling.

ACKNOWLEDGEMENTS

We would like to thank the family members of the child for agreeing to participate in this study.

FOOTNOTES

Author contributions: Lin SZ and Xie HY collected and analyzed all clinical data and wrote the manuscript; Qu YL and Gao W participated in the collation of the literature and the chart research; Jin CQ was involved in the genetic diagnosis and treatment of the patients; Lin SZ, Wang WQ, Li JY and Feng XC substantially participated in drafting and revising the important intellectual content of the manuscript; All authors involved have read and approved the final manuscript.

Supported by National Administration of Traditional Chinese Medicine, No. 2019XZZX-EK002.

Informed consent statement: All study participants, or their legal guardian, provided informed written consent prior to study enrollment.

Conflict-of-interest statement: All the researchers said there was no conflict of interest.

CARE Checklist (2016) statement: The authors have read the CARE Checklist (2016), and the manuscript was prepared and revised according to the CARE Checklist (2016).

Open-Access: This article is an open-access article that was selected by an in-house editor and fully peer-reviewed by external reviewers. It is distributed in accordance with the Creative Commons Attribution NonCommercial (CC BY-NC 4.0) license, which permits others to distribute, remix, adapt, build upon this work non-commercially, and license their derivative works on different terms, provided the original work is properly cited and the use is non-commercial. See: <https://creativecommons.org/licenses/by-nc/4.0/>

Country/Territory of origin: China

ORCID number: Shuang-Zhu Lin 0000-0001-5333-2138; Hong-Yan Xie 0000-0002-4116-5173; Yan-Lai Qu 0000-0001-8039-5345; Wen Gao 0000-0001-9230-368X; Wan-Qi Wang 0000-0002-8247-7616; Jia-Yi Li 0000-0002-7729-4479; Xiao-Chun Feng 0000-0001-5780-2811; Chun-Quan Jin 0000-0002-6082-6467.

S-Editor: Chang KL

L-Editor: Filipodia

P-Editor: Chang KL

REFERENCES

- 1 **Xia F**, Bainbridge MN, Tan TY, Wangler MF, Scheuerle AE, Zackai EH, Harr MH, Sutton VR, Nalam RL, Zhu W, Nash M, Ryan MM, Yapfite-Lee J, Hunter JV, Deardorff MA, Penney SJ, Beaudet AL, Plon SE, Boerwinkle EA, Lupski JR, Eng CM, Muzny DM, Yang Y, Gibbs RA. De novo truncating mutations in *AHDC1* in individuals with syndromic expressive language delay, hypotonia, and sleep apnea. *Am J Hum Genet* 2014; **94**: 784-789 [PMID: [24791903](#) DOI: [10.1016/j.ajhg.2014.04.006](#)]
- 2 **Ellis C**, Pai GS, Wine Lee L. Atypical aplasia cutis in association with Xia Gibbs syndrome. *Pediatr Dermatol* 2021; **38**: 533-535 [PMID: [33464633](#) DOI: [10.1111/pde.14515](#)]
- 3 **Yang H**, Douglas G, Monaghan KG, Retterer K, Cho MT, Escobar LF, Tucker ME, Stoler J, Rodan LH, Stein D, Marks W, Enns GM, Platt J, Cox R, Wheeler PG, Crain C, Calhoun A, Tryon R, Richard G, Vitazka P, Chung WK. De novo truncating variants in the *AHDC1* gene encoding the AT-hook DNA-binding motif-containing protein 1 are associated with intellectual disability and developmental delay. *Cold Spring Harb Mol Case Stud* 2015; **1**: a000562 [PMID: [27148574](#) DOI: [10.1101/mcs.a000562](#)]
- 4 **Griffiths A**, Toovey R, Morgan PE, Spittle AJ. Psychometric properties of gross motor assessment tools for children: a systematic review. *BMJ Open* 2018; **8**: e021734 [PMID: [30368446](#) DOI: [10.1136/bmjopen-2018-021734](#)]
- 5 **Richards S**, Aziz N, Bale S, Bick D, Das S, Gastier-Foster J, Grody WW, Hegde M, Lyon E, Spector E, Voelkerding K, Rehm HL; ACMG Laboratory Quality Assurance Committee. Standards and guidelines for the interpretation of sequence variants: a joint consensus recommendation of the American College of Medical Genetics and Genomics and the Association for Molecular Pathology. *Genet Med* 2015; **17**: 405-424 [PMID: [25741868](#) DOI: [10.1038/gim.2015.30](#)]
- 6 **Yang S**, Li K, Zhu MM, Yuan XD, Jiao XL, Yang YY, Li J, Li L, Zhang HN, Du YH, Wei YX, Qin YW. Rare Mutations in *AHDC1* in Patients with Obstructive Sleep Apnea. *Biomed Res Int* 2019; **2019**: 5907361 [PMID: [31737670](#) DOI: [10.1155/2019/5907361](#)]
- 7 **Gumus E**. Extending the phenotype of Xia-Gibbs syndrome in a two-year-old patient with craniosynostosis with a novel de novo *AHDC1* missense mutation. *Eur J Med Genet* 2020; **63**: 103637 [PMID: [30858058](#) DOI: [10.1016/j.ejmg.2019.03.001](#)]
- 8 **Della Vecchia S**, Milone R, Cagiano R, Calderoni S, Santocchi E, Pasquariello R, Battini R, Muratori F. Focusing on Autism Spectrum Disorder in Xia-Gibbs Syndrome: Description of a Female with High Functioning Autism and Literature Review. *Children (Basel)* 2021; **8** [PMID: [34073322](#) DOI: [10.3390/children8060450](#)]
- 9 **Wang Q**, Huang X, Liu Y, Peng Q, Zhang Y, Liu J, Yuan H. Microdeletion and microduplication of 1p36.11p35.3 involving *AHDC1* contribute to neurodevelopmental disorder. *Eur J Med Genet* 2020; **63**: 103611 [PMID: [30615951](#) DOI: [10.1016/j.ejmg.2019.01.001](#)]
- 10 **Cardoso-Dos-Santos AC**, Oliveira Silva T, Silveira Faccini A, Woycinck Kowalski T, Bertoli-Avella A, Morales Saute JA, Schuler-Faccini L, de Oliveira Poswar F. Novel *AHDC1* Gene Mutation in a Brazilian Individual: Implications of Xia-Gibbs Syndrome. *Mol Syndromol* 2020; **11**: 24-29 [PMID: [32256298](#) DOI: [10.1159/000505843](#)]
- 11 **Goyal C**, Naqvi W, Sahu A. Xia-Gibbs Syndrome: A Rare Case Report of a Male Child and Insight into Physiotherapy Management. *Cureus* 2020; **12**: e9622 [PMID: [32923223](#) DOI: [10.7759/cureus.9622](#)]
- 12 **Ritter AL**, McDougall C, Skraban C, Medne L, Bedoukian EC, Asher SB, Balciuniene J, Campbell CD, Baker SW, Denenberg EH, Mazzola S, Fiordaliso SK, Krantz ID, Kaplan P, Ierardi-Curto L, Santani AB, Zackai EH, Izumi K. Variable Clinical Manifestations of Xia-Gibbs syndrome: Findings of Consecutively Identified Cases at a Single Children's Hospital. *Am J Med Genet A* 2018; **176**: 1890-1896 [PMID: [30152016](#) DOI: [10.1002/ajmg.a.40380](#)]
- 13 **Jiang Y**, Wangler MF, McGuire AL, Lupski JR, Posey JE, Khayat MM, Murdock DR, Sanchez-Pulido L, Ponting CP, Xia F, Hunter JV, Meng Q, Murugan M, Gibbs RA. The phenotypic spectrum of Xia-Gibbs syndrome. *Am J Med Genet A* 2018; **176**: 1315-1326 [PMID: [29696776](#) DOI: [10.1002/ajmg.a.38699](#)]
- 14 **Park HY**, Kim M, Jang W, Jang DH. Phenotype of a Patient With a 1p36.11-p35.3 Interstitial Deletion Encompassing the *AHDC1*. *Ann Lab Med* 2017; **37**: 563-565 [PMID: [28841002](#) DOI: [10.3343/alm.2017.37.6.563](#)]
- 15 **Khayat MM**, Li H, Chander V, Hu J, Hansen AW, Li S, Traynelis J, Shen H, Weissenberger G, Stossi F, Johnson HL, Lupski JR, Posey JE, Sabo A, Meng Q, Murdock DR, Wangler M, Gibbs RA. Phenotypic and protein localization heterogeneity associated with *AHDC1* pathogenic protein-truncating alleles in Xia-Gibbs syndrome. *Hum Mutat* 2021; **42**: 577-591 [PMID: [33644933](#) DOI: [10.1002/humu.24190](#)]
- 16 **Cheng X**, Tang F, Hu X, Li H, Li M, Fu Y, Yan L, Li Z, Gou P, Su N, Gong C, He W, Xiang R, Bu D, Shen Y. Two Chinese Xia-Gibbs syndrome patients with partial growth hormone deficiency. *Mol Genet Genomic Med* 2019; **7**: e00596 [PMID: [30729726](#) DOI: [10.1002/mgg3.596](#)]



Published by **Baishideng Publishing Group Inc**
7041 Koll Center Parkway, Suite 160, Pleasanton, CA 94566, USA

Telephone: +1-925-3991568

E-mail: bpgoffice@wjgnet.com

Help Desk: <https://www.f6publishing.com/helpdesk>

<https://www.wjgnet.com>

