

World Journal of *Surgical Procedures*

World J Surg Proced 2022 July 15; 12(1): 1-12



ORIGINAL ARTICLE**Clinical Trials Study**

- 1 Freehand-robot-assisted laparoscopic colorectal surgery: Initial experience in the Trinidad and Tobago
Cawich SO, Singh Y, Naraynsingh V, Senasi R, Arulampalam T

CASE REPORT

- 8 Rare case of perforated giant gastric ulcer with concurrent thyroid storm: A case report
Wang JX, Soh LS, Mahendran DCJ, Woon CY, Chia CLK

ABOUT COVER

Editorial Board Member of *World Journal of Surgical Procedures*, Meer M Chisthi, MS, PhD, Professor, Department of General Surgery, Government Medical College, Trivandrum, Kerala 695011, India.
meerchisthi.m@tmc.kerala.gov.in

AIMS AND SCOPE

The primary aim of *World Journal of Surgical Procedures* (WJSP, *World J Surg Proced*) is to provide scholars and readers from various fields of surgical procedures with a platform to publish high-quality basic and clinical research articles and communicate their research findings online.

WJSP mainly publishes articles reporting research results and findings obtained in the field of surgical procedures and covering a wide range of topics including ablation techniques, ambulatory surgical procedures, surgical anastomosis, assisted circulation, bariatric surgery, biopsy, bloodless medical and surgical procedures, non-therapeutic body modification, cardiovascular surgical procedures, curettage, debridement, surgical decompression, deep brain stimulation, device removal, digestive system surgical procedures, dissection, etc.

INDEXING/ABSTRACTING

The WJSP is now abstracted and indexed in Reference Citation Analysis, China National Knowledge Infrastructure, China Science and Technology Journal Database, and Superstar Journals Database.

RESPONSIBLE EDITORS FOR THIS ISSUE

Production Editor: *Yu-Xi Chen*; Production Department Director: *Xu Guo*; Editorial Office Director: *Yun-Xiaoqiao Wu*.

NAME OF JOURNAL

World Journal of Surgical Procedures

ISSN

ISSN 2219-2832 (online)

LAUNCH DATE

December 29, 2011

FREQUENCY

Continuous Publication

EDITORS-IN-CHIEF

Dinesh Vyas, Pankaj Kumar Garg

EDITORIAL BOARD MEMBERS

<https://www.wjgnet.com/2219-2832/editorialboard.htm>

PUBLICATION DATE

July 15, 2022

COPYRIGHT

© 2022 Baishideng Publishing Group Inc

INSTRUCTIONS TO AUTHORS

<https://www.wjgnet.com/bpg/gerinfo/204>

GUIDELINES FOR ETHICS DOCUMENTS

<https://www.wjgnet.com/bpg/gerinfo/287>

GUIDELINES FOR NON-NATIVE SPEAKERS OF ENGLISH

<https://www.wjgnet.com/bpg/gerinfo/240>

PUBLICATION ETHICS

<https://www.wjgnet.com/bpg/gerinfo/288>

PUBLICATION MISCONDUCT

<https://www.wjgnet.com/bpg/gerinfo/208>

ARTICLE PROCESSING CHARGE

<https://www.wjgnet.com/bpg/gerinfo/242>

STEPS FOR SUBMITTING MANUSCRIPTS

<https://www.wjgnet.com/bpg/gerinfo/239>

ONLINE SUBMISSION

<https://www.f6publishing.com>



Rare case of perforated giant gastric ulcer with concurrent thyroid storm: A case report

Jasper Xiangwei Wang, Lin Seong Soh, Dinesh Carl Junis Mahendran, Chang Yi Woon, Clement Luck Khng Chia

Specialty type: Medicine, research and experimental

Provenance and peer review: Invited article; Externally peer reviewed.

Peer-review model: Single blind

Peer-review report's scientific quality classification

Grade A (Excellent): 0
Grade B (Very good): B, B
Grade C (Good): 0
Grade D (Fair): D
Grade E (Poor): 0

P-Reviewer: Awad AK, Egypt; Gao L, China; Luo XZ, China

Received: February 3, 2022

Peer-review started: February 3, 2022

First decision: March 12, 2022

Revised: March 27, 2022

Accepted: April 8, 2022

Article in press: April 8, 2022

Published online: July 15, 2022



Jasper Xiangwei Wang, Lin Seong Soh, Clement Luck Khng Chia, Department of General Surgery, Khoo Teck Puat Hospital, Singapore 768828, Singapore

Dinesh Carl Junis Mahendran, Department of Endocrinology, Khoo Teck Puat Hospital, Singapore 768828, Singapore

Chang Yi Woon, Yong Loo Lin School of Medicine, National University of Singapore, Singapore 117597, Singapore

Corresponding author: Chang Yi Woon, MD, Doctor, Yong Loo Lin School of Medicine, National University of Singapore, 10 Medical Dr, Singapore 117597, Singapore 117597, Singapore. e0345822@u.nus.edu

Abstract

BACKGROUND

Thyroid storm is an uncommon condition manifesting in severe thyrotoxicosis with a high mortality rate. The concurrence of peptic ulcer disease and hyperthyroidism is rare due to concurrent activation of both the sympathetic and parasympathetic pathways. We present a case of perforated giant gastric ulcer with concurrent thyroid storm who underwent damage control surgery with emergency patch repair with falciform ligament and recovered well.

CASE SUMMARY

A 53-year-old male chronic smoker, with no previous medical history, presented with severe generalized abdominal pain and vomiting for one day duration. Further history revealed weight loss, diarrhea, and anxiety over the past three months. On clinical examination, patient was febrile with temperature of 38.6 Degrees Celsius and tachycardic at 130-140 beats per minute, his blood pressure was low at 90/50mmHg. His abdomen was tender with generalized peritonism. In view of his clinical history, a thyroid screen was ordered which showed raised thyroxine (T4) levels of 90.3 pmol/L and low thyroxine stimulating hormone (TSH) levels of 0.005 μ U/mL. Chest X-ray showed no sub-diaphragmatic free air, but contrasted CT scan revealed pneumoperitoneum with large amount of intraabdominal free fluid. The working diagnosis was perforated peptic ulcer complicated by thyroid storm. An urgent endocrinologist consult was made, and patient was started on beta blocker and intravenous steroids pre-operatively. The patient underwent emergency laparotomy with washout and patch repair of the

perforated gastric ulcer. Patient was monitored post-operatively in intensive care unit and required IV hydrocortisone and Lugol's iodine. Histology of the ulcer edges showed no malignancy. On post-operative day seven, T4 decreased to 20.4 pmol/L, TSH was 0.005 mLU/L. His thyroid function test subsequently normalized 3 mo post-operatively with T4 18.1 pmol/L, TSH 1.91 mLU/L. Patient's recovery was otherwise uneventful. Thyroid receptor antibody subsequently was positive, and patient was managed for Grave's disease by the endocrinologist.

CONCLUSION

This case highlights the rare but life-threatening clinical emergency of peptic ulcer perforation complicated by thyroid storm. Multidisciplinary perioperative management is crucial to optimize patient for surgery and damage control principles should be taken for an acute surgical patient with concurrent endocrine crisis.

Key Words: Peptic ulcer; Perforated viscus; Thyroid storm; Multidisciplinary; Grave's disease; Case report

©The Author(s) 2022. Published by Baishideng Publishing Group Inc. All rights reserved.

Core Tip: Concurrent peptic ulcer perforation and thyroid storm is a rare but life-threatening surgical emergency. Multidisciplinary perioperative management is crucial to optimize patient for surgery, and damage control principles should be taken for an acute surgical patient with concurrent endocrine crisis.

Citation: Wang JX, Soh LS, Mahendran DCJ, Woon CY, Chia CLK. Rare case of perforated giant gastric ulcer with concurrent thyroid storm: A case report. *World J Surg Proced* 2022; 12(1): 8-12

URL: <https://www.wjgnet.com/2219-2832/full/v12/i1/8.htm>

DOI: <https://dx.doi.org/10.5412/wjsp.v12.i1.8>

INTRODUCTION

Thyroid storm is an acute, life-threatening, hypermetabolic state manifesting in severe thyrotoxicosis. This condition is uncommon and associated with a high mortality rate. The concurrence of peptic ulcer disease and hyperthyroidism is rare and the association between these two conditions is unusual. Few reports of perforated peptic ulcer complicated by thyroid storm have been reported, and these patients underwent trial of conservative management to optimize thyroid status before some required delayed surgical repair to control sepsis. We present a patient with perforated giant gastric ulcer with concurrent thyroid storm who was peritonitic and underwent damage control surgery with patch repair with falciform ligament and recovered uneventfully.

CASE PRESENTATION

Chief complaints

A 53-year-old male chronic smoker, with no past medical history presented to the emergency department with severe generalized abdominal pain and vomiting for one day duration.

History of present illness

Patient's symptoms started acutely one day ago. A history of weight loss, diarrhea and, anxiety over the preceding three months was also elicited from the patient.

History of past illness

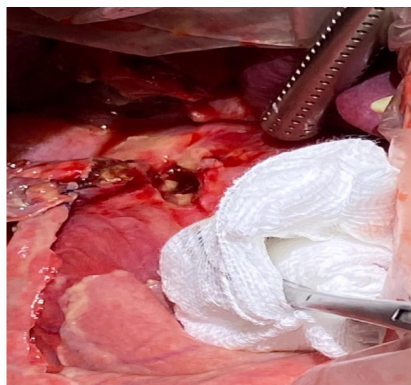
The patient had no past medical history.

Personal and family history

The patient had no significant personal and family history.

Physical examination

Clinically, patient was febrile with temperature of 38.6 Degrees Celsius and tachycardic at 130-140 beats per minute, blood pressure was 90/50 mmHg. On examination, his abdomen was tender with generalized peritonism. There was no goiter.



DOI: 10.5412/wjssp.v12.i1.8 Copyright ©The Author(s) 2022.

Figure 1 Intraoperative picture of perforated giant gastric ulcer.

Laboratory examinations

A thyroid screen was performed in view of patient's history, which revealed a markedly raised thyroxine (T4) levels (90.3 pmol/L) and low levels of thyroid stimulating hormone (TSH) (0.005 μ U/mL) that suggested primary hyperthyroidism.

Imaging examinations

Chest X-ray showed no sub-diaphragmatic free air. A contrasted CT scan was performed and revealed pneumoperitoneum with large amount of intraabdominal free fluid.

MULTIDISCIPLINARY EXPERT CONSULTATION

In view of the suspicion of a concurrent acute thyroid storm in this patient with perforated viscus, a multidisciplinary consult was made with endocrinologist and pharmacist and patient was started on beta blocker and intravenous steroids pre-operatively.

FINAL DIAGNOSIS

The patient underwent emergency laparotomy, and a perforated giant gastric ulcer was found.

TREATMENT

Patient was optimized pre-operatively with beta blocker and intravenous steroids pre-operatively. Intra-operatively, there was gross soilage with a perforated 2.5cm gastric antral ulcer (Figure 1). Damage control surgery was performed, comprising washout and patch repair using a tongue of falciform ligament. Post-operatively, he required IV hydrocortisone and Lugol's iodine with monitoring in intensive care unit (ICU). Hydrocortisone was weaned off after 48 h and patient was started on propylthiouracil (PTU) with sips of water. Feeds were commenced after 3 days and PTU was subsequently changed to oral carbimazole (30 mg/d) on discharge. On post-operative day seven, T4 decreased to 20.4 pmol/L, TSH was 0.005 mLU/L. His thyroid function test subsequently normalized 3 mo post-operatively with T4 at 18.1 pmol/L, TSH 1.91 mLU/L. Ulcer edge histopathology showed organizing fibrosis with no malignancy. Thyroid receptor antibody returned as positive, and he was managed by the endocrinologist for Grave's disease.

OUTCOME AND FOLLOW-UP

The patient had an uneventful postoperative clinical course and was discharged one week post-operatively. He is on follow-up with the endocrinologist for Grave's disease in the outpatient clinic.

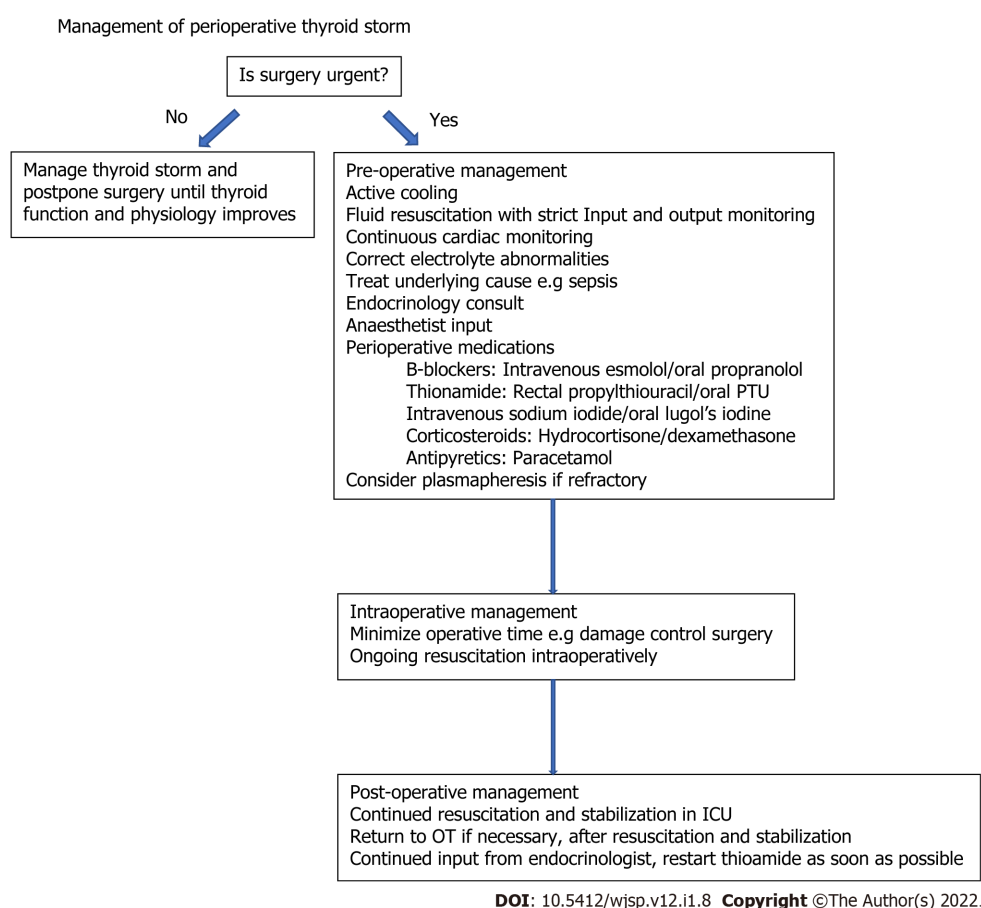


Figure 2 Perioperative management of patient with thyroid storm. PTU: Propylthiouracil; OT: Operating theatre; ICU: Intensive care unit.

DISCUSSION

Although causes for peptic ulcer disease (PUD) are well described, the association between hyperthyroidism and PUD is unusual due to differences in the autonomic activity behind these two disorders. PUD exhibits a parasympathetic predominance whereas sympathetic activity predominates in hyperthyroidism[1] with Ebert *et al*[2] showing that acid secretion is reduced in hyperthyroidism. These findings underscore the rarity of concurrent PUD with hyperthyroidism.

There are 3 cases of perforated peptic ulcer[3-5] complicated by thyroid storm reported in literature. All were treated conservatively till thyroid function improved prior to ulcer repair. While the Burch-Wartofsky score is routinely used as a diagnostic tool for thyroid storm, we note that there are conflicting factors in its calculation due to concurrent sepsis driving tachycardia and fever. However, the clinical history with markedly elevated T4 Levels and suppressed TSH levels suggested underlying untreated hyperthyroidism rather than an acute stress response.

Our patient was clinically septic and had generalized peritonism. IV beta-blockers and steroids were for rapid control of metabolic effects of thyrotoxicosis. Oral PTU was not used as in view of the perforation and requirements to be fasted. The alternative is rectal PTU prepared by the in-house pharmacist, but this requires 3-4 h of lead time. PTU takes days to manifest its anti-thyroid effects. Due to sepsis and peritonism, medical therapy and delay to further optimize him was inappropriate. Therefore, decision was made for emergency laparotomy.

Options for a giant gastric ulcer (defined as ulcer diameter > 2 cm) can be broadly divided into primary repair or resection surgery. The principles of damage control surgery in a severely physiologically challenged patient are central to the decision regarding the type of surgery. The aim is expeditious control of contamination and bringing the patient back to ICU for further resuscitation and restoration of physiology. Hence, a patch repair was chosen instead of a prolonged major resection. However, the lack of omentum in this thin patient made a patch repair challenging. As such an alternative using the falciform ligament which lies across the first part of the duodenum was chosen and easily mobilized for a tension-free patch repair. This case also highlights the utility of falciform ligament pedicle flap[6] as an alternative approach to repair perforated giant gastric ulcers and an attempt should be made to preserve the falciform ligament as a backup during initial midline laparotomy for a perforated viscus rather than routinely ligating and dividing it. Another alternative option to a damage control patch repair for large gastric ulcer perforation would be an ulcerectomy with/without pyloro-

plasty if a patch repair is deemed insufficient.

Postoperatively, the patient was transferred to ICU. The key principles of post-operative critical care management in this patient include aggressive resuscitation with fluids and empirical antibiotics, correction of thyroid dysfunction and nutritional support. Multidisciplinary collaboration involving the surgeon, intensivist and endocrinologist is key to good outcomes in an acute surgical patient with concurrent thyroid storm. A flowchart illustrating the principles of management is summarized in Figure 2.

CONCLUSION

Concurrent peptic ulcer perforation with thyroid storm is a rare but life-threatening surgical emergency. Multidisciplinary perioperative management and damage control surgery are critical to control sepsis, restore physiology and correct thyroid dysfunction in an expeditious fashion.

FOOTNOTES

Author contributions: Wang JX, Soh LS, and Chia LKC were the patient's general surgeons, reviewed the literature and contributed to manuscript drafting; Mahendran D performed the endocrinological consult for the patient, reviewed the literature, and contributed to manuscript drafting; Woon CY was responsible for the revision of the manuscript; all authors issued final approval for the version to be submitted.

Informed consent statement: Informed written consent was obtained from the patient for publication of this report and any accompanying images.

Conflict-of-interest statement: The authors declare that they have no conflict of interest.

CARE Checklist (2016) statement: The authors have read the CARE Checklist (2016), and the manuscript was prepared and revised according to the CARE Checklist (2016).

Open-Access: This article is an open-access article that was selected by an in-house editor and fully peer-reviewed by external reviewers. It is distributed in accordance with the Creative Commons Attribution NonCommercial (CC BY-NC 4.0) license, which permits others to distribute, remix, adapt, build upon this work non-commercially, and license their derivative works on different terms, provided the original work is properly cited and the use is non-commercial. See: <https://creativecommons.org/licenses/by-nc/4.0/>

Country/Territory of origin: Singapore

ORCID number: Jasper Xiangwei Wang 0000-0002-8115-0945; Lin Seong Soh 0000-0003-2872-6914; Dinesh Carl Junis Mahendran 0000-0001-8598-6961; Chang Yi Woon 0000-0001-6730-6774; Clement Luck Khng Chia 0000-0003-2248-9348.

S-Editor: Wang LL

L-Editor: A

P-Editor: Wang LL

REFERENCES

- Gill AM, Walton FW. Hyperthyroidism and peptic ulcer. *Lancet* 1952; **1**: 693-694 [PMID: 14909525 DOI: 10.1016/s0140-6736(52)90452-2]
- Ebert EC. The Thyroid and the Gut. *J Clin Gastroenterol* 2010; **44**: 402-406 [DOI: 10.1097/mcg.0b013e3181d6bc3e]
- Ogiso S, Inamoto S, Hata H, Yamaguchi T, Otani T, Koizumi K. Successful treatment of gastric perforation with thyrotoxic crisis. *Am J Emerg Med* 2008; **26**: 1065.e3-1065.e4 [PMID: 19091282 DOI: 10.1016/j.ajem.2008.03.005]
- Zweig SB, Schlosser JR, Thomas SA, Levy CJ, Fleckman AM. Rectal administration of propylthiouracil in suppository form in patients with thyrotoxicosis and critical illness: case report and review of literature. *Endocr Pract* 2006; **12**: 43-47 [PMID: 16524862 DOI: 10.4158/EP.12.1.43]
- Alfadhli E, Gianoukakis AG. Management of severe thyrotoxicosis when the gastrointestinal tract is compromised. *Thyroid* 2011; **21**: 215-220 [PMID: 21254909 DOI: 10.1089/thy.2010.0159]
- Boshnaq M, Thakrar A, Martini I, Doughan S. Utilisation of the falciform ligament pedicle flap as an alternative approach for the repair of a perforated gastric ulcer. *BMJ Case Rep* 2016; **2016** [PMID: 27102415 DOI: 10.1136/bcr-2015-213025]



Published by **Baishideng Publishing Group Inc**
7041 Koll Center Parkway, Suite 160, Pleasanton, CA 94566, USA

Telephone: +1-925-3991568

E-mail: bpgoffice@wjgnet.com

Help Desk: <https://www.f6publishing.com/helpdesk>

<https://www.wjgnet.com>

